

SURGICAL DIAGNOSIS

BY

DANIEL N. EISENDRATH, A.B., M.D.

ADJUNCT PROFESSOR OF SURGERY IN THE MEDICAL DEPARTMENT OF THE UNIVERSITY OF ILLINOIS (COLLEGE OF PHYSICIANS AND SURGEONS); ATTENDING SURGEON TO THE MICHAEL REESE AND COOK COUNTY HOSPITALS, CHICAGO

WITH FOUR HUNDRED AND EIGHTY-TWO ORIGINAL ILLUSTRATIONS, FIFTEEN OF THEM IN COLORS

PHILADELPHIA AND LONDON

W. B. SAUNDERS COMPANY

1907

Copyright, 1907, by W. B. Saunders Company

PRINTED IN PHILADELPHIA

PREFACE.

A recognition of the necessity of making a correct diagnosis before instituting treatment has prompted me to write this treatise. I have omitted the diagnosis of affections of the eye, ear, nose, throat, and skin, since these are so fully considered in the special treatises upon these subjects. The only exceptions are the intracranial complications of middle ear and mastoid disease and those affections of the upper respiratory tract which require major surgical intervention.

The question of diagnosis has been approached chiefly from the clinical standpoint. An attempt has been made to group injuries and diseases in the manner in which the surgeon or general practitioner must consider them when he examines a patient for the purpose of making a diagnosis. Thus, in the chapter upon injuries of the head, the various traumatic lesions of the scalp, skull, and brain are considered together. In the chapter upon the abdomen the injuries of all of the abdominal viscera are taken up in a similar manner.

The division of diseases of the abdomen into acute abdominal affections, abdominal tumors, and a further description of the remaining surgical conditions of the abdominal viscera, may occasion some criticism. In making such an apparently arbitrary classification I have had in mind the clinical picture as one encounters it at the bedside. Although such divisions are not appropriate for a text-book which includes pathology and treatment, they seem most practical for a book limited to diagnosis.

The same principle has been applied throughout. The importance of differentiation of affections which simulate each other has been constantly borne in mind, repetition being avoided as much as possible. The necessity of making a diagnosis at an early period for the purpose of instituting prompt surgical intervention, is frequently referred to. Much attention has been paid to the description of methods of examination, and this has been aided wherever possible by illustrations.

Being a strong advocate of the teaching of surgery by the education of the eye, I have introduced a large number of original illustrations of clinical cases and specimens. I am indebted to my colleagues upon the staffs of the Cook County and Michael Reese Hospitals for the privilege

of photographing many of their patients. I desire to thank Drs. M. L. Blatt and F. Baumann for valuable suggestions. The section upon methods of blood examination was written by Dr. D. L. Schram. The section upon cystoscopy and ureteral catheterization was written by Dr. Gustav Kolischer.

DANIEL N. EISENDRATH.

April, 1907.

CONTENTS.

CHAPTER I.

PAGE

SURGICAL AFFECTIONS OF THE HEAD 17
Injuries of the Scalp, Skull, and Brain 17
Injuries of the Scalp 17
Fractures of the Skull 22
Concussion of the Brain 35
Compression of the Brain 36
Cerebral Contusion or Laceration 42
Cerebral Localization 44
Intracranial Hemorrhage 48
Differential Diagnosis of Injuries of the Brain 54
Pachymeningitis Hæmorrhagica Interna 55
Intracranial Suppuration Following Injuries 55
Contusions of the Cranial Bones 61
Hernia Cerebri 62
Traumatic Epilepsy 62
Mental Conditions Following Cranial Injury 64
Diseases of the Scalp, Skull, and Brain 65
Diseases of the Scalp 65
Non-traumatic Surgical Diseases of the Brain and its Envelopes 73
Intracranial Complications of Middle Ear and Mastoid Suppuration 80
Injuries and Diseases of the Face 86
Injuries of the Soft Parts of the Face 86
Injuries of the Bones of the Face 87
Diseases of the Soft Parts of the Face 91
Diseases of the Mouth and Palate 103
The Lips 104
Diseases of the Jaws 108
Tumors 108
Infections 117
Diseases of the Temporo-maxillary Joint 122
Diseases of the Mouth 123
Stomatitis 123
Syphilis 124
The Diagnosis of Conditions at the Floor of the Mouth 124
Tumors of the Inside of the Cheeks 127
Tumors of the Palate 127
The Tongue 127
Affections of the Salivary Glands 138

CHAPTER II.

SURGICAL AFFECTIONS OF THE NECK 147
Congenital and Acquired Malformations 147

PAGE
Injuries of the Neck ... 152
Foreign Bodies in the Air Passages ... 156
Inflammatory Processes ... 157
Infection of the Superficial Structures of the Neck ... 160
Affections of the Lymph-nodes of the Neck ... 162
Tumors of the Neck ... 172
Cystic Tumors ... 174
Solid Tumors ... 178
Non-malignant Goiter ... 185
Malignant Goiter ... 187
Thyroiditis ... 188
Exophthalmic Goiter ... 189
Edema of the Glottis ... 190
Papilloma of the Larynx ... 190
Carcinoma of the Larynx ... 191

CHAPTER III.

THORAX ... 193
Injuries of the Bony Walls of the Thorax ... 193
Fractures of the Ribs ... 193
Fractures of the Costal Cartilages ... 194
Fractures of the Sternum ... 194
Injuries of the Thoracic Viscera ... 195
Non-penetrating or Subcutaneous ... 195
Penetrating Injuries of the Thorax Proper ... 199
Acute and Chronic Inflammatory Processes of the Thoracic Wall ... 201
Of the Skin and Subcutaneous Tissues ... 201
Affections of the Bony Thorax ... 202
Tumors of the Chest Wall ... 206
Empyema ... 208
Tumors of the Pleura ... 212
Pulmonary Abscess, Gangrene, and Bronchiectasis ... 213
Echinococcus of the Lungs ... 216
Actinomycosis of the Lungs and Pleura ... 216
Tumors of the Lungs ... 217
Suppurative Pericarditis ... 217
Affections of the Mediastinum ... 218
Inflammatory Processes ... 218
Tumors ... 219
Foreign Bodies in the Air Passages ... 220
Diseases of the Breast ... 221
Inflammatory Processes ... 221
Tuberculosis ... 225
Hypertrophy ... 227
Neoplasms ... 227

CHAPTER IV.

ABDOMEN ... 231
Affections of the Abdominal Wall ... 231
Inflammatory Processes ... 231
Tumors ... 233
Congenital Conditions ... 235

PAGE

Abscesses Discharging through Umbilicus ... 236
Tumors of the Umbilicus ... 236
Injuries of the Abdominal Walls and Viscera ... 237
Acute Abdominal Affections ... 245
Acute Cholecystitis ... 246
Hepatic Infections ... 248
Primary Forms of Peritonitis ... 250
Renal Infection ... 251
Subphrenic Abscess ... 253
Suppurating Echinococcus Cysts of the Liver ... 254
Pericolitis Sinistra ... 255
Multiple Abscesses of the Omentum ... 255
Appendicitis ... 256
Gallstone Colic ... 264
Perforations of Ulcers of the Stomach or Duodenum ... 266
Acute Pancreatitis ... 270
Renal Colic ... 270
Dietl's Crises ... 271
Embolism and Thrombosis of the Mesenteric Vessels ... 272
Torsion of the Pedicles of Ovarian and Uterine Tumors ... 273
Torsion of the Spermatic Cord ... 274
Visceral Crises ... 274
Angina Sclerotica Abdominis ... 276
Referred Pain from Spinal and Thoracic Conditions ... 276
Inflammation of the Intraabdominal Portion of the Vas Deferens ... 276
Acute Intestinal Obstruction ... 277
Ruptured Extrauterine Pregnancy ... 284
Abdominal Tumors ... 285
Tumors of the Stomach ... 289
Tumors of the Liver ... 291
Tumors of the Gallbladder ... 297
Tumors of the Pancreas ... 299
Tumors of the Spleen ... 304
Tumors of the Intestines ... 307
Tumors of the Peritoneum and Mesentery ... 310
Tumors of the Kidney ... 311
Ascites ... 318
Tumors due to Inflammatory Exudates or to Tuberculous Peritonitis ... 320
Tumors due to Aneurysms of the Abdominal Aorta or its Branches ... 321
Tumors of the Abdomen having their Origin in the Pelvic Viscera or Bones. 323
Diseases of the Esophagus ... 324
Stricture ... 324
Diverticula ... 329
Idiopathic Dilatation ... 330
Foregin Bodies ... 330
Other Abdominal Conditions ... 331
Surgical Diseases of the Stomach ... 331
Gallstones ... 337
Appendicitis (Chronic) ... 340
Chronic Intestinal Obstruction ... 341
Tuberculous Peritonitis ... 343
The Rectum ... 345

PAGE

Methods of Examination ... 345
Congenital Malformations ... 346
Injuries ... 347
Foreign Bodies ... 348
Inflammatory Processes ... 349
Hemorrhoids ... 355
Prolapse ... 356
Strictures ... 357
Neoplasms ... 359
Renal and Vesical Lesions ... 361
Older and Newer Methods of Diagnosis ... 361
Pyelitis ... 362
Tuberculosis of the Kidney ... 363
Diagnosis of Renal Calculi ... 365
The Bladder ... 371
Congenital Malformations ... 371
Wounds ... 372
Inflammation ... 372
Tuberculosis ... 374
Calculi ... 375
Tumors ... 376
Affections of the Prostate ... 377
Enlargement ... 377
Injuries and Diseases of the Urethra and Penis ... 379
Congenital Malformations ... 379
Contusion and Rupture of the Urethra ... 380
Localization of Pus in the Lower Portion of the Male Genito-urinary Tract ... 381
Phimosis ... 385
Paraphimosis ... 385
Balanitis ... 385
Epithelioma of the Penis ... 386
The Testes ... 387
Abnormalities in Development ... 387
Imperfect Descent and its Complications ... 388
Infections of the Male Reproductive Organs ... 391
Traumatic Affections ... 393
Tuberculosis ... 393
Syphilis ... 398
Tumors of the Testis and Epididymis ... 399
Spermatocele ... 399
Neoplasms of the Testis ... 399
Hernia ... 401
Inguinal Hernia ... 404
Femoral Hernia ... 414
Umbilical Hernia ... 417
Ventral Hernia ... 420
Rarer Forms of Hernia ... 421

CHAPTER V.

The Extremities ... 422
Injuries of the Soft Tissues, Bones, and Joints ... 422
Injuries of Muscles, Tendons, and Tendon-sheaths ... 424

PAGE
Injuries of Blood-vessels 429
Injuries of Nerves 433
Injuries of Individual Nerves 435
General Considerations upon Injuries of the Bones 438
General Considerations upon Injuries of the Joints 450
General Considerations upon Dislocations 456
Special Fractures and Dislocations 461
Complications of Injuries 525
Shock and Hemorrhage 525
Traumatic Delirium and Delirium Tremens 528
Infective Complications of Wounds 529
Surgical Diseases of the Extremities 544
Affections of the Skin and Subcutaneous Tissues 544
Surgical Diseases of the Skin 554
Diseases of the Arteries 557
Diseases of the Veins 561
Diseases of the Lymph-vessels 563
Diseases of the Lymph-nodes 565
Diseases of the Bursæ 566
Diseases of the Tendons and Tendon-sheaths 567
Diseases of Muscles 570
Diseases of the Fasciæ 573
Diseases of the Nerves 573
Diseases of the Bones 575
Diseases of the Joints in General 601
Diseases of the Individual Joints 627
Diseases of the Knee-joint 639
Diseases of the Ankle-joint 644
Deformities 646

CHAPTER VI.

Diseases and Injuries of the Spine 662
Spina Bifida 662
Injuries of the Spine 664
Spinal Localization 666
Diseases of the Spine 684
Tuberculous Spondylitis (Pott's Disease) 684
Scoliosis (Lateral Curvature of the Spine) 690
Arthritis Deformans (Spondylitis Deformans) 691
Acute Osteomyelitis 691
Typhoid Spine 692
Hysterical Spine 692
Tumors of the Spine and Spinal Cord 692
Sacrococcygeal Tumors 695

CHAPTER VII.

Postoperative Complications 696
Hemorrhage 696
Shock and Collapse 699
Infection 700
Pulmonary Complications 701

PAGE

Cardiac Complications ... 702
Hepatic Complications ... 703
Gastric Complications ... 704
Postoperative Ileus ... 707
Postoperative Peritonitis ... 708
Renal Complications ... 709
Circulatory Complications ... 710
Miscellaneous Complications ... 711
Diabetic Complications ... 712
Postoperative Parotitis ... 713
Status Thymicus ... 713
Acute Thyroidism ... 714
Postoperative Hysteria ... 714

CHAPTER VIII.

METHODS OF EXAMINATION ... 715
Examination of the Blood in Surgical Cases ... 715
Differential Leukocyte-count ... 715
Opsonins and the Opsonic Index ... 716
Leukopenia, Leukocytosis, and Hyperleukocytosis ... 720
Value of the Differential Leukocyte-count ... 725
Pernicious Anemia ... 728
Leukemia ... 728
Estimation of Blood-pressure in Surgical Cases ... 729
Cytodiagnosis ... 731
Examination of the Sputum, Stomach Contents, Urine, and Feces ... 732
The Newer Methods of Diagnosis of Renal Lesions ... 732

INDEX ... 751

SURGICAL DIAGNOSIS.

CHAPTER I.

SURGICAL AFFECTIONS OF THE HEAD.

INJURIES OF THE SCALP, SKULL, AND BRAIN.

For clinical purposes the scalp can be considered as composed of three layers (Fig. 1), viz., the outer or cutaneo-aponeurotic, the middle or subaponeurotic, and the inner or pericranial. In infants the last-named layer or pericranium is loosely attached to the skull, except along the sutures, while in the adult it is so firmly attached over the entire vertex that it can be torn off only with difficulty.

INJURIES OF THE SCALP.

These occur either in the form (*a*) of penetrating, *i. e.*, lacerated, incised, or punctured wounds, which may penetrate one or more of the layers, or (*b*) appear as contusions with swelling of these layers caused by extravasation of blood, or (*c*) the two forms may be combined.

Penetrating Wounds.—The diagnosis of these is readily made by inspection, which should be preceded by shaving the scalp for a distance of at least three inches from the edges of the wound. The chief point of interest is to ascertain whether they simply extend (*a*) through the skin and subcutaneous tissue, or (*b*) through the aponeurosis. Wounds of the former class never gape, while in those of the latter class the edges separate. Retraction of these edges will enable one to determine whether the wound also involves the pericranium and skull. It cannot be too strongly emphasized that the greatest care should be exercised to render aseptic not only the scalp itself, but also the hands of the examiner and the instruments to be employed, before an exploration of the depth and possible complications of a scalp wound are begun. The injury of the larger arteries of the scalp can be suspected when the hemorrhage is profuse and of a spurting character, especially

when the wounds are situated close to the frontal, temporal, or occipital arteries.

Contused Wounds of the Scalp.—The diagnosis of these must be made from a consideration of the age, the history, and the local findings. They may be quite superficial, causing only slight swelling and discoloration of the skin, or deeper, resulting in quite visible tumors (Fig. 1). The diagnosis of the former presents no difficulties.

In the deeper or more severe form anatomical peculiarities play a rôle. *In infants and young children* contusions of the scalp are often followed by marked swelling. This is especially the case in infants following a difficult labor, where considerable pressure has been exerted upon the head by instruments or by the bony pelvis.

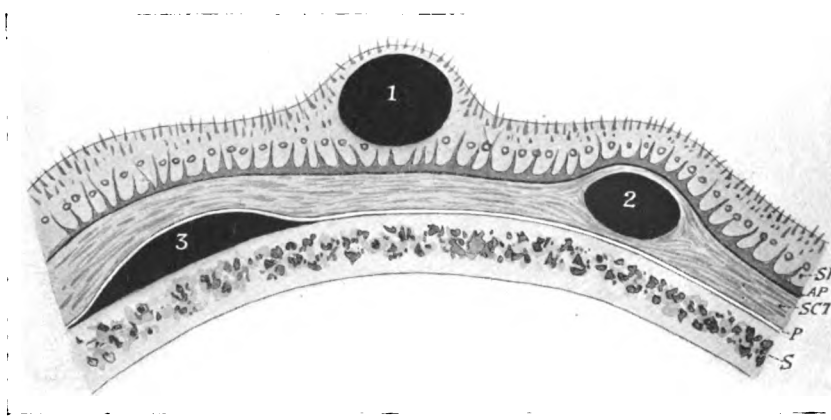

FIG. 1.—LOCATION OF VARIOUS HEMORRHAGES IN THE SCALP.

SK and *AP* represent the cutaneo-aponeurotic layer; *P*, pericranium; *S*, skull; 1, superficial hematoma or contusion in skin proper of scalp; 2, hemorrhage or pus-formation in subaponeurotic layer; 3, subpericranial hemorrhage. The latter is the location of the hemorrhage in the cephalhematoma of infants.

Such swellings are called *cephalhematomata*, and are the result of an extravasation of blood between the pericranium and the skull (Fig. 1). The pericranium, as was stated above, is loosely attached except along the sutures; hence the diagnostic features are that these cephalhematomata are situated over one or both parietal bones (Fig. 2), and can be followed until they terminate at the sutures (either coronal, sagittal, or lambdoidal). They fluctuate, but do not pulsate or increase in size when the child cries. The absence of the latter two features in cephalhematomata and the fact that meningoceles almost always occur in the frontal or the occipital region enable one to differentiate these two conditions in the scalps of young infants. At a later period (four to six weeks) a zone of ossification often begins at the edge of a ceph-

alhematoma, and, in the absence of the history, a fracture might be thought of. The limitation of the swelling by the sutures, the distinct fluctuation to be obtained, and the fact that pressure does not reveal any defect in the skull or cause any cerebral symptoms, enable one to exclude a fracture.

A cephalhematoma may at times occur without the history of injury in scorbutic and rachitic children, and be mistaken for an abscess following tuberculosis of the cranial bones.

It would seem advisable in connection with the subject of cephalhematoma in infants and young children to call attention to a swelling which may produce a considerable elevation of the overlying intact scalp. This swelling follows an injury to the scalp and skull in children in the first three or four years of life, and is called *traumatic cephalhydrocele* (Fig. 3) or *meningocele spuria traumatica*. The injury may have been accompanied by symptoms of cerebral concussion or contusion, but at times cases present themselves years after such an injury, or the latter has been so insignificant that no importance is ascribed to it. Such swellings may appear over any part of the vertex of the skull, and are due to the accumulation of cerebrospinal fluid between the scalp and the skull, which has escaped through an opening following a fracture. These swellings have, as a rule, a pulsation which is synchronous with that of the heart, but cases have been recorded where there is no pulsation. The swelling can be reduced, and when this is done, the edges of the skull opening can be felt. Often such a reduction causes compression symptoms. These spurious or false meningoceles must be differentiated from the following conditions:

FIG. 2.—CEPHALHEMATOMATA OF NEWBORN CHILD.
1, Hematoma over right parietal bone; 2, hematoma over left parietal bone.

1. Deep cavernous angiomata. These may show distinct fluctuation

and pulsation and can be decreased in size by compression, but firm pressure upon the veins leading to them will cause all these signs to disappear. In addition there is no peripheral elevation of bone, and no defect in the skull can be felt.

2. Hematomata or blood-cysts beneath the pericranium, following fractures of the skull, which communicate with the longitudinal or lateral sinuses. They are often called *sinus pericranii*, and are quite rare, only ten cases having been reported. They are more prominent when the patient bends forward, and are due to the rupture of an emissary vein which does not heal and which communicates with a sinus.

3. Congenital meningocele and encephalocele. These have a somewhat constant location in the frontal or the occipital region; there

FIG. 3.—MENINGOCELE SPURIA TRAUMATICA (Bayerthal).

is an absence of a history of injury, and the defect in the skull is round and smaller than the tumor itself.

4. Soft sarcomata of the dura which form subcutaneous tumors after penetrating the skull. These may pulsate, and can be reduced by pressure, but do not fluctuate, and there is usually a history of gradual growth without preceding trauma.

In older children and in adults, contusion of the scalp may be followed by a hematoma in the subcutaneous tissue, forming a swelling which can be moved upon the skull (superficial hematoma), or it may result in the escape of a larger or smaller quantity of blood into the subaponeurotic layer (Fig. 1). As was stated above (see page 17), the pericranium in the adult is so firmly attached to the skull that the

escape of blood beneath it is not sufficient to be recognized, in the absence of a penetrating wound. A subaponeurotic or deep hematoma often follows a severe contusion of the scalp. Its edges are frequently firm and elevated and its center depressed, resembling under these conditions a depressed fracture of the skull. By passing the finger firmly from the surrounding uninjured scalp across the peripheral elevation, one will find that the latter is above the level of the skull (Fig. 4) and can be pressed away. The edges of such a hematoma lack the hardness of the skull bone and also the sharp outline of a fractured bone.

In some cases, especially when there is an accompanying coma of uncertain origin and non-surgical conditions have been eliminated, the diagnosis of a simple contusion of the scalp is perplexing and justifies an exploratory incision carried out under proper precautions. The diagnosis becomes especially difficult when the patient is seen several days after the injury, and an infection of the hematoma has begun (see page 66).

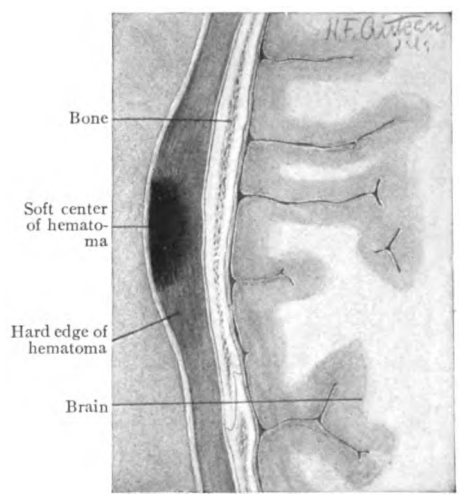

FIG. 4.—HEMATOMA OF SCALP, THE SOFT CENTER AND FIRM EDGE OF WHICH OFTEN SIMULATE FRACTURE (Scudder).

The hematoma may be quite extensive and communicate with a ruptured artery of the scalp, causing distinct pulsations (pulsating hematoma).

At times after a fracture of the vertex, especially in children, a large hematoma will form without a scalp wound, but accompanied by symptoms of compression (see page 36). In one case observed by the author there was a direct communication between the scalp hematoma and a ruptured middle meningeal artery. The compression symptoms are the only means of diagnosing such an injury, and in their absence it would be impossible to trace any relation between a large hematoma of the scalp and intracranial hemorrhage.

FRACTURES OF THE SKULL.

The diagnosis of a fracture of the skull must be based upon a consideration of the following points:

I. The history of the mode of injury.

II. The direct examination of the vertex.

III. The interpretation of certain special signs indicating fracture of the base.

IV. Evidences of injury of the intracranial structures.

I. History of the Mode of Injury.

At the time of the accident this is of subordinate value, because a careful estimate of the evidence obtained from the other three factors will usually enable a diagnosis to be made. At a later period, however, the possibility of a fracture having been the result of a certain mode of injury may arise, and an exact history should be obtained.

In general, fractures of the skull are produced by a force acting in one of two ways: First, upon some one point in the skull; for example, a blow with a hammer, a bayonet, or a bullet. A fracture is far more likely to occur where the force acts thus on a circumscribed area than in the second variety, where it is distributed in meridians radiating from the point of impact, and perhaps producing a fracture at some distant point, where the elasticity of the bone yields. A fall upon the vertex, the feet, or the buttocks is an example of a force acting thus in a more diffuse manner and, as a rule, a fracture is not so likely to follow it. The history of a gunshot or a punctured wound of the mouth or orbit is of aid in diagnosing a fracture of the base.

The history may be of some confirmatory value in the following instances: (*a*) Where a hematoma of the scalp (see page 21) resembles a simple depressed fracture. Here the history of some force applied in a concentrated manner should lead one to examine for other evidences of fracture, such as those of intracranial injuries. (*b*) Where bleeding from the nose and ears and other signs of basal fracture exist without coma, etc. A fall upon the vertex may by transmission of force produce a fracture at the base by meridional distribution and such a history will be of aid in confirming the above evidences of a fracture of the base. (*c*) When Jacksonian epilepsy has developed, the likelihood of a fracture having been sustained at the time of injury is greater if there is a history of a blow having been struck by some instrument or missile (*e. g.*, mallet, iron bar, a rock, etc.) capable of producing a circumscribed injury.

II. Examination of the Vertex.

This must be made under one of *two* conditions: (*a*) Where no open wound exists as a result of the accident, as is the case in simple fractures; (*b*) where a wound of the scalp leads either directly or indirectly to the seat of the fracture, as in compound fractures.

(*a*) *Where no Scalp Wound is Present.*—Under these circumstances our only method of diagnosis from an examination of the skull lies in direct palpation of a fissure or of a depression. In the case of a fissure this is usually impossible unless the fissure is very wide, and

Fig. 5.—Simple Depressed Fracture of the Skull in an Infant, without Symptoms. No Treatment. Gradual Disappearance of Depression (Elliot's Case).

in the absence of more direct evidence of intracranial injury is absolutely unreliable as an aid to diagnosis. In the case of a depression apparently in the vertex, which can be felt by passing the finger over the intact scalp, the following conditions must be excluded before a diagnosis of depressed fracture should be made.

1. The possibility of a hematoma of the scalp resembling a depressed fracture (see page 21).

2. Normal depressions in the adult skull, especially in the aged. One should always compare the two sides of the skull a number of times when palpating it through the intact scalp.

3. Depressions due to congenital defects, *e. g.*, meningocele.

4. Depressions due to the presence of Wormian bones.

5. Depressions following the softening of syphilitic gummata with thickening of the periosteum at the edges of such a depression.

6. Depressions due to pressure on the head by the bony pelvis or by forceps during birth. Such depressions can occur in the infant's skull, owing to its great elasticity, and upon first examination feel like a depressed gutter fracture. They rarely persist, but correct themselves spontaneously within a few weeks (Fig. 5).

In a case of depressed fracture occurring without scalp injury

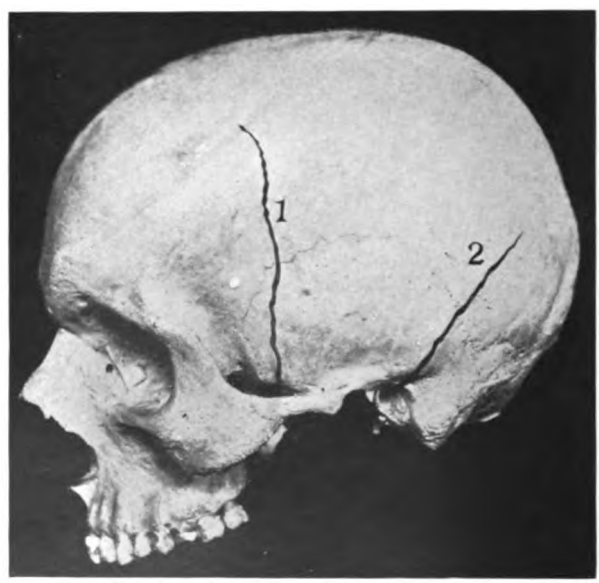

FIG. 6.—LOCATION OF MOST FREQUENT LINES OF FISSURED FRACTURE OF THE SKULL, EXTENDING INTO THE BASE.

Fissure extending through temporo-parietal bone into middle fossa; 2, fissure extending through occipital and temporal bones into base of skull, the petrous portion of the temporal bone.

the palpation of the irregular sharp edges of the bone will serve to distinguish it from the smooth edges of a congenital defect. The frequent location of the congenital defects in the parietal and occipital bones, will also be of aid.

In a case of depression following syphilis the history and the presence of other evidences of the tertiary stage will clear up the diagnosis.

At the present time the surgeon should never be content with making a diagnosis of depressed fracture of the vertex without a visual inspection of the skull through an exploratory incision made under proper precautions.

(*b*) *Examination of the Vertex where a Wound of the Scalp Exists* (*Compound Fracture*).—Under these conditions the diagnosis is comparatively easy in the majority of cases by both inspection and palpation at the seat of fracture if the patient is seen immediately after the injury.

A fissured fracture can be recognized as a fine, hair-like opening, from which blood escapes (Figs. 6, 7, and 8). At times the edges may gape. The fissure can be followed in many cases until it disappears at the base of the skull. One can differentiate it from a suture by the fact that it is impossible to rub the blood away in the case of a fracture. The diagnosis is confirmed in many cases by evidences of fracture of the base (see below), or by those of intracranial injury (see page 34).

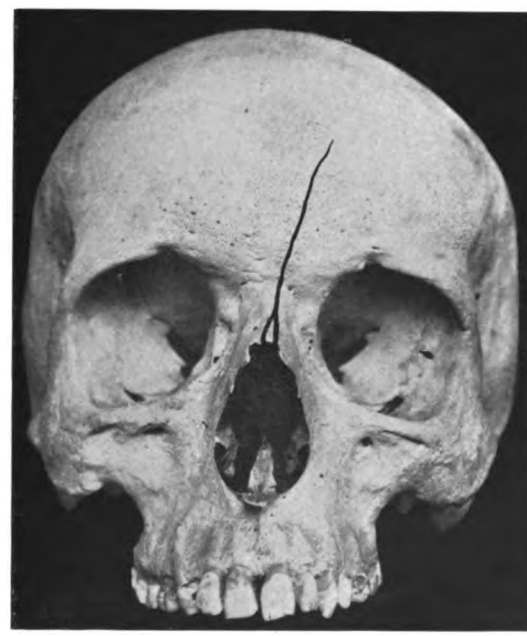

FIG. 7.—FRACTURE OF FRONTAL AND NASAL BONES.

A depressed fracture of the vertex can be readily diagnosed when the edges of the scalp wound are retracted. The depression may be linear, *i.e.*, there may be one or more large fragments which have slipped under and are firmly fixed beneath the adjacent skull, or the depression may be gutter-like or saucer-like, the center of the depression resembling the center of a star, from which the lines of fracture radiate (Fig. 14).

The diagnosis of a punctured fracture of the skull, such as follows a bayonet thrust, a bullet, or the use of some sharp projectile can be made—(*a*) from the history; (*b*) from the appearance of the scalp wound, and (*c*) from the examination of the skull itself.

The question may arise, How deep does the fracture extend? It may, in general, be said that:

1. Fractures of the external table alone can be diagnosed positively

as only involving this table, if the fragments are removed. Such a fracture may occur when the skull is struck obliquely by a sharp instrument, or in the mastoid or the frontal regions, where a considerable interval exists between the two tables.

2. Fractures of the internal table alone can be diagnosed only from the symptoms of the accompanying intracranial injury.

3. Fractures of both tables, of course, exist when there is a visible depression and after the majority of punctured or bullet wounds. Under the latter two of these conditions the internal table is more extensively involved. In a fissured fracture one can diagnose a fracture

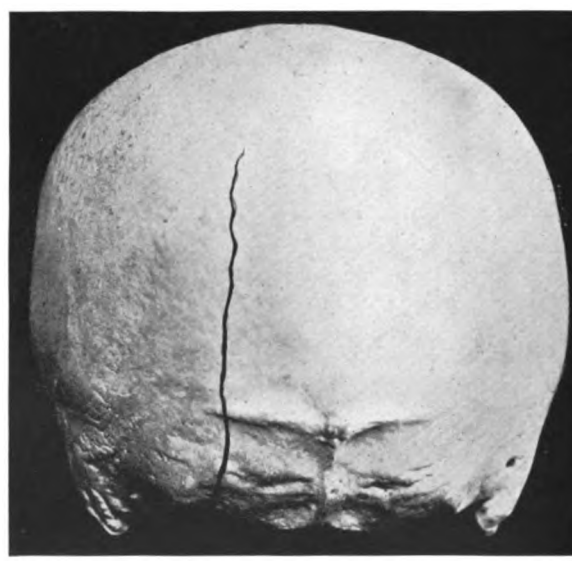

FIG. 8.—FRACTURE OF OCCIPITAL BONE EXTENDING INTO THE POSTERIOR FOSSA.

of both tables if there is evidence of intracranial injury or if the fissure is enlarged by chiseling. This latter step is never justifiable for merely diagnostic reasons in the absence of serious symptoms.

Diagnosis of Fracture of the Skull at a Later Period.—The question may arise months or perhaps years after an injury, when one of the late sequelæ, such as Jacksonian epilepsy, insanity, etc., have developed, as to whether a fracture had ever occurred. In the absence of a history from a reliable source, we must depend upon our objective examination, which may show one or all of the following:

1. Deformity in the shape of a depression of the vertex. All the conditions enumerated on page 23 must be excluded.

2. Hyperesthesia of the scalp, which can be determined by repeated tests.

3. A painful scar. At times pressure upon such a cicatrix may cause an aura.

4. Persisting evidences of intracranial injury or of fracture of the base, such as nerve paralysis, etc.

5. The development of a traumatic cephalhydrocele in children is positive proof of a fracture having occurred (see page 19).

III. The Interpretation of Certain Special Signs of Fracture of the Base.

The diagnosis of a fracture of the base of the skull is made from one or more of the following signs:

1. Hemorrhages into or the presence of air in the tissues around the base.

2. Escape of blood, cerebrospinal fluid, or even brain substance externally from certain cavities, such as the ear, nose, and mouth, which communicate with the seat of fracture.

3. Evidence of injury of the cranial nerves or of the vessels at the base of the skull.

1. **Hemorrhages or the Presence of Air in the Tissues.**—Ecchymoses appearing in the eyelids, around the mastoid, or the nape of the neck are of value, if the blow has not been received over the region in which the subcutaneous hemorrhages have occurred, and especially if the latter begin to appear some hours after the injury, and increase in amount in the first few days. Orbital (subconjunctival) hemorrhages are quite frequently present, and, if excessive, an exophthalmos may be produced, which is almost positive evidence of a basal fracture. Escape of air into the subcutaneous tissues, producing emphysema or a crackling sensation of the skin upon palpation, only occurs after fractures communicating with the mastoid cells or frontal sinuses, and, when found, is positive evidence of a fracture.

2. **Escape of Blood, etc., from the Ear, Nose, and Mouth.**—The escape of blood from the ear from other causes than a fracture of the base is of short duration and small in amount. Bleeding may occur from one ear alone, and this is very frequent, or it may take place from both. If it spurts, the internal carotid artery must have been torn. If it occurs in very large quantity without pulsation, a large sinus has been lacerated. Bleeding from the ear can be said to be due to a basal fracture, if after cleansing the ear and wiping out the blood one excludes the following sources of hemorrhage: Tearing of the cartilagi-

nous auditory canal in its anterior or posterior wall, simple rupture of the membrana tympani, and flow of blood from wounds of the scalp or external ear into the canal. The first and last of these can be eliminated by cleansing the ear and then observing the reaccumulation of blood. The rupture of the membrana tympani causes only a slight and transitory hemorrhage.

Blood escaping from the nose or mouth is only of diagnostic value if one can exclude local injury, and if it persists for a number of hours. Very rarely one can observe hemorrhage in the retropharygneal structures or the escape of blood from the Eustachian tube, when the membrana tympani is not torn.

The flow of cerebrospinal fluid most often occurs from the ear, and can be distinguished from blood-serum by the large quantity of fluid, the high percentage of sodium chlorid and the small percentage of albumin which it contains.

Less frequently cerebrospinal fluid may escape from the mouth or nose. Several cases have been reported where a diagnosis of basal fracture has been confirmed by the flow of cerebrospinal fluid persisting for years after the injury (rhinorrhea). The flow, whether from the nose, mouth, or ear, is increased by coughing or any form of exertion.

The escape of brain tissue is rare, except in fractures involving the orbit or the temporal bone, and, when present, is absolute evidence of a fracture. One can then find ganglion-cells microscopically.

3. **Injuries of the Nerves and Vessels at the Base.**—(*a*) *Injuries of Nerves in Basal Fractures.*—In the majority of fractures of the base, certain cranial nerves are more frequently injured than others, owing to the fact that the majority of the fractures pass through the petrous portion of the temporal bone (Fig. 12), and from here forward; hence one should always examine a patient for evidences of paralysis of the seventh, sixth, third, and fourth nerves in the order named, and then the remaining nerves. At the same time one must not forget that injuries of all of these nerves can occur without fracture of the base, so that a diagnosis of fracture should not be made from nerve paralysis alone, but by careful consideration of the other signs, as subcutaneous hemorrhages, flow of blood or cerebrospinal fluid from ears, nose, and mouth, with the evidences of nerve or vessel injury at the base. In addition to these three factors, in making a diagnosis a fourth is to be added, and that is whether the accompanying signs of injury to the brain (to be considered later) confirm the diagnosis already rendered probable by the other three.

Injury of the Facial Nerve.—This shows itself as a peripheral

paralysis affecting the ocular, labial, and nasal groups of muscles. When the case is first examined, this paralysis is best demonstrated by pressure upon the supraorbital nerves, as shown in Fig. 9. This manipulation, unless the coma is extremely deep, causes such pain that the patient will contract the facial muscles of the non-paralyzed

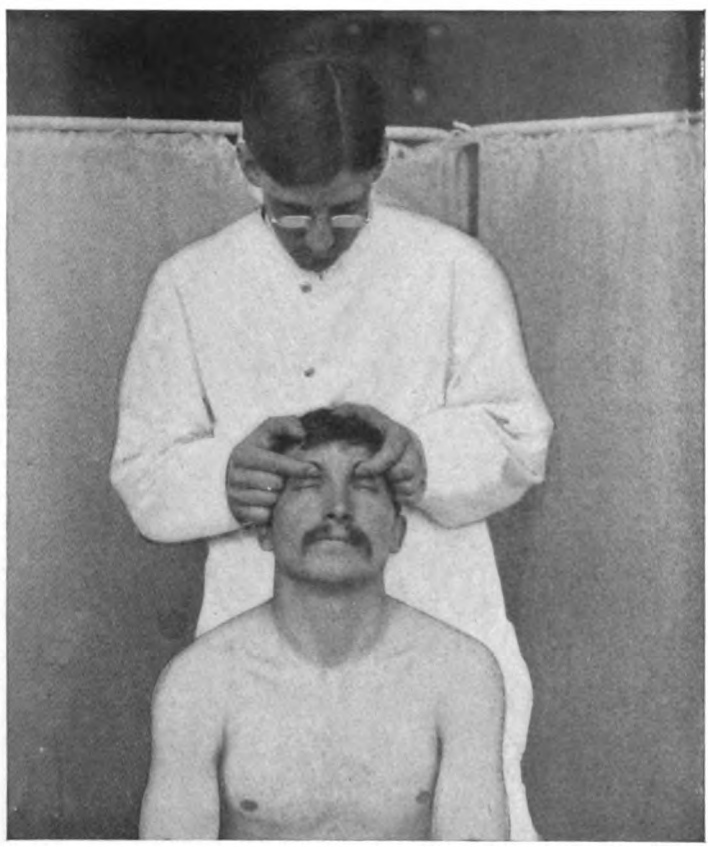

FIG. 9.—METHOD OF MAKING PRESSURE UPON THE SUPRAORBITAL NERVES.
To be employed in the diagnosis of certain intracranial affections (see text). The examiner should stand behind the patient's head, and make pressure with the index-finger of each hand over the supraorbital notches.

side. It is also of aid in distinguishing genuine from feigned unconsciousness or from an alcoholic stupor.

The paralysis of the facial nerve is usually unilateral, and may involve other branches of the nerve beside those supplying the muscles of expression. The paralysis is rarely permanent. It, like evidences of injury to all the nerves at the base, may not appear at the time of the accident, but several days later, owing to a secondary periostitis.

Injuries of the Third, Fourth, and Sixth Nerves.—Injuries of the *third* cranial or motor oculi nerve cause external strabismus and ptosis. The pupil is widely dilated and does not react to either light or accommodation. There is also double vision. Injury of the *fourth* nerve causes diplopia. In attempts at downward convergent vision the internal rotation of the eyeball fails to take place.

Paralysis of the sixth nerve results in internal strabismus and marked diplopia. The injuries of all these nerves are usually unilateral, owing to their involvement in fractures involving the base close to the apex of the orbit.

FIG. 10.—FACIAL PARALYSIS OF PERIPHERAL ORIGIN FOLLOWING GUNSHOT WOUND OF RIGHT FACIAL NERVE.

Note the inability to contract the muscles of the eyelids and the muscles of expression of the face proper, resulting in obliteration of the nasolabial fold and drooping of the angle of the mouth.

Injury of the Auditory Nerve.—According to some authors (Rawling), the seventh and eighth nerves are more frequently injured than any others, but others (Graf and Brun), from the analysis of a large number of cases, state that the order given above, viz., seventh, third, fourth, and sixth, represents the greater frequency of involvement.

The eighth nerve is most frequently involved in fracture of the base with the seventh, and upon this association rests much of the question as to whether the deafness resulted from the injury. If the auditory nerve is injured there is loss of hearing by bone conduction and loss of hearing of the higher tones.

Injuries of the Olfactory Nerve.—The effect of injury to this nerve is anosmia, or a loss of sense of smell on the side of injury. The presence of anosmia aids in localizing the fracture in the anterior fossa (cribriform plate of ethmoid). One must rule out hysteria, catarrhal nasal conditions, and fifth-nerve disturbances.

Injury of the Optic Nerve.—A fracture of the base may be followed by choked disc, because the dural covering of the nerve is injured; this quickly subsides, but an optic atrophy may remain.

Injury of the Trigeminal Nerve.—This nerve is seldom involved in fractures of the base. There are both sensory and motor disturbances. The motor are loss of function of the masseter and pterygoid muscles on the side of the injury, so that the patient is unable to keep the jaws tightly together. The loss of sensation involves almost the entire lateral half of the face, the conjunctiva, nasal and buccal mucous membranes, including the tongue, often causing a trophic ulcer of the cornea.

Injury of the Ninth, Tenth, and Eleventh Nerves.—Comparatively few cases of injuries to these nerves have been reported following fracture of the base. The paralyses of all three of these nerves are often associated, on account of their close relation at the base. In four of the cases reported there was dysphagia from paralysis of the palatal muscles. There were also disturbances of speech and of voice, due to paralysis of the recurrent laryngeal. In three of five cases there was unilateral anesthesia of the pharynx and larynx, and in two, disturbances of taste.

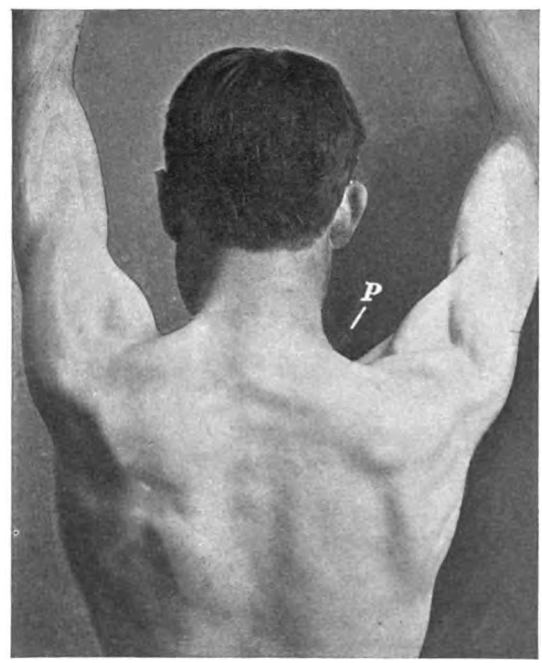

FIG. 11.—PARALYSIS OF THE RIGHT TRAPEZIUS MUSCLE, AS A RESULT OF CUTTING THE SPINAL ACCESSORY NERVE DURING AN OPERATION FOR TUBERCULAR GLANDS OF THE NECK.

P, Points to the paralyzed muscle. Observe the depression on the right side of the neck (paralyzed side).

In several cases in which there has been predominant involvement of the eleventh or spinal accessory, it produces difficulty in raising of the arm, due to paralysis of the trapezius (Fig. 11).

Injuries of the Twelfth or Hypoglossal Nerve.—This nerve is also rarely involved, very few cases having been reported. Its paralysis causes difficult deglutition, atrophy of the tongue, and speech is affected. Its injury is almost always in association with that of the ninth, tenth, and eleventh nerves.

(*b*) *Injuries of the Vessels at the Base of the Skull in Fractures of the Same.*—The diagnosis of these is considered on page 28. Special interest, however, is attached to cases of fractures of the base accompanied by wounds of the internal carotid artery and cavernous sinus simultaneously, resulting in the formation of an arteriovenous aneurysm. This result of a fracture of the base can be diagnosed by the presence of a pulsating exophthalmos. There is marked protrusion of the eyeball; the upper eyelid is swollen and tense, and there is a dis-

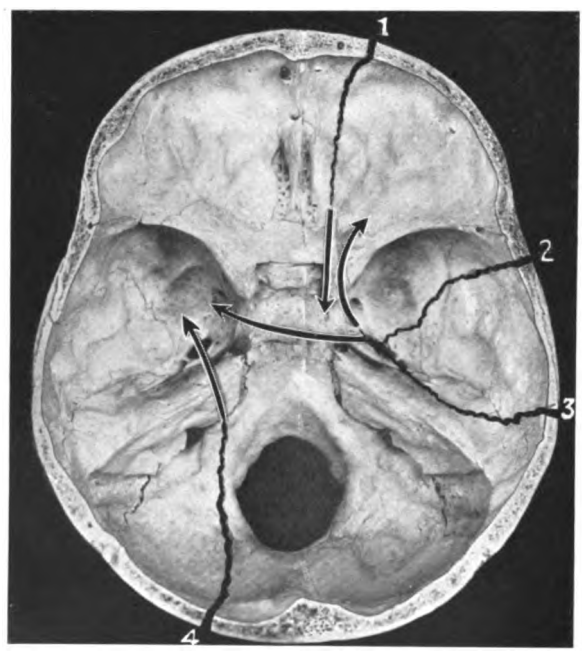

FIG. 12.—MOST FREQUENT LINES OF FRACTURE OF BASE OF SKULL.
The black arrows indicate their direction if they traverse further than indicated in the illustration: 1, Fracture of anterior fossa; 2, 3, fractures of middle fossa; 4. fracture of posterior fossa.

tinct pulsation and thrill—the latter two, in cases where the common carotid is compressed. Pulsating exophthalmos may, however, follow a fracture (gunshot wound of petrous portion of temporal) at another part of the skull, as reported by Barnard,[1] and then be due to a sacculated aneurysm of the internal carotid, without venous communication.

Diagnosis of Fracture of Individual Fossæ of the Base.—In addition to being able to make a diagnosis of fracture of the

[1] "Annals of Surgery," May, 1904.

base, it may become necessary to ascertain through which fossæ the fracture has occurred. The majority of fractures of the vertex due to a fall from a height or a blow upon the skull by some blunt instrument are followed by a fracture of the corresponding fossa of the base. In

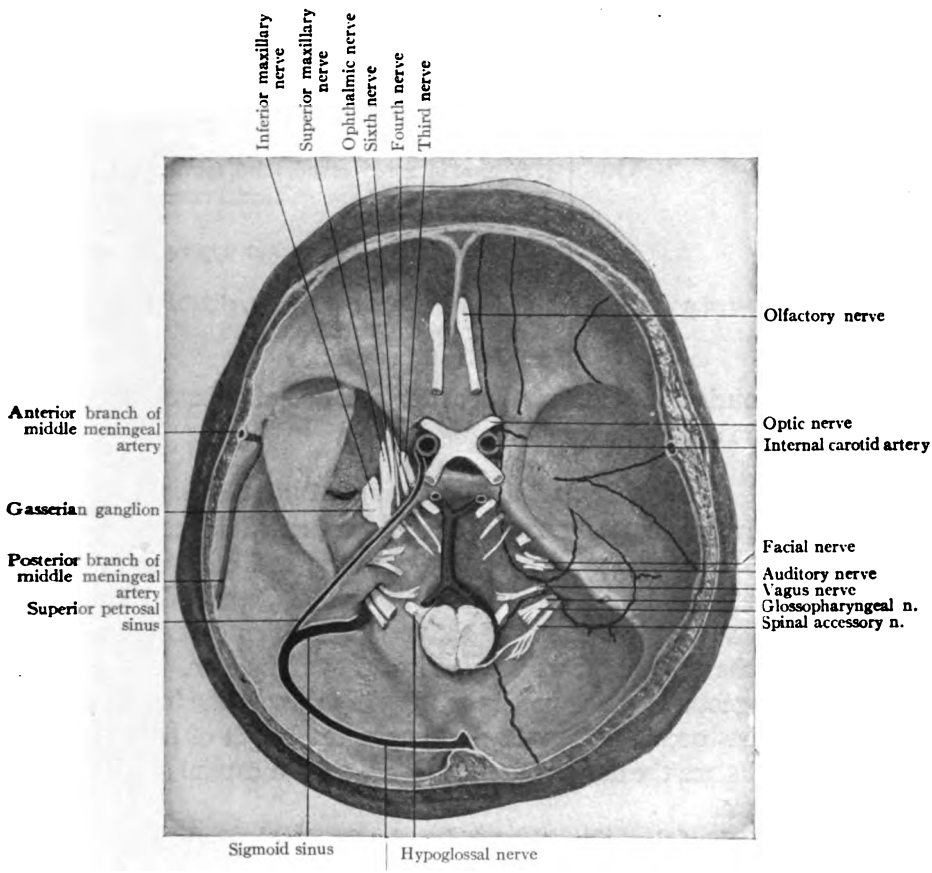

FIG. 13.—VIEW OF BASE OF SKULL, SHOWING RELATION OF CRANIAL NERVES, CAROTID AND MIDDLE MENINGEAL ARTERIES, AND SINUSES TO THE FOSSÆ.

This illustration shows on the right side of the skull the most frequent lines of fracture at the base of the skull.

many cases of fracture of the base following a punctured or gunshot wound the location of the wound of entrance is of assistance.

The greater number of basal fracture lines pass through the petrous portion of one or both temporal bones, either as extensions or isolated fractures.[1] Many fractures involve two or more fossæ (Fig. 12).

[1] Patel: "Revue de Chirurgie," April, 1903.

Aside from these facts, the following table may be of aid (Fig. 13):

Fractures of anterior fossæ	1. Subconjunctival and subcutaneous (eyelids) hemorrhages. 2. Exophthalmos (due to retrobulbar hemorrhage). 3. Bleeding or escape of cerebrospinal fluid or brain substance from the nose or mouth. 4. Pulsating exophthalmos. 5. Anosmia (due to olfactory nerve injury).
Fractures of middle fossæ	1. Subcutaneous hemorrhages around the mastoid. 2. Bleeding and escape of cerebrospinal fluid or brain substance from the ear and mouth (per Eustachian tube). 3. Signs of injury of second, third, fourth, fifth, sixth, and at times of seventh cranial nerves (see pages 28, 29).
Fractures of posterior fossæ....	1. Subcutaneous hemorrhages at upper part of back of neck. 2. Evidence of injury of seventh, eighth, ninth, tenth, eleventh, and twelfth nerves. 3. Bleeding from the ear.

Albuminuria and glycosuria have been reported after basal fracture, but are of no diagnostic value.

IV. Evidences of Intracranial Injury.

In by far the greater number of cases a fracture of either the vertex or the base is accompanied by unconsciousness and other symptoms of intracranial injury. This is especially true of depressed fractures of the vertex, fissured fractures of the temporal region (middle meningeal hemorrhage), and the majority of fractures of the base.

The diagnosis of which particular form of injury to the intracranial structures has occurred depends, first, upon the length of time which has elapsed since the accident; and, second, upon a careful analysis of the symptoms.

The length of time since the accident is of value because there is a certain sequence in which symptoms of the various conditions show themselves.

1. In the first forty-eight hours concussion, compression, and contusion[1] symptoms appear.

2. After the first forty-eight hours symptoms of meningitis, cerebral abscess, hernia cerebri, and pyemia from sinus thrombosis begin to appear. Quite rarely compression symptoms may show themselves for the first time some days after an injury, a condition known as late traumatic apoplexy (page 53).

[1] The term contusion is synonymous with laceration of the brain or non-penetrating wound.

3. After the immediate effects of injury have disappeared or improved, the so-called late sequelæ, such as traumatic neuroses, epilepsy, and chronic traumatic abscess, may appear.

In the majority of cases it is of the utmost importance, both as regards prognosis and treatment, to make a diagnosis as soon as possible after the accident. This can be done at times after the first examination of the injured person. In other cases a second or third analysis of the symptoms at intervals of a few hours will usually enable a diagnosis to be made, even where two or more of these intracranial conditions should chance to be present together.

Concussion, compression, and contusion of the brain usually occur as complications of fractures either of the vertex or base, so that the symptoms of the latter lesions must be taken into consideration in the diagnosis of intracranial injuries. It must, however, not be forgotten that serious damage to the brain, intracranial blood-vessels, and nerves may also occur after mere contusions of the skull, after falls upon the feet or buttocks, or after blows or falls upon the chin or head *without a fracture of the skull.*

CONCUSSION OF THE BRAIN.

Concussion symptoms always appear immediately after the injury, but vary somewhat in their severity. They occur with especial frequency after fractures of the base. Graf found concussion symptoms in 76 of 90 cases of fracture of the base. There are three classes of cases: (*a*) mild; (*b*) moderately severe, and (*c*) severe. In those who recover from the immediate effects of the concussion of the brain there is an initial stage of depression, and a second stage of irritation or reaction.

STAGE OF DEPRESSION.

Mild Cases.	Moderately Severe.	Severe.
1. Unconscious for a few seconds to minutes, rarely half an hour.	1. Unconscious for a number of hours.	1. Unconscious for a short period, followed by death.
2. Pulse but little affected.	2. Pulse slow and small (between 40 and 60).	2. Pulse rapid and weak.
3. Respirations a little slower than normal.	3. Respirations slow and shallow.	3. Respirations shallow and rapid.
4. Skin pale and cold.	4. Skin pale, cold, and clammy.	4. Skin pale, cold, and clammy.
5. Vertigo, tinnitus, or flashes of light.	5. Pupils contracted or dilated equal, and respond to light.	5. Pupils same as in moderately severe.
6. No memory of events just before accident.	6. No memory of events before accident, when reaction sets in.	

STAGE OF DEPRESSION.—(*Continued.*)

MILD CASES.	MODERATELY SEVERE.	SEVERE.
7. No rise in blood-pressure.	7. Involuntary micturition and defecation.	7. Same as in moderately severe.
	8. Vomiting—either during period of unconsciousness or upon recovery from same.	8. Subnormal temperature.
	9. Traces of sugar or albumin or both in urine.	9. Rise in blood-pressure in early portion, but rapid fall as vasomotor and other centers in the medulla become paralyzed.
	10. Rise in blood-pressures immediately after trauma.	

SECOND OR STAGE OF IRRITATION OR REACTION.

1. Pulse becomes stronger and more rapid, until normal.
2. Respirations deeper and more rapid, until normal.
3. Surface of skin becomes warmer and redder.
4. Temperature normal or slightly above.
5. Great mental irritability and apathy.
6. Some vomiting.

The symptoms of concussion in the average case will be considered below in differentiating it from compression and contusion (see page 54).

COMPRESSION OF THE BRAIN.

The symptoms of cerebral compression of traumatic origin vary both in their intensity and in the time of onset, according to the cause.

I. Compression from splinters of depressed fracture (Fig. 14). The symptoms appear almost immediately after the injury and are associated with those of concussion and contusion (see table on page 54).

II. Compression from intracranial hemorrhage.

This may arise—(*a*) from the middle meningeal artery (extradural hematoma or extrameningeal hemorrhage) (Fig. 21).

(*b*) From the pia arachnoid (subdural hematoma or intermeningeal hemorrhage).

(*c*) From the vertebral arteries and intracranial portions of the internal carotids.

(*d*) From the venous sinuses.

Compression from any of these causes appears in one of four ways:

1. First, symptoms of concussion, then a free interval followed by compression symptoms.

2. Distinct interval after accident without any symptoms of intracranial injury, then signs of compression begin to appear.

3. No perceptible interval between the symptoms of concussion and of compression, the symptoms of the concussion at first obscuring those of the compression.

4. Compression symptoms rarely appear a number of days after the accident (late traumatic apoplexy).

III. Compression symptoms from infection of the meninges or the brain, or from tumors of the brain.

Signs of cerebral compression due to infection appear after the first forty-eight hours.

Compression symptoms due to extradural hematoma from a laceration of the middle meningeal artery appear early, and are quite marked within a few hours after their onset. Hemorrhage from injury of the vessels of the pia arachnoid or the sinuses cannot be distinguished from middle meningeal hemorrhage in the majority of cases, but appears later, is less rapid, and the symptoms are not so marked (see pages 48, 49).

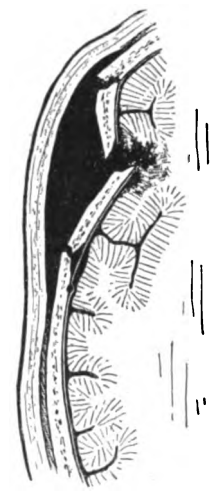

FIG. 14.—FRACTURE OF SKULL WITH DEPRESSED FRAGMENTS (Scudder).

Compression of brain by bone.

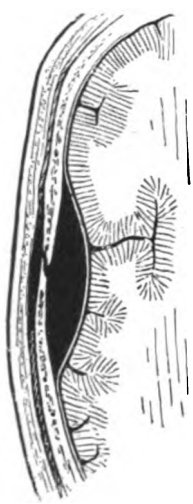

FIG. 15.—FRACTURE OF SKULL WITH MIDDLE MENINGEAL HEMORRHAGE (Scudder).

Compression of brain by blood.

The experimental work of Kocher[1] and of Cushing[2] on the subject of cerebral compression is being so rapidly confirmed by clinical observations, that the classification given by them will be followed here. According to these writers, there are four stages of compression of the brain.

First, or State of Compensation.—There are practically no symptoms with the exception of severe headache, which may be due to irritation of the dura.

Second, or Stage of Incipient or Mild Compression.—The symptoms of this stage are due to an obstruction to the outflow of venous blood (dysdiæmyrrhosis). They are:

(*a*) Headache—location varies according to seat of lesion.

(*b*) Delirium, great irritability, and restlessness.

[1] Nothnagel's "Specielle Pathologie," Bd. ix, 3.

[2] "American Journal Medical Sciences," June, 1903.

(*c*) Dullness of perception.

(*d*) Pupils contracted or unequal. May have conjugate deviation of eyeball.

(*e*) Choked disc.

(*f*) Pulse slower than normal (50 to 70). Tension moderately increased.

(*g*) Respiration slower but regular.

(*h*) Temperature higher than normal (101° to 103°). The greater the degree of compression, the higher the temperature.

(*j*) Rise of blood-pressure. This can be determined by the use of the Riva-Rocci apparatus (Fig. 16).

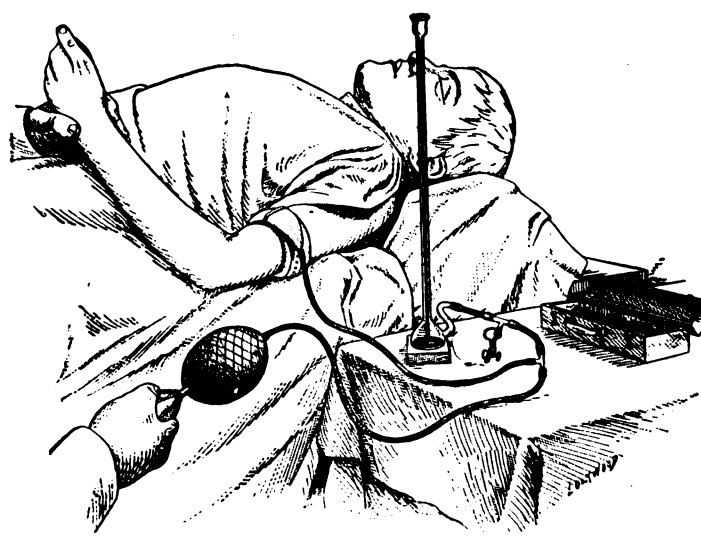

FIG. 16.—RIVA-ROCCI SPHYGMOMANOMETER AS MODIFIED BY COOK.

In cases of compression of the second stage (incipient or mild compression), there will be moderate increase of blood-pressure to 180 to 190 mm. of Hg. If this does not rise, it indicates that the intracerebral tension has not increased. Concussion will cause a rise in blood-pressure immediately after the accident, but it decreases as the symptoms subside. In cases where moderate compression exists, in addition to the concussion, the blood-pressure either remains stationary or there is a light rise, due to a posttraumatic cerebral edema (Cannon-Bullard[1]).

Third, or Stage of Advanced Compression.—In this stage the compression is so great as to cause an anemia of the brain both of

[1] "Boston Medical and Surgical Journal," August, 1901.

the cortex and medulla (adiæmyrrhosis). The vasomotor center is stimulated and causes such a rise in blood-pressure that it compensates for the increased intracranial tension. The diagnosis of this stage of compression may be made from the following (see footnote[1]) symptoms:

(*a*) The patient is deeply stuporous and gradually becomes comatose.

(*b*) The pupil is dilated and not responsive on the side of the lesion. There may be conjugate deviation of the eyeballs toward the side of the lesion.

(*c*) Marked choked disc.

(*d*) Pulse very slow. May drop to 40 or 50 and is of high tension.

(*e*) Respirations much slower and stertorous. They may be Cheyne-Stokes in character.

(*f*) Temperature higher than normal. It rises as compression increases.

(*g*) Blood-pressure greatly increased. In case the hemorrhage (if this be the cause of the compression) is subdural (intermeningeal), the increase is slow and only moderate; if, however, there is a large extradural clot or a large fragment of depressed bone, the rise will be rapid and quite marked, falling soon after the pressure is relieved, or if this does not occur, the fourth or stage of paralysis sets in, with its marked fall of blood-pressure. Following the primary fall after the operation there may be a second rise, due to a variable degree of cerebral edema.

(*h*) Focal symptoms. These may or may not be present, according to whether the pressure is or is not exerted over a localized area. If present, there may be hemiplegia of the face, arm, and leg of the opposite side, or a monoplegia of the arm or leg, at times accompanied by twitchings or convulsions of the affected muscles. There is also increase of the deep or tendon reflexes, with loss of control of the bladder and rectum.

Fourth, or Stage of Paralysis.—In this stage the intracranial tension can no longer be compensated for by increased blood-pressure, and there is inhibition of the functions of the medulla through extreme anemia. The symptoms are usually preceded by those of the third, or stage of advanced compression. In this fourth or paralytic stage the diagnosis may be made from the following:

(*a*) Deep coma. The patient cannot be aroused.

(*b*) The pupils are dilated and not responsive.

[1] The symptoms of this stage should be compared with those of the stage of incipient or mild compression.

(*c*) The pulse is rapid and weak, corresponding to the fall in blood-pressure.

(*d*) The respirations are shallow and irregular. Frequently they are of the Cheyne-Stokes' type.

(*e*) Rapid fall in blood-pressure.

Many patients are seen under one of the following conditions, when the differential diagnosis must be made between coma due to cerebral compression and that due to other causes:

1. A comatose middle-aged man or woman is brought to the hospital with the history of having fallen on the street and sustained a scalp wound an hour or less before admission.

2. Same condition and history as above, but smell of alcohol in breath very marked.

3. Man apparently deeply unconscious, with no external wound or signs of injury, but with a history of having fallen, six or eight hours before examination.

One must distinguish the symptoms of cerebral compression under any or all of the above conditions from the following forms of feigned or genuine coma:

(*a*) Coma due to ordinary cerebral apoplexy.

(*b*) Uremic coma.

(*c*) Diabetic coma.

(*d*) Alcoholism.

(*e*) Opium poisoning.

(*f*) Hysterical coma (or often malingering).

The diagnosis which is the most difficult is in the class of cases mentioned under 3, where the patient has, for example, been placed in the cell of a police station over night, with the diagnosis of alcoholism made by the police officers. Here the fall was originally due to the alcohol, but resulted in a skull fracture with hemorrhage, and the free interval between concussion and compression either did not exist or was overlooked. This instance is especially referred to on account of the fallacious teaching that symptoms of compression are always preceded by a free interval, which latter is diagnostic of this condition. Every case of coma must be systematically examined before a diagnosis is made. The average duration of life in non-operated cases of middle meningeal hemorrhage is 25 hours (Brun), and this fact emphasizes the importance of an early diagnosis of cerebral compression of traumatic origin.

The differential diagnosis of the various forms of intracranial injury will be taken up at the end of this section. As can be seen from the accompanying table, it will not be difficult to make a diagnosis of the

Coma from Intracranial Injury.	Apoplectic Coma.	Uremic Coma.	Alcoholic Coma.	Opium Poisoning.	Hysterical or Malingering.	Diabetic.	Hemorrhagic Pachymeningitis.
Deep coma may have history of onset after fall or injury. Evidence of fracture of vertex or base.	Deep coma; sudden onset. If any injury, only a scalp wound.	Deep coma. Slow onset unless convulsions have preceded the coma.	Can be aroused by supraorbital pressure unless very profound.	Can be aroused unless very deep.	Can be aroused by supraorbital pressure (Fig. 9).	Deep coma. Sweetish odor to breath.	History of previous attacks of coma or occurs after slight injury.
Pupil dilated on side of lesion. Choked disc.	Pupils unequal or dilated. Contracted in hemorrhage into the pons.	Albuminuric retinitis.	Pupils normal or somewhat dilated.	Pupils contracted to pinpoint size.	..	..	..
Pulse very slow.	Pulse full and slow, often arteriosclerotic, high-tension pulse.	Pulse rapid.	Pulse more rapid than normal and full.	Pulse rapid, may be irregular.	..	..	..
Respiration slow and stertorous.	Respiration slow and irregular.	Respiration frequent and irregular.	Regular respiration.	Respiration very slow--may be 6 to 8 per minute.	..	..	..
Temperature higher—101°.	Temperature higher on paralyzed side, but lower in rectum.	..	May be low or normal.	..	..	..	..
Urine normal or contains trace of albumin.	Urine contains trace of albumin, but may be same as in uremia.	Urine shows albumin, casts, and low urea percentage.	Normal.	Normal.	..	The urine contains variable amount of sugar and diacetic acid.	..
Hemiplegia on opposite side to that of injury. If contusion of brain is also present, may have generalized convulsions.	Hemiplegia with convulsions on one side.	..	..	..	..	..	..

nature of the coma, if the patient is systematically examined, as to—(*a*) the history preceding the onset, if obtainable, the condition (*b*) of the pupils, (*c*) of the skull, (*d*) of the extremities as to paralysis, (*e*) of the pulse, (*f*) respiration, (*g*) temperature, (*h*) urine, and an (*i*) ophthalmoscopic examination made.

CEREBRAL CONTUSION OR LACERATION.

The symptoms of actual demonstrable injury of the brain are due either to punctate or somewhat larger foci of contusion, which may involve various areas of the cortex, the conducting tracts, the cerebel-

FIG. 17.—SAGITTAL SECTION OF BRAIN IN A CASE OF EXTENSIVE TRAUMATIC HEMORRHAGE INTO THE FRONTAL LOBES.

B, Large clot occupying a cavity in the frontal lobe. Note the hemorrhages into the pia arachnoid as seen in the sulci along the upper surface.

lum, the pons, and the medulla, or they may be the result of the destruction of an entire lobe or even hemisphere (Fig. 17).

Contusion may be either direct, *i. e.*, in close relation to the seat of injury, or it may be indirect, at the end of the poles of force which start at the point of impact.

Evidences of contusion are usually most marked at the base of the brain, especially in the cerebellum, pons, and medulla. Next in order of frequency are the frontal and temporo-sphenoidal lobes (Fig. 17). Sixty per cent. of the deaths in the first twelve hours in 470 cases of skull fractures, observed at the Heidelberg clinic (Brun), were found to be due to contusion of the brain and this was most marked in the cerebellum.

Bullets, blunt instruments thrust into the skull, or the splinters of a depressed fracture cause localized foci of contusion, also called laceration of brain substance, *whose symptoms depend primarily upon the area involved, i. e.*, upon their degree of penetration. The symptoms produced immediately after the injury do not differ from those resulting from a non-penetrating force.

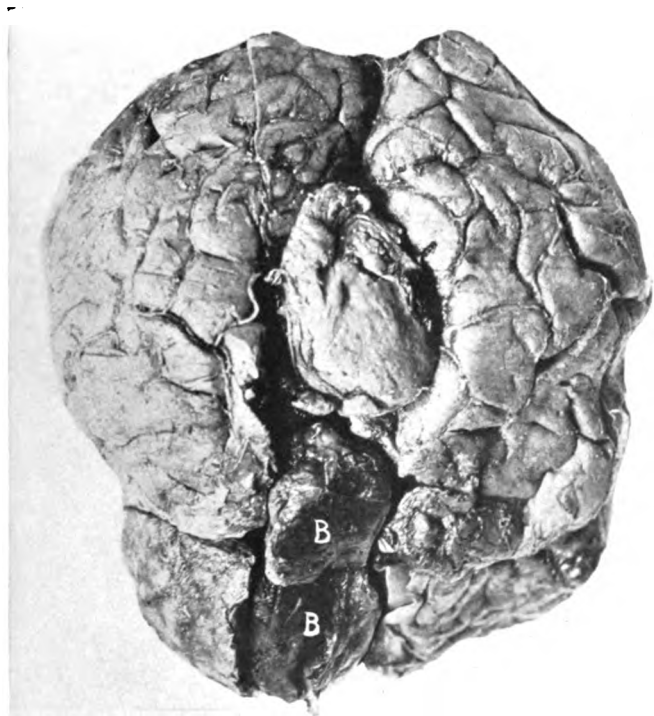

FIG. 18.—VIEW OF BASE OF BRAIN IN A CASE OF EXTENSIVE TRAUMATIC HEMORRHAGE INTO THE FRONTAL LOBES.

Same case as shown in Fig. 17. B, B, Blood-clots occupying a large cavity in the right frontal lobe.

Contusion or laceration of the brain may be present under one of several different clinical pictures, as follows:

(*a*) As generalized or localized twitchings or convulsions, obscured from further recognition by the symptoms of concussion or compression, or a combination of both twitchings and convulsions during the first forty-eight hours, accompanied by pareses or paralysis. After this period such symptoms are due to infective conditions, such as meningo-encephalitis (see page 55).

(*b*) As early focal symptoms (aphasia, etc.) in cases where the signs

of concussion or compression are either absent or present only for a short interval.

(*c*) As late focal symptoms which show themselves (in the form of pareses or paralyses, etc.) during convalescence from the immediate effects of an injury such as concussion or compression.

The diagnosis of the first of these three groups (*a*) is a very difficult one. This is due to the fact that the symptoms of concussion (loss of consciousness, slow pulse and respiration, etc.), or again those of compression (very slow pulse and respiration, deep coma, etc.), may in some cases obscure the clinical picture to such an extent that it is impossible to make an absolute diagnosis of a contusion. One can surmise its presence when twitchings or convulsions accompanied by pareses or paralyses appear immediately after the injury. These are at times present only on the side of the injury; at others on the opposite side of the body, or again are quite generalized. All of these symptoms show a decided irritation of the cortical centers.

The second class of cases (*b*) is much easier to diagnose, for the reason that the loss of consciousness was very slight or transitory, or not even present. The signs of brain contusion most frequently found in these cases are pareses or paralyses of the face, arm, or leg of the side of the body opposite to that of the injury, with or without aphasia. The aphasia may appear as an isolated paralysis, and by some writers (Koenig) is considered as one of the most characteristic signs of contusion of the brain. The correct interpretation of the early signs of focal brain injury, as well as of those occurring in the manner described in class *c* (*i. e.*, after the symptoms of concussion or compression have begun to disappear) can be made only if we recall the more important facts in our present knowledge of cerebral localization. In other words, *we can diagnose contusion only from certain symptoms indicating focal lesions.*

CEREBRAL LOCALIZATION (Figs. 19 and 20).

I. **Ascending Frontal and Ascending Parietal Convolutions:**

(*a*) Motor centers for leg in upper one-fourth of both convolutions.

(*b*) Motor centers for arm in middle two-fourths of both convolutions.

(*c*) Motor centers for face in lower one-fourth of both convolutions.

The total destruction of the entire motor region would result in complete and permanent hemiplegia of the opposite side of the body, with loss of muscular and stereocognostic senses.

Most frequently the cortical centers are not completely destroyed, so that the paralysis involves only one or more of the centers, and is

accompanied by evidences of cerebral irritation from the contusion, in the form of twitchings, convulsions, or contractures. The combination of these latter irritating symptoms with paresis or paralysis of the extremities or facial muscles is diagnostic of cerebral contusion, if they remain after the compression of the brain by a blood-clot or a

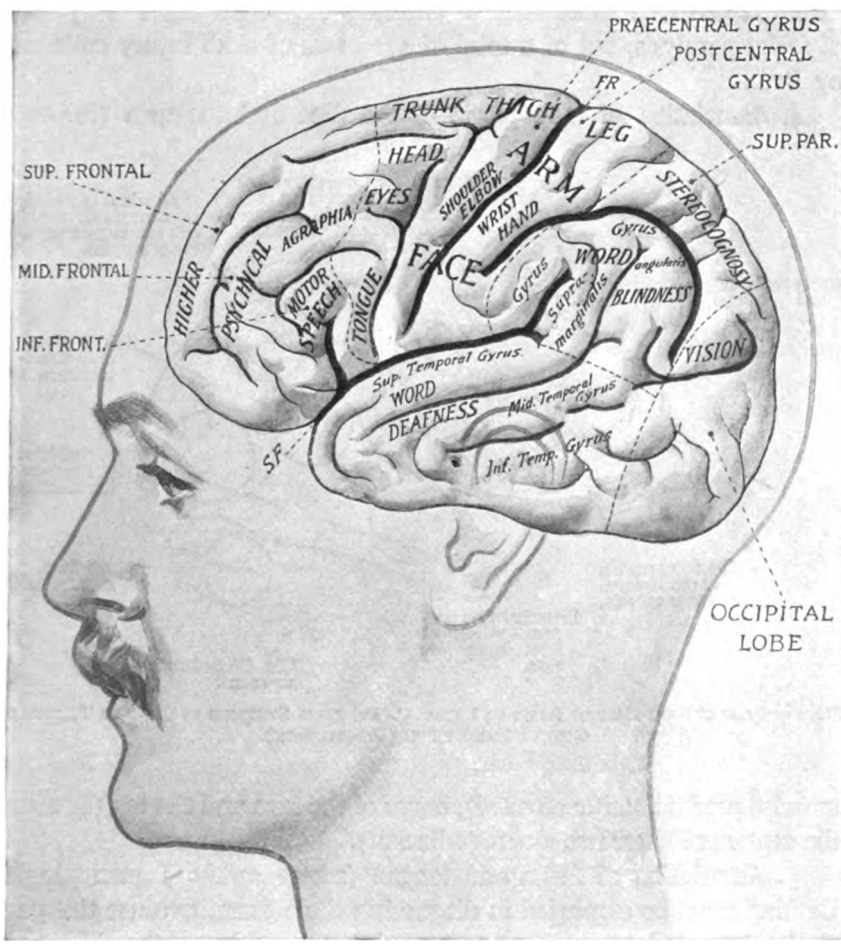

FIG. 19.—CEREBRAL LOCALIZATION

depressed fracture is relieved. Some partial destruction of the motor cortical centers is often associated with aphasia and sensory disturbances (muscle sense), owing to the proximity of these centers. One of the following combinations may occur:

1. Paralysis or clonic convulsions, or both, of the arm (monoplegia

and monospasm). This is often accompanied by a loss of muscle and stereocognostic senses.

2. Same condition of leg alone. Less often than in the arm there is a loss of muscle and stereocognostic senses. Monoplegia, etc., of the leg alone is not as frequent as in the arm.

3. Isolated paralysis of the face of cortical origin is comparatively rare. It occurred as an isolated paralysis only eight times in 83 cases of facial paralysis, out of a total of 470 cases of skull injury collected by Brun.

4. Association of monoplegia of the face and the arm (forearm

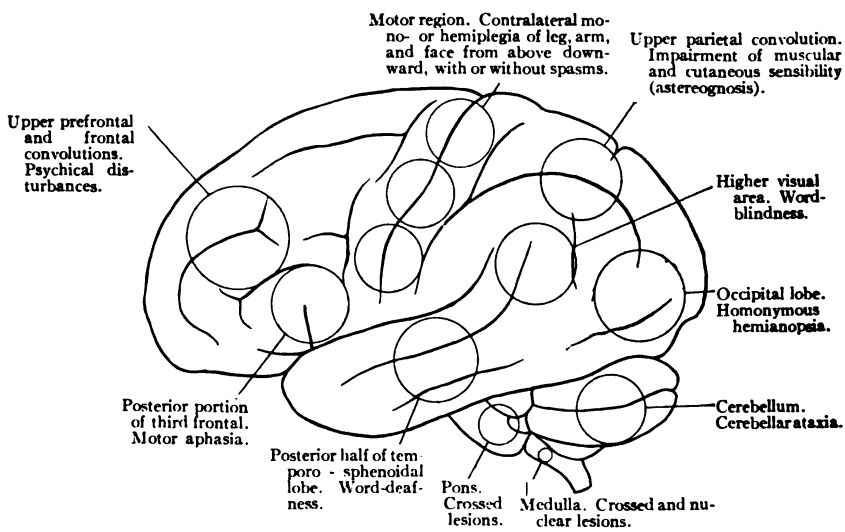
Motor region. Contralateral mono- or hemiplegia of leg, arm, and face from above downward, with or without spasms.
Upper parietal convolution. Impairment of muscular and cutaneous sensibility (astereognosis).
Upper prefrontal and frontal convolutions. Psychical disturbances.
Higher visual area. Word-blindness.
Occipital lobe. Homonymous hemianopsia.
Cerebellum. Cerebellar ataxia.
Posterior portion of third frontal. Motor aphasia.
Posterior half of temporo-sphenoidal lobe. Word-deafness.
Pons. Crossed lesions.
Medulla. Crossed and nuclear lesions.

FIG. 20.—VIEW OF LEFT HALF OF BRAIN TO ILLUSTRATE PRINCIPAL SYMPTOMS IN CASES OF TUMORS OR OTHER FOCAL LESIONS (DIAGRAMMATIC).

muscles predominantly affected), never of the face and the leg (because the centers of latter two are not adjacent).

5. Association of facial and tongue (motor aphasia) monoplegia. Caution must be employed in diagnosing these cases, because the paralysis of the facial muscles may *per se* interfere with speech. If a true faciolingual monoplegia exists, the tongue points to the paralyzed side.

6. Association of monoplegia of the arm and of the leg.

The paralysis or paresis and the convulsions of the muscles of the extremities may extend day by day from one motor center to the other, and thus not all appear at one time. If the paralyses are due to compression from blood-clots, or a depressed fracture, or a splinter of bone, they disappear as soon as the cause is removed. If the paralyses are

due to contusion, however, they disappear either gradually or become permanent. If the latter, they may be the beginning of a Jacksonian epilepsy.

II. **Parietal Lobe.**—Lesions of this region cause disturbances of muscle sense. It has been impossible up to the present time to exactly localize the centers of general sensation and its modifications, tactile, muscular, pain, and temperature senses.

III. **Frontal Lobe.**—Lesions of the right frontal convolutions more frequently result in psychical disturbances than do injuries of the left side. These occur especially in middle-aged patients who have been drinkers. Such patients in the early days after an injury are apt to be restless, suffer from insomnia, or they are very talkative, or again are apathetic. Later on they suffer from loss of memory, especially of the smaller things of everyday life, and are apt to be very excitable and lack concentration of the mind. In other words, lesions of the frontal lobes result in disturbances of the higher psychical functions with the exception of the motor speech-area.

IV. **Occipital Lobe.**—Lesions of this part of the brain, including the lobus cuneus and lingual lobule, cause bilateral homonymous hemianopsia, *i. e.*, loss of vision in the temporal one-half of the field on the side of the injury, and the nasal one-half of the opposite side. Destruction of the left gyrus angularis causes word-blindness, *i. e.*, inability to see printed speech. Destruction of both gyri angularis causes mind-blindness (Seelenblindheit), all objects failing of recognition.

V. **Subcortical Regions (White Matter).**—Lesions of these portions cause the same symptoms as the corresponding portions of the cortex.

VI. **Pons Varolii.**—The symptoms of injury of the pons depend upon whether the lesion is above or below the crossing or decussation of the facial fibers. If it occurs below (lower one-third of pons), it will cause a facial paralysis on the same, and a paralysis of the extremities on the opposite, side (crossed hemiplegia). If the lesion is above the decussation, the face, arm, and leg paralysis are on the same side. There is frequently involvement of the fifth and sixth nerves.

VII. **Speech Region.**—(*a*) *Motor Aphasia.*—The lesion is in the posterior half of the third frontal convolution on the left side. There is an inability to produce articulate speech spontaneously or from dictation. Reading (alexia) and writing (agraphia) are impaired.

One must always be careful to differentiate a difficulty in articulation due to paralysis of the facial muscles from true motor aphasia. The latter rarely occurs as an isolated condition, being usually associated

with paresis of the arm muscles. Motor aphasia occurs especially in depressed fractures of the anterior portion of the left parietal and the posterior portion of the frontal bones. It generally disappears in one and one-half to two months.

(*b*) *Sensory Aphasia* (*Word-deafness*).—The lesion is in the first left temporal convolution. In this form the patient does not understand what is said to him. If the visual speech-center in the gyrus angularis is also affected, there is also alexia or inability to understand printed words.

(*c*) *Visual Aphasia.*—This has been referred to above (page 43). There is word-blindness present, *i. e.*, written symbols, figures, and other conventional signs have lost their significance (Church). When the gyrus angularis alone is affected, there is word-blindness. When the radiations of the optic fibers from the basal ganglia are destroyed, there is hemianopsia in addition.

Lesions of the pons may also cause articulative disturbances.

VIII. **Lesions of the medulla** often cause immediate death through paralysis of the vagus nuclei. There may also be many symptoms of injury to the medulla should the patient survive, such as diabetes, albuminuria, polyuria, singultus, bulbar symptoms, and inflammatory conditions of the lungs. The latter are the second most frequent cause of death in the first days of the injury, the most frequent being contusion of the vital centers in the medulla.

IX. **Cerebellum.**—Injuries of this part of the brain cause ataxia, incoördination, muscular weakness, nystagmus, and vertigo. Irritative lesions cause muscular stiffness on the same side of the body and arching of the spine (opisthotonos).

INTRACRANIAL HEMORRHAGE.

In examining a patient for the purpose of making a diagnosis of whether an injury to the skull or brain has been complicated by intracranial hemorrhage, one must take into consideration the various sources from which it can arise and their symptoms.

Intracranial hemorrhage of traumatic origin can occur from the following vessels in their order of frequency:

1. *From the Trunk or One of the Branches of the Middle Meningeal Artery.*—This hemorrhage takes place between the internal table and the outer layer of the dura and is known as an extradural or epidural hematoma (Fig. 21). It is usually called "middle meningeal hemorrhage" in practice. In many cases there is an accompanying laceration

of the dura, so that the blood also escapes into the subdural space, causing a bilocular hematoma.

2. *From the Smaller Arteries of the Pia Arachnoid.*—The blood either remains in the sulci (Fig. 17), beneath the unbroken pia mater, or it escapes through lacerations in this membrane into the subdural space and collects especially at the base of the brain. This form of hemorrhage is known as the subdural and is often spoken of as "intermeningeal," because the blood lies in the subdural space between the dura mater and the pia arachnoid. From a pathological standpoint,

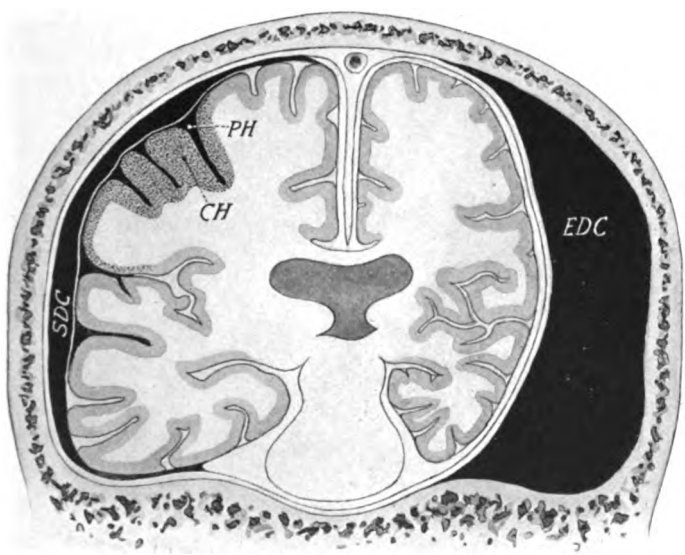

FIG. 21.—DIAGRAMMATIC REPRESENTATION OF VARIOUS FORMS OF INTRACRANIAL HEMORRHAGE. *EDC*, Epidural clot, most frequently due to rupture of middle meningeal; *SDC*, subdural hemorrhage; *PH*, hemorrhage into the pia arachnoid; *CH*, hemorrhages into the cortex.

as was stated above, there are many cases of middle meningeal hemorrhages in which the dura is torn so that the blood escapes into the subdural space as well as into the epi- or extradural space. Clinically it is impossible to differentiate such a bilocular hemorrhage from an epidural one in the true sense of the word.

3. *From the Venous Sinuses.*—Those most often injured are the longitudinal, the lateral, and the cavernous sinuses. Of these, the longitudinal is the most frequently involved, being torn by a fracture of the vertex or penetrated by a bullet or some blunt instrument. The lateral sinus is injured in a similar manner, although cases are recorded

in which it has been torn without an accompanying fracture of the skull.

The cavernous sinus is usually torn in fractures of the anterior and middle fossæ of the base. A laceration of the cavernous sinus is comparatively rare. It occurs most often in conjunction with an injury of the internal carotid artery, resulting in the formation of an arteriovenous aneurysm whose most prominent symptom is a pulsating exophthalmos. It is well to mention again that cases of this form of injury to the sinus and artery have occurred without a fracture of the base.

4. *Injuries of the Intracranial Portion of the Internal Carotid and of the Vertebral Arteries.*—Laceration and escape of blood into the interior of the skull may occur from injury of either of these vessels, for example, as a result of gunshot wounds. Fortunately, however, they are of rare occurrence and cause death before a diagnosis can be made.

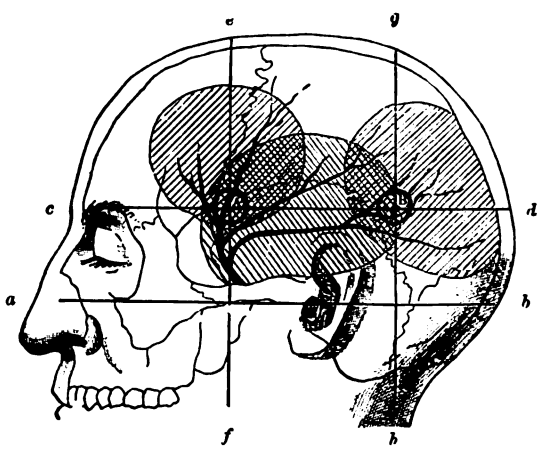

FIG. 22.—SITE OF TREPHINE OPENING TO REACH CLOT IN HEMORRHAGE FROM MIDDLE MENINGEAL ARTERY (Krönlein).

a, *b*, Horizontal line through the meatus; *c*, *d*, on a line with the eyebrows; *e*, *f*, vertical line 3 to 4 cm. behind the ext. ang. process; *g*, *h*, at the posterior border of the mastoid process. A, the point to reach the anterior, and B, the posterior branch.

It may be of some interest in connection with the diagnosis of intracranial hemorrhage to state that Chipault, out of 117 cases of intracranial hemorrhage, found 72 to be from the middle meningeal arteries and 30 from the sinuses. Treves believes that 80 to 85 per cent. of all intracranial hemorrhages are due to injury of the middle meningeal artery.

1. **Diagnosis of Middle Meningeal Hemorrhage.**—As was stated on page 36, *the symptoms of middle meningeal hemorrhages are those of the cerebral compression which it produces.* We must watch for these in every case of cerebral injury in which either the patient does not recover within a reasonable period from the symptoms of concussion which appeared immediately after the injury occurred, or he becomes drowsy, stuporous, and gradually comatose after a period of consciousness. This free interval may either follow the symptoms of concussion

or the latter may have been so slight that the patient or his relatives paid no attention to them until those of compression began to appear. According to some, this free interval is absolutely diagnostic of middle meningeal hemorrhage, and it is well to remember that this is the most typical manner in which it occurs. But one must not overlook the fact that there may be no free interval or that there is often no history obtainable of such a period devoid of symptoms of compression. The hemorrhage may occur from the trunk of the middle meningeal artery alone, under which conditions the hemorrhage is quite profuse, and a frequently accompanying tear of the dura permits the blood to escape into the subdural space as well as into the extradural. In general it may be said that the lower down the artery is torn the more rapidly do the symptoms appear.

If either the anterior or posterior branches are torn, a clot forms at the corresponding part of the extradural space, compressing the underlying brain (see Fig. 21). In infants the blood from a torn middle meningeal artery may escape through the opening in the skull caused by the fracture and collect beneath the scalp, forming an enormous cephalhematoma which does not have the suture lines as its boundaries. Cephalhematomata arising during parturition, or later as a result, have the suture lines as their boundaries (page 18).

If the symptoms of compression appear immediately after the injury, they are most likely due to a depressed fracture; if they appear after a few hours, they are due to hemorrhage. If they appear after thirty-six to forty-eight hours, they are due to some infective complication. The diagnosis of middle meningeal hemorrhage can be made from the following history: Immediately after the injury the patient either becomes unconscious and shows the signs of concussion (see page 35) instead of recovering consciousness, the coma grows deeper, the respirations, instead of being weak and slow, become stertorous, the pulse, which was of low tension and slower than normal, becomes firm, the tension greatly increased and very slow, often sinking to 40 or 50. The blood-pressure, which was but slightly increased by the concussion, becomes quite high. If the clot presses on the so-called silent area of the cortex, there are no focal symptoms, but if there is pressure over the Rolandic area (Fig. 19), there is a distinct lack of movement of the facial muscles, of the muscles of the arm, and of those of the leg on the side of the body opposite to that of the lesion, also called contralateral monoplegia or hemiplegia. The hemiplegia of a middle meningeal hemorrhage is complete; that due to a contusion of the brain is only partial. Both forms are often accompanied by twitchings or convul-

sions of the affected muscles, but this is more characteristic of contusion.

If the patient does not show the above-mentioned symptoms immediately after those of the primary concussion, they may appear after a short interval. Again, a man or woman may appear perfectly well after a fall on the head or a scalp wound, and have been dressed by a physician who has made a diagnosis of fissured fracture of the vertex or of fracture of the base without complications. A few hours later the patients become irritable and restless, the pulse becomes slower, they cannot be aroused, and the typical symptoms of compression appear. In addition to these general and focal brain symptoms one can often find as an aid to the diagnosis a tenderness, or a hematoma, or at times an ecchymosis over the temporal bone on the same side as the intracranial hemorrhage. The latter signs are due to the escape of blood through the gap in the bone.

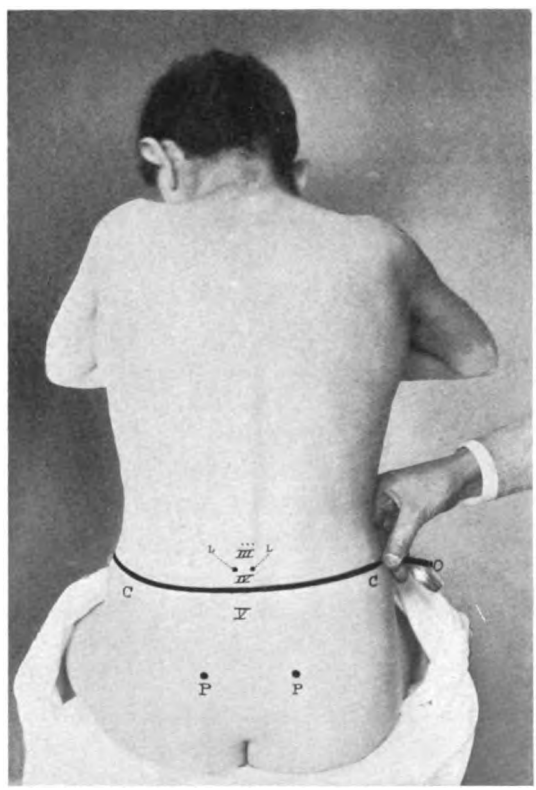

FIG. 23.—FIRST STEP IN DETERMINING THE POINT TO MAKE A LUMBAR PUNCTURE.

C, C, Tape-measure resting upon highest point of the crests of the ilia; P, P, posterior superior spines of the ilia; III, IV, and V, spines of the third, fourth, and fifth lumbar vertebræ; L, L, indicate two points lateral to the median line of the spine in third interspace, where needle is usually inserted.

2. **The diagnosis of an intermeningeal or subdural hemorrhage** in children and adults cannot be made with any degree of exactness. In general it may be said that the symptoms of compression are much less marked than in middle meningeal hemorrhage, and are slower in onset. In some cases lumbar puncture has been performed and the

cerebrospinal fluid thus withdrawn found deeply stained by blood (Figs. 23, 24). This means of diagnosis need, however, seldom be resorted to. In subdural hemorrhages cortical centers quite widely separated are often involved. The temperature is more uniformly high. If the hemorrhage occurs chiefly into the pia arachnoid and into the cortex, the symptoms, such as convulsions, cannot be easily distinguished from those of contusion, although the convulsions are more apt to be unilateral in a hemorrhage. In newborn infants subdural and pial hemorrhages cause tense fontanelles, asphyxia, and convulsions. These may not appear until several days after birth.

FIG. 24.—METHOD OF PERFORMING LUMBAR PUNCTURE.

P, Posterior superior spines of the ilia; C, uppermost level of crest of ilium; III, spine of third lumbar vertebra; IV, spine of fourth lumbar vertebra; V, spine of fifth lumbar vertebra. The needle is directed to the third lumbar interspace, a little lateral to the median line. (See text.)

3. **Hemorrhage from the Venous Sinuses.**—Of the three principal varieties of traumatic intracranial hemorrhage, that from the sinuses causes the least degree of compression and can be recognized from the extreme slowness of the onset of the symptoms. The diagnosis depends upon the situation of the wound or fracture, upon the mild compression symptoms, and in the case of the longitudinal sinus, upon the escape of considerable blood from a wound in close proximity to the sinus. Focal symptoms are usually absent.

Hemorrhage from the intracranial portion of the internal carotid causes almost immediate death.

4. **Late Traumatic Apoplexy.**—A number of cases have been reported in which symptoms of cerebral apoplexy have appeared after a

clear interval of days to weeks, the longest period being four weeks (Stadelmann) after an injury to the head. The question of whether these are due to trauma has come to be of considerable medicolegal interest. The symptoms of compression are the same as those due to extra- or subdural hemorrhage, the only difference being that the clot lies beneath the cortex, either in the white matter or in the internal capsule.

The question arises, Can these late hemorrhages be ascribed to the injury? A number of articles[1] have recently appeared, and the majority of writers believe that the injury merely plays the part of an exciting cause in a person predisposed by reason of some vascular weakness due to alcoholism, nephritis, syphilis, or cardiac disease.

DIFFERENTIAL DIAGNOSIS OF INJURIES OF THE BRAIN.

	Concussion.	Contusion.	Compression.
Time of onset of symptoms..	Immediately after accident.	Immediate, but are usually obscured by those of concussion or compression.	After free interval, unless due to depressed fracture. (See page 36.)
General cerebral symptoms ...	Loss of consciousness for some minutes to hours. Vomiting.	Unconscious if complicated by concussion or compression.	Restlessness, apathy, stupor gradually changing to deep coma in hemorrhage. Immediate unconsciousness in majority of depressed fractures.
Focal symptoms...	None, unless complicated by contusion or compression or injury to cranial nerves.	Localized or general twitchings and convulsions, accompanied by pareses or paralyses.	Localized (face or arm or leg) twitchings and convulsions precede paralysis (usually in form of mono- or hemiplegia).
Pulse.....	Slower than normal. No increase in tension.	No change, unless medulla affected, then indistinguishable from paralytic stage of concussion and compression except by earlier onset of rapid feeble pulse.	Slow (40 to 60) and of high tension.
Respiration.....	Slower than normal.	Same as above true for respiration.	Slower and deeper (stertorous). May be of Cheyne-Stokes type.
Blood-pressure ...	Slight rise.	No change.	Gradual rise as intracranial tension increases.
Pupils and eyeball.	May be dilated or contracted.	No change unless occipital lobe involved (homonymous hemianopsia).	Pupils usually unequal. Dilated on side of injury, with conjugate deviation of eyeball. Choked disc.
Temperature.	No change.	No change.	Usually rises as pressure increases.
Lumbar puncture.	Negative.	Negative.	Blood, if intermeningeal hemorrhage.
Variety of force....	Usually diffuse.	After circumscribed variety.	Diffuse in hemorrhage (extension of fissure to base). Circumscribed in depressed fractures.
Course.....	Symptoms gradually decrease and recovery, or symptoms of contusion or compression appear, or death ensues.	Signs of localized injury usually disappear. Very few become permanent.	Coma, etc., increase, and paralytic stage sets in unless relieved.

[1] Colley, "Deutsche Zeitschrift für Chirurgie," Vol. 69; Marie, "Revue de Médecine," May 10, 1905.

PACHYMENINGITIS HÆMORRHAGICA INTERNA.

This condition not infrequently follows an injury to the head in adults, as well as in children. In the former it occurs especially in alcoholics, and more particularly in middle-aged or older men. In a typical case one can get the history of an injury, followed by attacks of coma and paralysis, which entirely disappear, but recur after a variable interval of time. During these attacks the patient complains of headache, is drowsy, and soon becomes comatose. There is paralysis of one or both sides of the body, accompanied by exaggeration of the tendon reflexes, contractures, and clonic or tonic convulsions. The pupils are normal, or are contracted on one or both sides. In the interval between the attacks the patients usually complain of vertigo, are easily fatigued, show psychical disturbances, such as apathy and loss of memory, and there are evidences of pareses and paresthesia.

The differential diagnosis must be made from purulent leptomeningitis, in which there is stupor followed by coma, ocular paralysis, unequal pupils, and rigidity of the neck. There is also always fever present, as well as a rapid pulse, which is not true of pachymeningitis hæmorrhagica, unless there is an accompanying pneumonia. Furthermore, lumbar puncture shows the presence of pus in purulent leptomeningitis.

From sinus thrombosis it can be differentiated by the presence of a cause for the thrombosis, and repeated chills, followed by rises of temperature, sweats, and early evidences of metastases.

From intracerebral hemorrhage it is almost impossible to make a diagnosis during the attack, except that there is greater restlessness and delirium in pachymeningitis hæmorrhagica. The presence of epileptiform convulsions and contractures and the recurrence at intervals speak for pachymeningitis hæmorrhagica.

It can be differentiated from tumors of the brain by the presence of more circumscribed headache and marked choked disc, as well as more marked focal symptoms in a tumor.

From abscess of the brain it can be distinguished by the etiology and the more frequent presence of a choked disc in abscess.

INTRACRANIAL SUPPURATION FOLLOWING INJURIES.

The symptoms of infection usually appear within thirty-six to forty-eight hours after the injury. This is the case with infections of the meninges, while those of the brain proper and of the venous sinuses appear a

little later. Symptoms of infection may, however, not show themselves in the form of a circumscribed abscess of the brain until years have elapsed, and under these conditions the relationship between the injury and the cerebral abscess may be difficult to trace.

I. **Epidural Abscess or Purulent Pachymeningitis.**—The symptoms of a circumscribed collection of pus lying between the dura and the skull do not differ from those which are observed in cases where the pus lies in the subdural space, and their diagnosis will be considered in conjunction with the latter form. The only difference between the epidural and subdural abscesses is that in the former the external wound is much more apt to present the evidences of an acute infection in the shape of swelling, redness, and tenderness of the scalp, foul odor of the pus, and unhealthy appearing granulation-tissue. Such circumscribed collections of pus, in either the epi- or subdural space, most frequently complicate fractures of the vertex, especially of the depressed or punctured variety. Basal fractures are more often followed by meningitis of a diffuse character. In this connection it may be stated that the more circumscribed the collection of pus, the greater the possibility of making a diagnosis from the focal symptoms. Epidural abscesses occurring from causes other than trauma, such as osteomyelitis of the cranial bones, infections from the frontal, sphenoidal, or ethmoidal sinuses, and from middle ear, and mastoid disease, differ only in their history from the traumatic variety.

II. **Subdural Suppuration or Purulent Leptomeningitis.**—On account of the frequent involvement of the superficial portion of the brain in suppurative inflammation of the pia arachnoid, this form of infection has been given the name, by some writers, of meningoencephalitis (Koenig), and by others, of traumatic meningitis (von Bergmann). Subdural suppuration may occur in either a circumscribed or diffuse form. As is stated above, the localized form is more apt to follow fractures of the vertex and give rise to focal symptoms, but both the circumscribed and diffuse forms are likely to follow fractures of the base.

The diagnosis of an infection of the pia arachnoid following injury depends upon the recognition of certain symptoms of cerebral irritation, followed by those of coma. This condition of leptomeningitis should be suspected in every case of compound fracture, either of the base or vertex, but especially of the former, when the symptoms of concussion, contusion, and compression having either disappeared or improved the patient begins to complain of persistent headache, or is delirious, restless, drowsy, with rapid pulse, contracted pupils, and a gradually rising temperature of a continuous type. There may also be nausea and

vomiting of the projectile variety. At the same time, there are certain local signs of wound infection, such as abundant secretion of pus and angry appearance of the edges. Within a few hours this first or stage of cerebral irritation is followed by the second or paralytic stage. Aside from the presence of fever and the appearance of the wound, the symptoms in the first or stage of irritation are somewhat similar to those of the stage of reaction in concussion cases, which occurs at about the same period after the injury—thirty-six to forty-eight hours. The rapid rise of the pulse-rate (80 to 100) the gradual rise of blood-pressure, the presence of fever (101 to 103°), and the severity of the headache, are quite characteristic of a meningeal infection. The second stage soon clears up any doubts. The patient gradually becomes comatose, and there are signs of a marked increase in the intracranial tension.

The irritation of the cortex by the accumulation of pus either in the subdural space or meshes of the pia arachnoid shows itself in the form of localized or generalized muscular twitchings accompanied by tonic and clonic convulsions.

Pressure on the cortex causes paralyses of the face, arm and leg or monoplegias according to the area affected (Figs. 19 and 20).

When the accumulation of pus is especially marked at the base of the brain, as happens most frequently after basal fractures, there are scarcely any cortical symptoms. Early rigidity of the neck, evidences of pressure on the cranial nerves at the base, such as strabismus and disturbances of respiration, like the earlier appearance of the Cheyne-Stokes type of breathing, lead one to suspect the predominance of a basal meningitis. The respiration is rapid as a rule, unless the infection involves the cerebellar fossa. The temperature is of the continuous type.

True optic neuritis with choked disc, gradual rise in the blood-pressure as the pus accumulates, slow, high-tension pulse, and slow, often irregular, respiration, through stimulation of the vagus, are all characteristic of this second or paralytic stage of meningeal infection.

The condition of the wound in cases of fracture of the vertex is similar to that described above in the initial stage of the infection. Not infrequently there is a prolapse of the brain (secondary hernia cerebri) as a result of the increased intracranial tension, through the opening in the vertex (see page 62).

In some cases, lumbar puncture has been resorted to; the presence of pus in the spinal fluid confirming the diagnosis of a leptomeningitis.

III. **Abscess of the Brain.**—This variety of intracranial infection is far more frequent after fractures of the vertex than after those of the

base. The abscess is found close to the most frequent seat of fracture, hence close to the parietal bones. McEwen has shown that abscess of the brain, whether following a compound fracture or occurring as a complication of middle ear disease, or from any cause other than metastasis from pulmonary conditions, is always contiguous to the atrium of infection. About 25 per cent. of all brain abscesses are the result of trauma.

Posttraumatic abscess of the brain may occur either in an acute form, that is, within five to six days after the injury, or in a chronic form. In the latter, the symptoms may not show themselves until years after the injury. The symptoms of both forms are the same, the only difference being in their time of appearance.

The *diagnosis of acute traumatic abscess* depends upon the appearance of certain general and focal signs of infection which begin at the end of the first week following the injury. The *general signs* are (1) great mental depression or irritability accompanied by severe headache; this is followed by stupor and coma; (2) local tenderness on tapping the skull over the seat of the injury; (3) slow pulse and respiration, the pulse sinking to 60 or lower. The respiration may be irregular, even Cheyne-Stokes in character. This latter type is especially likely to be the case in abscesses of the cerebellum. (4) Papillitis and choked disc are not constantly present. Their absence will not exclude the presence of a cerebral abscess. (5) The temperature is either normal or subnormal. (6) *Focal symptoms*—these will vary according to the location of the lesions and consist of convulsions and paralysis, or symptoms of aphasia, etc. There may be localized twitchings with convulsions of the muscles of one extremity or of the entire opposite half of the body. The extent of the paralysis is not always a criterion of the amount of destruction of the cerebral tissue, owing to the fact that many symptoms both of irritation and paralysis are due to inflammatory edema in the neighborhood of the focus of suppuration called by German surgeons "Fernwirkung." Aphasia may be present in connection with the paralysis of the extremities, although this is less frequent after traumatic than after otitic infection. In abscesses of the cerebellum there are, in contradistinction to those of the cerebrum, a few more distinctly localizing symptoms. These are rigidity of the neck, occipital headache, cerebellar ataxia, and at times marked vertigo and vomiting. (7) The appearance of the wound—there is an increased amount of suppuration from the wound, the edges look angry, and the granulation-tissue edematous.

The *differential diagnosis of an acute traumatic abscess*, must be

made from the following: (*a*) From epidural abscess, in which the general pressure symptoms are far less marked,—there are no focal symptoms as a rule and the temperature is usually higher; (*b*) from a purulent leptomeningitis,—the differentiation cannot be made for the reason that the symptoms of the meningitis usually obscure those of the abscess; (*c*) from sinus thrombosis,—this form of infection is comparatively rare after fractures of the skull, usually involving only the longitudinal sinus. A septic sinus thrombosis can be distinguished readily from cerebral abscess by the frequent occurrence of chills followed by the characteristic steeple-like rise of temperature and followed by sweats as well as by the evidences of pulmonary metastasis.

The *chronic traumatic abscess* can only be distinguished from abscesses of the brain due to other causes by the history of a preceding trauma sufficient to permit of the invasion of the interior of the cranium by microörganisms. Often the only symptoms observed at the time of injury are those of cerebral contusion, from which the patient fully recovers. After a long period of latency in which apathy, melancholia, headache, and emaciation are present, three groups of symptoms begin to show themselves; (*a*) those due to the infection, such as slight rise of temperature, lack of appetite, muscular weakness, etc.; (*b*) the signs of increased intracranial pressure, such as mental depression or irritability, headache, increased by exertion or upon tapping the skull over the seat of the abscess, vomiting, stupor and choked disc, slow pulse, and increase of blood-pressure. Choked disc is less constant in an abscess of the brain than in tumor; (*c*) the focal symptoms, which vary according to the seat of the abscess in the same manner as in the acute form and consist of general or localized epileptiform convulsions, hemiplegia, and similar focal signs.

The differential diagnosis of chronic traumatic abscess must be made principally from tumor of the brain (see page 80).

Sinus Thrombosis.—Infective thrombosis of the intracranial sinuses is comparatively rare after injury to the scalp or skull. It can occur after erysipelas or phlegmon of the scalp, following infected wounds of the scalp, or compound depressed or punctured fractures of the vertex. The sinus most frequently affected after injury is the longitudinal.

The diagnosis can be made, first, by considering the nature and position of the injury and, second, the possibility of infection having traveled either by way of the lymphatics or veins, through the skull into the sinuses. The manner in which this occurs can be readily understood by a reference to Fig. 25, which shows how infection of the super-

ficial veins of the scalp or skull can by progression of the thrombotic process be transmitted to the sinuses into which these veins empty.

The second point in diagnosis is to observe the local signs of infection of particular sinuses. This is fully considered on page 85, in connection with otitic sinus thrombosis.

Thirdly, the general evidences of infection, usually of a pyemic

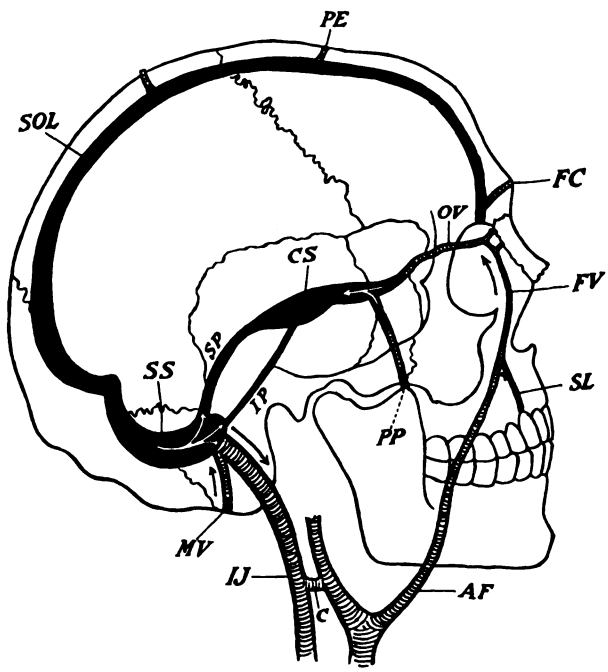

FIG. 25.—MODES OF TRANSMISSION OF INFECTIVE THROMBOSIS ALONG THE ENDOCRANIAL SINUSES.

SOL, Superior longitudinal sinus; *PE*, parietal emissary vein; *SS*, sigmoid sinus. The white arrows point to the three directions in which infection may be transmitted from this sinus along the superior petrosal (*SP*), the inferior petrosal (*IP*), and internal jugular (*IJ*). *MV*, Mastoid emissary vein, along which infection may be transmitted in the direction of the black arrow to sigmoid sinus; *CS*, cavernous sinus. The white arrow shows the direction of transmission of infection from the pterygoid plexus of veins (*PP*), and ophthalmic vein (*OV*). *FC*, Vein passing through foramen cecum into longitudinal sinus; *FV*, communication of facial (*FV*) and veins of upper lip (*SL*), with ophthalmic vein and cavernous sinus; *AF*, anterior facial vein; *C*, communication between the external and internal jugular veins.

character. The pulse is rapid. The temperature is of a remittent type, severe chills occur at irregular intervals, followed by high temperatures and sweats. The patient usually suffers from severe headache, either diffuse or circumscribed. The mind is clear unless there is a complicating meningitis or abscess.

The spleen is frequently enlarged, and following every chill there are evidences of fresh metastases. The majority of the latter are pulmonary,

in the form of miliary or somewhat larger abscesses which give rise to the symptoms of pleurisy or, if they break into the pleura, of pyopneumothorax.

There is a second clinical type of thrombosis known as the typhoid or septicemic form. It occurs more frequently after sinus thrombosis complicating middle ear disease and will be referred to later (page 84).

DIFFERENTIAL DIAGNOSIS OF INTRACRANIAL INFECTION FOLLOWING INJURY.

	Meningitis.	Cerebral Abscess.	Sinus Thrombosis.
Time of onset of symptoms..	Thirty-six to forty-eight hours after injury.	Either toward the end of the first week (early or acute) or after some months or years (late or chronic form).	Usually toward end of first week.
General cerebral symptoms.....	Severe headache, delirium, restlessness, stupor gradually changing to coma. May have nausea and vomiting.	Headache often more localized than in meningitis. Drowsiness followed by coma.	Clouded mental condition, but brighter than in meningitis or abscess unless these are present.
Focal symptoms...	Localized and generalized (more marked) twitchings and convulsions if on convexity. Paralysis of cranial nerves especially ocular and facial if basal (see page 28).	Majority of the posttraumatic abscesses close to motor region, hence localized twitchings and paralysis of mono- or hemiplegic type. Often speech and visual disturbances. (Distant action.) All focal symptoms more marked than in meningitis.	No cerebral focal symptoms. For local signs of thrombosis of individual sinuses see page 85.
Temperature.....	High and usually of continuous type. (101–103° F.)	Very slightly above normal.	Irregular chills followed by very high fever and sweats.
Pulse.....	Rises as symptoms increase, usually is 80 to 100.	Becomes slower as abscess forms.	More rapid than in abscess, rises greatly during and after chills and as disease progresses.
Respiration.....	At first more rapid than normal but becomes slower as exudate increases and again faster during terminal or paralytic stage.	Slower, often irregular and of Cheyne-Stokes type.	Becomes quite rapid as evidences of pulmonary metastases begin to show themselves.
Blood-pressure...	Rises gradually as exudate increases.	Marked rise as intracranial tension increases.	Slight rise.
Eyes.....	Paralyses of ocular muscles especially marked in basal meningitis. (Ptosis, dilated pupils, strabismus, etc.) Rarely have optic neuritis or choked disc.	Depends on location. If close to occipital lobe (homonymous hemianopsia). Optic neuritis and choked disc seldom well marked.	Rarely any changes in eye except in cavernous sinus thrombosis.
Lumbar puncture.....	Turbid fluid.	Negative.	Negative.
Condition of wound.....	If on convexity granulations edematous, wound edges swollen, reddened, tender and often necrotic.	Same as in meningitis, considerable pus discharged from wound.	Same as in meningitis.
Course.....	Death in a short time (1 to 2 weeks) after onset.	Recovery in majority if operated on and no complicating sinus thrombosis or meningitis. If not operated pus escapes into ventricles or subdural space.	Death from pulmonary complications.

CONTUSIONS OF THE CRANIAL BONES.

These, like fractures, may be either simple of compound. The diagnosis of their presence in either case can be made only from inspection of the wound and from the presence of intracranial injury without fracture of the skull. Their occasional resemblance to a fracture if filled with dirt or hair has been referred to on page 25.

HERNIA CEREBRI.

Hernia cerebri is the term given to a prolapse of the brain which may either immediately follow an injury or be the result of greatly increased intracranial pressure, such as (*a*) occurs from infection of the meninges or brain following an injury, or (*b*) the presence of a tumor within the cranial cavity.

The diagnosis of a primary hernia cerebri can be made from the protrusion, through a wound in the skull, of brain substance. If there is any question at the time of injury as to whether the protruding substance is brain, an examination of the material will show ganglion cells.

FIG. 26.—SECONDARY HERNIA CEREBRI FOLLOWING COMPOUND FRACTURE OF THE FRONTAL BONE IN A BOY OF EIGHT.

The diagnosis of a secondary hernia cerebri (Fig. 26) can be made from the presence of a soft mass which protrudes through the gap in the skull and pulsates synchronously with the heart. It is irregular and red or dark in color. After a short period the surface becomes necrotic, of a grayish color, has a foul odor, and bleeds easily, so that after a few days all of the brain tissue has sloughed away, leaving simply a bleeding mass of granulation-tissue. Pressure on this soft tumor causes symptoms of intracranial pressure.

TRAUMATIC EPILEPSY.

The diagnosis of traumatic epilepsy depends upon a careful analysis of the following factors: First, an accurate history of a recent or old trauma to the skull; second, the objective examination of the scalp and skull for evidences of the injury—this is best conducted when the scalp is shaven, and in all doubtful cases this should be done; third, a careful study should be made of the mode of onset, of the form of the twitchings or convulsions, whether tonic or clonic in character, and of the distribution of the twitchings or spasms; fourth, every effort should be made

to exclude the possibility of the epileptiform seizures being of the non-traumatic variety.

In connection with the first factor, one should ascertain as closely as possible the symptoms following the injury which has been suspected to have produced the epilepsy. In many cases one can get a history of a compound fracture, frequently of the depressed variety, in which after relieving the depression the fragments were replaced.

Again one can secure the history of symptoms of intracranial injury severe enough to have been produced by a fracture of the skull, in which no operative interference took place, so that it is proper to assume that the epileptiform convulsions are due to a non-corrected depressed fracture. This latter conclusion is corroborated if the objective examination of the scalp shows a distinct depression at the site of injury.

One should always examine the scalp and skull for scars and for areas of depression in the skull. The absence of scars or depressions in the skull does not exclude the possibility of the epileptiform seizures being due to an injury, since traumatic epilepsy follows non-depressed fractures as frequently as it does depressed ones.

One should also examine the patient further to ascertain whether scars or neuromata at other portions of the body than the head could be the starting-point of the convulsions, since it is well known that such scars or neuromata on the trunk and limbs may act as irritants sufficient to produce epileptiform convulsions.

The history and objective examination are further of value in cases where an operation has been performed on the skull or brain, for the removal of tumors, drainage of abscesses, etc.

Traumatic epilepsy generally begins in one group of muscles, and extends to adjacent areas of the cortex, in a definite order. Which centers are first affected depends entirely, in the case of bone, dural, or cortical changes, upon the situation of such lesions. The onset of the convulsions may be preceded by an aura which consists of pain in the scar or of numbness in the affected muscles.

In a typical case of traumatic epilepsy the convulsions are Jacksonian in character. They are at first clonic, and then tonic, in character, followed by more or less stupor and coma, and by temporary paralysis in the affected muscles. Rarely do the convulsions travel to the opposite side of the body, although there are cases in which the convulsions are general from the very beginning of the disease.

In the differential diagnosis one must exclude cortical irritation, due to tumor or abscess of the brain. One must also exclude the epileptiform seizures following infantile or adult hemiplegia. Again, there

is a so-called form of non-traumatic Jacksonian epilepsy which can be readily differentiated by the absence of the history of trauma or of any objective evidences of the same. In the common or essential non-traumatic epilepsy in which generalized convulsions occur, the onset of the convulsions is usually preceded by an aura and there is no history of trauma. This latter condition has also usually existed from infancy.

MENTAL CONDITIONS FOLLOWING CRANIAL INJURY.

The diagnosis of whether a disturbed mental condition is a direct sequence of an injury is difficult to say, for the reason that in many cases the symptoms may not appear until months or years after the injury, which may have been a slight one. In general, one may speak of primary conditions which directly follow the injury, and of secondary or late sequelæ. The primary conditions most frequently found are, first, defective memory, and, second, recurrent headache. In regard to the former, it may disappear, or remain as a permanent condition. There is often a marked loss of memory, or the patient only forgets the common things of everyday life. Not infrequently the musical and arithmetical faculties are lost, and there is a lack of concentration of the mind.

The third symptom of psychical change is greater irritability. Vertigo is often quite marked, especially on bending forward. Not infrequently other mental symptoms may follow the injury, especially if there has been contusion of the frontal lobes. These are delirium, restlessness, hallucinations, and insomnia. These latter symptoms disappear within two or three weeks after the injury, but leave a state of greater mental irritability, so that the patient is not able to resume his ordinary occupation for some time.

The late traumatic mental changes may be divided, according to Krafft-Ebing, into three groups. In the first the patients gradually become feeble-minded and idiotic, and associated with this condition there are disturbances in coördination and paralysis. In a second group the psychical disturbance develops after a long prodromal stage, in which mental irritability and change of character of the patient are noticed. These are followed by maniacal conditions, or by progressive paralysis. In a third group, the trauma seems to have only an indirect influence, affording a certain predisposition to the mental disease, which develops as the result of other accompanying causes.

DISEASES OF THE SCALP, SKULL, AND BRAIN.

DISEASES OF THE SCALP.

INFECTION.

The most frequent variety of infection of the scalp is in the form of furuncles and carbuncles. These are usually situated in the thick cellular tissue at the back of the neck. The diagnosis can be readily

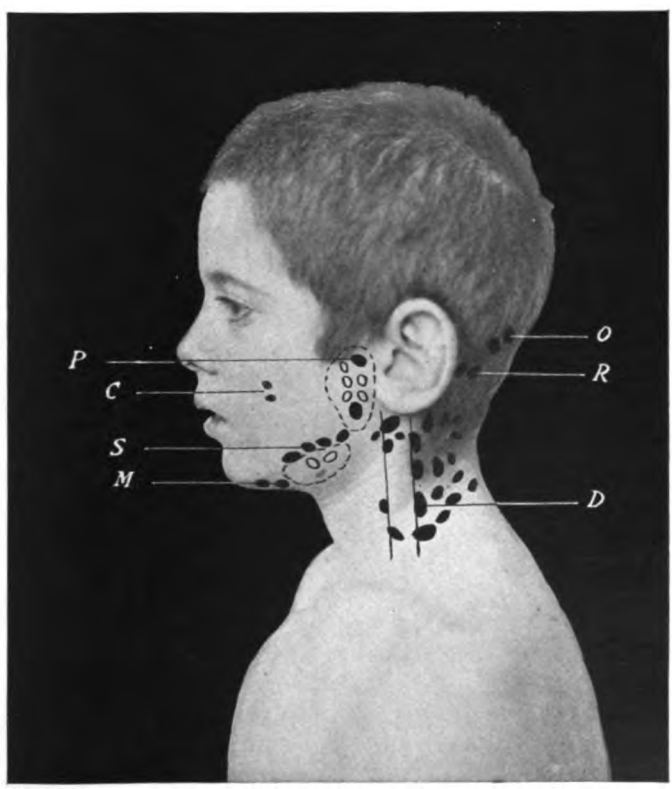

FIG. 27.—LYMPH-NODES OF FACE AND NECK.

The deep nodes are shown as black solid areas; the superficial as a black circle: *P*, Lymph-nodes lying within capsule of parotid gland; those lying upon the parotid and beneath the skin (preauricular nodes) are shown as black circles; *C*, lymph-nodes occasionally present in substance of cheek; *S*, submaxillary nodes lying within capsule of gland—those lying between the capsule and skin are shown as black circles; *M*, submental nodes; *O*, occipital nodes; *R*, postauricular or mastoid nodes; *D*, deep cervical nodes lying along the anterior and posterior borders of the sternocleidomastoid muscle and internal jugular vein, communicating with the nodes of the posterior triangle.

made from the central suppurating point in a furuncle and the tense area of infiltration surrounding it, which is quite characteristic of cutaneous infection in this region. In a carbuncle the area of induration is much more extensive and there are multiple foci of suppuration.

Carbuncles may become so large that practically the entire space below the occipital protuberance, as far down as the vertebra prominens, is occupied by a suppurating focus.

Infection of the Lymph-nodes.—The lymph-nodes draining the scalp are situated principally in front of and behind the ear, the former lying directly upon the parotid gland, the latter lying just below the superior curved line of the occipital bone. These may become enlarged, so that the surgeon is at times consulted. They may even suppurate, the suppuration often being very obstinate to treatment. The diagnosis can be readily made, by feeling nodules beneath the skin situated at the characteristic locations (Fig. 27), but every effort should be made to ascertain where the primary source is. At times pediculi capitis, eczema, and furuncles of the scalp will cause such an enlargement and suppuration of the lymph-nodes draining the scalp.

Phlegmon of the Scalp.—This usually follows infected scalp wounds. It can be recognized by the angry, swollen appearance and the tenderness of the edges of the wound. The granulations become edematous and there is constant discharge of pus. Pus may accumulate beneath the subaponeurotic layer, so that the entire scalp is raised, giving rise to distinct fluctuation all over the skull. The limits of the boggy swelling are the superior curved line of the occipital bone behind, the supraorbital ridge in front, and the zygomatic processes at the sides.

There is always danger in these cases of a septic thrombosis and meningitis, and the symptoms (see page 59) of these conditions should be looked for, especially if the phlegmon complicates a compound skull fracture.

Erysipelas of the scalp usually exists as a complication of the same disease in the face. It resembles ordinary infection of the skin of the scalp by causing a tense infiltration whose edge is sharply marked. The diagnosis can be made from this tense infiltration as well as from the many small bullæ or blisters and the pinkish discoloration of the skin of the scalp, which, like the infiltration, terminates rather sharply. Such a sharp demarcation is characteristic of erysipelas elsewhere, and is described more fully in the diagnosis of facial erysipelas on page 91. There is usually also some rise of temperature and moderate constitutional disturbance.

TUMORS OF THE SCALP.

Tumors of the scalp may be either benign or malignant. The former are far more frequent. In adult life sebaceous cysts constitute the larger number of benign tumors of the scalp. They occur either

singly or as multiple tumors and can be recognized from the fact that the tumor projects above the level of the scalp, the skin over it being stretched. It is distinctly movable upon the aponeurosis, and as a rule the skin covering it is not adherent. It is round in form but in the occipital region may be polypoid. If the surface is ulcerated and hard, carcinomatous degeneration has occurred (see below).

Dermoid cysts are usually smaller than sebaceous cysts and are situated at definite places, such as the root of the nose, inner and outer angles of the orbit, and at times within the orbit itself. Their size varies from a hazelnut to an egg. Their base is usually fixed, so they can be moved but little upon the skull, to which they are firmly attached.

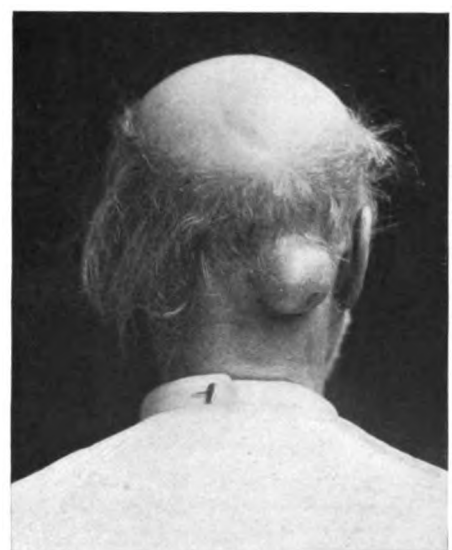

FIG. 28.—SEBACEOUS CYST OF OCCIPITAL REGION, WITH ULCERATION OF SURFACE.

A dermoid cyst must be differentiated from a meningocele. The latter occurs in the median line at the front and at the back of the skull (Fig. 29). It can usually be compressed, pulsates, and enlarges when any exertion is made. In children, in whom meningoceles are most frequently found, crying causes them to become more tense, and the reduction of the contents causes cerebral pressure symptoms. After a meningocele has been reduced, one can often feel the edges of the gap in the skull through which the tumor has protruded (see page 71).

Among the rarer forms of tumor of the scalp may be mentioned a pneumatocele, which will be readily recognized by the fact that it is situated over the mastoid or frontal regions, usually the former. It contains air, so that it is tympanitic on percussion. It is soft and elastic, and the air can be gradually pushed in through the gap in the skull.

Lipoma of the scalp occurs, chiefly in the frontal and temporal regions, as a flat, soft tumor, which does not raise the scalp as much as either dermoids or sebaceous cysts. In the temporal region it may attain some size, and give rise to a sense of pseudo-fluctuation.

Fibromata are rare. They are usually quite soft, and often present as a part of a generalized condition.

Warts can be readily recognized on the scalp. They are quite small, and bleed easily.

Pigmented moles occur quite frequently and are recognized by their brownish color, and the fact that they are slightly raised above the level of the skin of the surrounding scalp. They may develop into melanotic sarcomata (see below).

Vascular tumors of the scalp are most often present in the form of simple angiomata upon the forehead. They appear as bright red spots, slightly raised above the level of the scalp. The color can be

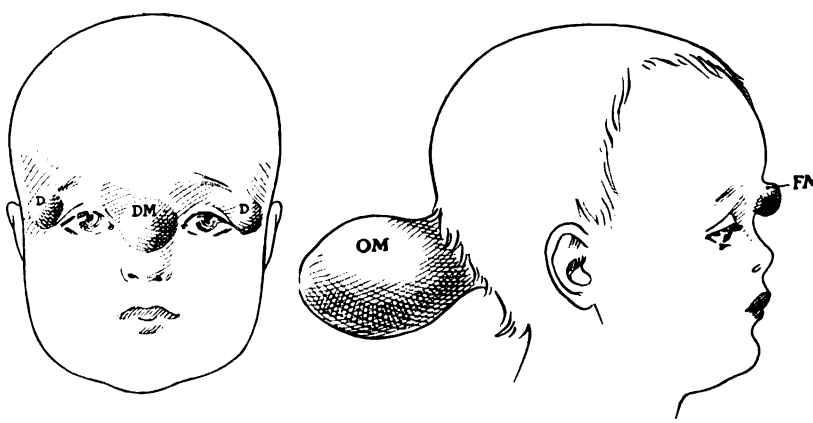

FIG. 29.—LOCATION OF VARIOUS TUMORS OF SKULL AND FACE (DIAGRAMMATIC).

D, Location of dermoid cyst at outer angles of orbits; *DM*, location of dermoid cysts at root of nose, and of meningocele of the naso-frontal type; *FM*, naso-frontal form of meningocele; *OM*, occipital form of meningocele.

made to disappear by pressure, but immediately returns when the finger is taken off.

A second type of angioma is the *cavernous*, which may occur with the simple or capillary form or be present independently. If the latter is the case the scalp is only slightly discolored, of a purplish hue, and the soft tumor can be caused to disappear to a great extent by pressure.

The fact that they do not pulsate and that there is no gap in the skull after they have been decreased in size by pressure, readily distinguishes simple and cavernous angiomata from meningoceles. At times they increase somewhat in size when the child cries, which may lead one to suspect it to be a meningocele.

A third variety of vascular tumor is the *cirsoid aneurysm*, which can be recognized as a mass of tortuous, elongated, and dilated

arteries. It feels like a bunch of worms and occurs especially in the frontal and temporal regions. It can be emptied by pressure, but refills. It pulsates, but ceases to do so when the temporal artery is compressed. This pulsation must be differentiated from that of a pulsating soft sarcoma, by the peculiar feeling one gets of elastic tubes filled with blood.

A fourth variety of vascular tumor is the *traumatic aneurysm*, in which there is a pulsating tumor, usually in the temporal or frontal regions, with an expansile pulsation and a distinct bruit.

A fifth variety is the *arterio-venous aneurysm*, which occurs either in the temporal or posterior auricular arteries. It can be recognized by the marked dilatation of the superficial veins leading to it, and the peculiar whirring sound at the point of communication of the vein and artery.

Malignant Tumors of the Scalp.—*Sarcomata* occur either as melanotic sarcomata, or as bleeding warts, in elderly people. They are usually soft, with overhanging edges, and can be recognized as belonging to the class of malignant tumors by their steady growth in all directions.

Carcinoma occurs as a primary form, either arising from the sebaceous cysts, or as a rodent ulcer on the forehead. The former can be recognized by the ulceration of a sebaceous cyst, and the marked induration of the edges of the ulcer.

Inflammatory Affections. Diseases of the Skull.

Tuberculosis of the skull may occur at any age, but is especially frequent in infancy and childhood, in the mastoid and petrous portions of the temporal bone. It may also occur in the frontal and parietal bones, especially when there are tubercular foci elsewhere. It can be recognized by its slow, insidious character. Unless there are intracranial complications, it causes but little tenderness or pain. Cases may present themselves with one of two conditions present, (*a*) either a sinus, lined with typical yellowish tubercular granulations, leading to bare and soft bone, or (*b*) as an unopened, cold abscess. Under the latter conditions care should be taken to differentiate such an abscess in the temporal region from a lipoma (see page 67).

The disease is a very progressive one, causing steady rarefaction of the bone, and often forming extradural collections of pus. These can be recognized by the presence of a dull headache and tenderness, and, in case of a large collection of pus, by the general symptoms of intracranial pressure.

Syphilis of the Skull.—This occurs in one of the four following

forms, which can be readily diagnosed by a careful history, a search for evidences of syphilis elsewhere, and the characteristic local findings:

First, as a periostitis, in the early weeks of the secondary stage. Here it produces a soft, flat elevation of the periosteum, which is extremely sensitive and causes much pain, the latter being especially severe at night.

Second, in the form of open gummata resulting in a worm-eaten condition of the bone (Fig. 30). Large areas of both tables, but especially the outer, become necrotic, and form sequestræ by a process of progressive osteoporosis or rarefaction. Each area is surrounded by a zone of osteosclerosis or hardened bone. Perforation of the skull, with subdural collections of pus, causing pressure symptoms, as is the case in tuberculosis, is quite rare in syphilis.

FIG. 30.—TERTIARY SYPHILITIC NECROSIS OF THE FRONTAL BONES.
Note the sharp, clean-cut edges of the area, and the necrotic bone in the center of the ulceration.

The third is in the form of an exostosis and enostosis of the skull. It is usually a result of osseous gummata.

Fourth, hereditary syphilis of the skull, which occurs in the form of ulcerations on the frontal and parietal bones of children, and the formation of nodules over the parietal eminences, known as Parrot's nodes.

Acute osteomyelitis and periostitis occur after septic compound fractures, furuncles, and middle ear disease. Usually there is considerable pain around the scalp wound, the scalp itself is red and swollen, there is distinct fluctuation, and when the wound in the skull is examined one either finds sequestræ, or the diploë is infiltrated with pus.

The chief point of interest in the diagnosis is to be able to exclude the various intracranial complications referred to on page 56.

Craniotabes.—This disease of the skull accompanies rickets, and consists of a softening of the skull-bones, especially in the parietal and occipital regions, so that the skull becomes almost translucent. It can be readily recognized by external palpation, the skull having a peculiar

elastic feeling, so that the bone can be distinctly pressed inward and springs back again.

It may be distinguished from hydrocephalus, which also causes a thinning of the skull-bones, by the fact that the head never attains as large a size. If tonic and clonic convulsions are present in a rachitic child, such a craniotabes may be mistaken for an abscess. The diagnosis can be made by consideration of the absence of the causes of suppuration.

FIG. 31.—ANTERIOR VIEW OF CASE OF ANGIOOSTEOMA OF THE LEFT FRONTAL AND PARIETAL BONES.

CONGENITAL DEFECTS OF THE SKULL.

Meningocele and Hydrocephalocele.—These are found chiefly in the occipital region and at the root of the nose. Rarely do they project into the pharynx. They cause either sessile or pedunculated tumors, which push the scalp before them, pulsate, and become tense during expiratory efforts. Those containing brain substance are usually much larger than those containing simple meninges. They affect the brain more than the latter. Many of the meningoceles can be reduced, but cause dullness. If the contents can be reduced, one can palpate a bony defect in the skull.

FIG. 32.—POSTERIOR VIEW OF ANGIOOSTEOMA OF PARIETAL BONE.
Same case as shown in Fig. 31.

Tumors of the Skull.

Osteomata.—This form of tumor may occur either on the vault of the skull or in one of the accessory sinuses, such as the frontal and sphenoidal. On the vault of the skull they may be diagnosed from the fact that their growth is very slow, their borders are sharp, they are extremely hard, are conical or mushroom in shape, and occur usually in the parietal and frontal bones. The osteomata may contain large vascular spaces and show a feeble pulsation. To this variety the name of angioosteoma has been given (Figs. 31 and 32).

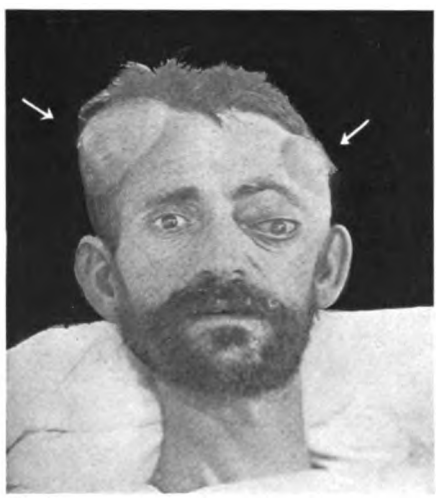

Fig. 33.—Multiple Osteo-sarcomata of the Skull.

The white arrows point to tumors situated in the right parietal and left frontal bones respectively. The protrusion of the left eye is caused by a tumor which has formed in the left frontal sinus, pushing the eye downward and outward.

Osteomata of the frontal sinus cause a diffuse swelling in the inner angle of the orbit, if they are unilateral, or at the middle of the forehead, if bilateral. They displace the eyeball, and can only be recognized when they have grown beyond the walls of the frontal sinus. The diagnosis can be confirmed by the use of the *x*-ray.

Osteomata of the sphenoidal sinus can be recognized from the pressure symptoms which they cause on the eyeball and optic nerve. If osteomata grow toward the inner side of the skull, their presence can be only suspected from the focal symptoms.

Echinococcus of the skull usually appears in the bone itself, but as often between the dura and the bone. It appears upon the surface as a cystic tumor, which can be recognized as an echinococcus if the disease is found elsewhere, or the characteristic hooklets are found in the cystic fluid.

Sarcoma.—Sarcoma of the skull may occur as a primary tumor in the periosteum or in the bone itself. Both of these form tumors which are hemispherical, and grow rapidly, are hard at first, and later become soft and ulcerated. Rarely an osteosarcoma occurs, containing hard and bony areas (Fig. 33).

Secondary sarcomata are more often multiple than the primary. They can be recognized by the fact that they have all of the characteristics of the primary growth just referred to, and the history or presence of such a primary focus.

Primary tumors of the dura or of the frontal, ethmoidal, or sphenoidal sinuses may penetrate the skull and grow externally as well as into the cranial cavity itself (Figs. 34 and 35). They cannot be distinguished from primary skull tumors, unless the case has been under

FIG. 34.—SIDE VIEW OF SARCOMA OF FRONTAL BONE WHICH INVADED INTERIOR OF SKULL AND ORBIT, CAUSING DISPLACEMENT OUTWARD OF THE EYE.

FIG. 35.—ANTERIOR VIEW OF TUMOR (SARCOMA) ORIGINATING IN FRONTAL BONE, WHICH INVADED CRANIUM AND ORBIT AND CAUSED DISPLACEMENT OF EYE. SAME CASE SHOWN IN FIG. 34.

observation from the earliest period. These dural sarcomata usually pulsate and cause intracranial symptoms.

Primary sarcomata of the brain may grow through the skull and present externally. Their growth is usually more diffuse than primary tumors of the dura.

NON-TRAUMATIC SURGICAL DISEASES OF THE BRAIN AND ITS ENVELOPES.

HYDROCEPHALUS.

The chief form of hydrocephalus which is of surgical interest is the chronic. It may be congenital or acquired. At times it may be impos-

sible to differentiate in a given case whether the condition was a congenital one or not. The causes for both are the same before the sutures and fontanelles are closed. These are a tubercular or posterior basic meningitis, a spina bifida, and rachitis.

FIG. 36.—SIDE VIEW OF CHILD SUFFERING FROM HYDROCEPHALUS.
Note how the face seems to be a mere parasite upon the enormous enlargement of the skull.

The diagnosis of hydrocephalus should never be made without comparing the circumference of the head with that of a normal child at the same age.

Hydrocephalus must be differentiated from rickets, and this is at times difficult, because the latter disease is often associated with hydrocephalus. They can, however, be distinguished from each other by the fact that in hydrocephalus there is apt to occur spastic rigidity, accompanied by convulsions and paralysis, as well as contractures in the paralyzed parts (Fig. 37).

FIG. 37.—SECONDARY CONTRACTIONS OF THE WRIST- AND FINGER-JOINTS IN HYDROCEPHALUS.

There is great impairment of mental development in hydrocephalus. The head is often retracted, there are night cries, unsteady gait and emaciation. In rickets the head is square or box-shaped; the fontanelles, although they are open, do not bulge; there is usually accompanying craniotabes but the enlargement is not so marked as in hydrocephalus. There are also usually present the characteristic rachitic enlargements at the junction of the costal cartilages and ribs and at the ends of the long bones, especially at the lower end of the radius and ulna.

Hydrocephalus must also be differentiated from tumors arising in early life from the third ventricle and posterior fossa of the skull. In these the enlargement of the head is very gradual and has not been present from birth, as in congenital hydrocephalus. In addition there are usually other general and focal symptoms, including, in the case of tumors, the presence of choked disc.

Tumors of the Brain.

The diagnosis of tumors of the brain can be made by the careful study of certain general and focal symptoms. The general symptoms indicate an increase of intracranial pressure. The focal symptoms are the evidences of pressure upon localized areas of the brain, causing more or less interference with their special functions. The **general symptoms** in the order of their frequency are:

I. *Headache.*—The headache is of a deep boring character, usually quite severe. It may be localized over the seat of the tumor or be diffuse all over the head. In tumors of the posterior fossa (pons, medulla, and cerebellum), the pain is characteristically situated in the occipital region.

II. *Vomiting.*—The character of cerebral vomiting is that it occurs without any effort, the contents of the stomach being thrown at times some distance in a projectile manner. The vomiting is also seldom preceded by nausea and is independent of the taking of food.

III. *Optic Neuritis.*—This is present at some stage in the majority of cases in one or both eyes. It is usually of such a degree as to give rise to the name *choked disc.* The larger the tumor, the more marked is this symptom. In cerebellar tumors it appears quite early, while in those in the motor region it appears quite late and in only 40 per cent. of the cases. It almost always results in optic atrophy.

IV. *Mental Symptoms.*—Stupor often marks the onset of the symptoms. It gradually develops into coma, which varies greatly in its intensity. Remission of the coma aids in distinguishing tumor from abscess of the brain, because the stupor and coma in the case of a tumor increase and decrease from time to time as intracranial pressure rises or falls. The psychical symptoms vary greatly and are most marked in tumors of the frontal lobe. There may be simple mental failure (loss of memory) and dullness, or marked mental confusion, or even actual delirium. Witzelsucht or loquaciousness, with a tendency to joke on all subjects, is occasionally found in tumors of the first frontal convolution.

V. *Slow Pulse and Marked Increase of Blood-pressure.*—In many

cases of brain tumor both of these symptoms are quite marked, the pulse sinking at times to forty beats per minute and the blood-pressure rising greatly, as determined by the use of the modified Riva-Rocci apparatus.

VI. *Vertigo.*—This is especially marked in cerebellar tumors, and is of value as a symptom if other causes of vertigo, such as ear and gastric causes, can be eliminated.

VII. *Apoplectiform attacks* occur from time to time through hemorrhages into the tumors, and may simulate ordinary apoplexy in the absence of a complete history.

VIII. *General convulsions* are apt to occur if the tumors are in the cerebral cortex.

IX. The skull is tender over the site of the tumor if the latter is superficial.

Focal Symptoms.—*Tumors of the Frontal Lobe.*—There are no localizing symptoms unless the growth compresses the motor centers in the adjacent pre- and postcentral gyri, or compresses the motor speech-center in the third left frontal convolution. Marked disturbances in mentality are usually associated with general symptoms of cerebral pressure in tumors of the frontal lobe, and are more marked in those of the right side. These mental disturbances are mental dullness or confusion, witzelsucht, irritability and childishness, or loss of memory (Fig. 20).

Motor Region.—Attacks of Jacksonian epilepsy occur, often preceded by disturbances of sensation such as tingling in the affected parts, in tumors of the motor region, and in irritation of the motor center from any cause. The parts which twitch, or are affected by disturbances of sensation and motion, vary according to the area involved (Fig. 19), so that it is possible to more accurately localize tumors of this region than those of almost any other. As the tumor grows, the attacks extend over a greater number of muscles, but are always localized, according to the situation of the motor centers in the cortex. For example, it may begin in the muscles of the leg and then involve those of the arm, and later still those of the face, on the side of the body opposite to that upon which the tumor is situated in the brain. Later in the course of the disease pareses or paralyses or even contractures occur in the affected muscles. Other symptoms than those of cortical irritation or pressure upon the motor centers are not infrequently associated in tumors of the motor region, some through direct pressure upon adjacent areas in the parietal or frontal lobes, others due to indirect effects of pressure (Fernwirkung). If the tumor is on the right side

in left-handed people, there may be motor aphasia or agraphia; if the third frontal convolution is compressed there is a loss of muscle sense and anesthesia of the paralyzed limb through pressure upon the parietal lobe.

Tumors of the Parietal Lobe.—Tumors of this lobe can be recognized by the absence of attacks of Jacksonian epilepsy and of paralysis, and by the presence of a marked loss of muscle sense or astereocognosy. If situated in the lower part of the parietal lobe, they may produce alexia and often agraphia. Tumors of the left temporo-sphenoidal lobe produce word-deafness, paraphasia and auditory hallucinations. This is the case especially in tumors of the first left temporo-sphenoidal gyrus. In tumors of the posterior portion of the left temporo-sphenoidal lobe, and extending toward the occipital lobe, there is visual aphasia.

Tumors of the Occipital Lobe.—Tumors involving the cuneus and first occipital convolution produce homonymous hemianopsia. Involvement of other portions of the lobe, if the cuneus is not greatly involved, produces soul-blindness, or incapacity to understand the things which one sees.

Tumors of the Cerebellum.—Tumors of the cerebellum, in addition to producing the well-marked symptoms of increased intracranial pressure, referred to under the head of general symptoms, produce somewhat characteristic focal symptoms. Vomiting is quite frequent. Early optic neuritis with blindness occurs very early, and paralysis of the external rectus muscle is very common and often bilateral. There is also apt to be rigidity of the neck, and involvement of the olfactory, oculomotor, and trigeminal nerves on the side of the tumor. One of the most characteristic symptoms is a severe occipital headache, most marked upon arising. Attacks of amyasthenia and general vertigo are also frequent. Another characteristic symptom is the so-called cerebellar ataxia. This latter is especially marked in children, who have a tendency to fall to one side in walking; usually toward that upon which the tumor is situated.

Tumors of the Pontomedullocerebellar Space.—A class of tumors has been recently described whose essential features distinguish them from tumors of the cerebrum and cerebellum. This feature is the early appearance of symptoms referable to the fifth or eighth cranial nerves. When involving the eighth nerve they are sometimes described under the name of neurofibromata of the acoustic nerve. They grow slowly, hence the symptoms referable to the involvement of the fifth or eighth nerve may precede the other symptoms for a long period. In the case of the fifth nerve these prodromal symptoms are obstinate and

show themselves as atypical attacks of facial neuralgia, for which no other peripheral or central cause can be found. The symptoms of the early involvement of the eighth nerve are tinnitus aurium with progressive diminution of hearing and aural vertigo. As the tumor increases in size, we have other evidences of pressure.

The diagnosis rests upon the symptom-complex of tumors of the posterior fossa, preceded by well-marked and long-continued signs of auditory or trigeminal involvement. These general and focal symptoms are those of increased intracranial pressure in the posterior fossa and are—(1) general: headache, vertigo, vomiting, optic neuritis, bradycardia; (2) focal: peduncular ataxia, cerebellar ataxia, lateropulsion, hemiasynergy, homocontralateral and crossed paralyses of the extremities, paralysis of the cranial nerves at the base of the skull (especially the fifth, sixth, and seventh), dysarthria, dysphagia, nystagmus, paralysis of the conjoint movements of the eyes, inequality of the pupils, and attacks of Adams-Stokes syndrome.

Before making a diagnosis of a primary tumor of these nerves, one must exclude primary disease of the base of the skull and meninges, such as syphilis and tumors of the bones of the base of the skull, and also exclude aneurysm of the vertebral artery.

Tumors of the Middle Fossa of the Skull.—These have their origin either in the pituitary body or the optic chiasm. If the pituitary body is involved the symptoms may for a long period be those of acromegaly (Fig. 38) and the general symptoms of intracranial pressure may not appear for a long period.

In tumors involving the optic chiasm irregular forms of hemianopsia appear. Optic neuritis and atrophy is a very early symptom.

The diagnosis of whether a tumor of the brain exists, and where it is located, may be made from a consideration of the general and focal symptoms just referred to. Of the former, the most constant are the headache, the vomiting, the choked disc, slow pulse, and mental symptoms, including stupor or coma, as the case may be. The focal will depend upon the location of the tumor and the extent to which neighboring areas of the cerebrum or cerebellum are pressed upon.

In regard to the *nature of the tumor*, variations in pressure—that is, remission in the symptoms and apoplectic attacks—speak for gliomata. These occur especially in childhood and early life. Syphilitic gummata can only be distinguished from other tumors of the brain by the history of preceding infection, or finding evidences of syphilis elsewhere in the body. They are apt to occur late in life.

Multiplicity of symptoms speaks for tubercles. These occur espe-

cially in childhood, and there is often evidence of a tuberculous focus elsewhere.

The most frequent variety of tumor of the brain is the tubercle. The next most frequent is sarcoma. Carcinoma and parasitic cysts (echinococcus and cysticercus) are comparatively rare. For practical purposes it will only be necessary, as regards the nature of the tumor, to distinguish between tubercle, glioma, and sarcoma. The two former occur most frequently in childhood, while sarcomata occur in adult life.

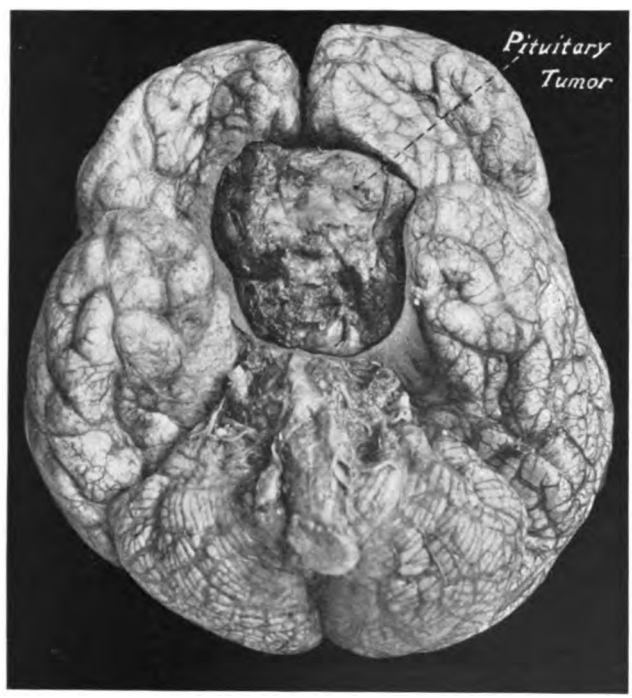

FIG. 38.—TUMOR OF PITUITARY BODY CAUSING ACROMEGALY.

In the *differential diagnosis* of tumor of the brain one must exclude abscess of the brain. Multiple sclerosis may also simulate a tumor, especially if there is optic neuritis or atrophy present, but there are usually no stupor, convulsions, slow pulse, vomiting, aphasia, or cortical epilepsy present in this disease.

The eye should be examined in every case of long-continued headache, and, if choked disc be found, the following other causes for it should be excluded: Hydrocephalus, meningitis, abscess of the brain, nephritis, chlorosis, and chronic lead-intoxication.

The differential diagnosis of abscess from tumor of the brain is given in the following table:

Tumor.	Abscess.
1. No primary focus of infection but often history of syphilis or malignant disease of other organs.	1. Suppurating area in ear, nose, pharynx, scalp, or lung abscess.
2. Very slow development.	2. More rapid.
3. More definite focal symptoms.	3. Focal symptoms often present but not so definitely localized as in tumor.
4. No rigors or septic symptoms.	4. Often begins with chills, septic symptoms often continue.
5. Temperature normal or slightly and irregularly elevated.	5. Temperature subnormal, other times higher—pus temperature.
6. Pulse slow.	6. Not slow as a rule.
7. Constant headache.	7. Not a constant or prominent symptom.
8. Projectile vomiting frequently present.	8. Not often; vomiting, if present, more frequent and not projectile.
9. General symptoms of pressure progressive.	9. When present, they vary greatly in intensity.
10. Choked disc constant.	10. Not constant.

THE INTRACRANIAL COMPLICATIONS OF MIDDLE EAR AND MASTOID SUPPURATION.

These are:

1. Epidural abscess or otitic pachymeningitis.
2. Purulent leptomeningitis.
3. Serous meningitis.
4. Cerebral and cerebellar abscess.
5. Sinus thrombosis.

I. Extradural Abscess.
(Epidural or Perisinuous Abscess.)

This condition is most frequently due to the extension of infection from a diseased mastoid or sigmoid sinus. It is more frequent on the right side. It is usually found during the operation for mastoid suppuration or may be suspected as a complication if symptoms such as fever, headache, tenderness, edema around the wound, and profuse discharge of pus persist, after opening the mastoid.

Focal symptoms are rare except in children. If the extradural abscess is on the left side there may be sensory aphasia. If it is beneath the dura of the middle fossa there may be pareses of the opposite half of the body and disturbances of sensibility. There are also general symptoms of increased intracranial pressure such as somnolence, vomiting, slow pulse, pain, and choked disc.

All of these symptoms may be present in purulent meningitis and cerebral abscess, so that the diagnosis must be made to a great extent from the local findings, which are as follows:

1. Persistence of profuse purulent discharge from the ear after a mastoid operation.

2. Edema and tenderness around the wound and the formation of subperiosteal and subcutaneous abscesses and fistulæ just behind the mastoid or on the squamous portion of the temporal bone.

II. Purulent Leptomeningitis.

This may appear in an acute or protracted form. As in other forms of intracranial complication of middle ear suppuration, there are both general and focal brain symptoms in addition to those of the local infection.

The general signs of intracranial pressure are:

(*a*) Headache. This may be on the side of the disease alone. It may be frontal or occipital or be present over the entire head. It is usually quite severe.

(*b*) Optic neuritis. This may or not be present. It is less frequent in a leptomeningitis than in cerebral or epidural abscess. It is more often found in basilar than in cortical leptomeningitis.

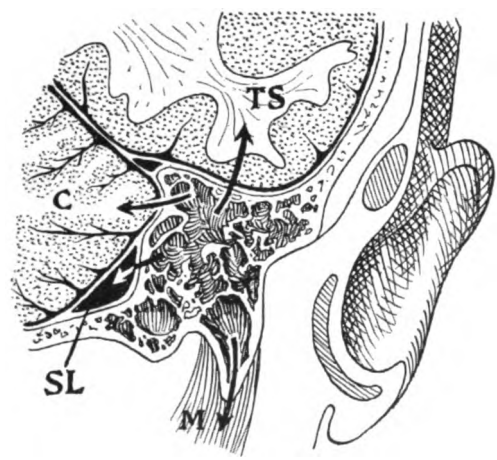

Fig. 39.—Modes of Transmission of Infection from Mastoid Process.

The arrows show the direction in which infection travels: (1) into temporo-sphenoidal lobe, *TS*; (2) into cerebellum, *C*; (3) into lateral sinus, *SL*, and free apex of mastoid into tissues of the neck, *M*.

(*c*) The pulse is rapid and there is often stupor and delirium.

(*d*) Respiration is slow, irregular at times, and may be Cheyne-Stokes in character.

The focal signs depend upon whether the meningitis is most marked at the base or on the convexity. If the process is predominant on the latter there may be focal signs such as one expects to find only in a cerebral or cerebellar abscess. These are paralyses upon the opposite side of the body, convulsions, motor aphasia or agraphia. If most marked at the base there is rigidity of the

neck and paralyses of the cranial nerves (especially of the fourth and sixth nerves).

In the acute form the temperature is high, while in the protracted form it may be normal or subnormal.

It can only be differentiated from an extradural abscess by the results of the operative treatment, *i. e.*, if the condition of the patient improves after opening the skull, an extradural focus existed. If there is a continuation and progression of the symptoms, leptomeningitis is present.

Only by finding tubercles in the choroid coat of the eye or tubercle bacilli by lumbar puncture can one positively differentiate the protracted form from a tubercular meningitis. Convulsions are less common, however, in simple purulent meningitis than in tubercular.

From the epidemic form of cerebrospinal meningitis, one can differentiate it by the more marked neck rigidity and opisthotonos and by finding the meningococcus by lumbar puncture.

III. Meningitis Serosa (Serous Meningitis).

This may also occur in an acute or chronic form, and is in reality an edema of the meninges. The symptoms are similar to those of the purulent variety just described and one can only differentiate it by the absence of fever, by the absence of pus in the lumbar puncture, and the course of the disease, which tends to recovery in the majority of cases.

The symptoms of the chronic form are similar to those of tumor, both the general and focal symptoms. It is only by recalling the fact that the symptoms have appeared after a middle ear disease and the tendency to spontaneous recovery that one can make a diagnosis.

IV. Abscess of the Brain.

Indefinite symptoms such as slight headache and mental depression and evening rise of temperature may exist for weeks to months in a patient suffering from a chronic otitis media and then suddenly marked cerebral symptoms appear. In other cases the symptoms may appear as a complication of one of the three following conditions:

(*a*) A chronic purulent discharge may suddenly cease.

(*b*) As an accompaniment of an acute otitis media and mastoiditis.

(*c*) Acute exacerbation of a chronic purulent discharge.

The majority of the abscesses are located in the temporo-sphenoidal lobe, the remainder in the cerebellum (Fig. 39).

The **general symptoms** of brain abscess are:

1. Headache which may be located over any portion of the head,

so that it is of little value as a symptom in localizing the seat of the abscess.

2. Nausea and vomiting.

3. The patient is mentally dull and becomes stuporous. As the intracerebral compression advances, coma sets in.

4. Convulsions occur, which are either localized or general. They are most frequently found in children.

5. Optic neuritis is more frequently present in abscess of the brain than in any other form of intracranial suppuration. It is usually simultaneous in its appearance in both eyes, but may exist on the affected side some time before appearing in the other eye. It is not as constant a symptom as in the case of a cerebral tumor and may not appear until late in the disease.

6. Slow pulse. This if present is a valuable sign of an increased intracranial tension, but it is quite inconstant in its appearance.

7. Localized tenderness of the skull is often present over the seat of the abscess.

Focal Symptoms of Brain Abscess.—*Temporo-sphenoidal Abscesses. Irritation and Paralytic Symptoms.*—These are pareses of the face, arm, and leg, on the opposite side of the body, often accompanied by spasms or convulsive movements in the affected muscles. Usually the face is involved first, then the arm, and last of all the leg centers.

Cortical facial paralysis can be distinguished from the peripheral form by the fact that in the former the eye muscles (orbicularis palpebrarum and corrugator supercilii) supplied by the facial are not involved. Abscesses of this lobe may also cause hemianesthesia and homonymous hemianopsia through indirect pressure. The latter two symptoms are often absent. In addition there may be paralysis of the motor oculi nerve on the side of the abscess. In a similar manner there may be hemianesthesia or motor aphasia, also through indirect pressure.

Abscess of the Cerebellum.—An abscess situated here usually causes vomiting and vertigo quite early. There are all kinds of pressure symptoms on the medulla, such as crossed paralysis, bilateral paralysis, and marked slow respiration and pulse.

Diagnosis of Otitic Cerebral Abscesses in General.—The diagnosis of an otitic cerebral abscess is impossible during the latent stage, as well as in the terminal stage when the symptoms of meningitis, such as vomiting, restlessness, clonic spasms, rapid pulse and respiration and high temperature appear. If during this terminal stage the abscess has ruptured into the ventricle, instead of through the meninges, the pupils become widely dilated, the respirations and temperature are

very high, and convulsions and tetanic seizures are followed by coma and death. The only stage in which a diagnosis can be made is in the so-called manifest stage, and even in this it is often uncertain. It is especially difficult in children, because the localizing signs are less marked and it is difficult to differentiate a tubercle from an abscess. The diagnosis is easy if one finds an external fistula leading to the abscess or if one opens the mastoid and finds a fistula leading through diseased bone to the abscess. In the majority of cases, however, there is no external fistula and one must depend on the brain symptoms alone.

The differential diagnosis between an extradural and an intracerebral or cerebellar abscess is very difficult unless found at operation, because both may cause the same symptoms, especially in children. The diagnosis from tumor is the most difficult of all, especially in children with tubercular disease elsewhere. Here the multiplicity of symptoms through the presence of multiple tubercles speaks for tumor, whereas symptoms which are due to the most frequent location of cerebral abscess speak for the latter.

Optic neuritis is usually more marked in tumors than in abscesses, and present at an earlier stage. The symptoms both general and focal of a tumor are slower in making their appearance, and there are apt to be periods of temporary improvement. (See page 80.)

V. Sinus Thrombosis.

The majority of these occur as a complication of mastoiditis or after a mastoid operation has been performed. There are two classes of cases:

1. Those with marked symptoms of sinus thrombosis and pyemia.

2. Those which resemble a septicemia in type and have no local signs of sinus involvement.

The symptoms of the first clinical form are:

1. Temperature. The fever is of the remittent type, there being a difference of 4 to 5 degrees in the daily temperatures.

2. Chills and sweats accompany the rises in temperature but may be absent, especially in children.

3. The pulse varies according to the temperature, being 120 to 140, during the chills.

4. The pain in the head is usually very severe, much more so than in an ordinary case of mastoiditis, and is referred to the side of the head and to the occipital region.

5. The sensorium is clear unless there is a complicating abscess or meningitis.

6. Optic neuritis and choked disc are present only in cases of cavernous sinus thrombosis.

7. Nausea and vomiting are usually present to a greater or less degree.

8. The spleen is enlarged and there are evidences of metastases in the lungs, subcutaneous tissues, and joints. The embolic abscesses in the lungs can be recognized by pains, coarse râles at various places, and prune-juice expectoration. These signs at first are localized but later are present over both lungs and may result in empyema or in pyopneumothorax.

9. Symptoms of thrombosis of the individual sinuses. In the case of the *sigmoid sinus* these are:

(*a*) The internal jugular vein is occasionally to be felt as a firm tender cord. This may be simulated by inflamed glands.

(*b*) Signs of compression of the ninth, tenth, eleventh, and twelfth cranial nerves—such as dyspnea, dysphagia, hoarseness, and slow pulse.

(*c*) Edema of the mastoid region.

In the case of the *cavernous sinus* they are:

(*a*) Edema of the forehead and eye-lids, chemosis, hyperemia of the retina, and optic neuritis (the latter is fairly constant in this form of thrombosis).

(*b*) Paralysis of the third, fourth, and sixth nerves.

(*c*) Retrobulbar edema with exophthalmos.

(*d*) Neuralgia of the supraorbital nerve (deep-seated pain).

(*e*) Dilated supraorbital, angular, and frontal veins.

The above ocular symptoms may appear in one or both eyes.

10. Leukocytosis is always present.

The diagnosis of the pyemic form of sinus thrombosis may be made from the remittent type of fever, splenic tumor, metastases, and local signs of thrombosis of either the sigmoid or cavernous sinuses. If associated with meningitis or abscess the symptoms of thrombosis predominate.

The septicemic form is characterized by the high continuous fever, rapid weak pulse, septic diarrhea, icterus, and nephritis. This form can be distinguished from typhoid by the absence of the Widal reaction and the presence of leukocytosis as well as by the local signs of mastoid involvement.

INJURIES AND DISEASES OF THE FACE.

INJURIES OF THE SOFT PARTS OF THE FACE.

The principal points of diagnostic interest in regard to injuries of the soft parts—that is, the skin and subcutaneous tissue—of the face, is that contused wounds around the orbit show a relatively larger amount of swelling than similar wounds in other parts of the body, owing to the loose arrangement of the subcutaneous connective tissue.

In contusions of the skin of the nose there is but little swelling or discoloration. It not infrequently happens that blows upon the nose, especially over the root of the nose, are followed by a considerable discoloration and swelling of the skin of the eyelids, which may not appear until from twenty-four to forty-eight hours after the injury. Contused wounds around the orbit have sharp edges, as though inflicted with a cutting instrument.

Incised, lacerated, and gunshot wounds of the face present no difficulty in diagnosis, and resemble in almost every respect similar wounds elsewhere in the body. As is the case in the scalp, a large flap of skin may be detached and still be followed by primary union.

In wounds penetrating the duct of Steno, in any portion of its course, a salivary fistula is apt to follow, if the duct is cut. This occurs most frequently in that portion of the duct which passes through the buccinator muscle, that is, about opposite the second molar tooth.

A division of the facial muscles causes no ill effects, with the exception of the levator palpebræ muscle, whose injury may result in inability to raise the upper lid.

Injuries of the arteries and nerves of the face occur in connection with lacerated and incised wounds, and at times after gunshot wounds. Bleeding from the facial artery or its larger branches is usually quite profuse. Injury of the facial nerve is of comparativly little significance, unless the main trunk of the nerve is injured before it divides within the parotid gland.

There is great danger of infection of the antrum in punctured wounds of the face. In gunshot wounds the structures injured vary according to the course of the bullet, the chief danger being a laceration of the internal maxillary artery, which will result in the rapid formation of a hematoma and the escape of blood into the mouth.

Burns and freezing affect especially the tip of the nose and the more exposed portions of the cheek, and may result in deeper loss of tissue, with resultant cicatrization and deformities. This is especially true of burns, which may cause marked ectropion.

INJURIES OF THE BONES OF THE FACE.

FRACTURES.

Fractures of the nasal (Fig. 40) **bones** occur usually at their points of attachment to the frontal and superior maxillary bones. They are often complicated by fractures of the vomer and perpendicular plate of the ethmoid, as well as by fractures of the cartilaginous septum of the nose.

The diagnosis may be made from the flattened appearance of the nose. By grasping the nasal bones between the index-fingers of both hands and moving the nose in a lateral direction to and fro one can readily obtain abnormal mobility and in many cases crepitus.

FIG. 40.—WIDENING OF NOSE FOLLOWING COMPOUND FRACTURE OF THE NASAL BONES IN BOY OF TEN.

Nasal Septum.—The diagnosis of injury of the nasal septum may be made in some cases from the external appearance alone, the nose turning well over to one side. This deviation of the nose may involve the tip or the entire nose. There is usually considerable interference with respiration and more or less epistaxis.

The diagnosis of the extent of the injury to the septum can only be made by an examination of the interior of the nose through the anterior nares. At times the septum is only bent, so that there is no deformity externally. Severe fractures of the nasal bones are often complicated by fractures of the anterior fossa of the skull, so that the symptoms of the latter predominate, and it is not until all swelling of the eyelids and around the root of the nose has disappeared, that the diagnosis of the fracture of the nasal bones is made.

In fractures of the nasal bones which extend into the frontal sinuses, there may be extensive emphysema of the upper portion of the face.

At times a fracture of the nasal bones will be followed by epiphora, through involvement of the nasal ducts.

Fractures of the Malar Bone.—This bone is usually fractured at its junction with the superior maxilla, or with the zygomatic process of the temporal bone. A rotation takes place of the malar bone, so that at its junction with the zygomatic process a distinct depression is to be felt, whereas at its point of junction with the malar process of the superior maxilla there is a prominence at the outer third of the lower border of the orbit (Fig. 41).

This deformity may be reversed if the blow has been received over

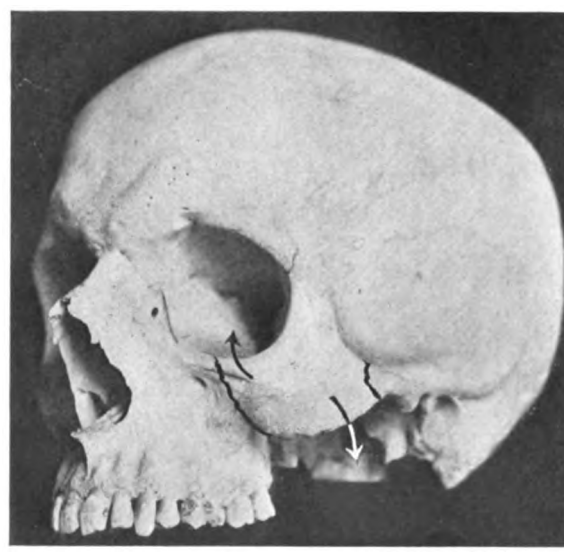

FIG. 41.—FRACTURE OF MALAR BONE.

A frequent seat of fracture of the malar bone is along the lines shown, namely, at its junction with the superior maxilla and the zygomatic process of the temporal bone. The arrows show the direction in which the fragments composed of the entire malar bone are dislocated.

the eye instead of over the zygoma, so that there is a depression along the lower border of the orbit and an elevation along the zygoma.

In crushing injuries of the malar bones there is a simple flattening of the prominent portion of the cheek normally formed by the malar bone.

There is great danger in these fractures of the malar bone, of injuring the orbit or the infraorbital nerve. A depression over the zygoma may cause some interference with the use of the muscles of mastication.

Fractures of the Superior Maxilla.—Fractures of this bone seldom occur alone, being usually associated with those of the other bones

of the face. They may simply involve the alveolar process, which occurs after faulty extraction of teeth or blows upon the jaw. Fractures of the body of the bone are usually multiple or comminuted.

The diagnosis may be made by inspection and palpation of the bone. At times one may feel a fissure in the bone, or a depression, which crepitates on pressure. The cheek is sunken in. Examination through the mouth shows that there is a distinct gap between two of the teeth, and if the fracture is a comminuted or a multiple one, as is often the case, there is abnormal mobility and the teeth are not in line with each other.

In fractures involving the anterior wall of the antrum, or in those in which the fracture line extends up into the frontal sinus, there may be some emphysema of the upper portion of the face.

Gunshot fractures of the superior maxilla or injuries following the bursting of shells in war are not infrequent. A diagnosis may be readily made by a direct inspection of the wound.

FIG. 42.—HEMATOMA OF FACE OVER MALAR BONE RESEMBLING MALIGNANT GROWTH, ON ACCOUNT OF SLOW ABSORPTION OF BLOOD AND MARKED INDURATION.

Fractures of the Inferior Maxilla.—The majority of these occur close to the canine teeth, either on one or both sides of the jaw. They most frequently follow a direct force, such as a blow, or a fall upon the chin. Fractures of the body are far more frequent than those of the ramus. The latter are comparatively rare.

The diagnosis of a fracture of the body is not difficult, and may be made by grasping the jaw in the manner shown in Fig. 43 on either side of the fracture, with the thumb and index-finger of each hand. One can usually obtain a false point of motion and crepitus. In addition, fractures of the body reveal, upon examination of the mouth, an unequal

position of the teeth on either side of the fracture line and a tear in the mucous membrane.

Fractures of the ramus can be best felt through the mouth, by inserting two fingers of one hand far back into the mouth toward the ramus and manipulating the jaw between the fingers of this hand and those of the other placed on the outer side of the ramus. In some cases there is considerable deformity, due to the fact that the masseter muscle pulls the lower fragment upward, so that the fracture line in the ramus can be distinctly felt through the cheek from the outside. Fractures of the ramus are usually accompanied by considerable difficulty in chewing.

FIG. 43.—METHOD OF GRASPING JAW (LOWER), IN ORDER TO DETERMINE FRACTURES OF THE LOWER JAW.

The thumbs of both hands are placed inside of the mouth on either side of the fracture line, the remaining fingers being placed on the lower border externally, the two fragments are then moved against each other in upward and downward directions alternately.

In fractures of the body of the bone, involving the inferior dental canal, neuralgic pains or anesthesia are often present, or there is a reflex lockjaw as a result of stimulation of the inferior dental nerve.

Fractures of the coronoid process of the lower jaw are extremely rare. Fractures of the neck of the condyle show a depression in front of the external meatus, and on palpation the condyle is not felt to follow the movements of the jaw. The chin is displaced toward the side of the injury, because the lower fragment is pulled upward and inward.

DISLOCATION OF THE JAW.

These are usually bilateral. The characteristic position of the mouth is well shown in Fig. 45. The lower jaw projects in front of the upper. The mouth is open. There is a depression in front of the ear, corresponding to the glenoid cavity, and the condyle can be felt just below the zygoma. There is great difficulty in deglutition, and the masseter and temporal muscles are very tense.

In unilateral dislocations all of these signs are less marked, the chin

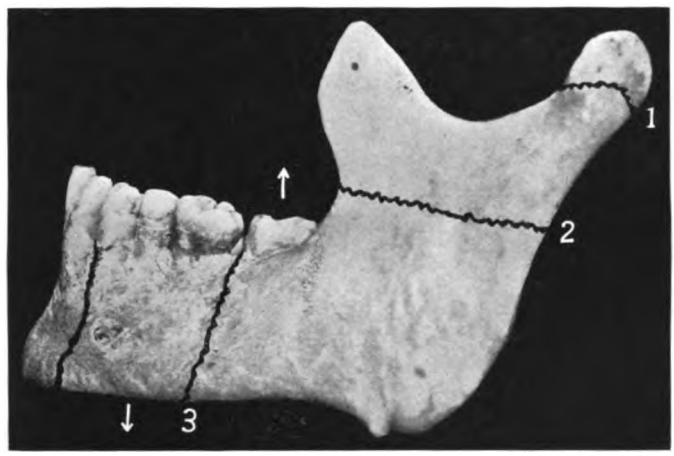

FIG. 44.—LOCATION OF MOST FREQUENT FRACTURE LINES OF VARIOUS PORTIONS OF THE JAW.

1, Fracture of condyloid process extending into temporo-maxillary joint; 2, fracture of ramus of jaw; 3, fracture close to junction of ramus and body. The white arrow to the right of 3 shows the direction in which the masseter muscle pulls the proximal fragment upward, and the arrow to the left of the 3 shows the direction in which the muscles attached to the lower jaw close to the median line pull it downward.

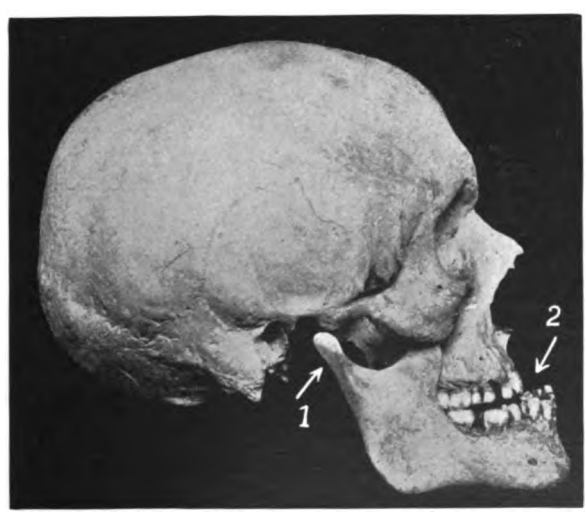

FIG. 45.—FORWARD DISLOCATION OF JAW.

1, Condyle resting upon, or in front of articular eminence; 2, note forward displacement of teeth of lower jaw.

is pushed over to the non-dislocated side, and the above signs are present only on one side of the face.

DISEASES OF THE SOFT PARTS OF THE FACE.

INFECTIONS.

Erysipelas constitutes the most frequent form of infection of the soft parts of the face with which the surgeon has to deal. It follows eczema and fissures of the mouth, nose, or ears. It may begin as an erysipelatous angina or sore throat and later spread to the face. The primary pharyngeal cases are extremely serious and are not infrequently followed by meningitis.

FIG. 46.—SWELLING OF THE FACE IN ERYSIPELAS.

In this case the swelling over the eyelids and edema and tenderness over the frontal sinuses were so marked as to simulate a bilateral sinusitis.

The diagnosis of facial erysipelas does not differ from that of the same disease in other parts of the body. The chief characteristic is the bright, glistening redness, which causes the skin of the face to be glazed and shining. There is distinct swelling over the erysipelatous area. If the finger is passed from the neighboring healthy skin across the boundary line, one can notice a distinct elevation of the skin. One can also feel the tense infiltration of the skin. The fact that the swelling scarcely pits on pressure, and that the redness cannot be caused to disappear quite as rapidly on pressure as in the case of the redness due to an ordinary phlegmon or infection of the subcutaneous tissue serves to distinguish erysipelas from a phlegmon.

The border line of the erysipelatous area is especially to be observed where a question arises as to whether erysipelas or an ordinary phlegmonous inflammation is present. This border line shows distinct demarcation from the healthy skin. It shows outrunners or pro-

jections along its entire length, giving it a jagged or irregular appearance.

In cases of phlegmon, this border line does not exist, and there is a gradual shading off of the redness of the skin into the surrounding area.

In phlegmonous inflammation the redness is also of a darker reddish-blue tint, and the induration is more marked owing to the involvement of the deeper tissues.

In erysipelas of the face, as of the head, the presence of numerous blisters or bullæ often assists in making the diagnosis.

If the erysipelas involves the upper portion of the face it may cause intense swelling of the eyelids (Fig. 46). The illustration referred to was taken from a case of facial erysipelas, with meningeal involvement and great tenderness over both frontal sinuses, so that the question arose, as it frequently does, of whether an empyema of both frontal sinuses might be present with secondary infection of the skin. A frontal sinus empyema can be differentiated by the fact that the swelling of the upper lid is usually greater than that of the lower; there is more local tenderness and the temperature as a rule is higher than it is in erysipelas. The pulse is also slow as compared with other septic infections.

A furuncle of the nose or of the upper lip may give rise to a confusion in diagnosis, since the redness and infiltration greatly resemble, in the earlier stages, that of the ordinary facial erysipelas. A furuncle can be readily differentiated from erysipelas by a careful search for a suppurating point, either on the inside or the outside of the nose, or upon the upper lip. In a furuncle of the upper lip the infiltration is usually board-like and brawny, and there is always considerable involvement of the entire thickness of the lip, with edema of the mucosa beneath it.

In the case of furuncles of the nose, especially those of the inner aspect, the diagnosis is much more difficult. It may be made (*a*) from observation of the course of the case; (*b*) from the fact that the redness does not spread as rapidly as in erysipelas, and also by observing the peculiar glistening redness of erysipelas and the sharply marked irregular borders just described.

Malignant pustule upon the nose, due to anthrax, may rarely give rise to confusion. This is also, as is the case with furuncles, readily to be differentiated, by the fact that palpation shows that the swelling of anthrax is very firm, and that there is a central, depressed scar. A bacteriological examination of the pus will readily serve to distinguish the anthrax infiltration from an erysipelas.

When erysipelas is complicated by meningitis there is accompanying delirium, the pulse and temperature both rise, and there are the other symptoms of infective meningitis referred to on page 56.

Furuncles of the Face.—There is usually no difficulty in making a diagnosis of a furuncle of the face, owing to the fact that the soft parts around the original atrium of infection are densely infiltrated and the swelling is board-like in consistency.

In furuncles of the side of the nose there is often quite marked edema of the eyelids and adjacent portions of the cheek. In furuncles of the upper lip the swelling is at times enormous, and the diagnosis may be readily made from the location of the swelling and the detection of a pus focus. In the later stages there is distinct fluctuation present.

FIG. 47.—SWELLING OF LIP IN A CASE OF FURUNCLE OF THE LOWER LIP.

The black area along the lower edge of the vermilion surface indicates the purulent focus.

The onset of complications of furuncles of the face, especially of the upper lip, such as a thrombophlebitis of the facial vein, resulting in a thrombosis of the cavernous sinus, may be suspected when the veins become markedly dilated toward the inner angle of the eye or root of the nose, accompanied by swelling. This is soon followed by the ordinary signs of thrombosis of the cavernous sinus, both local and constitutional, referred to on page 85 (see Fig. 25).

Meningitis as a complication of furuncles, and other forms of infection caused by the ordinary pyogenic organisms in the face, may be suspected by the persistence of fever, increase of pulse-rate, delirium, stupor, and other symptoms of an infective meningitis.

Extensive phlegmons of the soft parts of the face, extending down to the neck, may occur secondary to periosteal abscesses due to carious teeth, or rarely after a suppuration of the lymph-nodes situated within the substance of the cheek. The diagnosis can be made from the extensive swelling and other signs of deep-seated infection, such as high temperature and pulse-rate, local redness, etc. In every such case the mouth should be inspected at once, as this is the source in the majority.

In phlegmons of the deeper structures of the face there may be thrombophlebitis of the pterygoid veins (Fig. 25), which may spread to the cavernous sinus, causing infective thrombosis of this structure, with all of the characteristic signs of this condition.

Infection of the soft parts of the face may spread to the interior of the orbit, and the question may at times arise as to whether a thrombosis of the cavernous sinus is present, or an orbital phlegmon. In the latter disease, there is less dilatation of the supraorbital, angular, and frontal veins. The headache is supraorbital, rather than deep-seated. In both conditions the exophthalmos and swelling of the lid and conjunctiva are quite marked. There is choked disc or optic neuritis in a sinus thrombosis.

In orbital phlegmon, on the other hand, the changes in the fundus are but little marked.

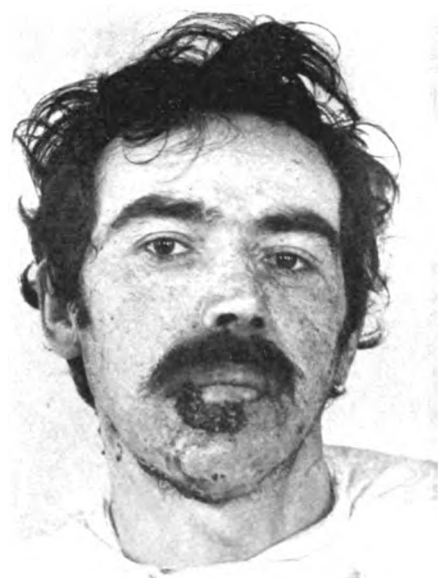

FIG. 48.—BLASTOMYCOTIC DISEASE OF THE SKIN OF THE FACE.
Observe the typical wart-like elevations.

Noma.—The diagnosis of noma may be made from the fact that it accompanies either the infectious diseases, such as measles, scarlet fever and typhoid, or marantic conditions in adults or children. It begins on the mucosa of the cheek or lip as a vesicle, but is soon followed by a black slough, whose situation is usually on the inner side of the cheek and extends through the entire thickness of this part of the face. It is complicated by severe septic disturbances, about 70 per cent. of the cases dying of sepsis. There is usually no difficulty in diagnosis, when one considers the accompanying diseases or conditions and the characteristic sloughing and septic symptoms.

Lupus.—Lupus vulgaris exists more frequently on the face than in any other part of the body. It involves especially the nose, the lips and the

cheeks, and is irregularly scattered over these parts. It destroys the tip and wings of the nose, and through its cicatrization may produce ectropion.

The diagnosis may be made from the presence of raspberry-red, pinhead-size nodules situated just beneath the epidermis. At times it is followed by carcinoma, which may be suspected when a papillomatous change takes place in the lupus area, with gradual extension of induration (Fig. 49).

Syphilis.—This rarely appears as a primary form, except upon the lips (page 105). The chief form of surgical interest is the tertiary or gummatous ulceration which may be mistaken for a beginning epithelioma of the face. It appears in the form of round and serpiginous ulcerations, not infrequently multiple, which are situated upon the cheeks, especially at the junction of the nose and cheeks.

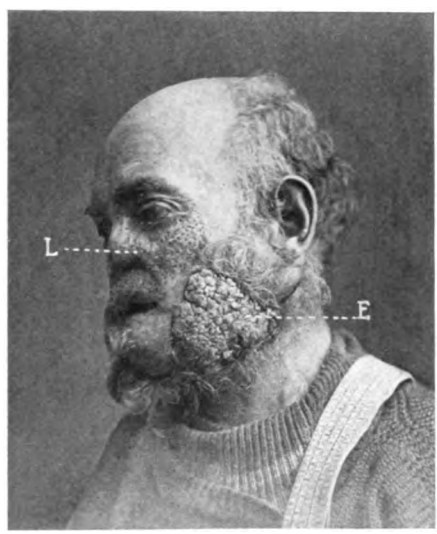

FIG. 49.—EPITHELIOMA OF THE FACE DEVELOPING ON LUPUS VULGARIS.

Observe how the alæ nasi have been destroyed by the long-existing lupus: *L*, Lupus nodules; *E*, cauliflower-like epithelioma.

A diagnosis can be made from the history of a preceding syphilitic infection, by an examination of the remainder of the body, and from the characteristic appearance of the broken-down gummata themselves. The outline of the ulcers is often serpiginous or round, the borders are not elevated, as in the case of a carcinoma, the induration is moderate, and not to be compared with that of the ordinary form of epithelioma. The edges are quite steep, as if cut out with a die, and the floor of the ulcer is covered with flabby granulations and necrotic, sloughing masses. There is usually but little, if any, enlargement of the cervical lymph-nodes. Tertiary syphilitic ulcers are also frequent upon the forehead, where they are associated with necrosis of the frontal bone (Fig. 30).

A differentiation from the slow-growing form of epithelioma, also called rodent ulcer, may be made by the fact that this latter process shows but little induration of the edges or tendency to ulceration in the earlier stages. Its course is very chronic, so that the breaking down of

tissue progresses very slowly, one portion showing cicatrization while another shows ulceration, and there is an absence of a history of primary syphilitic infection.

Actinomycosis of the Face.—This usually causes one of two conditions, (*a*) soft nodules, which fluctuate distinctly and sooner or later break down, giving rise to sinuses from which a brownish pus is discharged, and containing actinomyces. These latter organisms can be recognized by the naked eye as fine, yellowish granules.

(*b*) If the disease is more extensive it causes an infiltration of the deeper tissues of the face, especially of the masseter muscle, giving rise to a board-like hardness, resembling a sarcoma until softening occurs.

FIG. 50.—FRONT VIEW OF SADDLE-NOSE DUE TO TERTIARY SYPHILIS.

Note that the falling-in has taken place at the lower end of the quadrilateral nasal cartilages, owing to destruction of the cartilaginous septum nasi.

FIG. 51.—SIDE VIEW OF SADDLE-NOSE CAUSED BY TERTIARY SYPHILIS.

Note the beginning of depression at the level of the lower portion of quadrilateral nasal cartilages.

Actinomycosis should be thought of whenever abscesses recur in the face from time to time, and there is an absence of suspicion of tuberculosis. One should never neglect, under these circumstances, especially if there is the history of a recurring dental abscess, to search for the actinomyces.

The question may arise of making a differential diagnosis between actinomycosis and syphilis. In actinomycosis there are pockets of pus, or undermined ulcers, filled with flabby granulations and surrounded by smaller or larger abscesses. Syphilis can be differentiated by not finding the organisms of actinomycosis and by the sloughing condition

of the floors of its ulcers. The edges of the latter are quite steep and sharply cut.

Symmetrical Disease of the Lachrymal and Salivary Glands.—This disease, which was first called "Mikulicz's disease," consists in an infiltration of the connective tissue of the lachrymal and salivary glands on both sides of the face with lymphoid cells. The tumors are quite firm, there are no inflammatory symptoms, and the diagnosis can be made from the symmetrical enlargement of the lachrymal, parotid, and submaxillary glands.

It belongs to the class of infectious diseases, and bears some relation to the leukemic processes.

FIG. 52.—NASAL DEFORMITY DUE TO SYPHILIS.

In this case the cartilaginous and bony septum was completely destroyed, allowing the nose to fall in, and the two nostrils to become fused into one opening. There is scarcely any trace of the alæ nasi.

NEOPLASMS OF THE FACE.

BENIGN TUMORS OF THE SKIN OF THE FACE.

Angiomata.—The most frequent benign form is the capillary nevus, which may show itself as one or more small, raspberry-red, slightly elevated soft areas. It may involve an entire half of the face. It may combine with a second form of vascular tumor, in which the veins are involved, the so-called venous form of angioma, or this latter form may exist alone. It they are combined, the diagnosis may be made from the fact that the swelling is much greater than would exist in the case of an ordinary nevus involving only the capillaries; that the whole mass can be caused to disappear on pressure, but returns readily to its original size (Fig. 53). It increases in size when the child cries.

If the venous form exists alone, the tumors are quite soft, the skin over them is bluish in color, and the entire tumor can be caused to disappear upon pressure, but recurs as soon as the pressure is relieved. They are often associated with lipomata, especially in the parotid region, and this combination should be suspected when the tumors are

much larger than could be accounted for by the presence of a venous angioma alone.

Angiomata involving the arteries (cirsoid aneurysm) occur in the frontal and occipital regions. Their characteristics were referred to in the description of the same condition in the temporal region of the scalp (page 68).

Traumatic aneurysms are quite rare in the face and show the same signs as elsewhere.

Sebaceous cysts are not as frequent in the face as in the scalp and show some differences. They are usually adherent to the skin, are rounded, cause less elevation of the skin overlying it, are less firm, and show more fluctuation than is the case in similar tumors of the scalp.

FIG. 53.—ANGIOMA OF THE PAROTID REGION.

Lipomata.—These occur in the forehead or deeply in the tissues of the cheek. In the latter position they may be of slow development and must be differentiated from chronic tubercular abscesses and cystic tumors. This can be done by the fact that they are much more apt to be lobulated in structure and the fluctuation is very indistinct.

Dermoid Cysts.—These are found in the outer fourth of the upper eyelid, less frequently at the inner canthus or at the root of the nose. They can be readily distinguished from sebaceous cysts by the fact that they are not adherent to the skin, are usually immovable upon the skull, and by their characteristic location. Their differentiation from meningocele was considered on page 67, in connection with the latter form of swelling.

Fibroma molluscum occurs on the face usually in connection with the same condition elsewhere.

Adenomata of the sweat and sebaceous glands occur especially around the sides of the nose, as soft, flat tumors, which may become

pedunculated and bleed readily. They occur above middle age and are much softer and slower in their growth than epitheliomata.

Lymphangiomata usually occur in the cavernous form in the cheeks. They may form enormous tumors, which penetrate the entire thickness of the cheek and hang down as soft masses almost to the middle of the neck. They occur most frequently in children and may be differentiated from the venous forms of angioma by the absence of the peculiar bluish color of the skin, and the fact that the hemangiomata seldom reach the size of the lymphangiomata (Figs. 54 and 55).

Malignant Tumors of the Skin of the Face.—These include carcinomata and sarcomata. *Carcinoma* appears as a primary form,

FIG. 54.—ANTERIOR VIEW OF CASE OF LYMPHANGIOMA OF THE CHEEK.

FIG. 55.—SIDE VIEW OF LYMPHANGIOMA OF CHEEK. SAME CASE SHOWN IN FIG. 54.

either as a rodent ulcer or as the ordinary type of epithelioma. The characteristics of the rodent ulcers are that it first forms a crust and then a flat ulcer, which cicatrizes here and there. Its growth as a rule is very slow, but at times it may take on a more malignant form and cause extensive ulceration, destroying all the tissues in its path (Fig. 56). In its earlier stages, when it exists as a flat ulceration, it must be differentiated from the flat, ulcerating forms of lupus. This can be readily done by the fact that the ulcers of lupus usually show undermined edges, and there are evidences of lupus elsewhere on the face. From syphilis it can be distinguished by the fact that the edges of a syphilitic ulcer are quite sharp or steep, there is more sloughing, and there is either the history or the presence of syphilis elsewhere.

Ordinary *epithelioma* appears comparatively rarely on any other part of the face except the lips (Fig. 57), and this will be considered later. As a secondary form it may be the result of the extension of carcinomata from the jaws or interior of the mouth.

Sarcoma appears chiefly as the pigmented variety or melanosarcoma, arising from the pigmented moles which are so frequently present in the face.

FIG. 56.—EXTENSIVE DESTRUCTION OF FACE IN CASE OF EPITHELIOMA, EXPOSING LEFT SIDE OF BONE, ETC.
T, Middle turbinated bone.

TRIGEMINAL NEURALGIA.

The diagnosis of this disease can be made from the history of constant or recurrent pains in a portion of, or over the entire area of distribution of the trigeminal nerve. The pains are lightning-like, beginning after the least irritation. At first the intervals are of considerable duration, but later these become shorter, until the pains are almost continuous. The diagnosis may be made from the fact that the pains occur at first along one filament, and later along all of the branches of the trigeminal nerve. In addition, there is usually pain on pressure over the points of exit of the three principal branches of the nerve, supraorbital, infraorbi-

FIG. 57.—EPITHELIOMA OF SKIN OF FACE JUST BELOW AND INVOLVING LOWER EYELID.

tal, and mental. This can be elicited by moderate pressure over the nerves at their points of exit (Fig. 4).

FIG. 58.—DOUBLE HARELIP AND CLEFT PALATE IN NEWBORN CHILD.
Associated with microcephaly and supernumerary digits. Note the protruding intermaxillary bone and the skin covering it.

FIG. 59.—CONGENITAL SUPERNUMERARY DIGIT ON EACH HAND IN A NEWBORN BABE.
This child also had six toes on one foot, and a double harelip and cleft palate, as shown in Fig. 58.

In searching for a cause, one should consider whether the disease is of peripheral or central origin. If of peripheral origin there is usually the history of the disease having begun in one branch of the nerve and later involved the other branches.

One must search for peripheral causes, such as carious teeth, diseases of the jaw bones, tumors, chronic empyema of the frontal sinus or antrum, fractures and various constitutional causes, such as chlorosis, toxemia from malaria, or syphilis.

Among the central causes may be mentioned cerebral syphilis, aneurysm of the internal carotid artery, and tumors of the brain.

If both central and peripheral causes are eliminated, the disease is in all probability a reflex one.

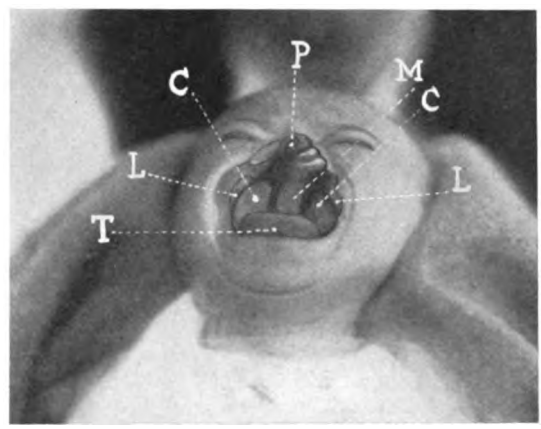

FIG. 60.—DOUBLE CLEFT PALATE AND HARELIP.

View of interior of mouth: *P*. Skin in median line covering the intermaxillary bone, the projecting portion of the latter being seen immediately below it; *M*, intermaxillary bone; *C*, *C*, palatal processes of the right and left superior maxillæ respectively; the black space between *C* and *M* on each side of the median line represents the cleft in the palate; *L*. *L*, right and left lips respectively. Note the cleft between these rudimentary lips and the central portion of the lip (*P*), covering the intermaxillary bone. *T*, Tongue. This photograph was taken while the child was crying.

DISEASES OF THE MOUTH AND PALATE.

Malformations of the Lips.—The most common congenital malformation of the lip is harelip. The diagnosis of this is easy (Fig. 58). It may involve simply the vermilion or red border of the lip, or extend through the entire thickness of the lip, either on one or both sides of the median line. If unilateral it is usually found on the left side. It causes a widening of the nostril of the corresponding side. If bilateral, there is associated with it the most frequent congenital malformation of the palate, viz., cleft palate (Figs. 58 and 60). In such cases the intermaxillary bone separates the double cleft in the palate and may project between the two clefts in the lips, being covered by a flap of skin, which is continuous with that of the median line of the nose. In many cases the intermaxillary bone is markedly prominent.

Acquired malformations of the lips most frequently follow extensive

burns or operations. In many cases the opening of the buccal cavity is very narrow, giving rise to a condition known as microstomia.

THE LIPS.

The most frequent conditions calling for diagnosis in the lips are herpes, enlargement of the lips (macrolabia), and ulcerations of the lip, due to syphilis, carcinoma, benign and malignant warts, or papillomata.

In regard to **herpes,** the chief point of interest is the fact that it usually occurs at the angle of the mouth, consisting of a group of vesicles which are often symmetrically situated on both lips. When ulcerated, that is, when the vesicles burst, they may be mistaken for either primary or secondary syphilis. This will be referred to below.

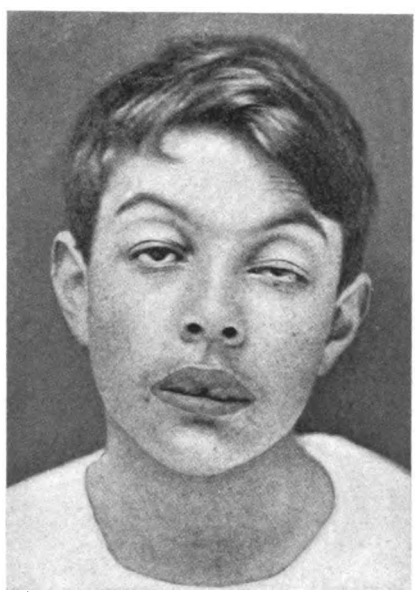

FIG. 61.—ENLARGEMENT OF THE LIPS DUE TO ADENOMATA OF THE MUCOUS GLANDS (MACROLABIA).

The enlargement is most marked in the upper lip on either side of the depression seen in the median line. In addition, this patient had a double ptosis.

Macrolabia may be due to one of three conditions: (*a*) In tuberculous children the lip is often greatly thickened and is accompanied by more or less inflammatory signs. The condition is a chronic one, growing slowly in size until the lip is greatly increased in thickness, and recurring from time to time. (*b*) In abnormal thickening of the lip due to lymphangioma, the lip is fairly firm, the enlargement is uniform, there is more or less connective tissue formation, and the enlargement involves the entire thickness of the lip. (*c*) A third form of macrolabia is that due to a primary adenoma of the mucous glands of the lip. The lip is soft, the enlargement is most marked in the upper lip (Fig. 61), and often one can feel a series of shot-like nodules through the stretched mucous membrane.

Both hemangioma and lymphangioma are usually congenital conditions or appear in early infancy. Tuberculosis of the upper respiratory tract is associated with evidences of the same disease

elsewhere, in the form of tubercular glands of the neck, etc. What was formerly called scrofulous thickening of the lip is rarely seen at the present day. Primary adenomatous thickening occurs after puberty. Ulcerations of the lip are usually due to either syphilis or carcinoma.

Syphilitic ulcerations are present either in the form of primary chancres or as broken-down gummata. In the case of chancres, one finds an ulcer with steep edges; there is marked induration around the edges, the floor is covered with a dirty slough or necrotic granulations, and

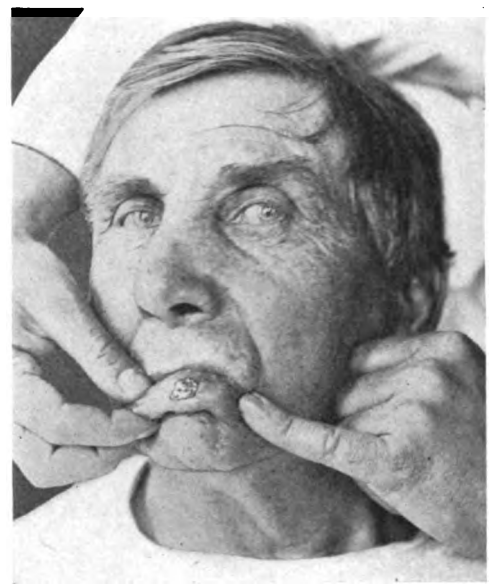

FIG. 62.—METHOD OF EVERTING LOWER LIP IN ORDER TO OBSERVE A CARCINOMA OF THE WARTY TYPE OF THE INNER ASPECT OF THE LIP.

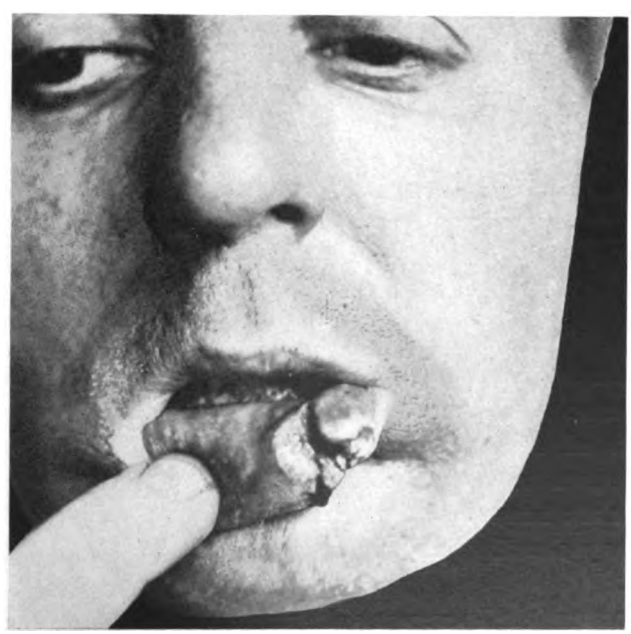

FIG. 63.—EPHITHELIOMA OF LIP IN A MAN OF THIRTY-TWO.
Showing extensive destruction on inner aspect. Lip has been artificially everted.

the process is usually quite limited, involving, however, almost the entire thickness of the lip at the vermilion border. It is accompanied by rapid enlargement of the submental and submaxillary lymph-nodes on the side of the lip upon which the chancre is situated. The induration is never as marked as in carcinoma. Chancre appears, as a rule, in younger persons, and the further observation of the case with the appearance of secondary symptoms will soon clear up the diagnosis. It may be stated that the enlargement of the lymph-nodes in chancre of the lip

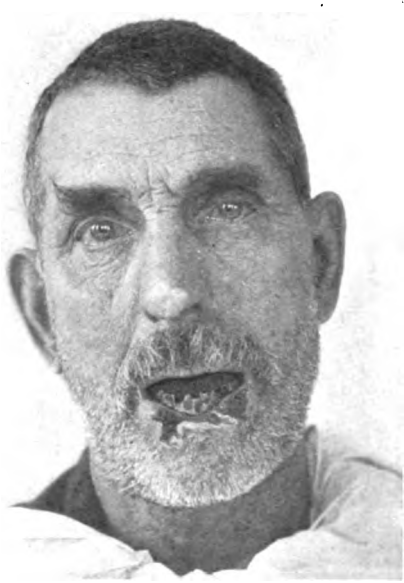

FIG. 64.—EXTENSIVE DESTRUCTION OF LOWER LIP CAUSED BY EPITHELIOMA, IN A PATIENT SIXTY YEARS OF AGE.

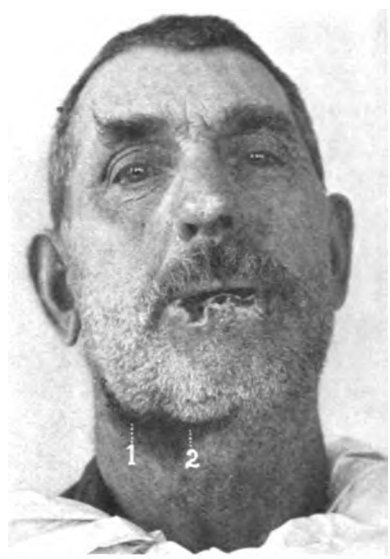

FIG. 65.—EPITHELIOMA OF LOWER LIP; SAME PATIENT AS SHOWN IN FIG. 64.

This illustration shows the most frequent localization of the regional lymphatic infection, namely, in the submaxillary (1) and submental (2) lymph-nodes.

is far greater, as a rule, than in carcinoma, with which it may be confused in some cases, but the lymph-nodes themselves are not as firm and indurated, but are softer in consistency. The question may at times arise as to whether an ulcer of the lip is due to the ulceration of the vesicles of a herpes labialis. In the latter case there is no induration, and recovery should occur within one to two weeks under ordinary treatment.

Gummata of the lip appear quite rarely, but must be borne in mind in considering the differential diagnosis of carcinoma of the lip. Gum-

mata are not accompanied by any enlargement of the lymph-nodes and are painless. The infiltration often involves the entire lip, although the ulceration may be quite localized. There is not the marked induration which is characteristic of carcinoma, and a week of administration of the iodid of potassium in moderate or large doses will soon clear up any doubts in diagnosis.

Epithelioma of the lip may appear in a number of different forms—first, as a wart (Fig. 63), whose base becomes indurated, the papillom-

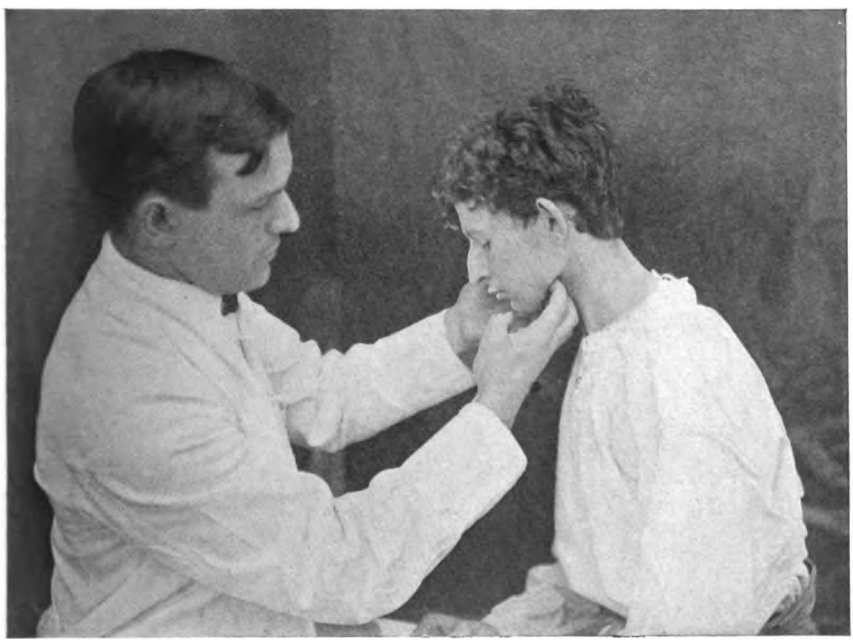

FIG. 66.—METHOD OF EXAMINATION IN ORDER TO DETERMINE ENLARGEMENT OF THE SUBMAXILLARY OR SUBMENTAL LYMPH-NODES.

The examiner should stand in front of the patient, or both may be seated face to face. The patient should be instructed to relax the muscles which pass from the lower jaw to the hyoid bone by flexing the head upon the neck while the finger-tips of the examining hand are inserted for a considerable distance further than if the head were extended.

atous surface rapidly enlarging, and the induration extending; second, it may appear as an ulcer which shows the following characteristic signs: it involves the entire thickness of the lip (Fig. 64); its edges and base are markedly indurated; there is no necrotic sloughing floor, as in a gumma or chancre. An examination of the submental and submaxillary lymph-nodes (Figs. 65 and 66) will show an enlargement of these nodes at a comparatively early period in carcinoma. In gummata there is no enlargement, while in chancres they are softer and larger.

Carcinoma of the lip almost invariably invades the lower lip and occurs most often in men; only 3 in 350 cases occurred in females.

DISEASES OF THE JAWS.

TUMORS.

The most frequent tumors which must be considered in making a diagnosis are:

BENIGN.		MALIGNANT.	
Dentigerous cysts.		Sarcomata...	(*a*) True epulis.
Odontomata.			(*b*) Chondro- or osteosarcomata (myelogenous and periosteal).
Cystadenomata.			
Osteomata.			
Fibromata { Central. Periosteal.		Carcinomata.	(*a*) Arising from the gums.
Chondromata.			(*b*) Arising from the mucous membrane of the antrum of Highmore.
Granulomata or granulation-tissue tumors.			

The chief points of differential diagnosis between the different forms are shown on page 109.

BENIGN TUMORS OF THE JAWS.

Dentigerous Cysts.—The appearance of a semifluctuating unilateral tumor on the outer side of the upper or lower jaw of a child between seven and ten years, should lead to the suspicion of a dentigerous cyst. They develop in connection with the eruption of the permanent teeth, and contain either a rudimentary or fully developed permanent tooth. The outer surface feels like a freshly broken egg shell, giving a peculiar crackling sensation, and the contents of the cyst is a clear mucoid fluid. In the lower jaw they protrude externally, while in the upper they may bulge into the antrum. At times they appear in children as a recurrent dental abscess which does not heal until the sac is extirpated and the permanent tooth removed. Under these conditions they may even penetrate the cheek like ordinary dental abscesses of the upper jaw (Fig. 75). As a rule, they grow slowly, but may develop to the size of a walnut within a few days.

The diagnostic features are the age, development on outer side of jaw, semifluctuation, and egg-shell crackling.

They must be differentiated from the following:

(*a*) *Sarcoma.*—The growth is more rapid; they break through the bone shell early, and one feels the soft tumor mass, if of the soft variety. If of the chondro- or osteosarcomatous type, there is no difficulty in differentiation because these are much firmer than a dentigerous cyst.

(*b*) *Fibroma.*—The diagnosis from dentigerous cysts must be taken into consideration, both in central and periosteal fibromata. The latter are quite rare, and are much smaller and firmer than the cyst. Central fibromata cannot be diagnosed until the bone begins to be expanded (Fig. 68). The growth is quite slow, and, if there is only a shell of bone covering it, one does not get the semifluctuant sensation of a dentigerous cyst, the tumor feeling much firmer. In case of doubt an exploratory puncture and the absence of fluid can be demonstrated. Again, an *x*-ray picture will show a shadow corresponding to the tooth, lying in the sac, in the case of a dentigerous cyst.

Odontomata.—Odontomata are either soft or very hard. The soft forms are myxomatous, like jelly in consistency or firmer like fibrous tissue. The hard forms have

	Age.	Most Frequent Location.	Egg-shell Crackling.	Size.	Rate of Growth.	Lymph-node Involvment.	Consistency.
Dentigerous cyst.	Between 7 and 12.	More frequent in lower jaw.	Present.	Small.	Slow, rarely rapid.	None.	Semifluctuant.
Odontoma.	Same.	Both jaws.	None.	Small.	Slow.	None.	Usually hard.
Cystadenoma.	Between 16 and 35.	Lower jaw.	None.	Large.	Slow and progressive.	None.	Firm.
Osteoma.	Middle age.	Lower jaw.	None.		Slow.	None.	Very hard.
Granuloma.	Children.	Either jaw.	None.	Small.	Slow.	None.	Soft.
Fibroma.	Between 16 and 35.	Majority in lower.	Only in central form.	Small.	Slow.	None.	Firm.
Chondroma.	Young persons.	Quite rare, usually lower.	None.	Small.	Slow.	None.	Hard.
Sarcoma.	Young persons.	Both jaws.	Only in early stage.	Epulis small, others large.	Rapid.	None.	Soft, except osteosarcoma.
Carcinoma.	Between 40 and 60.	Upper jaw.	None.	Those of gums small.	Rapid.	Early.	Hard, early ulceration.

the consistency of the normal tooth. Both forms occur during the eruption of the permanent teeth, especially the third molar or wisdom teeth. The softer varieties may resemble a sarcoma but are much slower in growth and cause no pain. The harder forms are always found at the neck of the tooth and are irregular in outline.

Cystadenomata.—This form of new growth is analogous in structure to the multilocular cysts of the ovary. They arise from the epithelium-containing odontoblasts which cover the root of the tooth. This epithelium proliferates and forms a gland-like structure whose lumen dilates until a cyst is formed. These tumors occur between the ages of sixteen and thirty-five, especially in women. They are more frequent in the lower jaw than in the upper, in the proportion of one to thirty.

Their growth may be quite rapid and they cause parchment-like crepitation, also called egg-shell crackling, as they develop. They can be recognized by their rapid and massive growth, the parchment-like crackling, and the absence of tendency to ulceration or of enlargement of lymph-nodes.

They must be differentiated from dentigerous cysts, which are usually monocular and occur at an earlier age. The jaw also does not attain the size of cystadenomata. The same is true for the softer odontomata, the harder form not being difficult to differentiate. Sarcomata occur at a younger age, do not grow as rapidly, and, unless of the softer variety, are more bone-like.

Carcinoma rarely occurs in the lower jaw and appears later in life than either cystadenomata, odontomata, or dentigerous cysts.

Osteomata.—Osteomata occur most frequently in the lower jaw, although occasionally an osteoma will develop into the antrum of Highmore and give rise to symptoms of pressure upon the infraorbital nerve and gradual bulging of the anterior wall. They may grow also toward the orbital cavity or toward the nose. Both in the upper and lower jaws they can be recognized by their bony consistency and their slow growth. Occasionally osteomata having their origin in the wall of the antrum may be recognized by the *x*-ray, but otherwise the same may be said of this class of tumors as of all the tumors of the upper jaw which originate in the antrum, that they cannot be diagnosed until they grow beyond the walls and cause bulging of the same. One can, however, suspect their presence from the complaint of dull pain over the antrum and, in the case of sarcomata or carcinomata, of escape of blood and mucus from the nose, without the ordinary symptoms of an empyema. Osteomata of the lower jaw must be differentiated from osteosarcomata. If

periosteal, they can be readily recognized, sometimes growing to quite enormous size. Their growth, however, is exceedingly slow, and, even though they be central in origin, they rarely cause any atrophy of the overlying bone such as will give rise to egg-shell crackling.

Granulomata (granulation-tissue tumors).—These are soft masses of granulation-tissue which project beyond the level of the gum from the sockets in which carious teeth lie. They are oftenest found in children. The absence of an increase in size, their soft consistency, and their relation to a carious tooth will enable a differentiation from a fibroma or a true epulis to be made.

FIG. 67.—OSTEOMA. (International Text-Book of Surgery.)

Fibromata.—These may either have their origin in the periosteum or in the central portions of the jaw. The former are more frequent, only eleven cases having been reported of the latter. Both the central and periosteal forms occur between the ages of sixteen and thirty-five. The periosteal can be recognized clinically as a small, hard tumor, growing from the periosteum of the outer surface of the jaw, usually of the lower jaw. The central form cannot be recognized until it has grown to a sufficient size to have caused expansion of the bone overlying it. They occur almost exclusively in the lower jaw, and until there is a prominence over the bone (Fig. 68) the patient is not aware of its

presence unless exceptionally it presses upon the mental nerve. Parchment-like crackling, so frequently observed in the other forms of tumors

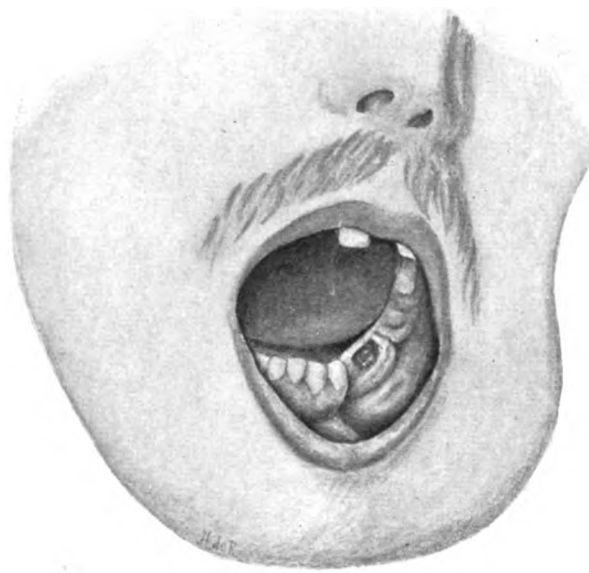

FIG. 68.—VIEW OF LOWER JAW IN A CASE OF CENTRAL FIBROMA.

of the jaw, is very rarely present, only once in eleven cases. As a rule, the cortex of the bone is intact. The chief conditions from which these tumors must be differentiated are in a periosteal fibromata, from a periosteal sarcomata. The consistency of the latter is softer, as a rule, and the growth is more rapid than in the case of a fibroma. The central fibromata, after they have caused sufficient expansion of the bone to be recognized, must be differentiated from the central form of sarcomata. As a rule, central fibromata do not grow as rapidly as the same form of sarcomata, nor do they give rise to egg-shell crackling sensations, or break through the shell of bone in their growth, as do the sarcomata. The periosteal form is also called false or fibrous epulis.

FIG. 69.—EPULIS (Edmund Owen).

There is a rare form of central actinomycosis which may resemble the central fibromata, but in these there is tendency to early softening and perforation of the bone with sinus formation, and the discharge of pus containing yellowish granules with the characteristic organisms.

Chondromata.—Chondromata seldom occur in the jaws as pure cartilage tumors. They are most frequently present in the form of chondrosarcomata or osteochondromata, which are allied to the sarcomata clinically. They occur as central chondromata in both the upper and lower jaws and as periosteal chondromata in both jaws, but especially in the upper. They form hard nodular tumors, which have the characteristic consistency of cartilage. The sensation on palpation can be compared to that felt on pressure over the nasal cartilages. Their growth varies greatly, that of the pure chondromata being very slow, so that the central form cannot be recognized until it breaks through the bone. The more they resemble the sarcomata in histologic structure, the more rapidly do they grow.

FIG. 70.—SARCOMA OF THE ANTRUM. (International Text-Book of Surgery.)

MALIGNANT TUMORS OF THE JAWS.

Sarcomata.—Sarcoma is the most frequent form of malignant tumor of the jaws. They may arise from the gums at the side of the tooth, giving rise to a soft, often pedunculated (Fig. 69) tumor, which must be differentiated from the ordinary fibrous form of epulis. In the case of the sarcomatous epulis, there is clinically the history of a rather rapid growth and expansion of the surrounding bone. Histologically, these tumors show distinctly the structures of a mixed giant- and spindle-celled sarcoma. The fibrous form of epulis is much firmer than the sarcomatous in consistency, and its growth is much slower. There is also but little tendency to cause expansion of the bone. Another variety of tumor must sometimes be differentiated. This is not a true tumor, but simply a mass of granulation-tissue which may arise in the

cavity from which either a tooth has been extracted or in which a carious tooth lies. It is composed of flabby, edematous granulations, and has a narrow pedicle, which can be traced up into the cavity occupied by the extracted or carious tooth. It is much softer than the sarcomatous epulis and can be readily recognized as composed of granulation-tissue. It can be differentiated from the sarcomatous epulis by the fact that the latter is firmer than this granuloma. Both the granuloma and sarcomatous epulis bleed easily. The history will also show that the sarcomatous epulis has grown more rapidly than the granulation-tissue tumor, spreading over several alveoli, and not being confined to a single alveolus, as is the case in a granuloma.



FIG. 71.—TYPICAL ENLARGEMENT OF THE FACE DUE TO TUMOR OF THE LOWER JAW (SARCOMA), EITHER OF THE RAMUS OR OF THE BODY, CLOSE TO THE JUNCTION OF THESE TWO PORTIONS OF THE INFERIOR MAXILLA.

The central sarcomata begin either in the body of the lower jaw or in the bone surrounding the antrum of Highmore in the upper jaw.

The diagnosis of such a sarcoma of the upper jaw of the endosteal or myelogenous type can only be made, as a rule, when the growth has caused expansion of the overlying bone. If the tendency of the growth is toward the nose, it has at times been treated for a polyp. Usually it grows toward the face, causes a prominence of the cheek, pushes the eyeball up, and, if toward the palate, causes a bulging in the latter (Fig. 70).

In the lower jaw these endosteal or central sarcomata cannot be recognized until the bone has been expanded by the growing tumor (Fig. 71). All types of sarcomata may occur, but most frequently one finds the osteosarcomata (Fig. 72).

The diagnosis of these forms of central sarcomata of the lower jaw may be made by the history of a rapid enlargement and the local examination. In the latter one finds an enlargement of the jaw, which is usually marked both on the side toward the mouth and that toward the cheek. In the softer varieties there is distinct egg-shell crackling. In

the harder forms, with more analogy to the osteosarcomata, the growth is quite firm and bone-like.

In the upper jaw, sarcomata must be differentiated from carcinomata arising from the antrum of Highmore. This cannot be done until the tumor has grown to a sufficient size to be palpated through the mouth. In the case of osteosarcomata or chondrosarcomata, palpation shows them to be much firmer than a carcinoma. Carcinomata tend to ulcerate upon breaking through the walls of the antrum much earlier than is the case with sarcomata.

In regard to age, carcinomata appear at a much later period of life than sarcomata. There is quite early involvement of the regional lymph-nodes (submaxillary and deep cervical) in a carcinoma.

Carcinoma of the upper jaw, as a rule, grows much more rapidly, and is more painful than is the case in sarcomata of the upper jaw.

From fibromata, both of the upper and lower jaw, sarcomata may be differentiated by their more rapid growth and the tendency to invade surrounding structures. The central fibromata of the lower jaw are quite localized, often encysted tumors, which is not the case with sarcomata. From the other forms of benign tumors of the jaws, like chondroma and osteoma, sarcomata may be readily differentiated by their rapid growth. It must be remembered that the pure form of chondroma is comparatively rare, the majority of these being chondrosarcomata.

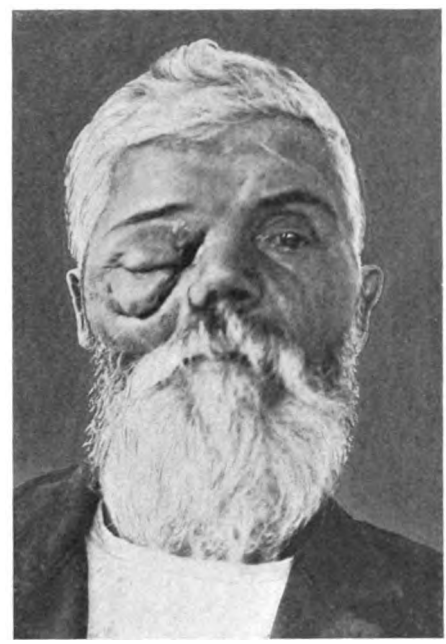

FIG. 72.—RECURRENT OSTEOSARCOMA OF THE SUPERIOR MAXILLA.

This illustration shows the typical site of tumors of the upper jaw which protrude externally, showing how they involve the surrounding osseous and soft structures. The curved line indicates incision of first operation.

Carcinoma of the Jaws.—These appear (*a*) either as primary tumors of the gums or growths arising from the mucosa of the antrum of Highmore, or (*b*) as secondary tumors by direct extension from neighboring carcinomatous involvement, either of the mouth or of the face (Fig. 73). The diagnosis of carcinoma arising from the mucous

membrane of the antrum can only be made, as was stated above, when the tumor is of sufficient size to grow toward the nose, face, or palate. They usually appear during the later years of life; their growth is quite rapid, much more so than is the case of sarcoma of the upper jaw, and there is greater tendency to ulceration. The most frequent form of carcinoma, however, is that which arises from the mucous membrane of the gums (Fig. 73) or palate, and of this variety those occurring in the upper jaw are more frequent. They almost invariably appear in elderly people in the form of a carcinomatous ulcer which is deeply excavated and has raised, everted, and markedly indurated edges. There is quite early enlargement of the submental, submaxillary, and deep cervical lymph-nodes (Fig. 74). The diagnosis in the earlier stages is not difficult when one considers that all other forms of ulceration which occur at this period of life are not accompanied by enlarged indurated lymph-nodes. Such ulcerations may occur in elderly people as the result of sharp teeth or of an ulcerative stomatitis, as the result of improper care of the mouth. In both of these the ulcers are quite superficial; the edges are seldom indur-

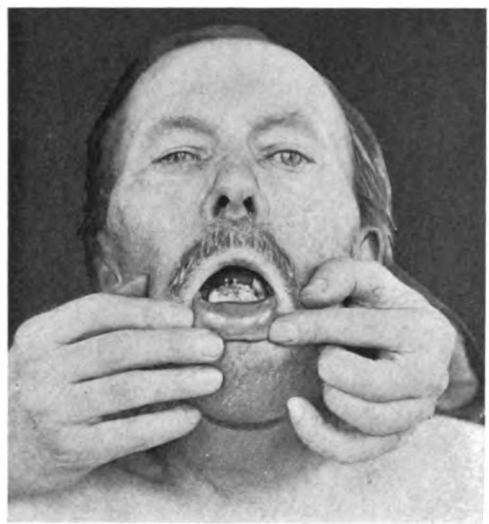

FIG. 73.—PRIMARY CARCINOMA OF GUMS OF LOWER JAW, WELL SHOWN BY EVERTING LOWER LIP.

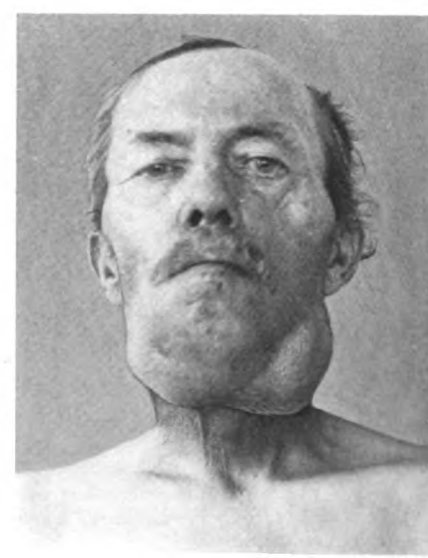

FIG. 74.—ENORMOUS SECONDARY CARCINOMATOUS LYMPH-NODES OF NECK, FOLLOWING PRIMARY CARCINOMA OF GUMS, SHOWN IN FIG. 73.

ated, and the ulceration rapidly disappears as soon as the cause is removed.

From tertiary gummata the carcinomatous ulcer can be differentiated by the fact that gummata seldom occur on the jaws except on the palate. There is usually a history of syphilis or the presence of syphilis elsewhere. No enlargement of the regional lymph-nodes occurs and the edges are never as indurated as is the case in a carcinomatous ulcer. The administration of potassium iodid will show a marked improvement if the ulcer is a gumma.

INFECTIONS OF THE JAWS.

In order to be able to recognize inflammatory processes of the jaws, it is necessary to have a clear conception of their pathology as well as of their clinical appearance.

It is important to determine (*a*) the nature of the process and (*b*) the extent of involvement of the bone.

The *nature* of the affection varies somewhat according to the cause. The most important of the latter are:

1. Infection from the teeth.
2. Infection following compound fractures.
3. Tuberculosis.
4. Syphilis.
5. Actinomycosis.
6. Phosphorus necrosis.
7. Acute pyogenic osteomyelitis.

The extent of the process varies according to the cause. In the majority of cases following tooth infection there is a suppurative periostitis with the formation of subperiosteal abscesses and resultant necrosis of the underlying bone. Such an abscess may form around the root of the tooth (Fig. 75) and remain confined to this location or it may extend to the extra-alveolar portion of the bone. Here its further course varies. In the upper jaw the pus may (*a*) burrow toward the antrum of Highmore (Fig. 75), or (*b*) penetrate the tissues of the cheek and perforate externally, or (*c*) it forms a subperiosteal abscess which causes a swelling at the line of reflection of the gum and mucosa of the cheek.

In the lower jaw the anatomic conditions differ. Here infective processes either form (*a*) an abscess within the alveolus itself around the root of the tooth, or (*b*) it causes a marked periostitis, usually on the outer aspect, or (*c*) the infection progresses to the floor of the mouth

and to the loose cellular tissue of the neck (Fig. 75) and, if not arrested, to the anterior mediastinum.

These various degrees of infection may result in necrosis of the bony structure of a single alveolus or of a number of them. In the lower jaw the above referred to periostitis of the outer aspect is either of a plastic nature which undergoes resolution or the infection causes a subperiosteal abscess with necrosis of a lamella or more of the cortex of the bone.

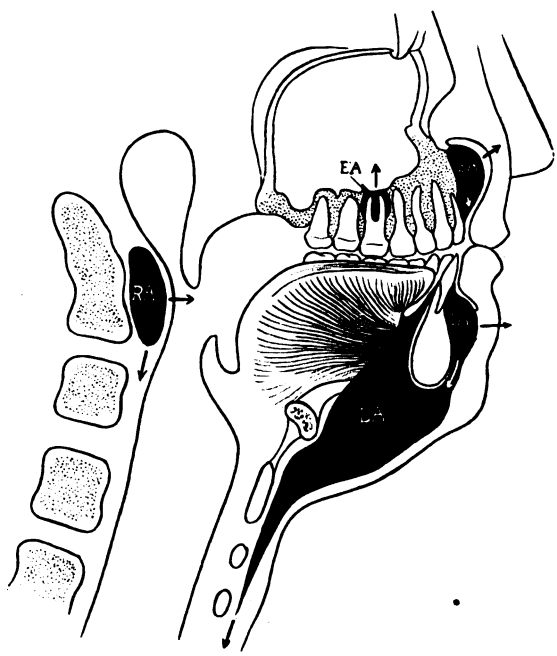

FIG. 75.—SAGITTAL SECTION OF HEAD TO SHOW SPREAD OF SUPPURATION FROM INFECTED TEETH; AND ALSO LOCATION OF RETROPHARYNGEAL ABSCESSES.

SA, Subperiosteal abscess of upper jaw opening toward cheek and mouth in direction of black and white arrows, respectively; *IA*, subperiosteal abscess of lower jaw opening toward submaxillary region and chin in direction of white and black arrows, respectively; *LA*, infection in submaxillary subcutaneous tissue as a result of abscesses arising from teeth and from floor of mouth (this condition is also called angina Ludovici); *EA*, infection around roots of bicuspid and molar teeth spreading toward antrum in direction of arrow; *RA*, retropharyngeal abscesses.

A true osteomyelitis, *i. e.*, an involvement of the medulla of the bone, is very rare after tooth infection.

In compound fractures, tuberculosis, syphilis, actinomycosis, and in infection following the acute exanthematous diseases the pathologic changes differ only in extent from those already described.

The chief diagnostic points of the various inflammatory processes are as follows:

Infection from Teeth.—Abscesses around the root of the teeth cause severe pain referred to the tooth, accompanied by tenderness on pressure, redness, and swelling of the gum. There is always more or less swelling and induration of the overlying skin, especially in the upper jaw, often causing marked edema of the lower eyelid and upper lip. If the infection migrates through the root canal it may penetrate the alveolus and give rise to an abscess beneath the gum (gum-boil), indicated by swelling and fluctuation here. If the underlying bone of the alveolar process is necrotic, the opening

from which the pus escaped either spontaneously or by incision continues to discharge. A fine probe passed through the opening encounters denuded dead bone. If the necrosis involves a number of adjacent alveolar processes there is more or less retraction of the gums, with constant discharge of pus. Upon inserting a probe the extent of the necrosis can be readily determined. In advanced cases the entire alveolus may be necrotic. The recognition of a form of infection which occurs with especial frequency in the lower jaw is the palpation of a swelling which is usually quite hard at first over the infected tooth. The further clinical history is like that described above.

In children spontaneous perforation through the cheek over both upper and lower jaws is frequent. A sinus is present externally along which a probe can be passed until exposed bone is encountered (Fig. 75).

In connection with the diagnosis of infection of the upper jaw from carious teeth it is well to call attention to the fact that an empyema of the antrum of Highmore, especially if acute, will cause irritation of the nerves of the bicuspids and first molar, so that these teeth are often thought to be diseased.

FIG. 76.—SUPPURATION OF THE SUBMAXILLARY LYMPH-NODES.

Infection of the surrounding cellular tissue of this region and of the cheek, the latter almost closing the eye, followed tooth infection.

Infection Following Compound Fractures.—Necrosis of the jaw is present in these cases when (*a*) a sinus is present, either within the mouth or externally, which leads to denuded bone at the seat of fracture; (*b*) if abscesses form after a fracture which heal and then fill up again until a piece of necrotic bone is either removed by operation or spontaneously discharged.

Tuberculosis of the jaws is quite rare. It is most frequently located at the junction of the superior maxilla and malar bone. It causes a swelling along the lower border of the orbit which has all of the clinical characters of a tuberculous or cold abscess. These are the gradual appearance of a swelling without pain, redness, or rise of local

or general temperature. The skin over it is bluish and, after evacuation of the pus has occurred, a sinus persists whose edges are lined by flabby, often caseous, granulations.

Tuberculosis also occurs in the alveolar and palatal processes and in the body of the lower jaw. The diagnosis in these locations can only be made by excluding the other forms of infection and the peculiarly slow onset.

Tuberculosis of the lower jaw may resemble sarcoma, syphilis, and actinomycosis. A sarcoma of the body of the lower jaw grows more rapidly; it is not accompanied by necrosis of the bone, but a gradual thinning of the same (page 114).

Syphilis is rare in the lower jaw and there are usually evidences of the disease elsewhere.

Actinomycosis is not apt to be accompanied by swelling of the lymph-nodes, as is the case in tuberculosis. The pus contains fine yellow granules in which the ray fungus is found.

Syphilis.—In the lower jaw it appears as a periostitis which causes either circumscribed or more diffuse swellings. The diagnosis can only be made if other causes of periostitis, especially those due to tooth infection, are excluded. There is usually, however, a history of syphilis elsewhere.

The hard palate is the most frequent localization of tertiary syphilis in the jaws. It causes a painless swelling which opens spontaneously, exposing denuded, often foul-smelling, bone. In other cases the patient may present himself for an opinion as to the nature of a perforation of the hard palate leading into the nose.

The alveolar processes of both jaws and of the nasal process of the upper jaw are also frequent seats of syphilis, especially of the type known as the late hereditary, which first appears in children at the age of puberty.

A diagnosis of the latter form can be made by a careful history, the absence of any other causes of necrosis, and antisyphilitic treatment.

Actinomycosis.—This inflammatory disease of the lower jaw occurs far more frequently than was formerly thought. It is almost invariably secondary to a primary infection of the gums or mucous membrane of the cheeks, which is rapidly followed by infection of the soft tissues of the face and neck, as described on page 118.

In the jaws actinomycosis may either appear as an accompaniment of the same affection in the soft parts or as an independent clinical entity. There are two forms, a peripheral and a central, both of which most frequently involve the lower jaw. The peripheral form of jaw actino-

mycosis either causes a superficial necrosis or abscesses, varying in size from a pea to a hazelnut, filled with soft granulations. In the pus from these latter cavities the actinomyces are found. These abscesses may first arouse the suspicion of the surgeon or dentist on account of the absence of acute inflammatory symptoms and the fact that they recur from time to time.

The central variety of actinomycosis of the lower jaw occurs in two forms—(*a*) a penetrating and (*b*) a tumor-like form. In the former there is marked rarefaction without the formation of sequestra, but considerable thickening of the outer layer of bone. This form is very virulent, especially when it affects the upper jaw. The tumor-like form is rarely met with in man, occurring usually in cattle as lumpy jaw. Its course is very slow and results in the formation of multiple cysts.

The diagnosis of actinomycosis of the jaws, as is the case elsewhere, can only be made if the characteristic organism is found. It bears great resemblance clinically to ordinary tooth infections, especially if associated with involvement of the cellular tissue of the neck. The course of actinomycosis is slower, it is more often accompanied by trismus (see page 122), and there is often a history of chewing hay, grain, etc., or of having been around infected cattle.

Phosphorus Necrosis.—Owing to the regulation of the manufacture of matches, this disease is practically extinct. It affects the lower jaw more often than the upper. The clinical picture is that of a suppurative periostitis, but the pus is very foul and necrosis is more extensive than is the case in ordinary tooth infection.

Acute Suppurative or Pyogenic Osteomyelitis.—This affection usually occurs in young persons, in the lower jaw. It may follow the acute exanthemata like measles, scarlatina, and variola, or occur simultaneously with acute osteomyelitis of other long bones. In other cases there is no apparent cause.

The diagnosis presents no difficulties. In the milder type the disease more frequently involves the upper jaw. There is gradually swelling of the face over the superior maxilla of one side or over the entire lower jaw with moderate fever. This is followed by necrosis of the entire alveolar process with the loss of the temporary teeth as well as the non-erupted permanent teeth.

In the more severe form the course is much more like that of the same disease in the extremities. It begins with a chill, followed by high fever and marked increase of pulse-rate. There is extensive swelling and redness of the soft parts over the jaw and severe septic symptoms.

DISEASES OF THE TEMPORO-MAXILLARY JOINT.

This articulation is subject to the same forms of inflammation as is the case in the joints of the extremities. These are:

Primary Acute Arthritis:

1. Acute traumatic arthritis (sprains).
2. Acute articular rheumatism.

Secondary Acute Arthritis:

1. Metastatic..(*a*) Through infection with ordinary pus cocci by metastasis from foci elsewhere in the body.
   (*b*) Through infection with gonococci, after scarlatina, typhoid, etc.
2. Direct.....Through extension into the joint from neighboring foci of suppuration.

Chronic Arthritis:

1. Tuberculosis.
2. Arthritis deformans.

Of the above, the acute inflammations are most often a result of acute articular rheumatism or a metastasis from a gonorrheal infection. The diagnosis is not difficult. There are redness, swelling, and pain over the joint, which latter is just in front of the tragus of the ear.

Pyemic inflammation is also not rare. The chronic forms are characterized by pain over the joint upon movements of the jaw, crepitation, and slight swelling. There are two forms of chronic inflammation of the joint which lead to relaxation of the ligaments and favor subluxation. One of these forms is the result of an arthritis deformans which usually accompanies the same disease in other joints. The movements of the jaw are accompanied by pain and crepitation and are very difficult.

Ankylosis of the Temporo-maxillary Joint.—Trismus (lockjaw) is the name given to inability to open the mouth. It may be congenital and acquired. The following forms exist of the latter: (*a*) A reflex spasm of the masseter muscles following acute inflammatory diseases of the jaws and occurring most frequently during the eruption of the wisdom-teeth—it has been given the name "symptomatic lockjaw"; (*b*) as the first symptom of tetanus (see page 540); (*c*) as a result of acute or chronic disease of the temporo-maxillary joint; (*d*) as a result of cicatrices in the tissues around the joint; (*e*) as a result of disease of the adjacent bones, especially after osteomyelitis of the condyle of the

lower jaw in children. It is very apt to follow acute gonorrheal arthritis and those varieties of suppurative arthritis which are due to metastasis or to direct extension from neighboring foci in the ear, mastoid, etc.

The diagnosis of the existence of an ankylosis is much easier than that of its cause. The cause of an acquired ankylosis can be ascertained through a careful history, an examination of the rest of the body and of the structures around the joint. A congenital ankylosis is frequently accompanied, or rather followed, by a lack of development of the lower jaw.[1]

DISEASES OF THE MOUTH.

Injuries.—Injuries of the lips and buccal cavity present no difficulties in diagnosis. It is of interest to note that wounds of the mouth are covered with a grayish-white deposit within twenty-four hours, which to those unaccustomed to see it causes them to think it at first sight to be the pseudo-membrane of diphtheria.

STOMATITIS.

There are two principal forms of inflammation of the buccal mucosa, viz., an ulcerative or catarrhal and gangrenous. In *gangrenous stomatitis* or *noma* there is a history of some recent infectious disease, such as measles, or the patient is quite cachectic. In its earliest stages there is a blister, usually on the inner side of the cheek, which soon becomes gangrenous. The area begins to spread along the mucosa and in the depth of the cheek, so that it penetrates the cheek. The gangrene is accompanied by a markedly fetid breath and the symptoms of general sepsis.

Ulcerative stomatitis is characterized by greatly swollen, reddened, readily bleeding gums, accompanied by salivation. Particles of food and detritus collect at the junction of the gums and teeth, and there is great fetor. Ulcers often appear on the inner side of the lips and cheeks and along the borders of the tongue. They are flat and could only be confused with mucous patches of secondary syphilis. The latter are, however, not accompanied by fetor, swollen bleeding gums, and salivation unless there is an accompanying mercurial stomatitis. Even then the distinction can be made by an examination of the remainder of the body for other evidences of syphilis, and the fact that the mucous patches are seldom ulcerated, are fewer in number, and seldom occur on the gums or inner side of the cheeks, but most often on the edges of the tongue.

[1] Orlow: "Deutsche Zeitschrift für Chirurgie," Bd. 60.

In scurvy the gums are swollen and bleed readily, and there are apt to be subperiosteal hemorrhages causing tenderness over the long bones and hemorrhages into the joints causing swelling of the latter.

SYPHILIS.

Tertiary syphilis in the form of ulcerating gummata occasionally affects the inner side of the cheek and may cause perforation. The favorite seat of perforations, however, is at the junction of the hard and soft palates, where it causes deep ulceration and perforation of the palate. Tertiary syphilis can be distinguished from carcinoma by the absence of enlarged lymph-nodes and the lack of induration in syphilis and the presence of evidences of the disease in its tertiary form elsewhere.

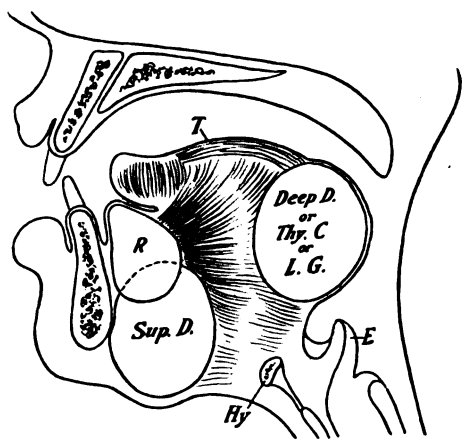

FIG. 77.—LOCATION OF VARIOUS CYSTS IN RELATION TO TONGUE AND FLOOR OF MOUTH.

R, Ranula; *Deep D. or Thy. C. or L. G.*, location of deep dermoids, of thyroglossal cysts and of lingual goiter at base of tongue; *Sup. D.*, location of superficial dermoids at floor of mouth causing bulging of submental region; *T*, dorsum of tongue; *Hy*, hyoid bone; *E* epiglottis.

THE DIAGNOSIS OF CONDITIONS AT THE FLOOR OF THE MOUTH.

A differential diagnosis must at times be made of conditions which occur at the floor of the mouth. These are (Fig. 77):

1. Inflammatory conditions:
   - (*a*) Angina Ludovici.
   - (*b*) Salivary calculus.
   - (*c*) Acute ranula.
2. Tumors:
   - (*a*) Of the submaxillary salivary gland.
   - (*b*) Chronic ranula.
   - (*c*) Dermoids.
   - (*d*) Thyroglossal cysts.
   - (*e*) Carcinoma of the floor of the mouth.
   - (*f*) Lipoma.

Angina Ludovici.—This occurs either as a complication of scar-

latina or of a tooth or tongue infection. It causes a tense brawny infiltration of the floor of the mouth, pushing the tongue upward and causing difficulty in swallowing, in speech, and in breathing. It is accompanied by the evidences of severe systemic infection (fever, leukocytosis, etc.) and the skin of the neck soon becomes infiltrated and of a dark red hue.

Salivary Calculus.—This may occur without inflammatory reaction or ulceration and is easy to feel when the finger is pressed along the floor of the mouth or a probe is passed along Wharton's duct. If the calculus be surrounded by connective tissue, it may be quite hard and resemble a carcinoma, especially if the tissues around the calculus be ulcerated and the ulcer be surrounded by exuberent granulations. A differential diagnosis can usually be made by the use of a probe passed through the buccal opening of Wharton's duct, on either side of the frenum of the tongue close to the floor of the mouth, and encountering the calculus.

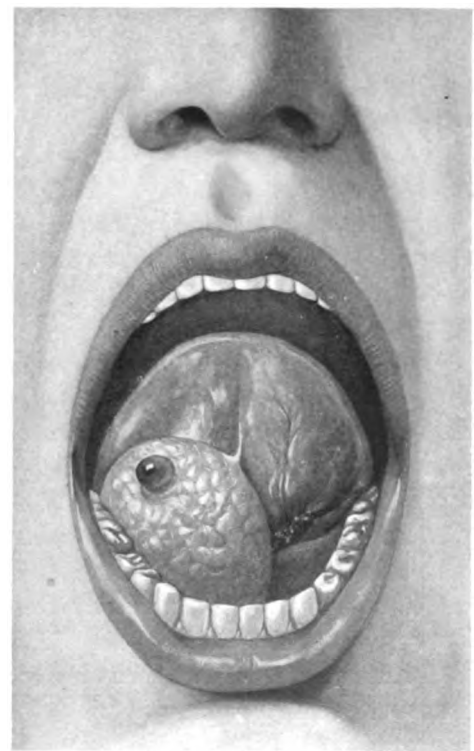

FIG. 78.—RANULA.
Note the prominent tumor on right side of floor of the mouth, pushing the tongue upward.

Acute Ranula.—The patient gives the characteristic history of recurrent swellings which appear very suddenly, especially while eating. The swelling is usually most marked just below the angle of the jaw and pushes up the floor of the mouth. It may attain the size of a fist and subside as rapidly as it appeared. It is due to the occlusion of Wharton's or the sublingual ducts, so that the saliva collects within the glands. The history is sufficiently typical to make a diagnosis even during the interval.

Solid Tumors of the Submaxillary Salivary Gland.—These are either chondromata or endotheliomata. They protrude below the jaw

(Fig. 116) and bulge in the floor of the mouth. A diagnosis can be readily made by the firm consistency of the tumor and the fact that its major portion lies in the normal position of the submaxillary salivary gland on the inner side of the jaw, close to the angle.

Chronic or Ordinary Ranula.—As a rule, this tumor is unilateral (Fig. 78). It pushes the tongue upward and appears as a translucent tumor varying in size from a pea to an egg in the floor of the mouth. It has its origin in the cystic dilatation of the sublingual gland and is a retention-cyst. Its fluid contents are like the white of an egg.

It can be differentiated from a lipoma of the floor of the mouth by the yellowish color, the lobulated structure, and firmer consistency of the lipoma.

From a dermoid of the sublingual variety (Fig. 77) it can be distinguished by the fact that a dermoid is doughy, is not translucent, has thicker walls, is attached to the lower jaw or hyoid, and lies deeper. A cystic dilatation of Wharton's duct or chronic ranula causes a cylindric translucent swelling and is accompanied by some enlargement of the submaxillary salivary gland.

Dermoid Cysts.—These occur at the floor of the mouth and have as their chief characteristic a doughy consistency, so that they pit on pressure. They are of a yellowish color, are softer than a calculus, and occur between the fifteenth and twenty-fifth year. They are situated deeper than a ranula (Fig. 77) and cause more bulging of the submental region.

Thyroglossal Cysts.—These are softer than dermoid cysts and push the tongue up and back, causing difficulty in speech, in swallowing, and in breathing. They appear externally between the hyoid and the lower jaw in the median line. Their deeper situation, absence of translucency, and the fact that they occur in the median line serves to distinguish them from a ranula.

Carcinoma of the Floor of the Mouth.—This condition may occur as a primary one and be situated in a fold of mucous membrane, so that attention is only called to its presence by pain. Upon lifting the tongue up, or pushing it to one side, one can detect an ulceration with dirty floor and indurated base and edges. The only condition likely to be confounded with it is a gumma. In the latter there are no enlarged submental or submaxillary lymph-nodes, the induration is less marked, and there is either the history of or presence of syphilis elsewhere. Carcinoma of the floor of the mouth due to extension from the tongue or gums presents no diagnostic difficulties.

Lipoma at the floor of the mouth is very rare.

TUMORS OF THE INSIDE OF THE CHEEKS.

The most frequent forms of neoplasms in this situation are the vascular tumors and carcinoma. The former have been referred to previously (see page 98) as invading at times the entire thickness of the cheek, so that they present the typical picture on the inner side.

An angioma may be primary in the buccal cavity, *i. e.*, on the inner side of the cheek, on the tongue or fauces.

The hemangiomata are usually of the venous type, so that one can see the typical soft bluish swelling disappear on pressure.

The lymphangiomata, if present, form a large, soft tumor of the entire cheek, congenital in origin, and growing at times to an enormous size.

Carcinoma of the inner side of the cheek is usually an extension from the jaws or lips. Only twelve cases of primary carcinoma of the cheek have been recorded. They occur close to the lower jaw and may penetrate the cheek. Their induration, raised, everted, hard edges, and tendency to early ulceration, with enlargement of the regional lymph-nodes, are so characteristic that the diagnosis is not difficult.

TUMORS OF THE PALATE.

The majority of these, if primary, are fibromata, and can be readily diagnosed from their position and consistency. They usually arise laterally and grow toward the median line. They are covered by periosteum and are slow in growth. They cause difficulty in swallowing and speech and must be distinguished from tumors of the upper jaw and from naso-pharyngeal polyps, which have grown toward the antrum. In the case of tumors of the jaw we have usually to deal with malignant growths which increase in size rapidly and also cause bulging of the anterior surface of the superior maxilla. In the case of naso-pharyngeal polyps an examination of the naso-pharynx will show the origin of the primary tumor. In addition, by palpation one can feel that there is a connection between the palatal vault and the pharyngeal tumor (Fig. 79).

THE TONGUE.

Congenital Affections.—The most important congenital affection is the ordinary *tongue-tie*, which is due to an abnormal shortness of the frenum linguæ. This can be recognized in infancy by inability to protrude the tongue as far forward as normal. The organ can seldom be

protruded further than the teeth. The condition may interfere with nursing and later with speech. The tongue is bound down to the floor of the mouth and the shortened frenum can be easily demonstrated by lifting the tongue up with a grooved director.

Injuries of the Tongue.—The most frequent injuries of the tongue are punctured or lacerated wounds. These are either due to foreign bodies, which penetrate the tongue during eating, or the wounds are received during a fall, the tongue being caught between the upper and lower teeth. At times the wounds are so extensive as to almost completely sever the tip of the tongue. Foreign bodies may be retained in the tongue and cause a circumscribed abscess, which can be recognized by a swelling which is usually unilateral, by tenderness, and by a sense of fluctuation.

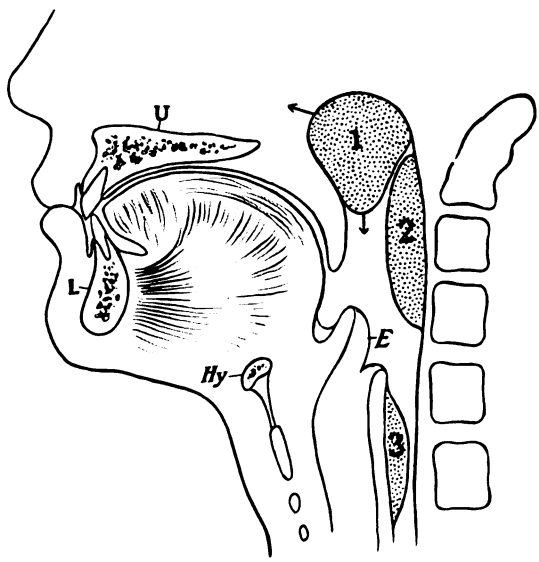

FIG. 79.—VARIOUS LOCATIONS OF PHARYNGEAL AND ESOPHAGEAL TUMORS.

U, Upper jaw; *L*, lower jaw; *Hy*, hyoid bone; *E*, epiglottis; 1, naso-pharyngeal growths; the arrows point in the direction of their most frequent extension toward the nose and pterygo-maxillary fossa and downward toward the mouth; 2, location of retropharyngeal growths; 3, location of carcinomata at the junction of anterior wall of pharynx and beginning of esophagus.

Dental or Decubital Ulcers.—These may follow the constant irritation of a sharp tooth and cause severe pain. Such dental ulcers are usually situated opposite the canine teeth, at the edges of the tongue, and cause considerable pain. The diagnosis can be made by finding the source of irritation and the fact that the ulcer heals rapidly when its cause is corrected. The differentiation of these decubital ulcers of the tongue from carcinomatous and syphilitic ulcers will be referred to again (see page 135).

Acute Parenchymatous Glossitis.—This may follow wounds of the tongue or may occur as a complication of the acute infectious diseases. This condition occasionally results in an abscess of the tongue or may be the starting-point of an infection of the cellular tissue of the floor of the mouth and neck called angina Ludovici.

Acute glossitis can be recognized by the enormous swelling of the tongue, which causes obstruction to breathing, with resultant dyspnea. The tongue cannot be moved, feels very firm and board-like, and there is profuse salivation and severe pain. The temperature as a rule is not high. Swallowing and the taking of nourishment is greatly interfered with. The mouth is usually held open and the entire clinical picture is that of great anxiety. On account of the inability to move the tongue there is also great danger of aspiration pneumonia. This condition of acute glossitis lasts from three to five days and may be complicated by an acute edema of the glottis. This complication can be diagnosed by the marked increase in dyspnea, cyanosis, and the stridor accompanying the inspiratory efforts. The only condition with which acute glossitis can be confused is an acute edema of the floor of the mouth due to inflammation around a salivary calculus. This latter condition is more localized and seldom extends to the tongue. It is always present on the floor of the mouth and by palpation one can usually demonstrate the presence of the calculus lying in Wharton's duct.

FIG. 80.—PSORIASIS LINGUÆ (Hutchinson).
Notice the silvery-white area characteristic of this disease.

Leukoma (leukoplakia, chronic glossitis or psoriasis linguæ).—This is a condition which is very frequent in smokers and is present on the inner side of the cheeks and lips, as well as upon the tongue. On the latter it presents itself in the form of milk-white patches of varying size. These patches of leukoplakia are distinctly white in color, especially on the dorsum (Fig. 80). On the edges and under surface of the tongue they have a little more bluish tint and are translucent. The disease may be so extensive as to cover the entire dorsum of the tongue.

The chief condition from which it must be differentiated is the

mucous patch occurring in secondary syphilis. The mucous patch is of a pure white or yellowish-white color and more opaque than the leukomatous or smokers' patches. There is a greater tendency on the part of the mucous patches to extend and there is usually evidence of syphilis elsewhere, such as a secondary eruption on the body or mucous patches at the angle of the mouth or on the tonsils. Whitish patches not infrequently appear on the edges of the tongue in patients who have had syphilis, which cannot be differentiated from ordinary leukoplakia, except from the history of a previous syphilis and their greater tendency to ulcerate.

Secondary mucous patches are most often found on the edge of the tongue, while leukoplakia appears usually on the dorsum of the tongue. In leukoplakia there is no enlargement of the submaxillary lymph-nodes, whereas the mucous patches are often accompanied by this condition.

Tuberculosis of the Tongue.—This is usually present as a condition secondary to tuberculosis of the larynx, tonsils or lungs, and is oftenest found near the tip of the tongue. The ulcer is of a grayish-pink color, the floor is covered with a caseous material, and the edges are undermined and not indurated.

Tubercular ulcers are usually quite painful. They can be differentiated from syphilitic ulcers by the fact that the latter have indurated edges and there is considerable induration of the tissues around them. The ulceration is deeper and the edges are not undermined. There are no enlarged lymph-nodes and there is usually the presence or the history of syphilis elsewhere. Syphilis affects the middle, while tuberculosis is more often found on the lateral portions of the tongue. Syphilitic ulcers are painless.

Tuberculosis of the tongue can be differentiated from carcinoma of the tongue of the ulcerative type by the facts (*a*) that the induration in carcinoma is very marked; (*b*) that the ulcer itself is not painful in the early stages; (*c*) that there are no evidences of tuberculosis in the lungs or elsewhere, and (*d*) the carcinomatous condition is accompanied by early enlargement of the submaxillary or deep cervical lymph-nodes. The age also will assist in the diagnosis, carcinoma occurring as a general rule at a later age than the average case of tuberculosis.

Syphilis of the Tongue.—This may appear (*a*) in the form of a primary chancre; (*b*) in the form of secondary mucous patches, which may or may not have broken down to form ulcers; (*c*) in the form of gummata, which may be superficial or deep, and (*d*) as a syphilitic atrophy of the base of the tongue.

Chancre of the tongue is a comparatively rare lesion. It is usually

present on the upper surface or anterior edge. It shows a slight central depression, with its floor covered with necrotic tissue, and has moderately indurated edges. There is usually quite early enlargement of the submaxillary lymph-nodes (Fig. 81). The diagnosis can be confirmed within a comparatively brief period by the appearance of secondary symptoms. The principal condition which must be differentiated from a primary syphilitic lesion of the tongue is a decubital or dental ulcer, which may also be present along the edges of the tongue. This dental ulcer is not accompanied by any enlargement of the lymph-nodes, and one can usually find the source of the ulcer in the form of a sharp tooth and the ulcer heals as quickly as the source of irritation is removed.

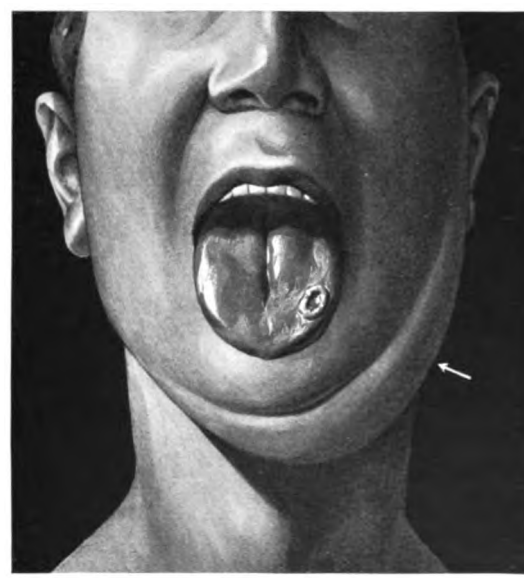

FIG. 81.—CHANCRE OF LEFT EDGE OF TONGUE, WITH SECONDARY ENLARGEMENT OF SUBMAXILLARY LYMPH-NODES, TO WHICH THE WHITE ARROW POINTS.

Secondary syphilitic lesions or mucous patches occur on the borders under surface of the tongue. They may occur simply as pure white, small, slightly raised areas, which are quite opaque, or as minute ulcers. They are usually quite painful and often fissured. A condition from which they must be differentiated is the small, painful, so-called aphtha sometimes associated with disturbances of digestion. These aphthous patches are usually oval in outline, seldom multiple, as is the case with mucous patches, and much more painful. The absence of the history of syphilis and of evidences of the disease elsewhere, as well as the fact that the condition heals within a few days after regulation of the diet, will serve to exclude this condition.

Tertiary Syphilitic Lesions of the Tongue.—These occur about five to fifteen years after the primary infection and are usually multiple. They may occur as gummatous infiltrations seated deeply in the substance of the tongue, which ulcerate later, or as superficial gummata. They are

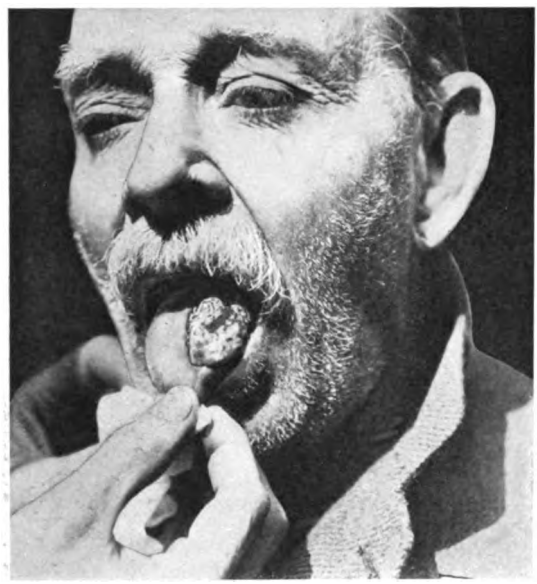

FIG. 82.—CARCINOMA OF MIDDLE OF LEFT EDGE OF TONGUE DEVELOPING UPON A GUMMA. Anterior view.

most frequently present on the dorsum of the tongue, but may also develop, rarely, along the edge of the tongue. An ulcer, due to a broken-down gumma, has only a moderate amount of induration. The edges are not much above the level of the surrounding tissue and the floor of the ulcer is necrotic. The edges are not everted, like those of an epithelioma, and are quite steep or straight. There is no enlargement of the regional lymph-nodes, viz., the submental, submaxillary, and deep cervical.

The differentiation from a dental or decubital ulcer can be readily made by ascertaining the source of irritation and by the fact that the induration in decubital ulcer is seldom as well marked as in either a syphilitic or a carcinomatous ulcer.

In case of any doubt, the removal of the cause of the irritation and the administration of iodid of potassium for a period of one week will clear up the diagnosis.

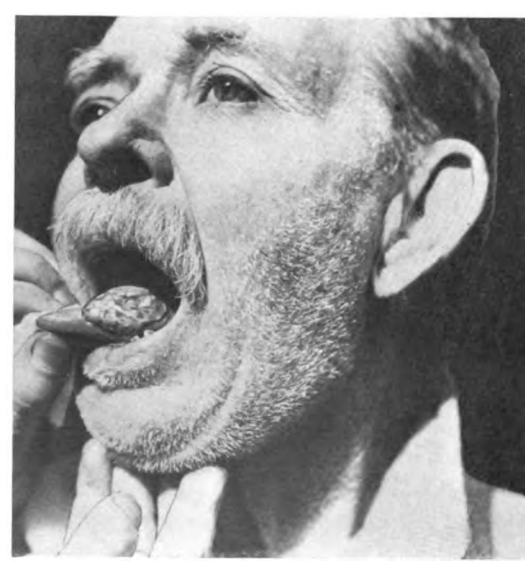

FIG. 83.—LATERAL VIEW OF A CARCINOMA OF THE LEFT EDGE OF THE TONGUE.
Same patient as shown in Fig. 82.

In addition to this therapeutic test, one can usually obtain a history of or evidences of syphilis elsewhere.

Tertiary syphilis may occur in the form of fissures at the edges of the tongue, which are quite painful, and can only be discovered by separating the furred epithelium of the tongue. Syphilis is the most frequent cause of fissures of the tongue. In advanced cases these fissures may be long and sinuous and resemble either a tubercular or carcinomatous ulcer. A carcinoma appearing in the form of a fissure has markedly indurated edges and there is always accompanying enlargement of the submaxillary and deep cervical lymph-nodes. Carcinoma may, however, develop upon a tertiary syphilitic lesion (Figs. 82 and 83) and under these circumstances a differentiation between the two at an early stage can only be made by considering the degree of induration, which is far greater in carcinoma than in syphilis, and finding enlarged, hard lymph-nodes under the chin and at the angle of the jaw.

The fourth form of syphilis of the tongue is the so-called syphilitic atrophy, which was first described by Virchow. This is always at the base of the tongue and shows itself by a smooth, shining condition, due to a loss of the epithelium of this portion of the tongue. It may appear and disappear during the course of syphilis from time to time or may persist. It may be necessary in some cases to differentiate the deep form of gummata from neoplasms of the tongue, such as carcinoma or sarcoma. Both of these are much firmer and more sharply demarcated from the surrounding structures of the tongue, the gumma is inelastic, and cannot be separated from the surrounding structures. The gummata often occur multiple, while carcinoma and benign tumors are almost always single.

The differentiation of tertiary syphilitic lesions from carcinoma will be referred to later.

NON-MALIGNANT TUMORS OF THE TONGUE.

These are lipoma, hemangioma, lymphangioma, and papilloma. The **lipoma** occurs late in life, near the tip or on the dorsum of the tongue. It is very slow in growth, and can readily be recognized by the fact that the mucosa is stretched over the tumor, and through it one can see the lemon-yellow fat. There is also distinct lobulation.

Hemangiomata may occur in the capillary form as deep red nodules, the size of a pea, either single or multiple, on the dorsum or edges of the tongue. They present the same characteristics as this

form of tumor elsewhere, namely, that the tumor itself can be caused to disappear by pressure but speedily returns as soon as it is relieved.

The other form of hemangioma, which occurs on the tongue, is the soft palate and cheek. It may involve only a small area, or an entire half of the tongue, causing considerable swelling, which can be greatly decreased by pressure but rapidly refills.

Lymphangioma.—Lymphangioma may occur in the capillary or cavernous forms (Figs. 84 and 85). The former can be recognized by the minute vesicles or rarely larger cysts which are present along the edges and dorsum of the tongue. The vesicles are translucent and about the size of a millet seed. The cavernous form causes a condition known as macroglossia. It is usually congenital, or develops in early infancy (Fig. 84), and is not infrequently accompanied by the capillary form. It may cause such an enlargement of the tongue that it cannot be withdrawn into the mouth but constantly protrudes through the lips. It causes disturbances in the development of the lips, jaws, and teeth through pressure.

One of the characteristics of this form of new growths is the fact that it is subject to recurrent attacks of inflammation, which are accompanied by great swelling and pain in the affected portion. If the condition is circumscribed it may resemble a sarcoma of the tongue, but can be readily differentiated from it by the history of its having been present since birth and the fact that its growth is far slower than that of a sarcoma.

Papilloma of the tongue occurs in the form of soft, pedunculated tumors which can be readily diagnosed.

MALIGNANT TUMORS OF THE TONGUE.

Sarcoma.—Sarcoma of the tongue is quite rare. It has only been found in young girls and women. It grows rapidly and ulcerates at quite an early stage. It must be differentiated from gumma and from carcinoma of the tongue. This can be done by remembering the fact that gumma is usually multiple, even though it be present in the form of a nodular growth within the substance of the tongue. Gummata occur at a later period of life and there is usually a history of syphilis or the evidences of the disease elsewhere. The growth is far less rapid than is that of a sarcoma.

From carcinoma a sarcoma of the tongue can be differentiated by the fact that the induration is much harder in a carcinoma than in sarcoma and that the former appears at a later period in life.

Carcinoma of the Tongue.—This may appear in one of four forms:

Fig. 84.

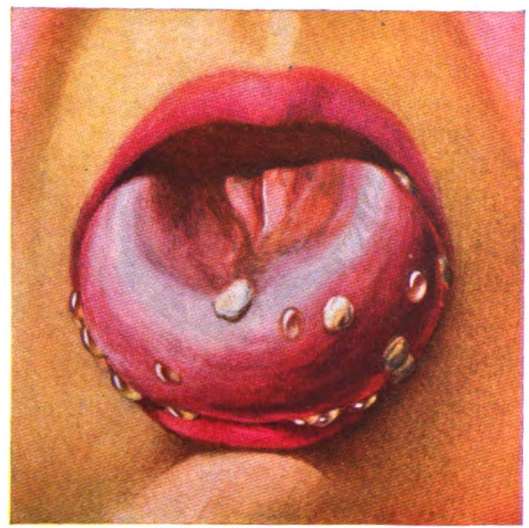

Fig. 85.

Figs. 84 and 85.—Lateral and Anterior Views of a Case of Macroglossia, Due to Lymphangioma Involving Both the Superficial and Deep Lymph Vessels of the Tongue in a Boy of Five.

The clear vesicular spaces correspond to the dilated superficial lymph vessels. The general enlargement of the tongue is caused by the involvement of the deeper lymph vessels. The whitish patches are the result of a hyperplasia of the epithelium of the tongue (keratosis).

(*a*) As a fissure, with indurated edges; (*b*) as a carcinomatous ulcer; (*c*) as a warty growth whose base has become indurated, and (*d*) as a hard nodule in the substance of the tongue.

Usually one does not see carcinoma in the nodular form. Ordinarily it appears as an ulcer or fissure.

According to Butlin, the most important precancerous condition is the papilloma, which precedes the development of carcinoma. The warts enlarge in size, the base becomes harder, and sooner or later ulceration occurs. Not infrequently the warts are present (Fig. 86) upon a tongue which is the seat of an extensive leukoplakia.

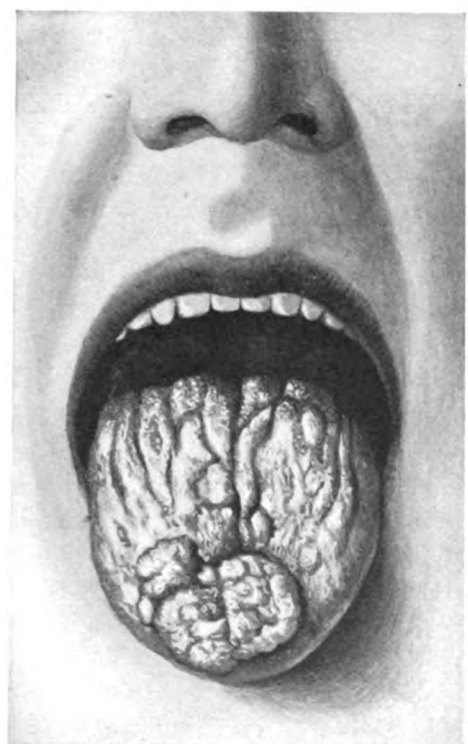

FIG. 86.—PAPILLARY FORM OF CARCINOMA OF TONGUE DEVELOPING ON PSORIASIS LINGUÆ (Jonathan Hutchinson).

The least frequent form of carcinoma of the tongue is the nodule in its substance. It must be differentiated from sarcoma or gumma in the substance of the tongue before it begins to ulcerate. This has been referred to above, under the head of sarcoma of the tongue.

The characteristics of carcinoma of the tongue, after ulceration has once begun, are:

(*a*) It appears most frequently along the edges or under surface of the tongue, (*b*) there is early enlargement of the submaxillary and deep cervical lymph-nodes; (*c*) the edges of the ulcer are everted and very firm, and (*d*) the floor of the ulcer is covered with a large amount of necrotic epithelium.

There is usually severe pain, which radiates to the ear. In the later stages the carcinomatous ulcer has a very fetid odor, is very painful, and severe hemorrhages may occur.

Carcinoma of the tongue must be differentiated from the following conditions:

(*a*) *Dental or Decubital Ulcers.*—These are present along the edges

of the tongue opposite a sharp tooth. The ulcer is never as deep as that of a carcinoma, nor are the edges as indurated, and there is no enlargement of lymph-nodes. The ulcer heals in a few days if the tooth is either extracted or the sharp edge filed down.

(*b*) ***From Tubercular Ulcers.***—These never show the induration which characterizes the carcinomatous ulcer. The tubercular ulcer is quite shallow, usually with undermined, not raised, edges, and there is no lymph-node enlargement. They occur at an earlier age and are usually secondary to tuberculosis of the larynx or lungs.

(*c*) ***From syphilis*** the question of differentiation most often arises in the case of gummatous ulcers. The diagnosis, as will be seen in Figs. 82 and 83, is at times exceedingly difficult. In the case shown in the illustrations, the patient gave a distinct history of syphilis and had well-marked symptoms of tabes dorsalis. The first diagnosis made in the case was that of epithelioma of the tongue, on account of the marked induration, and raised, everted edges, and deep ulceration. The administration of iodid of potassium caused a marked improvement in the condition, the induration and ulceration disappearing to a great extent. In a short time, however, these signs recurred, in spite of the continued administration of the drug. At the time the diagnosis of epithelioma was first made, there was an accompanying enlargement of the submaxillary lymph-nodes on the side upon which the ulcer was situated, and this was thought to confirm the diagnosis of epithelioma. The final diagnosis made in this case, after removal of the tongue, was that it had been a carcinoma of the tongue, which had developed upon a tertiary, *i. e.*, gummatous ulcer.

This case illustrates the difficulties of diagnosis between epithelioma and tertiary syphilis. According to Jonathan Hutchinson,[1] at least 30 per cent. of the patients with epithelioma give the history of previous syphilis. An accurate diagnosis can be made in the majority of cases, but in some only the microscopic examination decides.

A therapeutic test may at times be fallacious, either from the fact that carcinoma may improve after the hygiene of the mouth has been attended to, or that, as in the case illustrated in Fig. 82, the carcinoma has developed upon a gummatous ulcer.

In general, the following may be taken as the chief differential points, between epitheliomatous and gummatous ulcers:

[1] "Practitioner," May, 1903.

Gummatous Ulcer.	Carcinomatous Ulcer.
1. Appears usually multiple on dorsum.	1. Appears on sides of tongue and floor of mouth.
2. May occur at any age.	2. May occur as early as thirty.
3. But little if any enlargement of lymph-nodes.	3. Early and indurated enlargement of submaxillary and deep cervical lymph-nodes.
4. But little pain.	4. Considerable pain, radiating to ear.
5. Induration less marked than in carcinoma.	5. Very marked induration. Edges raised and everted.
6. Iodid of potassium causes marked improvement within a week.	6. No improvement or only slight, unless carcinoma has developed upon a gummatous ulcer.
7. Evidence of tertiary disease elsewhere.	7. No evidence of tertiary disease, unless carcinoma has developed in an individual with previous syphilis.

Carcinoma of the floor of the mouth may spread to the under surface of the tongue, so that it is at times difficult to ascertain where the disease began. There is only one condition which it may at times be necessary to differentiate, under these circumstances, and that is the ulceration due to the infection of the tissues around a salivary calculus. There is not infrequently considerable painful induration around such a calculus, with ulcer formation, the ulcer being covered with foul granulations. It can be differentiated from a true carcinoma by the fact (*a*) that the induration is never as marked as in carcinoma; (*b*) by the use of a probe one can find the calculus, and (*c*) as a rule there is no induration of the lymph-nodes. It is almost impossible to make a diagnosis between an unbroken gumma and the nodular form of carcinoma, which occurs in the substance of the tongue, except perhaps the fact that the nodular form of carcinoma is single, while the gumma is multiple. There are other signs of syphilis or the history of syphilis in the case of a gumma.

The only other conditions of the tongue which need to be mentioned are lingual goiter and lingual tonsils.

Lingual goiter (Fig. 77) is an enlargement of the upper end of the original thyroglossal duct, which has its termination close to the foramen cecum at the posterior portion of the dorsum of the tongue. Ordinarily a lingual goiter causes no symptoms, except that when it begins to grow it may cause some difficulty in swallowing. It may be as large as a walnut and yet cause no inconvenience.

The first symptom is generally an uncomfortable feeling at the base of the tongue, a fullness in the throat accompanied by a frequent desire to swallow. There is a change in the voice, which becomes thicker

and nasal in quality.[1] There may be fits of coughing. Only in the case of the largest tumors is the respiration interfered with.

Later in the disease there are recurrent, profuse hemorrhages. These occur at any time, without any apparent cause, the patient being simply aware that the mouth is filled with fluid, which on expectoration proves to be blood.

The presence of the growth can only be determined by the use of the laryngoscope or the finger. The tumor is soft, reddish in color, shows no ulceration or induration, or enlarged lymph-nodes.

The diagnosis can be made from the facts (*a*) that it is soft, not indurated or ulcerated; (*b*) it is not accompanied by enlarged lymph-nodes, and (*c*) its course is a very chronic one. The cases so far reported appear to have occurred exclusively in women between the ages of fifteen and forty.

The differential diagnosis of a lingual goiter includes:

(*a*) Dermoid cysts. This is the only condition which offers any difficulty. It is generally yellow, grows rapidly, pits on pressure and is not vascular.

(*b*) Angioma is a quite common tumor at the base of the tongue and may give rise to hemorrhages. It is, however, easily reduced by pressure, refilling immediately, and is of a bluish color.

The Lingual Tonsil.—The enlargements of this group of adenoid tissue on the dorsum of the tongue, near the foramen cecum, may cause some symptoms, especially if they become inflamed or enlarged. These are pain in swallowing, aching, irritable throat, and coughing.

The diagnosis can only be made by the use of the laryngoscopic mirror. One then sees whitish follicles, swollen and filled with secretion, extending in either direction from the foramen cecum. At times one of these may suppurate and be accompanied by parenchymatous glossitis.

AFFECTIONS OF THE SALIVARY GLANDS.

Injuries.—Wounds of the submaxillary and sublingual glands are so rare that only those of the parotid will be referred to.

Injuries of the parotid gland itself not infrequently occur in connection with those of the face.

Wounds of the gland parenchyma itself are of but little consequence, since a salivary fistula rarely follows such an injury. Chief interest lies in injuries of the vessels passing through the gland and of the facial nerve, which divides within the capsule. The vessels which pass through

[1] Storrs: "Annals of Surgery," 1904.

the gland and might be injured by a penetrating wound are the temporo-maxillary (posterior facial) vein and the termination of the external carotid artery. The recognition of their injury does not differ from that of similar structures elsewhere.

An *injury of the facial nerve* during its passage through the parotid capsule is recognized by the paralysis of the muscles of expression (Fig. 87). The naso-labial fold upon the side of the injury is flattened, there is inability to close the eyelids and to show the teeth or to whistle.

Injuries of the parotid duct are more important than those of the gland itself. It may be wounded while (*a*) it is still in the parotid capsule, (*b*) during its passage across the masseter muscle, and (*c*) while penetrating the tissues of the cheek to open into the mouth. The recognition of such injury is usually not difficult. Saliva is seen to escape from a wound in the cheek, especially during mastication. The diagnosis is confirmed by inserting a fine probe through the opening of Steno's duct where it opens into the mouth opposite the second upper molar tooth. The probe will pass through the opening in the duct and emerge in the cheek wound externally. One can also observe the escape of colored liquids such as methylene-blue when injected into the buccal orifice of Steno's duct.

FIG. 87.—LEFT-SIDED FACIAL PARALYSIS.

Involving all three groups of muscles supplied by the seventh cranial nerve, namely, the eye, nasal and labial groups. Note the obliteration of the naso-labial fold on the side of paralysis, the drooping of the left angle of the mouth, the inability to close the left eyelid, and loss of action of the muscles of the eyebrows.

A *salivary fistula* is rarely congenital. In the majority of cases it follows an injury to the gland or its duct or it is the result of abscess formation in the gland or in the duct with subsequent ulceration of the overlying tissues. In both cases there is an external opening, either over the glands or along the course of the duct, lined by granulations from which a watery fluid escapes.

The secretion of a duct fistula is much greater than that of a glan-

dular one. In the duct fistulæ there is an absence of any ejection of saliva from the opening of the duct within the mouth. This is best seen when the cheek is retracted while the opening of the duct into the mouth is observed.

Salivary Calculi.—The majority of these occur in the excretory duct (Wharton's) of the submaxillary gland. They are very rare in Steno's duct. The calculi are usually the size of a pea or bean but occasionally attain to that of a pigeon's or hen's egg. Salivary calculi may give rise to the following clinical pictures:

1. They may remain dormant for many years and not give rise to any symptoms.

2. They give rise to acute attacks of salivary retention. These are recognized by the sudden appearance, usually after eating, of pain along the duct, accompanied by a markedly tender enlargement over the normal situation of the gland whose duct is blocked. After a few hours there is a sudden discharge of saliva into the mouth, and the swelling and tenderness rapidly disappear. With such a history of recurrent swelling one must always pass a probe into the duct or palpate along its course for the calculus, which can usually be readily felt.

3. There may be inflammation of the tissues around the stone and resultant abscess formation. This clinical form is characterized by the appearance of great pain, tenderness, and induration along the course of one of the salivary ducts. In the case of Wharton's duct this is most marked along the floor of the mouth, while in that of Steno's duct it is best felt with the finger while palpating the inside of the cheek or externally along the course of the duct. In the latter location, *i. e.*, Steno's duct, the first sign may be the appearance of an induration in the middle of the cheek, accompanied by redness and swelling of the skin lying over it. The diagnosis can be made from the location of the abscess and the absence of any other cause.

4. A salivary calculus may appear as an ulceration on the floor of the mouth or on the inside of the cheek. The ulcer has indurated edges and a dirty foul-smelling base. Its resemblance to carcinoma has already been referred to. The diagnosis can only be made by the use of the probe or the finger, which encounter the calculus lying at the bottom of the crater-like ulcer.

Inflammatory Affections.—These may be acute and chronic. The acute may occur (*a*) as an epidemic variety of acute inflammation of the parotid or submaxillary glands commonly called "mumps." This is fully described in the text-books on internal medicine and presents but little difficulty in diagnosis. If, however, a complication

such as orchitis or oöphoritis occurs, it is of great diagnostic importance to obtain the history of a preceding acute swelling in front of the ears or below the jaw, which lasted for a week to ten days.

(*b*) The other form of acute inflammation of the salivary glands occurs as a complication of typhoid and other of the acute infections diseases. It may also occur after laparotomies and is then given the special name of "cœliac parotitis."

These so-called acute secondary inflammations almost always involve the parotid gland. The diagnosis can be made from the appearance of severe pain at first referred to the angle of the lower jaw and later in front of the ear and greatly increased by movements of the jaw. The onset of swelling is rapid and there is marked edema and redness of the overlying skin. If suppuration occurs the skin-infiltration and redness increase and there is soon distinct fluctuation. The abscess may burst externally either through the external auditory canal or the cheek. Such a parotid suppuration may be the starting-point of a retropharyngeal and periesophageal phlegmon or the infection may spread to the skull and give rise to a fatal meningitis.

Tuberculosis of the Salivary Glands.—This is a very rare affection, especially as a primary disease. It is not infrequent as the result of an extension of a tuberculosis of the lymph-nodes contained within the parotid capsule. In either form there is moderate enlargement of the gland and fistulæ form, lined by flabby, often caseous, granulations.

Syphilis.—This form of chronic inflammatory enlargement usually occurs in the tertiary stage. The disease almost always involves the parotid, causing a soft tumor-like swelling. The diagnosis of its syphilitic nature can only be made from the history and its rapid disappearance under appropriate treatment.

Tumors of the Salivary Glands.—In attempting to make a diagnosis of the nature of an enlargement of one of the salivary glands one must bear in mind the following possibilities:

1. If the onset is sudden the enlargement is either of an acute inflammatory nature or is due to an acute retention of secretion through obstruction of the excretory duct.

2. If the onset has been slow and the increase in size gradual it may be due (*a*) to a retention-cyst, (*b*) to chronic inflammatory changes as a result of syphilis or tuberculosis, or (*c*) to a neoplasm.

Retention-cysts and neoplasms occur far more frequently in the parotid than in either the submaxillary or sublingual glands.

Retention-cysts differ from the condition described on page 125 as acute dilatation of the ducts or glands themselves due to transitory ob-

struction to the flow of saliva. Retention-cysts are permanent and are due to a complete and chronic obstruction of the duct. The accumulation of secretion may take place either in the duct or in the gland. In the former case (*cysts of the salivary ducts*) the condition must be thought of when an elongated sausage-shaped fluctuating tumor is found in a location corresponding to that of either Steno's or Wharton's duct.

The swelling is quite sharply demarcated and is not tender. Infection of the contents may occur with all the signs of inflammation, *e. g.*, pain, redness, etc. If such infection occur the swelling may resemble, in Steno's duct, an inflamed lymph-node in the cheek. This, however, is a very rare condition and can be readily excluded by its more superficial location and the absence of a primary focus.

Cysts of the salivary glands give rise to a visible and palpable enlargement of the gland involved, especially if the cyst is situated close to the surface. They are very rare in the parotid and submaxillary, but occur more often in the sublingual gland. In the latter the condition is known as ranula (see Fig. 78) and can be recognized by the location at the floor of the mouth, and by its fluctuation and translucency.

Tumors of the Salivary Glands.

In the *diagnosis* of a tumor of the salivary glands one must consider (*a*) the size of the growth; (*b*) the condition of its surface, whether smooth or nodulated; (*c*) its consistency, whether fibrous, cartilaginous soft, or cystic; (*d*) its clinical history, whether it remained stationary for many years and then suddenly increased in size, whether its growth has been rapid from the time it was first noticed or whether it has remained of about the same size for a considerable period.

Tumors of the salivary glands are best divided into the following groups:

1. Those of the benign connective-tissue type { (*a*) Fibromata. (*b*) Angiomata. (*c*) Lipomata.
2. Mixed tumors (including sarcomata).
3. Carcinomata.

1. **Benign Connective-tissue Type:**

(*a*) *Fibromata.*—These are very rare. They are firm, encapsulated growths which run a benign clinical course. They grow very slowly and do not tend to recur when removed.

(*b*) *Angiomata.*—These are also very rare and usually occur in chil-

dren. They greatly resemble simple hypertrophy and form irregular soft tumors.

(*c*) *Lipomata.*—But few cases of this form of tumor have been reported and of these all occurred in the parotid. They raise the gland itself, are soft, and often lobulated. The diagnosis is seldom possible before operation.

2. **Mixed Tumors (Including Sarcomata).**—It has been frequently observed that sarcomata of the salivary glands differed clinically from the same form of tumors as found elsewhere, both in their clinical and pathologic characteristics. Since the systematic study of these tumors, by Hinsberg,[1] Wilms,[2] Wood[3] and others, it has been found that the majority of tumors of the salivary glands belong to the class of mixed growths and that pure sarcomata are comparatively rare. Of fifty-nine cases examined by Wood, all but four belonged to the mixed tumors. They occur about twice as frequently in the parotid as in the submaxillary and usually between the ages of twenty to forty. They contain elements from both the epiblast and mesoblast in most intimate relation to each other. The stroma contains embryonic connective tissue, cartilage, bone, fat, and lymphoid tissue. There is also epithelium present in about 24 per cent. of the cases.

The mixed tumors of the salivary glands are found, as a rule, to be encapsulated, lobular growths, with harder and softer areas, the denser portions being due, as a rule, to the presence of cartilage or firm connective tissue. They can be divided macroscopically into three great rough groups with characteristic morphology and to a certain extent with a definite clinical course:

1. Very fibrous tumors with very little cellular structure and with but little mucous degeneration and no cartilage.

2. Very hard tumors containing large masses of cartilage and but little connective tissue or cellular parenchyma (Fig. 88).

3. Soft, very cellular growths with transparent trabeculæ of mucous tissue surrounding areas which are opaque and yellow, which on microscopic examination will be found to be dense cellular areas, the color being occasionally, though not always, due to fatty degeneration or necrosis of the cells.

The first and second forms are usually benign in their clinical course, while the third form is likely to recur locally or to pursue an exceedingly malignant course.

[1] Hinsberg: "Deutsche Zeitschr. f. Chirurgie," Vol. 61.
[2] Wilms: "Deutsche Zeitschr. f. Chirurgie," Vol. 69.
[3] Wood: "Annals of Surgery," Jan. and Feb., 1904.

The skin is freely movable over the benign growths. The ear may be distorted or pressed entirely backward by a large tumor in the parotid region, especially if the growth has extensions behind the angle of the jaw and is therefore unable to expand anteriorly.

An average of the cases of mixed tumors in the literature shows that some 25 per cent. undergo changes which express themselves in a clinically malignant course, while about 30 per cent. recur after operative

FIG. 88.—CHONDROSARCOMA OF PAROTID GLAND.
Note how the tumor arises in the parotid region and extends toward and below the lower jaw and its nodulated surface.

removal, though some of these recurrences may be checked by a second and more complete removal.

The malignancy of these tumors can be judged to a certain extent by their slowness of growth and their physical characteristics. The hard fibrous and cartilaginous tumors are apt to be benign, while the soft cellular types are likely to prove malignant. But frequently a tumor which has remained for a long time quiescent will begin a most rapid growth, and in a few months increase in size more than during its entire previous existence. This sudden and rapid growth is accompanied

by the clinical and microscopic evidences of malignancy, and the tumor spreads through the surrounding tissues, involves the skin and the salivary glands, and may form metastases.

Carcinomata of the Parotid.—These occur in people between forty and sixty years of age and are apt to be very painful. They may grow either slowly as a scirrhous form, causing considerable retraction of the skin, or as a medullary form, growing very rapidly and causing ulceration of the overlying skin. Carcinomata of the parotid are apt to be very painful and also cause early enlargement of the lymph-nodes of the neck on the corresponding side.

The medullary form of carcinoma resembles greatly that of the same form of carcinoma of the breast. It grows very rapidly and may occur at a comparatively early period, *e. g.*, at the age of forty years, and is readily recognized not only by the rapidity of the growth, but from the early involvement of the skin. The latter is not movable over the tumor as in the other forms of parotid tumors. The scirrhus form resembles the scirrhus form of carcinoma of the breast, causing not only retraction of the skin of the parotid region but also an invasion of the skin itself in the form of a diffuse carcinomatous lymphangitis, giving rise to the same variety of board-like infiltration which occasionally occurs in carcinoma of the breast. To this latter condition the name armor-like cancer has been given.

Diagnosis of the Tumors of the Parotid in General.—In attempting to make a diagnosis of tumor of the parotid one must bear the different groups in mind. Tumors of the parotid cause a characteristic prominence (Fig. 88) just in front of the ear, which latter is raised away from the head. They may either grow toward the neck, forming a very prominent tumor, or toward the depth, that is, toward the pharynx. In some cases, enlargement of the parotid of an inflammatory nature, such as (*a*) retention-cysts, due to salivary calculi, (*b*) of the induration described as occurring in syphilis, or (*c*) enlarged lymph-nodes lying within and upon the parotid, must be excluded.

Lymph-nodes have at times the consistency of the soft variety of mixed tumors. If they lie within the capsule and have enlarged rapidly, it may be almost impossible to make a diagnosis. If, however, they lie outside of the capsule they are movable upon the underlying parotid.

As to the variety of tumors, those belonging to the first group of mixed tumors are usually quite small, not nodular, movable within the capsule of the gland, and give the history of having been present for a long time. Those of the second group of mixed tumors contain *one-fourth* of all the tumors appearing in the parotid. They are distinctly nodulated,

have the characteristic consistency of cartilage and the history of long duration, as a rule, although a rapid increase in growth may suddenly take place.

A soft tumor usually belongs to the third group of mixed tumors. These are very cellular and give the history of comparatively rapid enlargement, or, on the other hand, they remain benign for a long time and then suddenly grow. The latter is very apt to happen after an operation. This third group has the consistency of inflamed lymph-nodes more than any of the others, but the inflamed lymph-node soon becomes softer and fluctuates distinctly while the neoplasm is more apt to grow steadily in size.

Carcinomata of the parotid are exceedingly hard, occur late in life, and give the history of a steady, progressive enlargement of the gland with frequent ulceration of the overlying skin.

In the differential diagnosis of tumors of the parotid, one must not forget (*a*) lipomata lying within the capsule of the gland, (*b*) tumors of the temporo-maxillary joint, or (*c*) tumors of retropharyngeal origin growing toward the temporal fossa and pushing the parotid upward.

Cystic tumors of the parotid give rise to distinct fluctuation, are of long duration, and must always be differentiated from those varieties of mixed tumor in which much myxomatous tissue is present which may give rise to a sense of pseudo-fluctuation.

CHAPTER II.

SURGICAL AFFECTIONS OF THE NECK.

CONGENITAL AND ACQUIRED MALFORMATIONS.

Thyroglossal Fistulæ.—These are always found in the median line of the neck. The external opening may be situated (*a*) just above the isthmus of the thyroid (Fig. 119), extending upward beneath the skin. The fistulous tract itself runs up behind the body of the hyoid where it may form a cyst. (*b*) It may extend through the substance of the tongue and form a cyst at the base of the tongue (Fig. 77). A fistulous opening situated in the median line of the neck should always arouse the suspicion of a patent thyroglossal duct. The only other congenital fistulæ which occur in the neck are situated along the anterior border of the sternocleidomastoid. These lateral fistulæ belong to the branchial variety and are referred to later. A thryoglossal fistulous tract extending from the isthmus of the thyroid to the inner surface of the body of the hyoid can be demonstrated by injecting colored fluids, such as methylene-blue, through the external opening. If the tract is pervious as far as the foramen cecum at the base of the tongue, the colored fluid will escape at the latter place. At times there is no external opening, but only a dilated thyroglossal duct filled with fluid. Under these circumstances, the diagnosis can be readily made if one recalls the fact that the only other cyst which occurs in the middle of the upper part of the neck is a dermoid cyst. This is usually situated more superficially and is more often in the submental region. It is also of larger size and of firmer, more doughy, consistency than a thyroglossal cyst. The diagnosis of thyroglossal cysts at the base of the tongue was taken up on page 138.

Branchial Fistulæ.—These are usually unilateral, and the external openings are more often situated just above the sternoclavicular joint or at the middle of the sternocleidomastoid. The internal openings are usually found on the tonsil, the lateral wall of the pharynx, or on the pillars of the fauces. The fistula may be complete, having both internal and external openings, or incomplete, having only an internal or external opening, as the case may be. The incomplete internal fistulæ are lined with cylindric, and the incomplete external

fistulæ with squamous epithelium. From the external opening a small amount of mucus escapes. It may close, the secretion being retained, and suppuration occur. The course of a branchial fistula can be demonstrated, as in the case of thyroglossal fistula, by injecting colored fluids. It can be felt at times as a firm cord through the skin, extending upward along the anterior border of the sternocleidomastoid toward the region of the tonsil. The deeper portions of a branchial fistula may dilate to form a cyst.

Carcinoma may originate from the epithelium of branchial fistulæ. Branchial cysts and branchiogenic carcinomata are discussed in the section upon tumors of the neck.

FIG. 89.—CERVICAL RIB OUTLINED ON SURFACE OF NECK.
The cross indicates the tip of the rib.

The diagnosis of branchial fistulæ may be made (*a*) from the fact that they usually occur in young individuals, (*b*) that their external opening is along the external border of the sternocleidomastoid muscle, and (*c*) the secretion is a thin, viscid mucus. In the absence of a suppurating lymph-node which might form a sinus here, the diagnosis is not difficult. In the case of a sinus due to tubercular lymph-nodes, the edges of the sinus are often lined by flabby caseous granulation-tissue, which will readily serve to distinguish it from a congenital fistula.

Cervical Rib.—Abnormal length of the transverse process of the seventh cervical vertebra not infrequently gives rise to symptoms calling for surgical interference, so that it is important to be able to recognize its presence. The majority of the cases in which a diagnosis has been made during life have occurred in adults. The bony outgrowth is usually bilateral and can be palpated as a firm, bony tumor just above the inner end of the clavicles, running backward and upward toward the spine. Thirty-seven cases have been reported in which it has been recognized during life, either through producing pressure on the subclavian artery or some of the branches of the branchial plexus. When the sub-

clavian artery passes across a cervical rib, it may occasionally give rise to a pulsating tumor simulating an aneurysm. There is an absence, however, of the expansile pulsation characteristic of aneurysms in general, and a cervical rib producing such abnormal pulsation of the subclavian artery occurs at an earlier period of life than do non-traumatic aneurysms. A skiagraph will confirm the suspicion that the pulsating tumor is simply the subclavian artery stretched over the end of a cervical rib. The effects on the arteries vary from weakness of the radial pulse to cyanosis. In extreme cases there is thrombosis of the peripheral vessels, resulting in gangrene. The nerve-pressure symptoms vary from neuralgic pain, situated in one of the branches of the brachial plexus, simulating at times a neuritis, to paresthesias and pareses of the muscles of the arm.

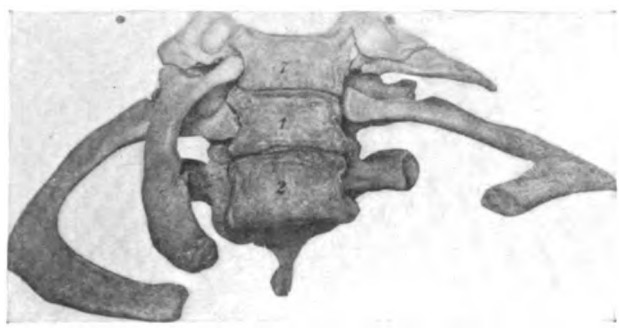

FIG. 90.—DISSECTION OF A CASE OF CERVICAL RIB.

7, Seventh cervical vertebra; 1, first dorsal vertebra; 2, second dorsal vertebra. On the right side observe the large cervical rib arising from the seventh cervical vertebra close to its junction with the first dorsal. On the left side observe a shorter cervical rib (Schultze).

The diagnosis can be easily made by (*a*) the palpation of the bony tumor in the neck, (*b*) by disturbances of circulation, and (*c*) pressure symptoms upon the brachial plexus. The cervical rib may vary from a short projection an inch long to one extending to the first rib. It must be differentiated chiefly from exostoses of the spine. These cause less pressure on the subclavian artery, but more on the vein, causing edema of the arm. The condition must also be differentiated from tubercular lymph-nodes in the posterior triangle of the neck. These nodes are never as hard as the cervical rib, nor are they ever attached to the spine. Similar nodes are also to be found in the upper portions of the neck. A third condition from which a cervical rib must be differentiated is that of carcinomatous enlargement of the supraclavicular glands, causing pressure on the surrounding structures. These may be very firm in

consistency, but are never as hard as a cervical rib, and there is usually a history of a primary growth or its presence at the time of examination in the territory drained by these nodes (Fig. 74).

Wry-neck, or Caput Obstipum.—Wry-neck produces a deformity which can be readily recognized by the fact that the head is inclined (Fig. 92) toward the side of the affected muscles, while the chin is directed toward the opposite side, and there is always some rotation of the head toward the opposite side. The chief point of surgical interest is to determine (*a*) whether the condition is of acute or chronic nature, or (*b*)

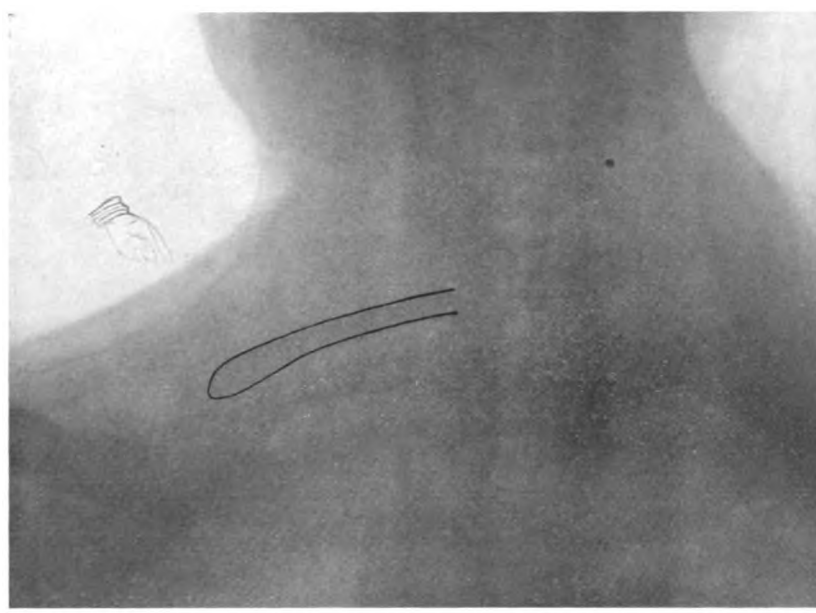

FIG. 91.—X-RAY OF A CASE OF CERVICAL RIB.
The rib itself has been outlined in black.

whether it is symptomatic or congenital in origin. Of the acute causes which may produce it the most frequent is muscular rheumatism. This form can be recognized by its sudden appearance, the absence of any swelling or tenderness along the muscle, with considerable pain on movement, and the history of its having appeared quite acutely. Its form disappears rapidly after antirheumatic treatment. A second variety of acute wry-neck is that accompanying infection of the deep cervical lymph-nodes (Fig. 92). This form is always accompanied by a swelling along the anterior or posterior borders of the muscle and there is considerable pain upon movement. The neck is held quite

rigid in the typical wry-neck position. Unless this swelling be correctly interpreted as due to infection, the rigid position of the neck with rotation of the head, etc., may cause the suppuration to be overlooked. A symptomatic wry-neck posture is at times assumed by patients following operations for extirpation of tubercular lymph-nodes, and may continue for some months. A fourth variety of wry-neck is that following extensive burns or other cicatricial processes of the neck. It is often called the dermatogenous variety, to distinguish it from the simple or rheumatic, and the symptomatic forms just referred to. There is no difficulty in distinguishing this form, owing to the fact that there is always ample evidence of scar tissue, either on the surface or in the subcutaneous structures. A fifth form is that which occurs in children, the myogenic. It is due to rupture of and hematoma formation in the sternocleidomastoid muscle, and is known as the congenital form. Congenital wry-neck is often accompanied by a scoliosis of the cervical vertebræ, the convexity in the cervical region being toward the side opposite to that upon which the wry-neck is situated. It is not infrequently associated with limitation of the visual field and facial hemiatrophy. A sixth form of wry-neck is that due to disease of the cervical vertebræ. In this there are neuralgic pains radiating from one or both sides of the vertebræ. There is also pain over the spine, stiffness, and the head is held in the typical fixed position.

FIG. 92.—TYPICAL WRY-NECK POSITION.
Occurring as the result of suppuration of the deep cervical lymph-nodes.

Wry-neck may also occur in a seventh form secondary to subluxation and rotation of the cervical vertebræ. These cases always have a history of trauma and the spine is held rigid without any of the pain characteristic of tubercular processes, and the *x*-ray may at times confirm the subluxation.

An eighth form of wry-neck which may at times call for surgical interference is that in which there is a frequently recurring spasm of the sternocleidomastoid and trapezius muscles. This form is called spasmodic wry-neck.

INJURIES OF THE NECK.

Injuries of the various structures of the neck may occur as the result of suicidal attempts, of gunshot or stab wounds, or of fractures. The injuries to the veins, arteries, nerves, and thoracic duct occurring as the result of operation do not differ from those due to other modes of injury and will not be considered separately.

Injuries to the Arteries.—These occur most often as the result of stab or gunshot wounds and may result in a partial or complete severing of the artery or in the formation of an aneurysm. The result of injuries of the arteries of the neck is either (*a*) immediate death, if the wound in the artery communicates with the wound in the skin, or (*b*) a large swelling forms in the neck in the immediate vicinity of the wounded artery, due to the escape of blood into the cellular tissue. Again, (*c*) death may occur at a later period through sloughing of the wall of an artery following a small wound of its wall, with resultant secondary hemorrhage.

The diagnosis of injury of the carotid artery may be made from the escape of bright red blood in large quantities through the external wound or the formation of a hematoma beneath the skin. There is no temporal pulse to be felt. In wounds of the subclavian arteries the same symptoms of tremendous primary hemorrhage or the formation of a hematoma may be present, accompanied by the absence of the radial pulse of the same side.

The majority of cases of wounds of the arteries of the neck are not seen immediately, so that the diagnosis depends upon the location (*a*) of the subcutaneous hematoma, (*b*) the location of the wound, and (*c*) the fact that there is no pulse in the distal arteries.

The vertebral artery is sometimes injured through gunshot wounds passing through the mouth or through a wound entering an inch below and behind the mastoid. At times the symptoms of injury of an artery may have been so slight at the time of the accident that the swelling, if any was present, is overlooked, and the patient only presents himself when a pulsating tumor has appeared as the result of the formation of a traumatic aneurysm.

Traumatic Aneurysms.—The symptoms of both traumatic and spontaneous aneurysms of the neck are the same. In the former there

is, however, the history of an injury, usually a gunshot or stab wound. The aneurysm may involve the artery alone or there may be communication between the artery and the vein. The majority of traumatic aneurysms of the neck are found in the carotid artery.

The diagnosis can be made by finding a pulsating tumor, usually situated close to the bifurcation of the common carotid artery, in which there is a thrill to be felt. If the aneurysmal tumor is compressed between the index finger and thumb, one can feel a distinct expansile pulsation. Not infrequently the diagnosis is aided by finding symptoms (*a*) of compression upon the trachea, causing more or less dyspnea, (*b*) upon the esophagus, causing difficulty in swallowing, and of (*c*) pressure upon the hypoglossal or recurrent laryngeal nerves, causing difficulty in speech and hoarseness, respectively. There may also be symptoms of pressure upon the nerves of the brachial plexus. In aneurysm of the external carotid the tumor is situated below the angle of the jaw and pushes the tonsil inward. At this point an aneurysm may be simulated by a lymph-node lying upon the external carotid. Under these conditions the pulsation is only marked when the gland is pressed against the vessel and there is no expansile pulsation, as is the case in true aneurysm.

Aneurysms of the subclavian artery may follow gunshot or stab wounds or rarely fractures of the clavicle, in which the fragments have penetrated the artery. Most often, however, aneurysms of this vessel are the result of endarteritis. The aneurysms of the first part of the subclavian artery are difficult to distinguish from those of the common carotid and innominate arteries, if on the right side. The aneurysms of the third part of the subclavian can be recognized by the presence of a pulsating tumor just above the clavicle, with the thrill, expansile pulsation, and bruit so characteristic of aneurysms elsewhere.

An aneurysm of the subclavian artery must be differentiated from the condition referred to above, viz., the subclavian artery being stretched across a cervical rib and giving rise to a pulsating swelling, which may resemble an aneurysm. The absence of expansile pulsation and the detection of the elongated cervical rib serve to distinguish these. Subclavian aneurysms may also be distinguished by the fact that they are much more apt to give rise to symptoms of pressure on the nerves of the brachial plexus, causing either neuralgia or weakness of the affected muscles. The most frequent location of aneurysms of the subclavian is in the third portion of the artery, situated on the outer side of the sternocleidomastoid muscle.

Arterio-venous aneurysms as the result of trauma most frequently

involve the common carotid artery and internal jugular vein. The tumor is usually irregular and firm, and it may be diminished but not entirely obliterated by pressure. There is an intense murmur and very marked thrill present, both of which disappear when the carotid is compressed just above the clavicle.

Injuries of the Veins.—Injuries of the deeper veins, such as the innominate and subclavian, are most frequently the result of gunshot or stab wounds. Those of the internal jugular and of the superficial veins of the neck, which pass across the median line, are usually the result of attempts at suicide.

The diagnosis of an injury of a vein may be made in the same manner as in the case of injury of an artery. In the case of wounds of a larger vein such severe hemorrhage may occur as to cause immediate death. A hematoma may form beneath the skin around the wound in the vein, and in the majority of cases the patient is seen in this condition.

In wounds of the smaller veins *air embolism* may be the result. This condition is recognized from the presence of one of two groups of symptoms, either (*a*) a gurgling sound in the neighborhood of the wound, followed by immediate death, or (*b*) the onset of marked dyspnea, great anxiety, rapid and weak pulse, coma, and death within five to ten minutes.

Wounds of the veins may be recognized, as was just mentioned, either by primary symptoms, such as the escape of blood externally, the position of the wound, and the history of a gunshot or stab wound or an attempt at suicide, or it may be recognized by the formation of a hematoma or the presence of symptoms of air embolism. The secondary effects of wounds of the veins are the formation of an arterio-venous aneurysm, if the wound in the vein communicates with the one in the artery.

Another late result of injury to the vein is a secondary hemorrhage occurring from erosion of the vein.

Injuries of the Nerves of the Neck.—Injuries of the vagus may occur as the result of gunshot or stab wounds or rarely following operations. It can be recognized by the appearance of dyspnea and occasionally of hoarseness through severing of the recurrent laryngeal. At times the injury of the vagus of one side will produce no symptoms. The injury of both vagi results in aspiration pneumonia.

Injuries of the sympathetic cause dilation of the pupil on the side of the injury if above the superior ganglion.

Injuries of the phrenic cause paralysis of the corresponding half of the diaphragm. *Injuries of the brachial* plexus may occur as the result of violent blows, of fractures of the clavicle, after gunshot wounds, or as

the result of severe traction on the shoulders during birth. This last-named form may appear in children under the clinical picture of the Duchenne form of paralysis (Fig. 271). In this condition there has been laceration of the lowermost branches of the brachial plexus.

A diagnosis of injuries of the brachial plexus may be made from the appearance of trophic disturbances, of paralyses with or without painful contractures, or of neuralgias of some of the branches of the plexus, following the injuries just referred to.

Injuries of the cervical nerves are very rare and usually cause only loss of sensation, transitory in nature, of the skin of the neck.

Injury of the spinal accessory nerve often occurs as the result of operations in the posterior triangle of the neck. It may be recognized by the inability of the patient to raise the shoulder on the side of the injury (Fig. 11).

Injuries of the Thoracic Duct.—This most often follows extirpation of tumors or of lymph-nodes in the posterior triangle of the neck. It may be recognized by the escape of a thin, milky fluid from the wound, and may involve either the main duct itself or one of its branches. If it has persisted for some time, it causes considerable emaciation and weakness, due to the non-absorption of fat.

Fractures of the Hyoid Bone.—These occur after attempts at strangulation or after being run over. It may be diagnosed by the presence of swelling over the hyoid, by severe pain referred to the same region, and from the dyspnea. Not infrequently there is also great difficulty in speech and in swallowing. Hemorrhage accompanying coughing spells is also a frequent symptom.

Fractures of the Larynx.—These occur as the result of choking, of gunshot wounds, and of attempts at suicide. On palpation one can find a deformity due to a dislocation of the cartilages of the larynx and also crepitus. There is often severe cough with bloody expectoration and other symptoms referred to under fractures of the hyoid bone. One can distinguish it from a fracture of the hyoid, however, by the greater cyanosis and dyspnea. One can often feel the ends of the bone projecting through the overlying skin.

Fractures of the Trachea.—These are comparatively rare. They are the result of stab or gunshot wounds or attempts at suicide. They may be recognized by the presence of symptoms of stenosis of the air passages, such as stridor, dyspnea, asphyxia, and hoarseness. Not infrequently there is emphysema of the subcutaneous tissues. In wounds of the trachea following cut-throat, there is often suppuration of the surrounding tissue and secondary hemorrhage. The infection may

spread to the mediastinum. When the external wound is large, the diagnosis of an injury of the trachea is easy. When it is small, one can only suspect it from the presence of subcutaneous emphysema and bloody expectoration. If the wound in the trachea communicates with a wound in the esophagus, food escapes through the wound in the trachea and is expectorated by the patient.

Cut-throat.—The various conditions found in cases of cut-throat or attempts at suicide have been described in detail. A diagnosis may be made by considering the symptoms of injuries of the air passages, nerves, arteries, and veins just spoken of. The internal jugular or common carotid are seldom, if ever, injured. The typical place for the wound in the skin and deep parts is at the level of and through the cricothyroid membrane. If the wound passes into the larynx, it may sever the epiglottis and open the pharynx. At this level the lingual and superior thyroid arteries and veins and superior laryngeal nerve may be injured. If the wound is above the hyoid, the lingual and facial arteries and veins may be severed, and the tongue may fall back upon the epiglottis, causing asphyxia. If the wound is through or below the thyroid cartilage, the recurrent laryngeal may be severed, the trachea and esophagus cut across, and there may be marked asphyxia from entrance of blood into the trachea. The late complications of wounds at this latter level are cellulitis, mediastinitis, pneumonia, and fistulæ of the trachea.

FOREIGN BODIES IN THE AIR PASSAGES.

The diagnosis of foreign bodies in the larynx must be made from the history and the presence of symptoms of stenosis or irritation. These latter are violent coughing, recurrent attacks of suffocation, cyanosis, hoarseness, or aphonia. The sputum is at first bloody and then purulent. If the foreign body is a solid one it may act as a ball-valve, being drawn downward during inspiration and pushed up during expiration. The symptoms of stenosis are in general most marked during inspiration.

Foreign Bodies in the Trachea or Bronchi.—The diagnosis depends (*a*) upon the history (one must ascertain how the foreign body entered the air passages) and (*b*) upon the presence of certain local symptoms. These latter are wheezing sounds in the bronchi, accompanied by diminished respiratory movement upon the side on which the foreign body is situated, and diminished fremitus. Often there is partial or entire collapse of the corresponding lung.

In the case of metallic substances an *x*-ray picture will often show their exact location (Fig. 93). In the case of non-metallic substances one must depend upon a search for them with the bronchoscope, an instrument devised by Killian.

INFLAMMATORY PROCESSES.

Inflammatory processes in the neck may be either acute or chronic. The majority of the latter are tuberculous or actinomycotic in nature. The tuberculous form will be taken up in connection with inflammation

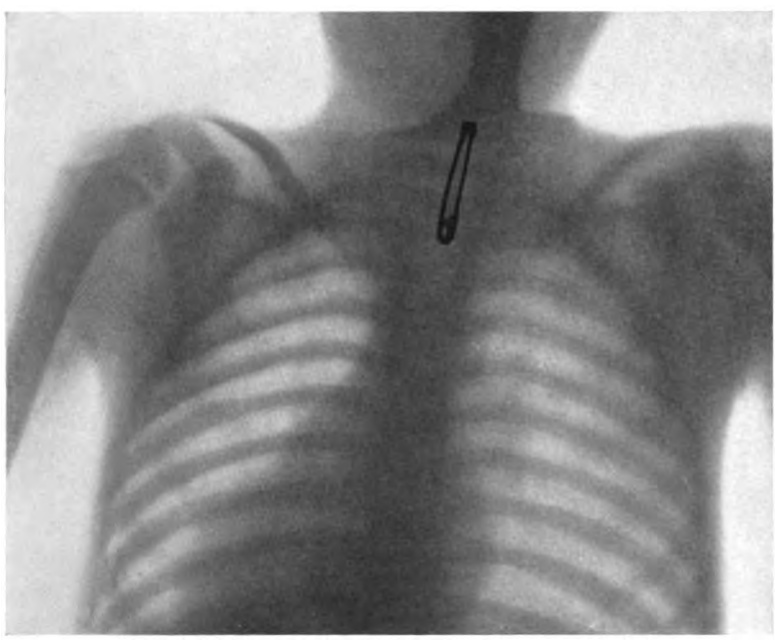

FIG. 93.—X-RAY OF SAFETY PIN OF MEDIUM SIZE IN TRACHEA REMOVED BY TRACHEOTOMY AFTER INEFFECTUAL ATTEMPTS TO USE THE KILLIAN BRONCHOSCOPE.
The outlines of the pin have been strengthened in black.

of the lymph-nodes. Acute inflammatory processes may arise in the neck in four different ways:

1. Infection of wounds of the skin or soft parts.
2. Extension from infection in the mouth, or from the arm, or thorax, or spine.
3. Infection of the lymph-nodes (this is the most frequent form).
4. Metastatic (this is quite rare).

The diagnosis of acute infective processes of the neck depends upon

a knowledge of the applied anatomy. This teaches that there are four places in which infection most frequently occurs, as follows:

1. In the submaxillary region. In this the submaxillary lymph-nodes lying within the pocket of deep fascia (Fig. 76) in which the submaxillary salivary gland is contained are affected, and from this focus the surrounding tissue is invaded.

2. The previsceral form. In this the tissue in front of the trachea and esophagus lying beneath the deep layer of the deep cervical fascia is involved.

3. The connective tissue along the carotid sheath. Infection occurs most frequently here from the lymph-nodes.

4. The space at the lower end of the sterno-cleidomastoid and just above the clavicle.

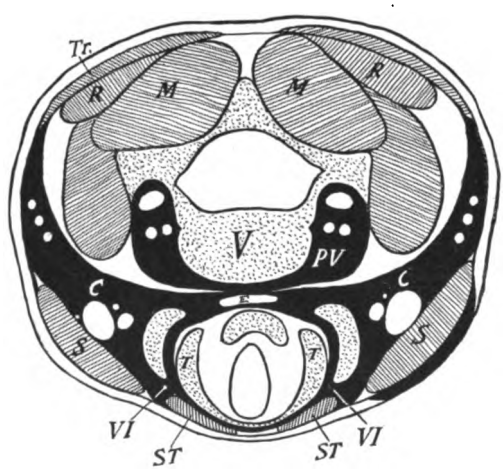

FIG. 94.—MODE OF EXTENSION OF INFECTION IN DEEP CERVICAL FASCIA.

ST, Sternothyroid and hyoid muscles; *S*, sternocleidomastoid muscle; *R* and *M*, deep muscles at back of neck; *Tr*, trapezius muscle; *V*, body of cervical vertebra; *C*, structures of carotid sheath; *E*, esophagus; *T*, thyroid cartilage, and opening of larynx; *VI*, connective tissue of free visceral space (the black shading shows direction in which pus can spread); *PV*, mode of spreading of pus in prevertebral layer.

1. **Infection in the Submaxillary Region.**—The diagnosis of infection of the submaxillary region may be made from the presence of great swelling, of a tense infiltration of the surrounding tissues, and tenderness. The swelling is accompanied by heat and redness. There is also dysphagia or difficulty in swallowing from pressure on the esophagus and dyspnea in the more extensive cases of infection. The dyspnea, owing to pressure on the larynx and trachea, may be even so severe as to cause edema of the glottis or asphyxia.

The floor of the mouth is swollen and the tongue is elevated. In severe cases ulceration of the arteries, rarely of the veins, or a phlebitis of the internal jugular may occur. If no surgical relief is given, suppuration may extend to the mediastinum along the previsceral or carotid sheath spaces. In ordinary cases of infection in this region the suppuration is simply confined to the lymph-nodes.

2. **Previsceral Suppuration.**—The majority of the infections of

the cellular tissue of the previsceral space (Fig. 94) arise from the thyroid gland, or as extensions from suppuration in the submaxillary or carotid sheath spaces. The diagnosis can be made from the presence of edema, usually of a tense character, of redness, pain and the ordinary signs of infection, such as temperature, and, in the severer cases, symptoms of sepsis. There is great danger of pressure on the trachea and esophagus, especially on the former, and of extension of the suppuration to the anterior mediastinum, with which this previsceral space communicates. The presence of this extension to the mediastinal connective tissue can be recognized by the continuance of the temperature and evidences of sepsis after subsidence of the inflammatory disturbances in the previsceral space, as well as the extension of the local inflammatory signs to the suprasternal fossa and the tissues over the sternum. This condition is referred to more fully in the chapter upon the thorax.

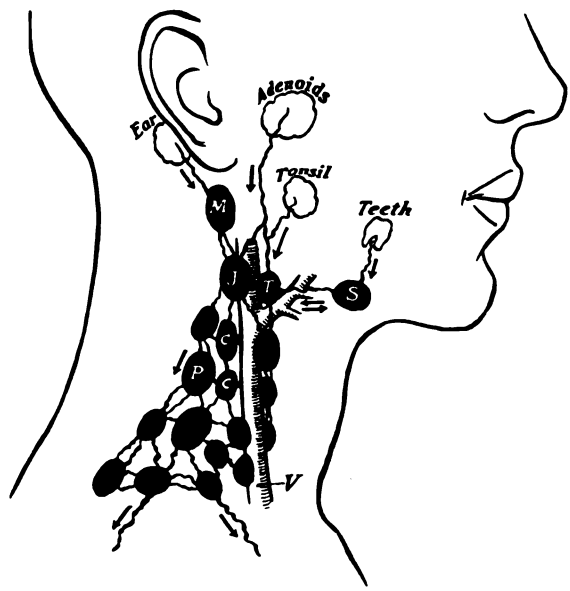

FIG. 95.—PORTALS OF INFECTION AND THE MOST FREQUENT NODES INVOLVED IN TUBERCULOSIS OF THE CERVICAL LYMPH-NODES.

The arrows show the direction of the efferent lymph-vessels leading from the various portals of infection toward the respective nodes which are first infected: *M*, Uppermost node of internal jugular vein which receives the infective material from the ear; *T*, tonsillar gland located in angle of internal jugular and anterior jugular. This receives the lymph from the tonsil. From *J* downward are to be seen the principal lymph-nodes of the neck which receive the lymph from the head and face. These are the internal jugular group lying beneath the sternocleidomastoid muscle in close relation to the internal jugular vein (*V*) and in direct connection with the lymph-nodes of the posterior triangle of the neck (*P*). *S*, Submaxillary nodes. These lie either upon or within the capsule of the submaxillary salivary gland and receive the infective material from the teeth and jaws, but may be infected by retrograde currents from the tonsillar lymph-nodes. *C*, Two nodes are shown with their short venous branch leading into the internal jugular.

3. **Suppuration in the Carotid Sheath Space.**—The most frequent sources of infection of this space are the lymph-nodes lying beneath the sternocleidomastoid muscles and along its anterior and posterior borders. These suppurative inflammations of the lymph-nodes *are always secondary to a primary infective focus in the territory drained by them.* In the case of the upper internal jugular

group the primary focus is usually to be found in the pharynx. It may, however, be the direct result of extension from infection of the submaxillary lymph-nodes. In the lower internal jugular group (Fig. 95) the infection may have had its origin in the skin of the supraclavicular fossa. It is well to remember, from a diagnostic standpoint, that the primary focus in every form of suppurative lymph-node infection may have entirely healed and the presence of such a primary focus be forgotten by the patient when he is examined. In the case of the infective cellular inflammations along the carotid sheath, the patient presents himself with a swelling most marked either along the anterior or posterior border of the sternocleidomastoid. If the infection is extensive there is usually a wry-neck, referred to on page 151, edema of the overlying skin, dyspnea, and dysphagia. If the upper internal jugular set is affected, the swelling is usually between the angle of the jaw and the sternocleidomastoid muscle. If the lower set is involved, the swelling is most marked at the posterior border of the muscle just above the clavicle. In severe cases there are symptoms of constitutional sepsis, such as high temperature, rapid pulse, a high degree of delirium, and great prostration. In addition there may be dyspnea and difficulty in swallowing through pressure on the trachea and esophagus. If the condition is not relieved, the pus will either escape to the surface and break through the skin, or find its way to the anterior mediastinum.

Infection of the Superficial Structures of the Neck.

The most frequent form of superficial infection which occurs in the skin of the neck is a furuncle, which may occur at any portion, but especially in the region just beneath the superior curved line of the occipital bone, that is, at the nape of the neck. The area involved may be extensive, there being multiple foci of the suppuration. The term carbuncle is given to this form by the laity.

The diagnosis of this condition is not difficult. The chief point to be remembered, however, is the possibility of the infection extending to the lymph-nodes along the carotid sheath or in the posterior triangle of the neck, referred to later. This infection of the lymph-nodes may be present quite early in an ordinary furuncle, as a nodular enlargement along the borders of the sternocleidomastoid muscle. This nodule will frequently subside as soon as the furuncle has healed. In other cases two or three weeks after healing of the furuncle, these deep lymph-nodes begin to enlarge and suppurate. The diagnosis of this complication is referred to later.

A number of other infective inflammations occur in the neck, whose recognition is of great importance.

The Woody Phlegmon, or Phlegmon Ligneux of Reclus.—This occurs either in the lateral or anterior regions of the neck. It is characterized by a very chronic course and involves a large area of skin and subcutaneous tissue. There are but few inflammatory symptoms. The skin is red and extremely hard, almost woody in consistency, hence the term woody phlegmon. Later this induration becomes softer and there is pus formation.

Actinomycosis.—The neck is more frequently affected than any other portion of the body, after the jaw and teeth. The disease usually arises by direct extension from primary foci in the jaw or teeth. It can be recognized by the appearance of a slowly increasing, painless swelling in the submental and submaxillary regions, which is at first quite indurated, but soon softens, and the abscess breaks, leaving a sinus lined with flabby granulation-tissue, containing the characteristic yellowish granules. There is a distinct bluish color over the softer areas. The diagnosis can be made usually (*a*) from the history of the occurrence of similar abscesses around the jaw, (*b*) from the characteristic tense infiltration of the deeper connective tissue of the neck, with abscess and sinus formation. There are two conditions which must be differentiated from it. The first is tubercular inflammation of the lymph-nodes, and the second, tertiary syphilitic gummata. The former can be distinguished from the fact that the area involved by actinomycosis is larger than is the case in tuberculosis.

Tuberculosis is usually limited to certain definite groups of lymph-nodes, either the submental, submaxillary, or deep cervical, which, if they break down and form sinuses, differ in their external appearance from actinomycosis. The tubercular sinuses have undermined edges, and the granulations, although flabby, are often caseous in appearance. The finding of the actinomyces in the yellow granules of the pus will confirm the diagnosis of actinomycosis. There is often a history of cattle infected with the disease, which the patient has been taking care of. From tertiary syphilitic gummata the differentiation is comparatively easy. These, when they give rise to ulceration of the skin, have indurated edges and the ulcer is usually extensive. The edges are sharp or steep and are not undermined. There is also a history of an initial lesion or the evidences of the disease elsewhere.

Affections of the Lymph-nodes of the Neck.

These may be either primary or secondary, acute or chronic. The lymph-nodes of the neck, as elsewhere in the body, act as filters for infective agents brought to them from the territory which they drain. If one bears this in mind, the diagnosis of affections of the lymph-nodes in any portion of the body becomes much simpler and is a valuable diagnostic aid (Fig 95).

Acute Inflammation.—With the exception of the quite rare acute

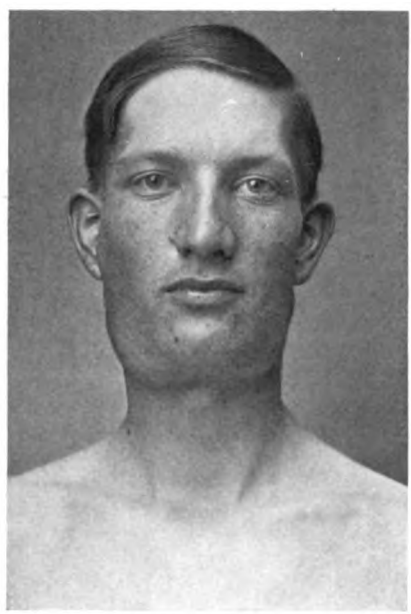

Fig. 96.
Bilateral enlargement of the submaxillary and parotid lymph-nodes in Hodgkin's disease.

Fig. 97.—Side View of Patient with Hodgkin's Disease.
Observe the large submaxillary glandular swelling as well as the relatively large size of the nodes lying over the parotid salivary gland.

and subacute forms of tubercular inflammations of the cervical lymph-nodes, all of the acute infective processes belong to one of two groups.

1. Acute infection of the submaxillary and deep cervical or internal jugular lymph-nodes. These are almost invariably secondary to infections of the tonsils, either the faucial or pharyngeal tonsil, or due to carious teeth.

2. Those of the deep cervical chain. These are either secondary to furuncles in the skin or to infective processes of the pharynx. The

diagnosis of both of these forms is comparatively easy and has been referred to on pages 158 and 159.

Chronic Enlargements of the Cervical Lymph-nodes.—The cervical lymph-nodes are more frequently enlarged than those of any other portion of the body and in the majority of cases this is due to the tubercle bacillus. The different forms of chronic enlargements of the lymph-nodes of the neck belong to one of the following groups:

(*a*) Simple hyperplastic lymph-node inflammation.

FIG. 98.—ANTERIOR VIEW OF CASE OF MARKED HODGKIN'S DISEASE.

FIG. 99.—VIEW OF CASE OF HODGKIN'S DISEASE. Showing both cervical and axillary node enlargement.

(*b*) Tuberculosis of the cervical lymph-nodes:

1. The acute progressive form.
2. The subacute or pseudo-leukemic form.
3. The chronic form.

(*c*) Pseudo-leukemia or Hodgkin's disease.

(*d*) Lymphatic leukemia.

(*e*) Lymphosarcoma.

(*f*) Secondary carcinomatous lymph-nodes.

(*g*) Syphilis of the cervical lymph-nodes.

In examining any case in which by a process of exclusion of other forms of tumors of the neck (see page 172) one has arrived at the con-

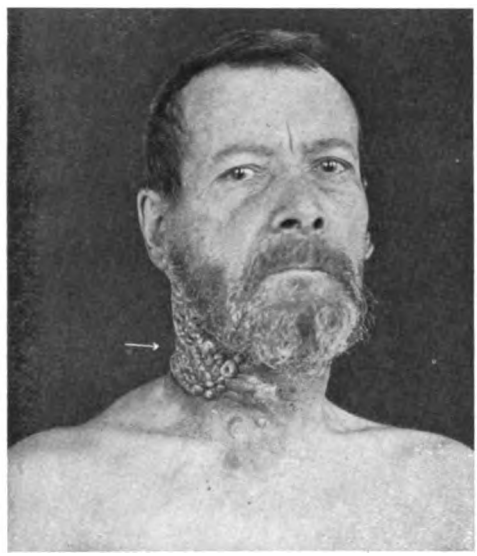

FIG. 100.—PRIMARY BRANCHIOGENIC CARCINOMA OF NECK (anterior view).

Observe the involvement of the skin at a point slightly distant from the original focus.

clusion that the enlargement is due to the lymph-nodes, the first question to be considered is, are these lymph-nodes primary or secondary in nature?

The majority of all enlargements of the lymph-nodes of the neck are secondary in nature, only a small percentage being primary. In this manner one can first exclude, in any given case, the so-called primary forms, which are as follows:

(*a*) Lymphatic leukemia.

(*b*) Lymphosarcoma.

(*c*) Pseudo-leukemia (Hodgkin's disease), or malignant lymphoma.

The chief characteristics of these primary enlargements are the following:

Lymphatic Leukemia.—In this disease the enlargement of the lymph-nodes is usually quite extensive, being distributed over both sides of the neck, as well as over the axillary and inguinal regions. The glands themselves are soft and quite movable. There is no tendency to any adhesion of the individual glands to each other or to the surrounding tissue. There is also no tendency to softening, as is the case with tuberculous enlargements. The examination of the blood will show the presence of a very large number of lymphocytes, so that the proportion of white to red corpuscles, instead of being

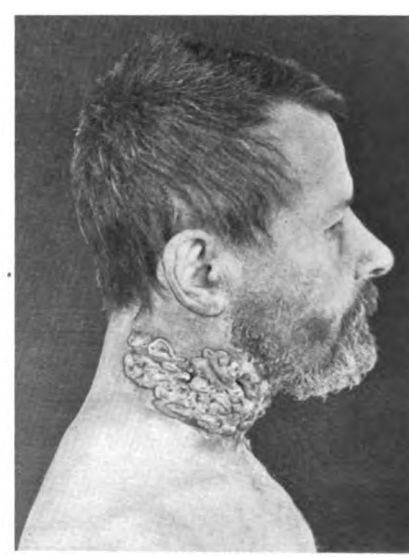

FIG. 101.—LATERAL VIEW OF A CASE OF BRANCHIOGENIC CARCINOMA OF THE NECK.

Note the serpentine raised edges and the ulcerating centers.

one to five hundred, is sometimes one to two. The disease may occasionally begin in a very acute manner with fever, etc. (acute lymphatic leukemia).

Lymphosarcoma.—This disease usually begins in one node, which enlarges rapidly. The growth soon infiltrates the surrounding tissue

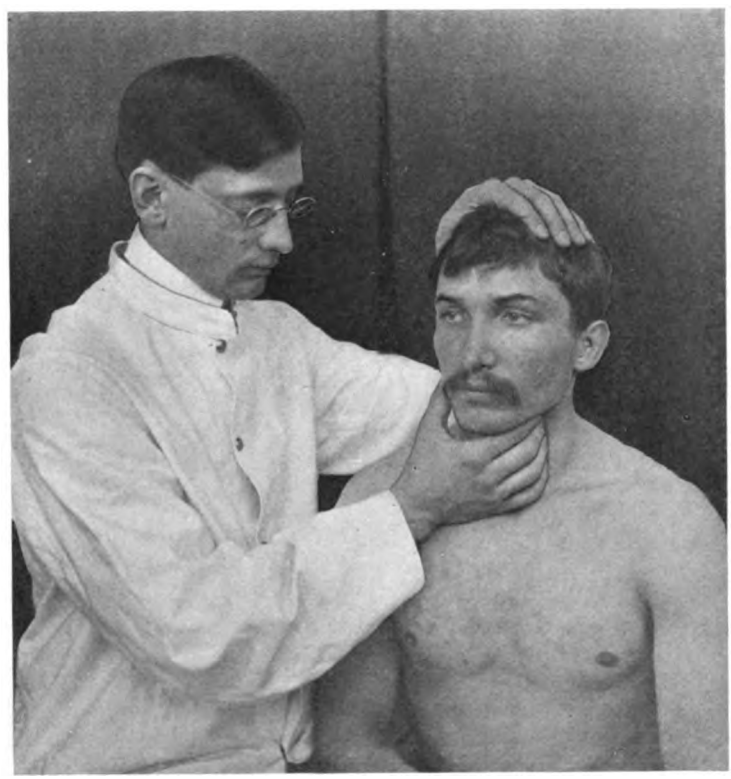

FIG. 102.—METHOD OF EXAMINATION FOR ENLARGEMENT OF THE DEEP CERVICAL LYMPH-NODES ALONG THE BORDERS OF THE STERNOCLEIDOMASTOID MUSCLE.

Both patient and examiner should be seated, the latter sitting upon the right side of the patient, when the size and number of the nodes of the left side is to be determined and vice versâ in the case of the right side. The patient's head should be grasped with one hand, while the other hand is inserted along the anterior border of the sternomastoid, the muscles of the neck being relaxed by bringing the patient's chin down somewhat toward the sternum.

and there is early ulceration of the skin over the tumor. Very early in the disease there are evidences of metastases in distant parts of the body.

The tumor is always movable on the deeper structures, so that it can be distinguished from sarcomata arising from these. The diagnostic points are the rapid growth of the tumor and its firm consistency.

It is much harder than tuberculous lymph-nodes and has a marked tendency to ulceration.

Pseudo-leukemia, or Hodgkin's Disease.—This may occasionally appear in an acute form, but more frequently in a chronic. The nodes become enlarged at first on one side of the neck and soon afterward those of the other side are affected. This is accompanied by enlargement of the axillary and inguinal lymph-nodes, and later of the bronchial, mediastinal, and mesenteric. This form of enlargement of the lymph-nodes is progressive in character. It affects the lymph-nodes all over the body, usually more or less symmetrically. There is no tendency to suppuration although the lymph-nodes themselves are soft. They are easily movable in the surrounding tissue, and do not become adherent to the skin, which is movable over it. Often different nodes of one group become adherent to each other, forming quite large tumors, which can be recognized as lymph-nodes by their nodulated, soft consistency and their location along the usual area of distribution of the cervical lymph-nodes. The enlargement is painless as a rule and not accompanied by temperature.

FIG. 103.—METHOD OF DETERMINING FLUCTUATION IN SUPPURATING LYMPH-NODES OF THE NECK.

The diagnosis of this form can be made from (*a*) the symmetrical distribution of the lymph-node enlargement, (*b*) the absence of any tendency to break down, and (*c*) the progressive involvement of lymph-nodes all over the body, which later in the disease cause pressure symptoms.

These are dyspnea through pressure on the trachea, or dysphagia through pressure on the esophagus, or, in the abdomen, ascites. There is usually accompanying anemia and cachexia. There are no changes in

the blood except a progressive anemia, thus serving to distinguish it from lymphatic leukemia. There is great difficulty in differentiating a true case of pseudo-leukemia or malignant lymphoma (Hodgkin's disease) from the pseudo-leukemic form of tuberculous inflammation of the lymph-nodes. This is referred to on page 171.

If, in a case of enlargement of the lymph-nodes of the neck, one has excluded these three primary forms of lymph-node enlargement, the diagnosis must be further made by excluding one after the other of the following secondary forms:

(*a*) Carcinomatous.

(*b*) Syphilitic.

(*c*) Tubercular.

(*d*) Simple hyperplastic.

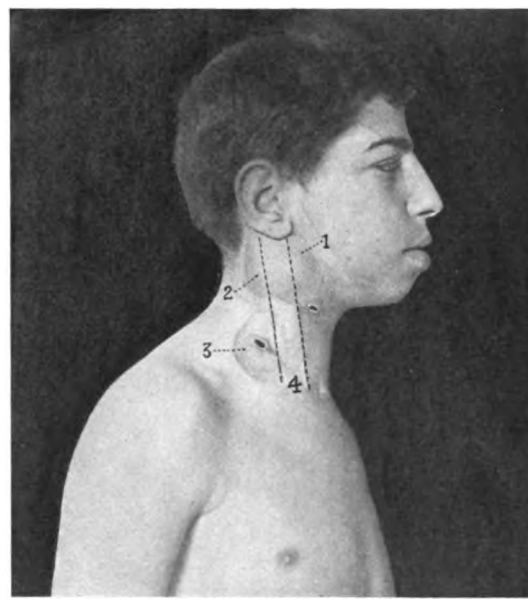

FIG. 104.—THE RELATION OF TUBERCULOUS LYMPH-NODES OF THE NECK TO THE STERNOCLEIDOMASTOID MUSCLE.

1, Several large nodes which are fused together, lying in front of the muscle, extending as far forward as the angle of the jaw; the black area at the lower level of this mass indicates a sinus covered with tuberculous granulation-tissue; 2, a similar mass situated in the upper portion of the posterior cervical or occipital triangle, between the upper ends of the sternocleidomastoid and trapezius muscles; the sternocleidomastoid muscle usually lies superficial to such glandular masses, the latter being adherent to the deep vessels; 3, mass of nodes at lower portion of posterior cervical triangle (subclavian triangle); the black area at the center of this mass is a sinus similar to the one in relation to the other nodes; 4, outlines of sternocleidomastoid muscle.

(*a*) *Carcinomatous*.—These appear in the neck as an early manifestation of the presence of a carcinoma in the respective territories drained by the cervical lymph-nodes (Fig. 95). The primary carcinoma may be comparatively easily found, so that the diagnosis is not difficult. But there are cases where the secondary lymph-node involvement is the first evidence that a carcinoma exists and this latter may be quite small. The characteristics of carcinomatous lymph-nodes are that they are extremely hard, the skin is movable over them, and they are easily movable upon the underlying and surrounding structures. The enlargement may be confined to the lymph-nodes of one region (Fig. 75),

for example, submaxillary or submental, or may be present on both sides of the neck.

The diagnosis can be made (*a*) from the extremely firm consistency of the tumors situated in places where the various lymph-nodes are normally found, (*b*) the age—usually above forty, (*c*) presence of cachexia, (*d*) negative findings in the blood, and (*e*) the discovery of the primary focus. In the later stages, when ulceration of the overlying skin has taken place, the case may impress one as a primary carcinoma of the neck, but these are extremely rare, and are always due to a branchiogenic carcinoma (Fig. 100). In some cases one is justified in making a diagnosis of a primary growth if a careful search has failed to reveal any other primary focus. The only conditions which could be confused with carcinomatous lymph-nodes are those cases of primary branchiogenic carcinoma which have not broken through the skin. These are always deeply situated along the middle of the sternocleidomastoid, but differ from secondary carcinomatous lymph-nodes by being firmly attached to the deeper structures of the neck. In every case of suspected carcinomatous enlargement, one should examine systematically the various structures of the head where a primary carcinoma occurs, not omitting a search in the sinus pyriformis, anterior wall of the pharynx, and interior of the larynx.

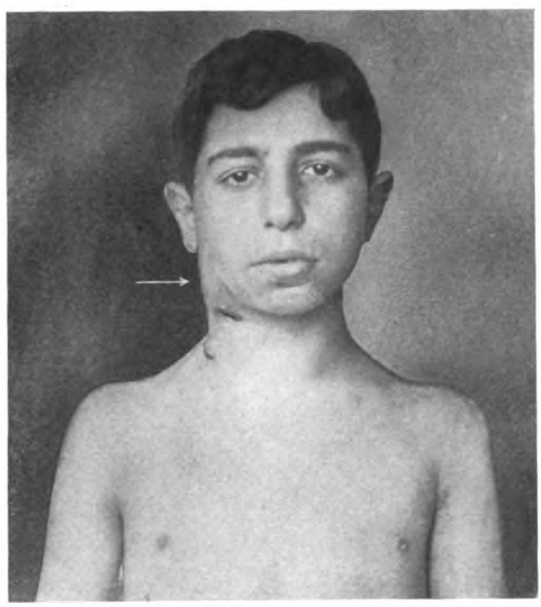

FIG. 105.—TUBERCULOUS LYMPH-NODES OF THE NECK.

Observe the prominence just below and behind the angle of the jaw, to which the arrow points. The black area at the lower edge of the swelling and a similar area at the lower portion of the neck are two sinuses lined with yellowish granulation-tissue, characteristic of tuberculosis.

(*b*) *Syphilitic Lymph-node Enlargement.*—These occur in the primary stage, secondary to a chancre of the lips, tongue (Fig. 81), or other forms of extragenital infection of the head or neck. The finding of the primary

focus and its recognition as syphilitic in nature will render the diagnosis easy. In the secondary stage of syphilis there is occasional enlargement of a few of the lymph-nodes of the neck. The presence of secondary eruptions on the skin or mucous membrane often accompanies this condition and in their absence the only forms which need to be differentiated from them in this stage are simple hyperplastic lymph-nodes, which are usually much firmer and smaller. In the tertiary stage one will encounter quite rarely, enlargement of the deep cervical or internal jugular lymph-nodes, which cannot be distinguished, in the absence of a history of syphilis, from simple hyperplastic or tubercular nodes until ulceration of the skin has occurred. At such a time the aspect of the ulcer will clear up any doubt about the diagnosis. It has the typical appearance of the syphilitic processes in the tertiary stage. The edges are somewhat copper-colored and indurated, but not as much so as in the case of a carcinoma. They show the characteristic steep edges of a syphilitic ulcer and the ulceration is always more extensive than in the case of tuberculosis. In doubtful cases the administration of iodid of potassium will cause a speedy healing of the enlarged gland or ulcer, as the case may be.

FIG. 106.—ENLARGEMENT OF THE SUBMENTAL LYMPH-NODES, THE RESULT OF TUBERCULOUS LYMPHADENITIS.

(*c*) *Tuberculous Lymph-node Enlargement.*—As a rule, tuberculosis of the cervical lymph-nodes appears in a chronic form, with the following clinical picture: In the submaxillary region or along the anterior or posterior borders of the sternocleidomastoid, or in the posterior triangle of the neck, one finds slowly enlarging, soft, non-adherent tumors, which soon coalesce, becoming adherent to each other, and to the surrounding

tissues and skin. This adhesion of the skin may not take place until the enlargement has become quite advanced. At an early period there is softening and pus formation and the caseous gland becomes adherent to the surface (Fig. 103), fluctuation becoming distinct. Unless surgical measures are undertaken at this stage, the pus discharges through the skin and a tubercular sinus forms. The diagnostic points of the chronic form of tuberculous lymph-nodes are the slowly-forming, soft tumors, which show a great tendency to softening and pus formation. There are no evidences of inflammation of the overlying skin until the node becomes adherent to it, when the skin becomes of a bluish color, and there is quite distinct fluctuation. Before making a positive diagnosis, however, of tuberculous infection, a careful search should be made for primary foci such as a pharyngeal tonsil (adenoid vegetations), or of enlarged caseous tonsils, or of a chronic middle ear suppuration. These three are the most frequent infection atria for tuberculous cervical lymph-nodes. The less frequent ones are the teeth and tongue. If a sinus has formed, it can be recognized as tuberculous by its bluish undermined edges and the presence of flabby, caseous granulations lining the opening in the skin. This form of lymph-node enlargement occurs most frequently during the first twenty years of life, but must be thought of in examining any case, even at a later period. The *acute form* is fortunately quite rare. The clinical picture is that of a rapid enlargement of the submaxillary and deep cervical lymph-nodes, accompanied by a high continued fever, with morning remissions in some cases. In others there is only a moderate degree of fever. It can be differentiated from the other acute forms of infective lymph-node inflammation by the absence of a primary pus focus in the skin or mucous membrane.

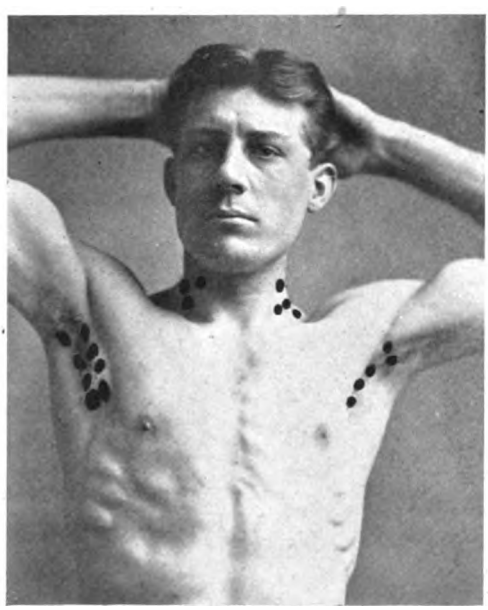

FIG. 107.—DISTRIBUTION OF ENLARGED LYMPH-NODES IN A CASE OF THE PSEUDO-LEUKEMIC FORM OF TUBERCULOUS LYMPH-NODES.

There is also less pain and swelling of the surrounding structures. The nodes soon become adherent to each other, pus formation occurs, and the course of the disease, such as sinus formation and discharge through the skin, is the same as in the chronic form. During epidemics of so-called glandular fever, more properly called Pfeiffer's disease, such cases of acute tuberculous cervical lymph-nodes are apt to be interpreted as this disease, and vice versâ. *Pfeiffer's disease* is usually accompanied by more constitutional symptoms, such as a rapid pulse and higher temperatures, there is little tendency to breaking down of the glands, and they do not become adherent to each other. There is not infrequently the history of an epidemic of this disease.

The *pseudo-leukemic or subacute form of tuberculous lymph-node enlargement* greatly resembles (Fig. 107) true pseudo-leukemia or malignant lymphoma. It involves not infrequently lymph-nodes on both sides of the neck as well as those of the axillary and inguinal regions, but there is not the same tendency to progressive enlargement as is the case with true pseudo-leukemia. The only crucial test in moderately advanced cases is by the excision of one of the nodes, and its inoculation into a guinea-pig. This pseudo-leukemic form of tuberculous lymph-node inflammation has been fully described by Fischer. Its clinical recognition is of considerable importance, as many such cases are erroneously diagnosed as true pseudo-leukemia. The characteristic difference between the two is the less marked enlargement of the lymph-nodes in tuberculosis, the fact that the mediastinal and abdominal nodes are never involved, and that there are no pressure symptoms, anemia, or cachexia.

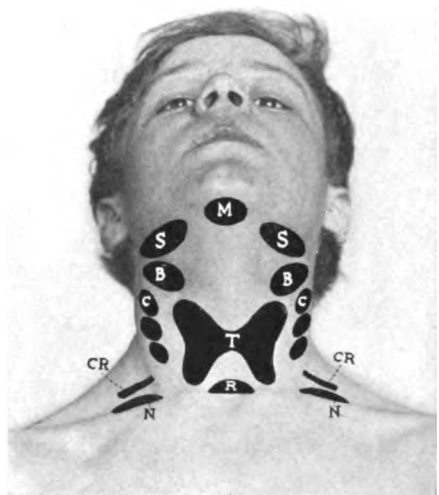

FIG. 108.—ANTERIOR VIEW OF LOCATION OF VARIOUS FORMS OF TUMORS OF THE NECK (diagrammatic).

M, Dermoid cysts and enlargements of the submental nodes; *S*, tumors and inflammatory enlargements of the submaxillary lymph-nodes and salivary glands; *B*, most frequent location of branchial cysts and parathyroids; *C*, enlargements of the deep cervical lymph-nodes; *T*, tumors of the thryoid; *CR*, cervical rib; *N*, subclavian aneurysms; *R*, retrosternal goiter.

The differentiation of chronic tuberculous lymph-nodes must be made (*a*) from syphilitic, (*b*) from malignant (most often lymphosarcoma, rarely carcinoma), (*c*) from pseudo-leukemic, and (*d*) from leukemic

enlargement. This differentiation has been referred to under the separate groups.

Simple Hyperplastic Lymph-nodes.—This last form of lymph-node enlargement is characterized by the presence of painless soft nodules, in the usual location of the cervical lymph-nodes. Rarely they are firmer in consistency. The diagnosis can be made from the fact that they are painless, show no tendency to breaking down, are freely movable, not matted together, and cause no symptoms.

TUMORS OF THE NECK.

Examination.—In examining a tumor of the neck for diagnostic purposes one should conduct the examination in a systematic manner as follows:

1. The history of the case.
   - (*a*) The age of the patient.
   - (*b*) When did the tumor appear? Was it present at birth or shortly after? Did it appear at infancy, at or near puberty, middle or old age?
   - (*c*) Has the growth of the tumor been rapid or slow?
   - (*d*) Where did the tumor first show itself?
   - (*e*) History of trauma, etc.
   - (*f*) Is the tumor subject to attacks of inflammation? (This is frequently the case in lymphangiomata.)
2. Physical examination.

A. Inspection:

I. Location of the tumor. This is easy to note unless the tumor spreads over both sides of the neck. The various regions in which the tumors of the neck occur most frequently, are:

- (*a*) Submaxillary and submental regions (lymph-nodes, tumors of the jaw, dermoids of the floor of the mouth, branchial cysts, lipomata).
- (*b*) Along the course of the trachea and the larynx (goiter, thyroglossal cysts, thyrohyoid bursæ).
- (*c*) Along the carotid sheath (lymph-nodes, sarcomata (deep), aneurysms, angiomata, branchial cysts and branchiogenic carcinomata, pressure diverticula of the esophagus).
- (*d*) Supraclavicular fossa (lymph-nodes, aneurysms, osteomata, cervical rib).

(*e*) Suprasternal fossa (retrosternal goiter and aneurysms).

II. Consistency of the skin over the tumor.

(*a*) Whether it is bluish or reddened, whether stretched or adherent, whether ulcerated or marked by dilated veins.

B. Palpation:

(*a*) The consistency of the tumor. Whether it is hard or soft, semi-fluctuating, or cystic.

(*b*) Whether it is adherent or movable to the underlying tissues and skin covering it.

(*c*) Its relation to the trachea as determined by the swallowing test (see page 185)—a symptom frequently pathognomonic of goiters.

(*d*) Pressure symptoms on the trachea, vessels, or nerves, and upon the esophagus.

(*e*) Examination for the presence of expansile pulsation and thrill—a sign characteristic of aneurysm.

(*f*) Condition of surface of tumor, whether smooth or nodulated.

(*g*) Whether larger after eating and then smaller again as is the case in pressure diverticula of the esophagus.

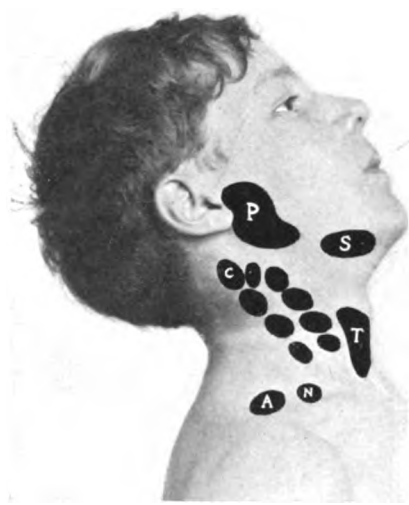

FIG. 109.—LATERAL VIEW OF MOST FREQUENT SITUATIONS OF TUMORS OF THE NECK.

P, Parotid tumors; *S*, submaxillary neoplasms and lymph-node enlargements; *T*, enlargements of lateral lobes of thyroid; *C*, the many black areas correspond to the locations of the larger of the deep cervical nodes under the sternocleidomastoid muscle and in front of and behind it; *A*, lymph-nodes in posterior triangle of neck; *N*, subclavian aneurysm.

C. Examination of Blood, Spleen, Mouth, and of Body in General.—In every case of tumor of the neck one should not omit the general examination of the patient. This should include (*a*) the mouth, ear, nose, and throat, with the aid of the special instruments required for these purposes; (*b*) the blood for evidences of leukemia, anemia, or leukocytosis; (*c*) the condition of lymph-nodes in other parts of the body,

e. g., the axillæ, inguinal regions, pelvis, and mesentery; (*d*) the spleen, whether enlarged or not, as a part of the clinical picture of a pseudoleukemia or of some cases of lymphatic leukemia; (*e*) the presence or absence of cachexia, etc.

D. Auscultation and Percussion.—These are of little value in the diagnosis of tumors with the exception of the bruit heard over aneurysms of the common carotid and subclavian arteries.

Classification.—Tumors of the neck are most conveniently divided into the cystic and solid varieties for diagnostic purposes.

	Cystic.	Solid.
I. Those which are congenital in origin.	1. Branchial cysts.	1. Lipoma—diffuse or symmetrical.
	2. Thyroglossal cysts.	2. Fibroma.
	3. Lymphangioma cysticum.	3. Lymph-nodes—tuberculous, syphilitic, or leukemic, lymphosarcoma (see page 165).
	4. Hemangioma cavernosum and blood-cysts.	4. Osteoma.
II. Non-congenital....	5. Thyrohyoid bursæ.	5. Chondroma.
	6. Cystic goiter.	6. Sarcoma, including carotid tumors.
	7. Diverticula of the esophagus.	7. Carcinoma— Primary: From the skin or branchiogenic in origin. Secondary: To primary focus in head, larynx, thyroid, esophagus, or breast.
	8. Cysts of accessory or parathyroids.	8. Tumors of the submaxillary salivary gland.
	9. Echinococcus cysts.	9. Goiter, benign and malignant.
	10. Sebaceous cysts.	10. Aneurysms of common carotid or subclavian arteries.
	11. Dermoid cysts.	11. Primary tumors of the parotid extending to the neck.
	12. Suppurating lymph-nodes (most often of a tuberculous nature).	12. Accessory thyroids or parathyroids.

Cystic Tumors.

The chief characteristics of the various forms of cystic tumors of the neck are:

1. **Branchial Cyst.**—These are generally located in the submaxillary region (Fig. 110) or along the middle of the inner border of the sternocleidomastoid. It has the sensation of a tense cyst, is oval, and

is firmly attached to the deeper tissues. The skin is movable over it

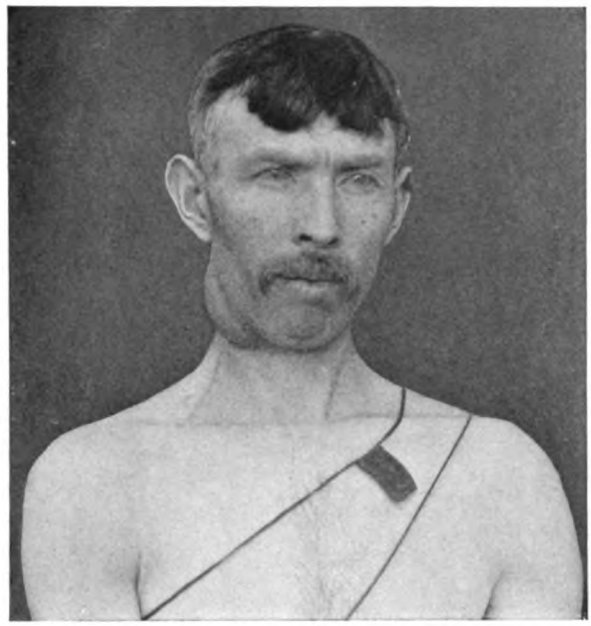

FIG. 110.—FRONT VIEW OF BRANCHIAL CYST.

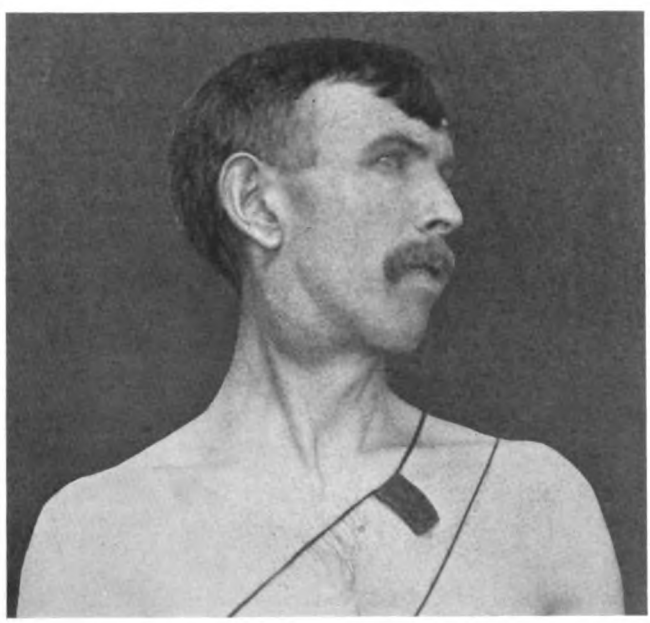

FIG. 111.—SIDE VIEW OF A UNILOCULAR BRANCHIAL CYST.
Observe its position in the superior carotid triangle of the neck.

unless suppuration has occurred. They appear at birth but may not begin to enlarge sufficiently to be recognized until adult life. The contents may be serous, mucoid, or sebaceous. They are most often monocular.

2. **Thyroglossal Cysts.**—These are always in the median line between the hyoid bone and the middle of the trachea. They are monocular like the branchial cysts, are usually small, and move upward when the patient swallows. They cannot be distinguished from cystic lymphangioma, except by microscopic examination.

3. **Congenital Cystic Lymphangioma.**—These may occur either as monocular or multilocular tumors, most frequently situated in the submaxillary region. Less often they are found beneath the occiput and in the supraclavicular region. They arise from dilated lymph-vessels and vary from a small tumor to one occupying half of the neck (Fig. 112). They push their way like the hemangiomata between various structures of the neck, but rarely cause compression symptoms. They are, however, subject to recurrent attacks of inflammation, during which they increase in size and the skin over them becomes reddened.

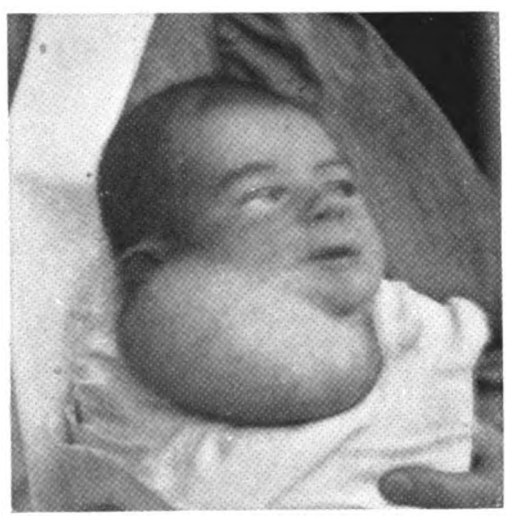

FIG. 112.—CONGENITAL CYSTIC LYMPH HEMANGIOMA OF NECK.

They are almost always present at birth. They cannot be differentiated from those branchial cysts of the submaxillary region which are present at birth except by the fact that their contents is a clear serous fluid while that of the branchial cysts may be pure serum or mucus or sebaceous material with or without hair.

4. **Hemangioma.**—This variety of tumor occurs in two forms in the neck:

(*a*) *Simple and Cavernous Hemangiomata.*—These are multilocular and may occupy one side of the neck (Fig. 112), contain blood and grow in all directions but rarely cause pressure symptoms.

(*b*) *Unilocular or Blood-cysts.*—They vary from a walnut to a child's head in size, are movable, and not attached to the skin. They often cause pressure symptoms such as dyspnea and dysphagia. They must be differentiated from aneurysms, cavernous angiomata, and lipomata. In the first-named there is a bruit, thrill, and expansile pulsation. In the cavernous angiomata there is a history of their presence at birth and they are multilocular. The lipoma is firmer and quite rare in the regions in which blood-cysts are found.

5. **Thyrohyoid Bursæ.**—These occur most frequently over the thyroid cartilage (bursa antethyroidea) or on the thyrohyoid membrane. They are the size of a small nut and accompany the movements of the thyroid in swallowing, and are apt to be painful at times in rheumatic persons. They must be differentiated from cysts of an aberrant thyroid.

6. **Cystic Goiter.**—This usually involves one or both of the lateral lobes of the thyroid. It may be of large size and cause considerable elevation of the skin (Fig. 113). It gives a distinct sense of fluctuation.

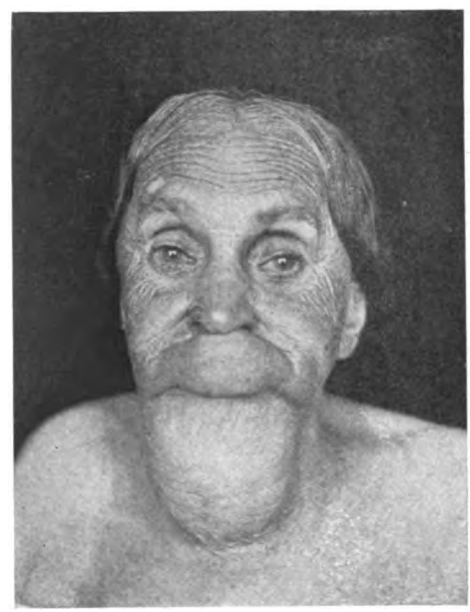

FIG. 113.—ANTERIOR VIEW OF AN ENORMOUS CYSTIC GOITER.

It occupied all the space between the sternocleidomastoid muscle on either side, the lower jaw above, and the sternum below, and contained a brownish gelatinous fluid with cholesterin crystals.

7. **Diverticula of the pharynx or esophagus** are always on the left side and there is a history of their alternately full and empty condition. They are quite rare in the neck.

8. **Cysts of the Accessory Thyroids and of Parathyroids.**—These are found in the typical location of these structures (Fig. 108) and are quite small and appear usually after the age of puberty.

9. **Echinococcus cysts** are quite rare and are found close to the sheath of the carotid vessels or in the sternomastoid itself. They cannot be differentiated from tuberculous lymph-node abscesses except from the history of a solid tumor which has softened and is quite adherent. This speaks for tuberculosis.

10. **Sebaceous Cysts.**—These are quite superficial, small, and stretch the overlying skin over it considerably. They may also be adherent to the skin.

11. **Dermoid cysts** occur in the median line, especially just below the chin. They are firmer and more doughy in consistency than any of the other cysts occurring in these locations.

SOLID TUMORS.

1. **Lipomata.**—These usually occur at the back of the neck as subcutaneous soft tumors, not adherent to the skin. They are usually more or less fixed at their base and when the skin is stretched over them during examination, showing a distinct diversion into lobules. They may attain an enormous size.

FIG. 114.—LARGE CYSTIC GOITER.
Extending from level of lower jaw almost to sternum. This patient also had a marked kyphosis, due to old age. (Side view of same patient shown in Fig. 113.)

A form of diffuse lipoma (Fig. 115) may occur in which the fatty tissue grows indiscriminately between the other structures of the neck, burrowing between the muscles and vessels. This condition may be present in connection with a peculiar form of multiple fatty tumors situated more or less symmetrically over the entire body and called symmetrical lipomatosis. A deep or subfascial form also rarely occurs which simulates the softer forms of solid tumors, such as goiter or tense cystic tumors.

2. **Chrondromata** are very rare and arise from aberrant islands of cartilage. The skin is movable over them and their firm consistence, like that of the cartilage of the nose, renders their diagnosis easy. They occur in young people.

3. **Osteomata** usually occur in the lower part of the neck as outgrowths from the spine, ribs, and clavicles. Their bone-like consistency, location, and fixation aid in differentiating them from every other

form of solid tumors, even without the use of the *x*-ray. The only condition which resembles an osteoma at the base of the neck is a cervical rib, which was described on page 148. Such a supernumerary rib is thinner and more frequently causes pressure of the adjacent nerves and vessels than an osteoma.

4. **Fibromata.**—These usually occur as soft pedunculated tumors of the skin, often associated with a generalized condition of fibroma molluscum (Fig. 376).

5. **Solid Tumors of the Submaxillary Salivary Gland** (Fig. 116).—These appear in the typical location of the submaxillary salivary gland on the inner side of the body of the lower jaw close to the angle. They are either chondromata or mixed tumors and must be differentiated from enlargement of the submaxillary lymph-nodes due to tuberculosis or malignant disease (such as carcinoma). The former may be excluded by the firm consistency of the tumor and the latter by the absence of a primary growth.

FIG. 115.—SYMMETRICAL LIPOMATOSIS.

In this case the entire neck from the sternocleidomastoid on each side was occupied by a diffuse lipomatous tumor. Lipomata were distributed symmetrically over both deltoid regions, over the abdomen on either side of the median line, and over both gluteal regions.

6. **Goiter.**—Here the tumor is situated in the region usually occupied by the thyroid gland along either side and across the middle of the trachea (Fig. 119). It may be soft or quite firm, varying in this respect according to whether it is parenchymatous, colloid, or fibrous in character. When the patient swallows a glass of water the tumor moves upward on account of its attachment to the trachea. The skin is movable over the tumor. Goiter is considered in detail on page 185.

7. **Sarcomata.**—These arise in the deeper parts of the neck and grow toward the surface. They may arise from the following structures:

(*a*) The carotid body.
(*b*) The connective tissue of the carotid sheath.
(*c*) As lymphosarcomata from the cervical lymph-nodes.
(*d*) From the thyroid gland.

(*a*) *Sarcomata Arising from the Carotid Body* (also called Luschka's gland).—They are usually endotheliomata and appear in middle-aged or old people. The tumor is of very rapid growth and is situated at the point of bifurcation of the common carotid artery. It invades the vessel sheath in its growth. The tumor is soft and compressible, attaining the size of a hen's egg, and shows no expansile pulsation or thrill like

FIG. 116.—SOLID TUMOR OF THE SUBMAXILLARY SALIVARY GLAND.
This illustration shows how these tumors appear to come from behind the lower jaw, projecting outward in the submaxillary region. (See text.)

an aneurysm. It is much firmer than a branchial cyst, appears at a later period in life, and grows more rapidly. It has a transmitted pulsation due to its relation to the vessels.

(*b*) *Sarcomata arising from the carotid sheath itself* grow rapidly and are firmly fixed to the deeper structures of the neck, although they are not adherent to the skin until a later period when they may ulcerate and

present a sloughing mass. They cause pressure symptoms such as dysphagia, dyspnea, neuralgia, and recurrent laryngeal paralysis at an early stage of their growth.

They are of firm consistency and usually occur in middle or old age. Their location under the sternocleidomastoid muscle, rapid growth, fixation to the deep structures, and pressure symptoms render their diagnosis comparatively easy. Lymphosarcomata and sarcoma of the thyroid are discussed on page 187.

9. **Carcinoma.**—This form of tumor of the neck may be primary or secondary. The former are very rare and may arise in the skin either (*a*) from an old ulcer or a scar or (*b*) in the deeper tissue from the branchial cysts or fistulæ or from aberrant thyroids.

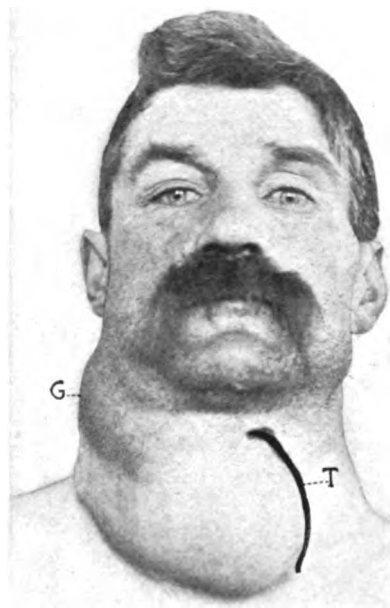

FIG. 117.—ANTERIOR VIEW OF CARCINOMA OF THE THYROID.

Causing displacement of the trachea (*T*) to the left: *G*, Secondary enlargement of the cervical lymph-nodes, of a carcinomatous nature.

(*a*) *Primary Carcinoma.*—The cutaneous carcinomata present the same characteristics as elsewhere. The deeper forms of primary carcinoma are usually rapid in their growth and located just below the angle of the jaw or at the middle of the sternocleidomastoid muscle at the same location as the branchial cyst (Fig. 100). They occur late in life and become adherent to the vessels early and cause ulceration of the skin, with everted hard edges (Fig. 101). The diagnosis of a primary branchiogenic carcinoma may be made if the growth has the typical induration of carcinoma, situated in the usual cyst location of a branchial cyst. They are fixed and cause pressure symptoms only at a late period. The growth is harder than a sarcoma and there is often involvement of the regional lymph-nodes (deep cervical).

Primary carcinoma of the thyroid is lower in the neck and attached to the trachea and displaces the latter (Fig. 117).

(*b*) *Secondary Carcinoma.*—This form of solid tumor can be readily

diagnosed from the fact that it involves the lymph-nodes draining the mouth, nose, ear, pharynx, or thyroid (Fig. 74). They are very hard, cause early pressure symptoms, and like the sarcomata and primary carcinomata ulcerate quite early. The diagnosis can be made from the consistency of the tumor and its location. The latter corresponds with that of the lymph-nodes. One should search for a primary growth in the head, larynx, esophagus and thyroid, breast or stomach (supraclavicular nodes). The latter is a rare occurrence.

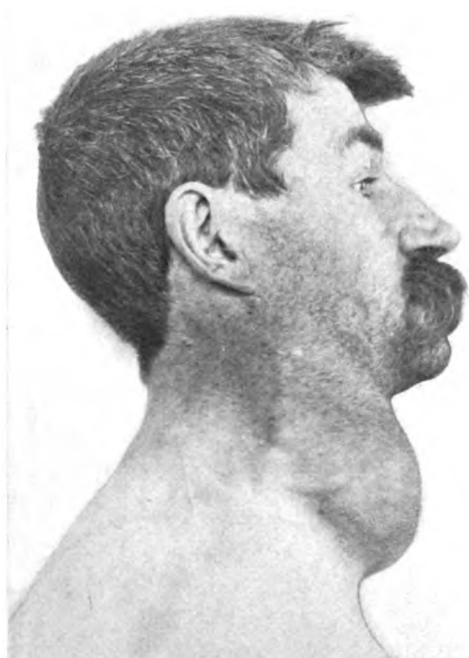

Fig. 118.—Lateral View of Case of Carcinoma of the Thyroid.

At times the external tumors may be enormous and even bilateral and the primary growth be an insignificant one, hidden in some obscure place like the sinus pyriformis or the anterior wall of the pharynx. One should always examine in their order the face, mouth, tongue, nasopharynx, larynx, esophagus, ear, salivary glands, thyroid, and rarely the stomach.

Primary carcinoma of the esophagus may at times first involve the submaxillary nodes to such an extent that the tumor is diagnosed as a primary one of the submaxillary salivary gland.

The secondary carcinomatous nodes are often movable and painless for a considerable period and may be the first sign to direct suspicion toward a malignant growth in the region which they drain. They are much firmer than tuberculous nodes and the latter are very rare at such a late period of life. Primary branchiogenic carcinomata, as was stated above, become adherent quite early to the vessels and cause severe pain.

CYSTIC TUMORS OF NECK.

	Most Frequent Location.	Age.	Mobility.	Pressure Symptoms.	Results of Palpation.
1. Branchial cysts.	Submaxillary region and middle of sternocleidomastoid.	Adults, rarely present at birth.	Fixed in the depth. Skin movable over it.	None.	Usually unilocular.
2. Thyroglossal cysts.	Median line between hyoid and middle of trachea.	Same as above.	Same as above.	Same as above.	Move upward when swallowing, otherwise same as above.
3. Lymphangioma.	Submaxillary region, but may spread. Less often supraclavicular.	Present at birth.	Fixed in depth but skin movable over it.	Present if of large size.	May be uni- or multilocular.
4. Hemangioma.	Cavernous. Anywhere in anterior region. Blood-cysts along carotid artery.	Often at birth or early life.	Cavernous attached to skin, blood-cysts to vessels.	Same as above.	Soft, can be reduced in size by pressure.
5. Thyrohyoid bursæ.	Over middle of thyroid.	Adult life.	Fixed to thyroid cartilage or hyoid bone.	None.	Firm cystic tumors. Unilocular.
6. Cystic goiter.	Lateral to middle of or over trachea.	Adults.	Fixed to trachea, otherwise movable.	If large it compresses trachea.	Distinctly fluctuating. Moves with trachea.
7. Diverticula of esophagus or pharynx.	On left side beneath sternocleidomastoid.	Adults.	Fixed to esophagus and lie very deep.	None.	Alternately full and empty, varying according to feeding.
8. Cysts of accessory or parathyroids.	At usual location of these.	Adults.	Skin movable. Fixed in depth.	None.	Firm tense cysts. Unilocular.
9. Echinoccocus cysts.	In sternocleidomastoid itself or beneath it. Are very rare.	Any age, but usually adults.	Skin movable. Fixed in depth.	None unless very large.	Unilocular. Tense cyst. May rupture spontaneously.
10. Sebaceous cysts.	Anywhere, but usually between sternocleidomastoids.	Adults.	Usually adherent to skin and very superficial.	None.	Soft tumor. Unilocular.
11. Dermoid cysts.	In median line of submental region.	Any age, but usually young adult.	Skin movable. Fixed in depth.	None unless very large, then dyspnea, dysarthria and dysphagia.	Firm, doughy consistency. Unilocular.

SOLID TUMORS OF THE NECK.

	Most Frequent Location.	Age.	Mobility.	Pressure Symptoms.	Results of Palpation.
1. Lipomata.	Back of neck or diffuse under chin.	Adult.	Movable unless diffuse.	None unless of diffuse variety.	Soft-lobulated growth very slow.
2. Fibromata.	As a part of fibroma molluscum, anywhere.	Adult.	Movable with skin.	None.	Firm or soft.
3. Lymph-nodes non-malignant.	In submental and submaxillary regions, along carotids, and above clavicles.	Any age.	Mobility varies (see page 165).	None except in Hodgkin's disease or lymphosarcoma.	Varies, but usually soft or fluctuating.
4. Osteoma.	Above clavicles or along spine.	Adult.	Fixed.	None except neuralgic pains. Very slow growth.	Very hard.
5. Chondroma.	Anywhere from islands of cartilage.	Any skin.	Fixed in depth but skin movable.	None.	Consistency of cartilage.
6. Sarcomata.	Along lymph-nodes (lymphosarcoma), at bifurcation of carotids or along large vessels.	Adult.	Fixed in depth, often ulcerate skin.	Quite early pressure on trachea, esophagus and vessels.	Grows rapidly. Consistency varies from soft to firm.
7. Carcinomata.	Primary same location as branchial cysts or in skin, thyroid, or secondary in lymph-nodes.	Old age.	Fixed in depth in early stage, later universally adherent.	Same as above. In primary a rapid growth. Late pressure symptoms in secondary.	Very hard and nodular. Regional infection of lymph-nodes in primary.
8. Tumors of submaxillary salivary gland.	Below angle of jaw.	Adult.	Skin movable, fixed to lower jaw.	None unless very large.	Firm consistency.
9. Goiter.	Sides of trachea or over middle of same.	Any age after puberty.	Skin movable. Attached to trachea. (Try the swallowing test.)	Varies as to size first on trachea.	Consistency varies according to whether parenchymatous, colloid, fibrous, or malignant.

10. Aneurysms.	Along carotids or subclavians.	Adult.	Skin movable. Adherent at depth.	None unless quite large.	Expansile pulsation, thrill, and murmur.
11. Primary tumors of parotid.	Begin in parotid and then invade neck.	Any age, but usually adult.	Fixed to deep tissues only.	None unless very large. Rapid growth.	Very firm, often like cartilage (see page 146).
12. Goiters of accessory or parathyroid glands.	At location of these (see Fig. 108).	Adult.	Same as above.	Slow growth and no pressure symptoms.	Firm, often nodular.

NON-MALIGNANT GOITER.

This may involve the thyroid gland proper, or one of the accessory thyroids or parathyroids. The pathologic changes are the same in all and the diagnosis of which one is involved can only be made from the location (Fig. 108).

The chief questions in every case of non-malignant goiter are:

(*a*) Whether the suspected tumor is a goiter.

(*b*) What is the extent of the involvement and the variety?

(*c*) Are pressure symptoms present?

A goiter of the accessory or parathyroids will have all the clinical characteristics of the true goiter, but its situation is different and it is not attached to the trachea.

A goiter involving the thyroid gland proper causes a prominence in the lower portion of the neck (Fig. 119) best seen when looked at from the side. It may be most marked in the median line if it involves the isthmus or more on one side if one lobe is involved, or be butterfly-like causing a prominence on both sides connected by a bridge (Fig. 119).

Tumors of the thyroid, unless a brawny, board-like infiltration exists, move upward with the trachea. This can be determined by permitting the patient to swallow some water while the tumor is grasped with the fingers (Fig. 121). This is absent in goiters of the para- or accessory thyroids.

The extent of involvement can be ascertained by flexing the head upon the neck and palpating the tumor while standing behind the patient.

The varieties of enlargement are:

1. *Simple Parenchymatous.*—This occurs at any age but is especially frequent in young people. It usually involves the entire gland, is soft and smooth, and rarely causes pressure symptoms. It may give the sensation of fluctuation. Any of the other forms may develop in it. It may begin during adolescence or pregnancy and remain stationary.

2. *Thyroid Adenoma.*—This is the most frequent form. It causes firm nodular tumors whose outlines are quite sharp. It often contains small cysts and its acini, which resemble those of the normal thyroids, may coalesce to form large fluctuating cysts forming very prominent tumors (Fig. 113). This form (adenoma) involves only a portion of the gland, either one lobe (Fig. 122) or the isthmus. Pressure symptoms such as dyspnea are marked if it compresses the trachea. If smaller or larger collections of colloid material occur it gives it a doughy consistency.

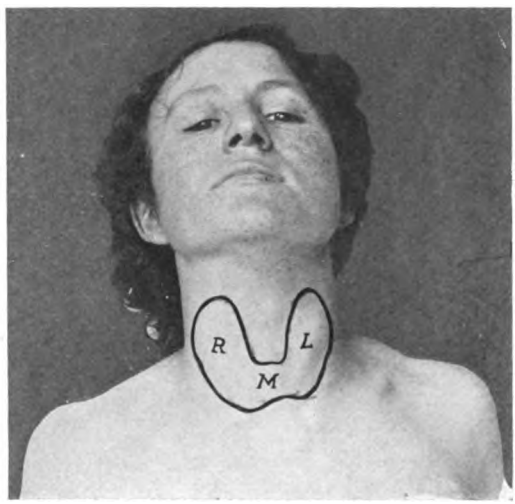

FIG. 119.—PARENCHYMATOUS GOITER.

Causing enlargement of right (*R*) and left (*L*) lateral lobes and isthmus (*M*) of thyroid. The palpable outlines of the tumor are traced upon the neck in black.

3. *Fibrous Goiters.*—These occur as enormously hard nodules or as a diffuse induration of one lobe or of the entire gland. In the latter form they cause pressure symptoms quite early.

4. *Vascular Goiters.*—This variety presents a distinct pulsation or thrill of the goiter due to the enlargement of the vessels. There are murmurs to be heard over the tumor.

Pressure symptoms are most marked if the posterior part of one or both lateral lobes are involved, or if there is a retrosternal goiter. These pressure symptoms are:

(*a*) Those due to pressure on the trachea. If moderate there is dyspnea, cyanosis, and some stridor. If the pressure is of high degree asphyxia may result (Fig. 117).

FIG. 120.—LATERAL VIEW OF SAME CASE SHOWN IN FIG. 119, OF PARENCHYMATOUS GOITER INVOLVING ISTHMUS AND LATERAL LOBES.

The extent of this pressure on the trachea may be ascertained by a laryngoscopic examination and the use of the *x*-ray as recently suggested by von Bruns.

(*b*) Pressure on the recurrent laryngeal nerve. This causes hoarseness, a brassy cough, and aphonia. Death may ensue suddenly from spasm of the glottis.

(*c*) Pressure on the sympathetic causes vasomotor disturbances of the skin of the face and neck and a dilatation of the pupil on the side upon which pressure is exerted.

(*d*) Pressure on the esophagus is less frequent than any of the above and results in difficulty in swallowing.

A retrosternal goiter produces dullness over the manubrium (Fig. 148), may cause pressure on the trachea, and this tracheal stenosis be the only symptom. It may also compress the large veins, the innominate artery, and the esophagus.

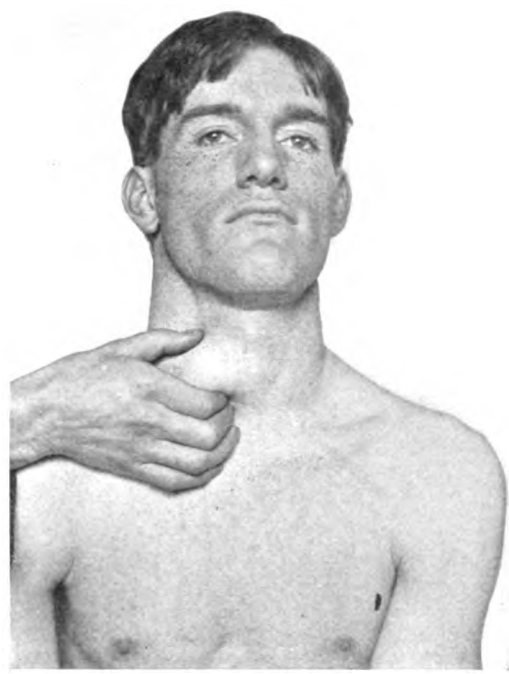

FIG. 121.—METHOD OF GRASPING TUMORS OF THE THYROID TO SHOW THEIR RELATION TO THE TRACHEA.

The lobes of the enlarged thyroid are grasped between the index-finger and thumb, and the patient instructed to swallow. During the act of swallowing the tumor moves distinctly upward, and sinks again after cessation of the same.

A retrosternal goiter must be differentiated from other conditions, such as other varieties of mediastinal tumor, such as sarcomata, aneurysms, and esophageal diverticula which could produce the same symptoms (see page 329). In retrosternal goiter the dyspnea is intermittent, varying with the rise and fall of the tumor during respiration.

MALIGNANT GOITER.

Both sarcoma and carcinoma occur rather infrequently. Sarcoma occurs at an earlier age (thirty to fifty) than carcinoma (forty to

sixty). Sarcoma grows more rapidly than carcinoma and attains a much larger size. Both can be distinguished from non-malignant goiters by the fact that they cause a steady, at times quite rapid, enlargement of the gland and the pressure symptoms on trachea, esophagus, and blood-vessels are very marked (Fig. 117). Both forms of tumor are much harder than the ordinary forms of goiter. Sarcoma causes a uniformly rapid enlargement while carcinoma is quite nodulated, accompanied by enlarged hard lymph-nodes, and is very painful.

Carcinoma of the thyroid produces early metastases in the long bones and skull.

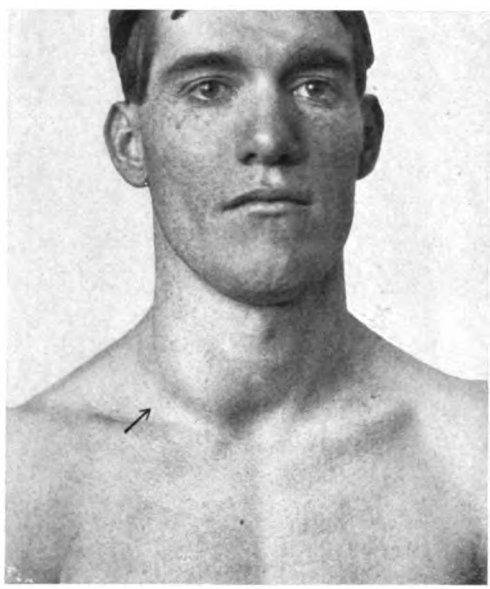

FIG. 122.—UNILATERAL RIGHT-SIDED GOITER.

The arrow points to the tumor along the inner side of the lower portion of the sternocleidomastoid muscle, caused by the goiter.

THYROIDITIS.

Inflammations both of the normal thyroid gland and of a goiter may occur. The symptoms are identical in both.

They may follow injury to the neck in the vicinity of the gland or occur during the course of some general disease, such as typhoid, malaria, articular rheumatism, scarlatina, variola, and pyemia. The diagnosis presents no difficulties if one remembers the normal situation of the thyroid. The gland can be felt to be considerably swollen and indurated. It is quite tender and the pains radiate toward the face and the ear. In the very acute cases there is redness of the overlying skin.

The leukocytosis, pulse-rate, and temperature vary with the severity of the infection, being higher in the very acute cases. The swollen gland may compress the trachea and esophagus and cause symptoms of stenosis, dyspnea, and dysphagia respectively. If the inflammation goes on to suppuration the surrounding tissue becomes edematous and tender and pus forms in the gland. This may be ascertained by the persistence of the temperature and the increase of the local signs and leukocytosis.

The pus may escape externally through perforation of the skin or rupture into the trachea, esophagus, or mediastinum.

Exophthalmic Goiter.

The diagnosis of this condition may be made from the presence of a group of four symptoms, exophthalmos, tachycardia, a goiter, and a fine tremor.

It may occur as a disease without any marked enlargement of the thyroid or be accompanied by any of the forms of goiter.

Fig. 123.—Front View of Case of Exophthalmic Goiter.

The bulging of the eye resulting in abnormal separation of the lids is well shown. The thyroid was greatly enlarged, of the parenchymatous variety, and involved both right and left lobes and the isthmus of the thyroid, all of which were quite prominent. The pulse-rate in this case was 152.

Fig. 124.—Side View of Case of Exophthalmic Goiter.

Note the protrusion of the eyeballs and the marked prominence over the thyroid region, due to the presence of a parenchymatous goiter of both lobes and isthmus of the thyroid.

The exophthalmos is bilateral and (Figs. 123 and 124) accompanied by certain typical ocular symptoms which, however, are not constant. These latter are the Stellwag symptom (abnormal wideness of the palpebral opening), the Moebius symptom (a lack of convergence of the two eyes), and the von Graefe symptom (the upper lid does not follow the eyeball when it is moved down). The tachycardia varies from ninety to one hundred and forty beats or even higher in severe cases. The face and neck are flushed and there are frequent attacks of profuse sweating, especially of the extremities.

The goiter is moderately firm, not as large as in ordinary cases, and often so vascular as to show a distinct bruit.

The tremor is of a very fine character, best seen when the hands are extended. There is often great muscular weakness (myasthenia).

From time to time there are attacks of vomiting and diarrhea as well as of palpitation and angina pectoris.

The larval or *formes frustes* often accompany goiters, but are apt to be overlooked. In these, any of the above symptoms, such as tachycardia, tremor, sweating, and palpitation, may accompany a goiter and not be correctly interpreted.

Edema of the Glottis.

This is usually secondary to inflammmatory conditions in the vicinity spreading to the loose connective tissue of the aryepiglottic folds. The swelling causes marked dyspnea, cyanosis, and stridor. The symptoms may appear so rapidly that death occurs immediately. The diagnosis may be made from the onset of the above symptoms during the course of a peritonsillar (Fig. 125) or perichondritic suppuration or as a complication of a Ludwig's angina (deep phlegmon of floor of mouth) or of ulcerative laryngeal processes.

The diagnosis can be confirmed by laryngoscopic examination. One can see the swollen aryepiglottic folds almost touching each other.

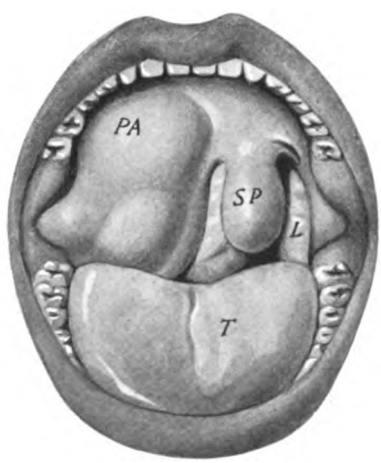

Fig. 125.—Peritonsillar Abscess.

PA, Prominence along anterior pillar of fauces and caused by peritonsillar abscess; *SP*, edematous uvula; *L*, normal left tonsil and pillars of fauces; *T*, tongue.

Papilloma of Larynx.

This is the most frequent form of benign tumor of the larynx. They occur especially in children on the true vocal cords and are usually multiple. They give rise to symptoms of stenosis and hoarseness and if pedunculated may fall into the space between the cords and cause asphyxia. By laryngoscopic examination they look like a pink mulberry-shaped tumor situated at the anterior end of one of the vocal cords or scattered diffusely over both the cords.

Carcinoma of the Larynx.

Carcinoma of the larynx usually occurs late in life. It may be primary, *i. e.*, have its origin within the larynx, or secondary, by extending to it from the tongue, pharynx, or esophagus. The primary is also spoken of as intrinsic, the secondary as the extrinsic form.

The diagnosis may be made from the gradual onset of hoarseness, pain in the larynx radiating to the ears, and dyspnea in elderly men taken in conjunction with the local findings. Later on when the lymph-nodes along the anterior border of the sternomastoid become enlarged and there is expectoration of a fetid, tenacious mucus, with recurrent hemorrhages accompanied by dysphagia and emaciation, the diagnosis is no longer difficult.

The local examination at an early stage, will show one of the following laryngoscopic pictures:

1. A papillomatous growth which has a broad indurated base situated usually on the posterior third of a vocal cord.

2. As a marked thickening and induration of one of the vocal or ventricular bands or aryepiglottic folds. At times one sees in addition to the induration a nodulated condition. The entire thickness of the cord seems to be involved. Later in the disease, the picture is different; one now sees ulcerations with raised and indurated edges. The carcinoma has now begun to grow either through or around the thyroid cartilage and is to be felt externally as a hard mass accompanied by firm enlarged lymph-nodes. In the very advanced stages it may grow toward the trachea, pharynx, or esophagus, and cause corresponding symptoms.

There are a number of conditions from which carcinoma of the larynx must be differentiated. These are benign papilloma, syphilis, and tuberculosis. The first-named occurs very rarely so late in life and according to Bland Sutton any papilloma beyond the age of forty must be looked upon with suspicion.

In regard to the two last-named conditions, tuberculosis and syphilis are always seen as ulcers and seldom as infiltrations and never papillomata. In tuberculosis severe pain, cough, and dysphagia are prominent symptoms. The arytenoids are greatly swollen and club-shaped. The tuberculous ulceration is very shallow, has no indurated edges, and the larynx is very anemic. Tuberculosis is never primary and is accompanied by signs of pulmonary disease with tubercle bacilli in the sputum. Tuberculous ulcers are multiple while carcinoma occurs in a single place. Tuberculosis has as a favorite seat the interarytenoid

space or the arytenoid cartilages. Syphilis is accompanied by signs of the same disease elsewhere and if iodids are given there is marked improvement of the laryngeal condition which causes hoarseness and dyspnea as does carcinoma. The syphilitic ulcerations as elsewhere are deep and the edges are clear cut as though cut out with a die, and may occur anywhere in the larynx, but like tuberculosis are usually multiple. There is no enlargement of the lymph-nodes of the neck.

It must not be forgotten that as on the tongue carcinoma may be combined with syphilis. It is almost impossible to diagnose such cases.

CHAPTER III.

THORAX.

INJURIES OF THE BONY WALLS OF THE THORAX.

The diagnosis of whether an injury has occurred and its extent can only be made from a systematic examination of each rib, of its costal cartilages, and of the sternum.

FRACTURES OF THE RIBS.

If the mode of injury has been a blow received from some blunt object or a fall upon the same, the fracture will usually be found at the point of impact. If the thorax has been crushed in a diffuse manner, as in being run over or caught between bumpers, the fracture will usually be found between the midaxillary line and angle of the ribs. Those most often broken are from the third to ninth ribs inclusive. Only one rib may be broken or a number (six or seven). A single rib may at times be broken in places. The diagnosis of whether there are complications, such as injury of the vessels, pleura, or lung, will be considered on page 196.

The diagnosis of a fracture of a rib depends upon the presence of two classes of symptoms.

1. Those due to the fracture proper, such as pain, crepitus, false point of motion, and deformity.

2. Those due to injury of the intrathoracic viscera.

1. **Signs Due to the Fracture Proper.**—These are not as easily elicited in the ribs as in the long bones, nor is it necessary to obtain all of them in order to make a diagnosis.

Crepitus can rarely be elicited and no great stress should be placed upon its absence. It can be obtained at times by placing the hand over the suspected point of fracture and asking the patient to breathe deeply. If this does not elicit it, no further effort should be made to obtain it. Occasionally it may be heard with the aid of a stethoscope. A false point of motion may often be obtained by direct palpation over the seat of fracture without causing pain to the patient. Each rib should be examined by palpating it from its anterior to posterior ends for this

sign. One must not mistake the apparent yielding of the lower ribs for this sign. During the same manipulation one can usually feel a depression or unevenness in the outline of the ribs if present. The latter is especially true in fractures at the costochondral junction.

On placing one hand in front and the other at the back of the chest and compressing the chest, the patient will experience a sharp pain at the seat of fracture. The diagnosis must at times be made from the presence of pain and deformity alone, with or without accompanying symptoms of intrathoracic complications.

2. **Signs Due to Injury of the Intrathoracic Viscera (i. e., of the Pleura or Lung.**—These are discussed on page 196. They are friction rub, hemothorax, pneumothorax, emphysema of the subcutaneous tissuse, hemoptysis and pneumonia.

FRACTURES OF THE COSTAL CARTILAGES.

Fractures of the costal cartilages themselves are most common in old age when they are ossified, while in younger persons there is a separation of the cartilage from the ribs. The diagnosis may be made from palpation of the deformity, the cartilage itself being displaced backward, while the rib is pushed out or forward. There is also local pain and some degree of abnormal motion.

FRACTURES OF THE STERNUM.

Aside from gunshot wounds, these are usually transverse and occur in connection with injuries of the spine as the result of crushing injuries of the thorax. They are most common at the junction of the manubrium and gladiolus, and next most frequent opposite the third and fourth ribs. The diagnosis may be made from the severe pain referred to the site of the injury and the deformity. The deformity may be present either as a decided displacement backward of the manubrium, so that when the finger is passed along the sternum from above downward there is a sudden, sharp, step-like elevation at the manubrio-gladiolar junction. In other cases there is a marked increase of the normal ridge or angle (angulus Ludovici) which these two portions of the sternum form with each other.

Fractures of the sternum may be accompanied by signs of severe intrathoracic injury.

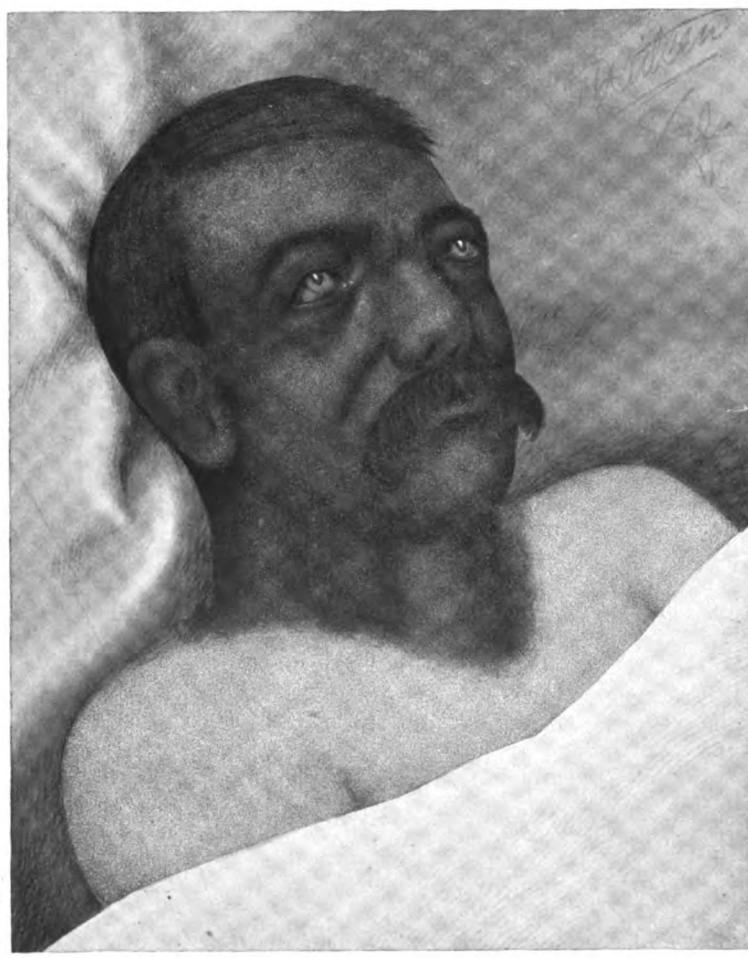

FIG. 126.—ILLUSTRATION OF A CASE OF TRAUMATIC ASPHYXIA (see text) FOLLOWING COMPRESSION OF THE THORAX. (Kindly lent by Drs. H. H. A. Beach and Farrar Cobb, of Boston, from their article in the April, 1904, number of the "Annals of Surgery.")

INJURIES OF THE THORACIC VISCERA.

These may be divided into two classes:

1. The non-penetrating or subcutaneous.
2. Penetrating.

The first group includes those following the application of a crushing force, whether applied in a circumscribed manner, such as follows a blow or a fall upon some object, as well as in those where the force acts diffusely, *e. g.*, crushing between two objects, etc.

The second group includes those following the use of sharp or cutting weapons or the use of firearms of whatever nature.

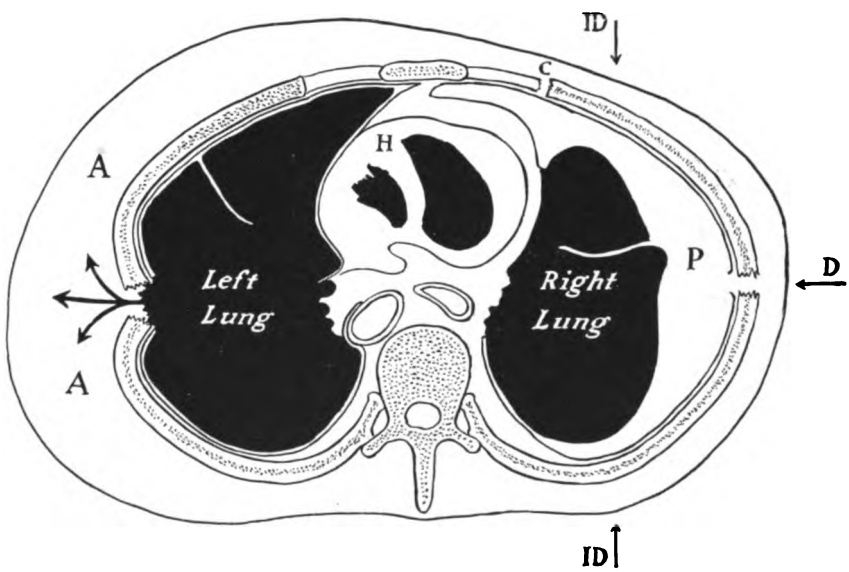

FIG. 127.—CROSS-SECTION OF THORAX (DIAGRAMMATIC) TO SHOW MODE OF PRODUCTION OF PNEUMOTHORAX OR HEMOTHORAX AND OF SUBCUTANEOUS EMPHYSEMA AS A RESULT OF FRACTURES OF THE RIBS.

ID, The arrow accompanying these letters shows the mode of action of indirect force in producing fracture of the ribs; D, mode of action of direct force in producing fracture of the ribs; P, pneumothorax as a result of fracture of the rib and laceration of the pleura on right side; A, extensive subcutaneous emphysema as a result of puncture of a lung by the sharp ends of a fractured rib fragment; the triple arrow shows the mode of egress of the air from the punctured lung into the subcutaneous tissues; H, cross-section of heart; C, fracture at costo-chondral junction without displacement.

1. NON-PENETRATING OR SUBCUTANEOUS.

The thorax behaves like the skull toward a crushing force, but possesses greater elasticity, so that its contents can alter their volume and form more readily.

Death may follow immediately with symptoms of collapse without even visible external signs, probably as the result of the injury of the

vagi. Serious injuries are more frequent after crushing of the thorax in younger persons than in older, because the elasticity of the ribs is greater and the ribs offer less resistance. The majority of injuries of this group are accompanied by fractures of the ribs and sternum.

Traumatic Asphyxia.—This is a peculiar result of severe thoracic compression (see Fig. 126). It may be recognized by the marked cyanotic discoloration of the head, face, and neck.

This cyanosis terminates very abruptly in the upper portion of the thorax. It is usually accompanied by fractures of the ribs and emphysema. It is due to a dilatation of the cutaneous capillaries of the discolored parts.

FIG. 128.—EMPHYSEMA OF SKIN FOLLOWING FRACTURE OF THE RIBS ON THE RIGHT SIDE.
Note the puffiness of the face—the eyes almost closed (Warren).

Subcutaneous Injuries of the Lungs and Pleura.—The diagnosis of these complications occurring either with or without fractures of the ribs depends on the appearance of the signs of pneumothorax or hemothorax, hemopericardium, pleuritis, emphysema of the subcutaneous tissues, and hemoptysis.

(*a*) *Subcutaneous Injury of the Pleura.*—A moderate degree of emphysema, or of pneumothorax which does not increase, or the presence of a dry pleuritic friction rub is indicative of an injury of the pleura. If the intercostal or internal mammary arteries are injured, there are evidences of hemothorax.

One can make a probable diagnosis of pleural injury alone from the presence of a slight degree of emphysema and of pneumothorax which rapidly subsides or from the friction sound alone. At times, injuries of the pleura will cause no symptoms. The emphysema can be recognized by the peculiar crackling or crepitating sensation obtained upon palpating the skin.

(*b*) *Subcutaneous Injury of the Lungs.*—Subcutaneous injuries of the lungs cause a high degree of emphysema of the skin which rapidly spreads over the entire body (see Fig. 101) and may imperil life. In addition, a pneumothorax results which increases rapidly in degree,

crowding the lung and heart over to the opposite side. Rarely it may become bilateral.

Hemothorax and hemoptysis are also characteristic of subcutaneous lung injury, varying according to the extent of the same and disappearing gradually.

All of these signs of lung injury may be absent. Bloody sputum is especially apt to be inconstant. A number of cases have been recorded where a pneumonia developed after a subcutaneous injury.

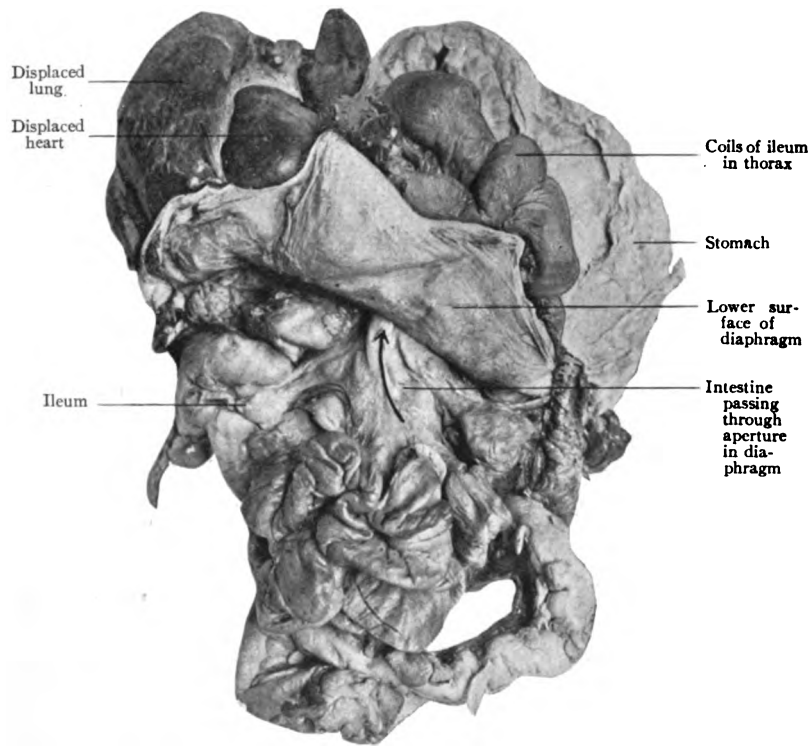

FIG. 129.—VIEW OF DIAPHRAGMATIC HERNIA WITH DIAPHRAGM RAISED IN ORDER TO SHOW HERNIAL OPENING IN DIRECTION OF ARROW.

It was quite localized, but having all of the clinical characteristics of this disease.

A pulmonary hernia may appear in one of the intercostal spaces as a reducible swelling with a tympanitic note, becoming prominent on expiratory efforts such as coughing. It crepitates distinctly like lung tissue while being reduced.

(*c*) *Subcutaneous Injuries of the Diaphragm.*—These are seldom recognized during life, being usually immediately fatal. They show

marked displacement (see Figs. 129 and 130) of the thoracic viscera by the abdominal organs which have escaped through the rent in the diaphragm. There is usually great dyspnea, cyanosis, and a disturbance of cardiac action. In addition, there is a tympanitic note on percussion, bulging of the thorax, and gurgling on the injured side. Vomiting and symptoms of strangulation may also be present. In this connection it is well to speak of the frequent association of serious abdominal injuries, especially of the parenchymatous organs, with

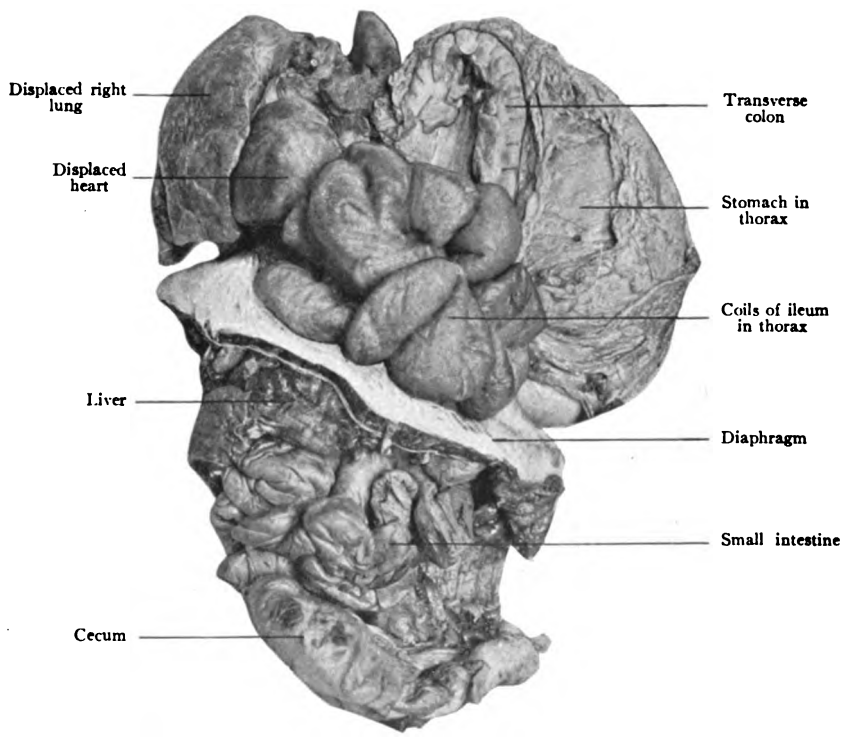

FIG. 130.—ANOTHER VIEW OF DIAPHRAGMATIC HERNIA SHOWN IN FIG. 129 WITH DIAPHRAGM IN POSITION AS FOUND AT AUTOPSY.

crushing injuries of the bony wall of the thorax or of the thoracic viscera. This association should always be borne in mind in the examination of such a case.

(*d*) *Subcutaneous Injuries of the Pericardium, Heart, Blood-vessels, Esophagus, and Thoracic Duct.*—With the exception of those of the pericardium, these injuries are so rare and rapidly fatal that they cannot be recognized during life. Injuries of the pericardium without external signs cause either a dry pericarditis or hemopericardium,

with the characteristic friction rub of the former and the increased area of dullness and other physical signs of the latter. In addition, there are always syncope and symptoms of collapse.

Ruptures of the thoracic portion of the esophagus are very rare and can only be recognized by the resultant mediastinitis.

There are nine cases of rupture of the thoracic duct recorded, of which eight were followed by chylothorax.

2. PENETRATING INJURIES OF THE THORAX PROPER.

These may be due to the action of a sharp or cutting weapon or to gunshot wounds, and include chiefly injuries of the lungs and pleuræ. As in the subcutaneous injuries, the cardinal symptoms are emphysema, pneumothorax, and hemothorax. All of these may, however, be absent.

Pneumothorax.—This can be recognized by the usual signs, viz., a tympanitic note on percussion, the absence of respiratory and voice sounds and of vocal fremitus. If it is present upon the left side, there is displacement of the heart to the right.

If the pneumothorax is only moderate in extent and disappears rapidly, it indicates pleural perforation alone (Fig. 127) and is due to the entrance of air through the wounds.

If it increases and becomes more tense in spite of the external wound being closed, it indicates a wound of the lung which has remained open.

Hemothorax.—In every case one must decide whether the hemorrhage has occurred from the vessels of the thoracic wall (intercostal and internal mammary arteries) or from the lungs.

(*a*) If from the parietes, the external wound is situated over the internal mammary artery, if the hemorrhage is from this artery. If it is from the intercostal vessels, there is also an external wound to be found bearing some relation to these vessels. In both instances the diagnostic signs are the escape of blood from the wound in many cases, and the presence of a hemothorax.

(*b*) If the hemorrhage is from the lung, there is expectoration of foamy blood and the signs of hemothorax. If the lung is adherent to the chest wall, foamy blood escapes from the wound. Hemoptysis may be absent if the bronchus is plugged or there is no communication of the wound in the lung with a bronchus.

Bilateral hemothorax is usually fatal. Pneumothorax is often combined with hemothorax so that there is a combination of physical

signs of the presence of both air and liquid in the chest, because the blood almost invariably remains liquid.

3. *Emphysema of the Skin.*—(*a*) If due to a pleural wound alone, it is only moderate in extent, and is due to the entrance of air through the wound and disappears rapidly.

(*b*) If it be due to injury of the lung, it is far more marked and constantly increases. If the lung is adherent it may become excessive and cause death from asphyxia unless relief is obtained by artificially producing a collapse of the lung.

4. *Dyspnea and Cyanosis.*—These are only marked if there is a high degree of pneumothorax or hemothorax.

5. *Prolapse of lung* through the external wound is positive proof of a pleural injury. It is more marked during coughing or expiration.

6. The secondary complications of pleural and pulmonary injuries are *pneumonia* and *empyema*. These are more frequent after penetrating than non-penetrating injuries. The hemorrhagic infiltration of the lungs favors the localization of microörganisms, especially of the pneumococcus.

Penetrating Injuries of the Heart and Pericardium.—Just as in the case of similar injuries of the thoracic cavity proper and of the abdominal cavity, it is impossible to make a diagnosis of the perforation of a viscus, from the position of the external wound alone, although its location over a viscus is of some value. The wound may be at some distance from the heart, as in gunshot wounds.

In the case of injuries of the heart we place more value upon the accompanying general and local signs.

In the majority of cases there is unconsciousness immediately after the accident, probably due to shock, since the same symptoms appear after injuries of the heart without external wound. Accompanying this primary syncope, and especially to be noticed after consciousness has been restored, are the symptoms of collapse due to internal hemorrhage. The pulse is very feeble and irregular; at times it is scarcely to be felt. There is marked anemia. The local signs of value in diagnosis are those of the accompanying hemopericardium and pneumopericardium. In general, one may speak of three classes of cases:

(*a*) Those associated with a wound in the lung. In these the prominent symptom is pneumopericardium. This may or may not be associated with hemothorax or pneumothorax. The heart sounds are to be heard as if at a distance and there is a tympanitic note replacing the normal area of cardiac dullness. If there is a hemothorax there are signs of internal hemorrhage and dullness over the lung. In such

cases there is considerable anemia, marked collapse, and feeble pulse.

(*b*) Those of the heart alone with escape of blood into the pericardial cavity. These give rise to all of the physical signs of hemopericardium, accompanied by very feeble and irregular pulse, cyanosis, dyspnea, and moderate anemia. The area of cardiac dullness is increased and one hears a splashing sound due to the heart beating in the fluid which surrounds and interferes with its action. This splashing gradually disappears as the pericardial cavity fills up.

(*c*) This third class of cases is characterized by the escape of blood externally through the wound in the chest wall. The blood will be red or blue according to whether the wound is in the right or left heart.[1] In these cases there are marked collapse, signs of hemorrhage (pallor, rapid, very feeble pulse), and irregular heart's action. There is also a slight increase in cardiac dullness and no hemothorax.

The diagnosis of whether the heart has been penetrated or not may be made from considering the location of the wound, the general symptoms, and the physical signs of pneumopericardium or hemopericardium associated or not with those of pneumothorax or hemothorax.

Penetrating Wounds of the Diaphragm.—These are usually associated with gunshot or stab wounds of the thorax and abdomen, and a diagnosis cannot be made until the wound has been explored.

ACUTE AND CHRONIC INFLAMMATORY PROCESSES OF THE THORACIC WALL.

OF THE SKIN AND SUBCUTANEOUS TISSUES.

Furuncles are apt to appear on the back of the chest, and may become quite large, especially over the scapulæ, forming large carbuncles which extend quite deeply in the subcutaneous tissues. One must always bear in mind the possibility of diabetes in patients who suffer from these large or recurrent carbuncles.

Acute phlegmon of the subcutaneous tissue of the thoracic wall is quite rare. It may occur by extension from suppuration of the axillary lymph-nodes. The infection travels rapidly in the connective tissue lying between the skin and pectoralis major muscle and in that lying beneath the latter. There is general tenderness, induration, and redness, accompanied by signs of septicemia.

Tertiary Syphilis.—One of the favorite seats of gummatous ulcerations is on the skin of the back. They can be recognized by their irregu-

[1] Niebert: "Philadelphia Medical Jour.," Mar. 3, 1902.

lar serpentine form, clear-cut, sharp edges, and deep character. Their multiple occurrence, lack of induration, and the absence of indurated lymph-nodes or lymph-vessels will exclude a carcinoma (see Fig. 131).

Actinomycosis of the skin and subcutaneous tissue of the thorax is secondary to that of the lungs or mammary glands. In the former case one finds indefinite symptoms of pulmonary consolidation, with subsequent breaking down of lung tissue associated with multiple areas of softening and sinus formation in the skin. In that secondary to actinomycosis of the breast there are also sinuses of long duration leading to the parenchyma and discharging pus. The condition greatly resembles tuberculosis, but there is a more brawny infiltration of the skin, and examination of the pus shows the actinomyces. Both sarcoma and carcinoma of the skin of the thorax may occur as primary affections upon the site of a previous pigmented mole (see Fig. 132).

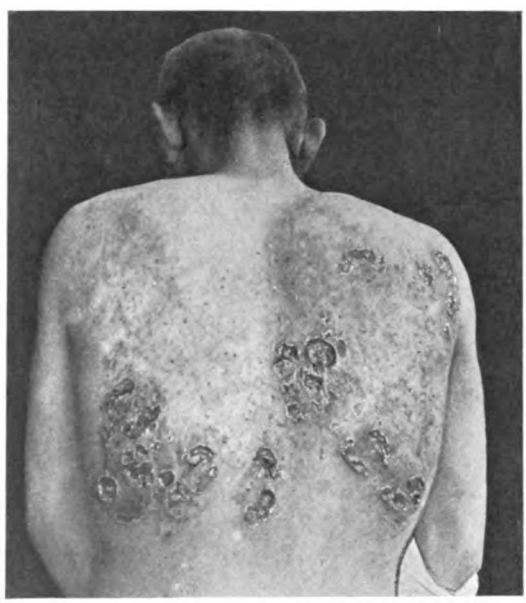

FIG. 131.—TERTIARY SYPHILITIC ULCERATIONS OF BACK.
Note the characteristic sharp edges and punched-out condition of the ulcers, and the tendency to oval outline.

AFFECTIONS OF THE BONY THORAX.

Acute Osteomyelitis of the Ribs.—This is a very rare affection of the ribs, especially the form which is due to the organisms producing the same condition elsewhere, viz., the staphylococci. It may occur as a complication of an acute infectious disease, such as influenza, pneumonia, and typhoid, either during the course of the disease or following it. It is most frequent at or near the costochondral junction. In the form which follows the above acute infections the diagnosis may be made from the history of the infectious disease, the local findings, and the constitutional disturbances. These two latter are swelling, acute pain, and tenderness over the rib, more or less fever, and leukocytosis.

Acute Osteomyelitis of the Sternum.—This condition is very rare, only nine cases having been reported. The symptoms are those of violent epigastric pain, high fever, delirium, and local inflammatory symptoms, such as tenderness and edema. The pus may collect in the anterior mediastinum, which is the direction of least resistance; if so, the condition is very apt to be overlooked.

FIG 132.—PRIMARY CARCINOMA OF THE SKIN OF THE THORAX (*T*); *CL*, CARCINOMATOUS LYMPHANGITIS, THE NODULES OF WHICH COULD BE DISTINCTLY PALPATED THROUGH THE SKIN.

Tuberculosis of the Ribs or Sternum.—This form of bone disease is comparatively frequent in the ribs and sternum. Its course is so insidious that the patients often seek surgical advice only when a tubercular abscess or sinus has formed. It may at times be difficult to determine the point of origin of a tubercular abscess, owing to the fact that it is apt to gravitate so that its external opening is found at some distance from the original focus. Upon the back such an abscess may lie beneath the fascia and greatly resemble a lipoma (see Figs. 134 and 135), fluctuation being very indistinct. In the scapular region tuberculous abscesses both from the posterior ends of the ribs and from the dorsal vertebræ may appear gradually without any inflammatory symptoms or pain. The following are, in general, the diagnostic features of tubercular affections of the ribs and sternum. The appearance of a thickening of the rib or sternum is accompanied by slight pain and by elevation of

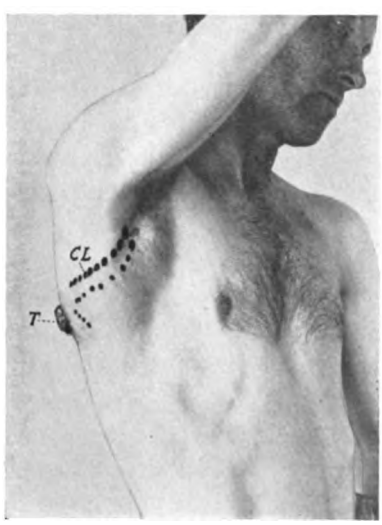

FIG. 133.—LATERAL VIEW OF PATIENT SHOWN IN FIG. 132, WITH PRIMARY CARCINOMA OF THE SRIN (*T*).

The dotted lines (*CL*) indicate the nodules of a carcinomatous lymphangitis passing toward the axillary lymph-nodes which could be distinctly felt through the skin.

temperature. In the more advanced stage, in which the cases are usually seen, a soft, fluctuating swelling is found, devoid of inflammatory symptoms and distributed over one or several ribs and their interspaces.

Such tubercular abscesses must be differentiated from lipomata and subcutaneous abscesses due to a spontaneously perforated empyema (see page 212). Lipomata are generally lobulated, the skin can be moved over them, and they are freely movable as a whole upon the thorax. They do not fluctuate.

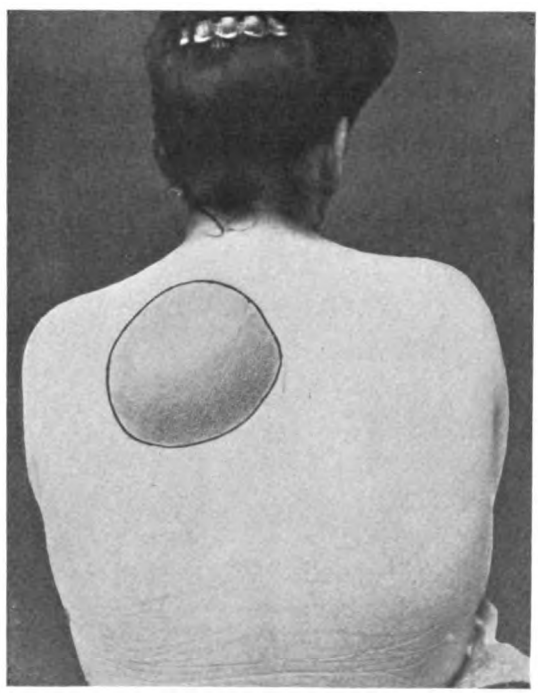

FIG. 134.—DIRECT POSTERIOR VIEW OF PATIENT SHOWN IN FIG. 135, SHOWING THE EXTENT OF THE TUMOR, DUE TO A TUBERCULOUS ABSCESS, SECONDARY TO DORSAL SPONDYLITIS, AND SIMULATING A LIPOMA.

An abscess resulting from a spontaneously perforated empyema occurs oftenest in children and usually around the nipple, but may take place anywhere. There is fever and the physical signs of an effusion into the pleural cavity (see Fig. 141).

When single or multiple sinuses have formed, the diagnosis presents no difficulties. There is a history of a long-continued, almost painless illness, with constant discharge of a thin yellowish pus. The edges of the sinus are lined by flabby or even caseous granulations.

Tubercular abscesses may form upon the inner side of the rib as peripleuritic abscesses or collections of pus, and be difficult to differentiate from encapsulated empyema except from the history of an acute infection with high temperature.

In elderly people a tuberculosis of the rib may begin as a marked enlargement and induration of the rib which greatly resembles a malignant growth until softening with accompanying fluctuation occurs.

If tuberculosis occurs in the sternum and causes a retrosternal

collection of pus, the pressure symptoms may resemble those of a retrosternal tumor (see page 220) or of an aneurysm, but there is often an edema over the sternum. The pus generally escapes at the left of the sternum at the level of the second rib, but may gravitate downward toward the recti muscles of the abdomen.

Syphilis.—The form of syphilis of the bones of the thorax that is of greatest interest is the gumma. It occurs as a flat, often exquisitely sensitive, localized thickening of the periosteum of the ribs and sternum greatly resembling the softer varieties of the periosteal sarcoma. When the process has affected the bone itself, necrosis results and a sinus is present in the skin from which a tenacious and homogeneous pus escapes. At this stage it may be thought to be tuberculosis. In the latter, there is generally a softer fluctuating swelling preceding the formation of the sinus. The pus from a tubercular abscess is caseous and flocculent and the granulations are flabby and often cheesy. There is also an absence of the history and of the manifestations of syphilis elsewhere. The latter is also true of those periosteal gummata resembling sarcoma of the ribs or sternum, *i. e.*, before they are broken down. They also present more inflammatory symptoms, such as tenderness, etc., than a sarcoma, are slower in growth, and rapidly respond to antisyphilitic treatment.

FIG. 135.—LATERAL VIEW OF PATIENT AS SHOWN IN FIG. 134, SUFFERING FROM TUBERCULAR ABSCESS OF SCAPULAR REGION, SIMULATING A LIPOMA.

The dotted line shows the extent of the pseudo-fluctuation.

TUMORS OF THE CHEST WALL.

In making a diagnosis of a thoracic swelling which can be either seen or felt externally the following points must be considered:

1. How long has the swelling existed?

2. Does it belong (*a*) to the skin or the bony thorax, or (*b*) arise from within the chest and protrude externally?

3. The consistency and other characteristics, such as rate of growth, etc.

The various forms of tumors or swellings which occur are:

1. FROM THE SKIN ITSELF.
   - Pigmented moles.
   - Single or multiple soft fibromata.
   - Sarcoma and carcinoma.
   - Capillary and cavernous hemangiomata.
   - Lymphangiomata (capillary and cystic).
   - Lipomata.

2. FROM THE BONY THORAX.
   - Enchondromata of the ribs or sternum.
   - Sarcomata of the ribs or sternum.
   - Secondary carcinomata of the ribs or sternum.
   - Abscesses due to tuberculous ribs or sternum.
   - Gummata of the ribs.

3. FROM WITHIN THE THORAX.
   - Aneurysms.
   - Gravitation abscesses due to dorsal spondylitis.
   - Spontaneously perforated empyemata.
   - Actinomycotic abscesses.

The characteristics of the swellings due to tubercular, syphilitic, or actinomycotic infection were considered on pages 203 and 205. All of the tumors in the above lists except the angiomata appear after birth. The lymphangiomata and hemangiomata do not differ from the same forms of new-growths elsewhere and have been fully described in the preceding chapter. They may at times attain an enormous size, involving the entire one-half of the thorax.

Pigmented moles can be recognized by their brownish color and occurrence in the skin. They are stationary in growth until a sarcomatous or carcinomatous change, when they increase in size rapidly, forming very malignant growths (see Fig. 132).

Fibromata also occur in the skin, either as a single pedunculated, often very large tumor, or as multiple fibroma molluscum, smaller tumors (see Figs. 376, 377). They are, as a rule, quite soft, and slow in growth unless a sarcomatous change occurs.

Sarcoma of the skin is not frequent. It can be recognized by its rapid growth and firmer consistency than ordinary fibromata.

Lipomata almost always occur in the subcutaneous tissues of the back and sides of the chest. The skin is movable over them and the

tumors show characteristic lobulation. When deeply situated they may give rise to a sense of pseudo-fluctuation resembling that of an abscess. They may grow rapidly at times, giving rise to very large tumors.

The most frequent tumors of the bony thorax are **periosteal sarcomata of the ribs.** Sarcomata of the sternum are much rarer. Sarcomata can be recognized by the history of a rapid growth, by their attachment to the ribs, and their firm consistency. They may at times spread over the interspaces to adjacent ribs (Fig. 136). They are seldom attached to the skin, which is usually freely movable over them.

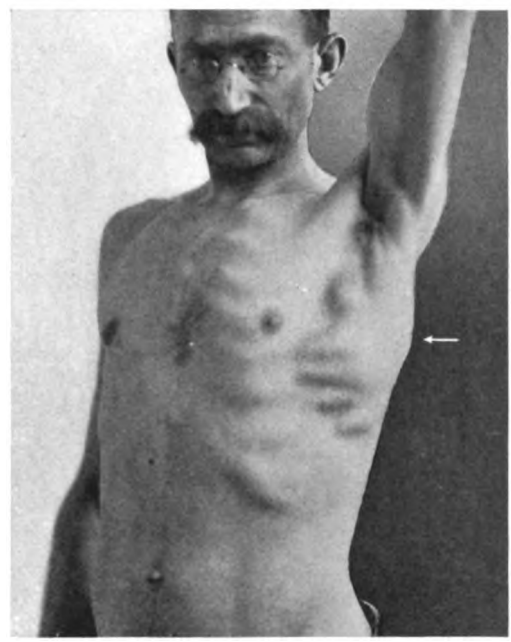

FIG. 136.—PERIOSTEAL SARCOMA INVOLVING FOURTH, FIFTH, SIXTH, SEVENTH, AND EIGHTH RIBS.

The arrow points to the prominence caused by the tumor when viewed in an antero-posterior direction.

Pure **enchondromata** of the ribs are infrequent, but chondrosarcomata are almost as frequent as the pure periosteal variety of sarcoma. They give rise to large and very firm tumors, which enlarge the rib rapidly in all directions. They may grow into the spinal canal and compress the spinal cord.

Secondary tumors of the ribs or sternum belong either to the carcinomata or sarcomata. The diagnosis may be made from the sudden appearance of a growth whose consistency varies according to the nature of the primary growth. This latter should always be searched for in such cases.

Of swellings or tumors arising from within the thorax, the ones of chief interest are **aneurysms** and **pulmonary hernia.** The former can be recognized by the appearance of a prominence over the upper portion of the sternum (see Figs. 138 and 139) or over the second rib which pulsates in the expansile manner characteristic of aneurysms in general, and produces a distinct murmur on auscultation. They must be

differentiated from those rare abscesses of the sternum or rib which have a transmitted pulsation. Their characteristic situation, the presence of murmurs, expansile pulsation, and the confirmatory x-ray examination render a diagnosis easy in the majority of cases.

A pulmonary hernia may appear as an oval swelling in an interspace following a history of injury. It becomes more prominent on coughing, but can be reduced, giving rise to a crackling sound or crepitation. Quite rarely interthoracic lipomata penetrate the chest wall and appear externally.

FIG. 137.—CAPILLARY ANGIOMA OF MAMMARY REGION OF INFANT.

EMPYEMA.

Pus in the pleural cavity may be due to a number of causes.

Causes.—(*a*) *It may follow pneumonia.* It is then due to the pneumococcus, and is called a metapneumonic empyema.

(*b*) *It may occur secondary to other foci of suppuration of the lung or neighboring viscera.* This form is caused by the Streptococcus pyogenes. The infection extends to the pleura either by direct continuity of tissue or by means of the lymphatics. It is in one of these ways that empyema follows an abscess or gangrene of the lung, a subphrenic or hepatic abscess, an appendicitis, a perforation of the esophagus, or a penetrating wound of the thorax. The Streptococcus is often associated with the Staphylococcus aureus. These two, or other organisms such as the typhoid or colon bacillus, may cause an empyema independently.

(*c*) *Tuberculous Empyema.*—This is a variety which is due to the tubercle bacillus, either alone or in conjunction with streptococci or staphylococci.

The **diagnosis** of empyema may be from:

1. The history.
2. The clinical course.

3. The physical examination and results of exploratory puncture.

History.—There is either an accompanying pneumonia, or the history may show that it followed a preceding pneumonia or serofibrinous pleurisy or one of the acute infectious diseases, like typhoid, measles, scarlatina, etc. It may also follow some septic pulmonary or abdominal process or there may be the history of a trauma. There often may be a coexisting pulmonary tuberculosis.

Clinical Course.—The symptoms may have appeared in a slow, insidious, or in an abrupt manner. In the former there is gradually increasing pallor and emaciation. In the acute onset the disease begins with a chill and great prostration.

Fig. 138.—Side View of Case of Aneurysm of the Arch of the Aorta.

After the disease has begun there is a fever of a continuous type in the ordinary purulent form and of an irregular type in the putrid empyemata. In the latter there are frequent chills and remissions of temperature. There is marked leukocytosis. Repeated profuse sweats are quite characteristic.

Physical Examination (see Figs. 140 and 141).—*Inspection* shows diminished movement on the side of the effusion. In children there is often bulging of the intercostal spaces. In left-sided empyema the apex-beat is seen to be displaced to the right beyond the right sternal line. In children there is often a lateral curve of the dorsal spine, the convexity being toward the diseased side.

Palpation.—There is absence of vocal fremitus except in children, where the transmission of the voice sounds is frequently retained. The apex-beat can be felt to be displaced a variable distance to the right in a left-sided empyema.

Percussion.—If the exudate lies between the two adjacent lobes of a lung (interlobar), or between the base of a lung and the diaphragm (diaphragmatic form), it cannot be recognized by percussion. The

area of dullness, or rather flatness (the note being of a wooden quality), may be circumscribed (Fig. 142) or diffuse, according to whether the empyema is encapsulated or not. In the diffuse variety the upper line of dullness is either S-shaped or flat. The liver and spleen are displaced downward.

Auscultation.—Over the area of dullness the breath and voice sounds are absent, while above it they are harsh and exaggerated. In children both of these signs are apt to be misleading because the respiratory murmur and voice sounds are often increased, even tubular in quality.

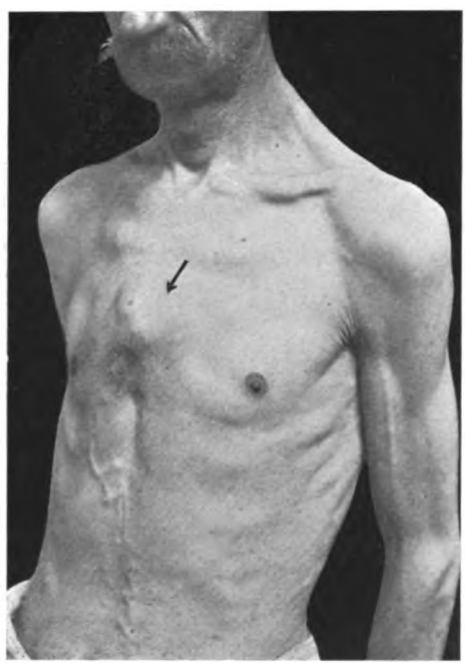

FIG. 139.—FRONT VIEW OF SAME CASE SHOWN IN FIG. 138.

Exploratory Puncture.—This method is of great value. The needle should be of medium length and about twice the caliber of an ordinary hypodermic needle. It should be inserted into the center of the area of dullness in an encapsulated empyema. In the diffuse variety it is best introduced in the sixth interspace in the midaxillary or postaxillary line and the piston gradually withdrawn. If the examination is seen to be negative when the piston has been withdrawn one-third of the way, the needle should be pulled out. One will often find a drop of pus in the tip of the needle when none has been drawn into the barrel of the syringe (Fig. 143).

Differential Diagnosis of Empyema.—(*a*) *From Pneumonia.*—The onset of pneumonia is always sudden, accompanied by a chill, the fever is higher, there is more cyanosis and dyspnea, and the sputum is rusty. The dullness is not so wooden in character, there is less resistance, and vocal fremitus is not absent. In some cases the auscultatory signs, especially in children, may be very confusing. In such patients the voice and respiratory sounds are either plainly to be heard or are even exaggerated. The only way in which such cases, in both adults and children, can be differentiated from empyema is by exploratory puncture.

The same holds true for cases of circumscribed dullness in children due to slowly resolving bronchopneumonia with persistent fever, pallor, and sweats.

(*b*) *From Tumors and Hydatids of the Lung and Pleura.*—Both of these give rise to dullness with suppression of respiratory sounds. The percussion note is, however, even flatter than in empyema and there is greater resistance. There is also no fever or sweats and an exudate, if present as the result of the tumor, is hemorrhagic in character.

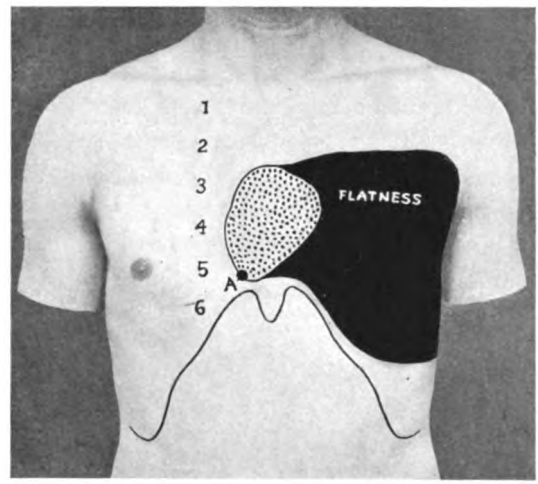

FIG. 140.—AREA OF FLATNESS IN LEFT-SIDED DIFFUSE, THAT IS, NON-ENCAPSULATED, EMPYEMA.

A, Location of apex-beat. The dotted area above it indicates the area of dullness of the displaced heart. The numerals refer to the respective ribs.

(*c*) *Hepatic and Right-sided Subphrenic Abscesses.*—These give rise to dullness and absence of voice and respiratory sounds in the lower portion of the pleural cavity. The area of dullness is, however, quite localized (see Fig. 163) or does not extend very high. There is a history of preceding abdominal infection and the liver is displaced downward far more than is the case in an empyema. The septic symptoms are also usually more marked.

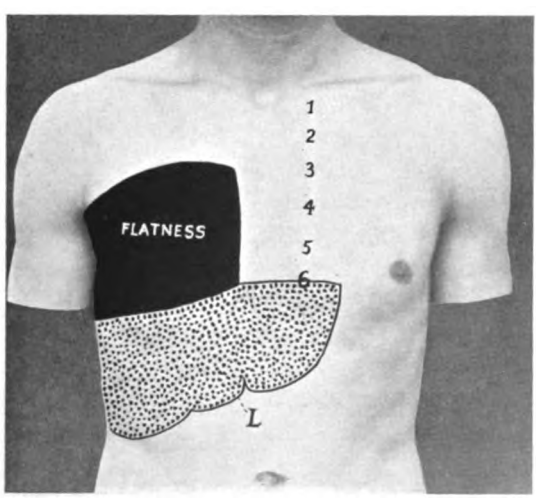

FIG. 141.—AREA OF FLATNESS IN A CASE OF DIFFUSE, THAT IS, NON-ENCAPSULATED, EMPYEMA OF THE RIGHT PLEURAL CAVITY

L, Area of liver dullness, merging above into the flatness of the empyema. The ribs are indicated on the left side by numerals.

The pus from a heptic abscess is chocolate colored; that from an empyema, yellow.

In left-sided subphrenic abscesses the dullness is often most marked at the back of the chest.

An empyema may spontaneously rupture through the pleura and form a subcutaneous fluctuating tumor (see page 204) from the third to the sixth interspace, usually the fifth. When near the heart the tumor may pulsate. On the other hand, the pus may escape along the peripleuritic connective tissue and gravitate toward the abdominal or lumbar muscles, appearing as an abscess in these regions, simulating one following disease of the spine or a perinephritic abscess.

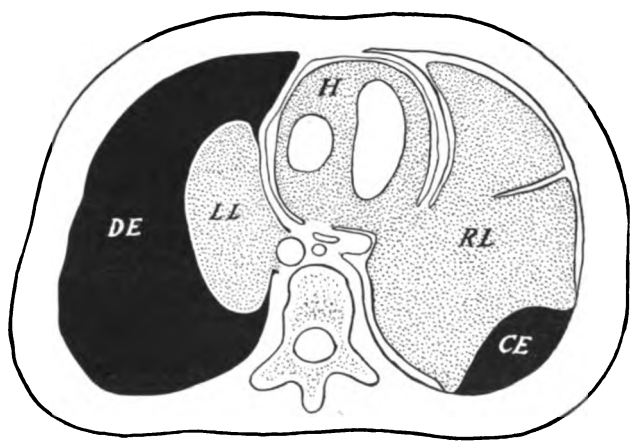

FIG. 142.—LOCATION OF FLUID IN DIFFUSE AND ENCAPSULATED THORACIC EMPYEMATA, AS SEEN IN CROSS-SECTION (DIAGRAMMATIC).

DE, The black area represents the distribution of the pus in a diffuse empyema; *CE*, black area represents the distribution of the pus in an encapsulated empyema; *H*, cross-section of heart; *RL*, right lung; *LL*, left lung (compressed)

TUMORS OF THE PLEURA.

Carcinoma, enchondroma, endothelioma, and rarely lipomata are observed in the pleura. The carcinomata and sarcomata are almost always secondary to the same growths in the ribs, mammary glands, mediastinal lymph-nodes, and lungs. The lipomata may arise from the mediastinal or subpleural fat and project into the pleural cavity.

The diagnosis of tumors of the pleura is very difficult, unless there is demonstrable primary tumor. The symptoms simulate those of a pleural or pericardial effusion, and they are frequently accompanied by more or less exudate, which is hemorrhagic in character, but may be serous. A tumor can be suspected if there is increased resistance when the needle is introduced and by the absence of fever. In the malig-

nant forms of pleural tumors there is rapidly increasing cachexia; the effusion, if present, reaccumulates rapidly; and there are often severe intercostal neuralgic pains due to the tumor growing through the intervertebral foramina.

PULMONARY ABSCESS, GANGRENE, AND BRONCHIECTASIS.

The lesions that present themselves for diagnosis may be classified as follows: (*a*) Acute simple abscesses; (*b*) chronic simple abscesses,

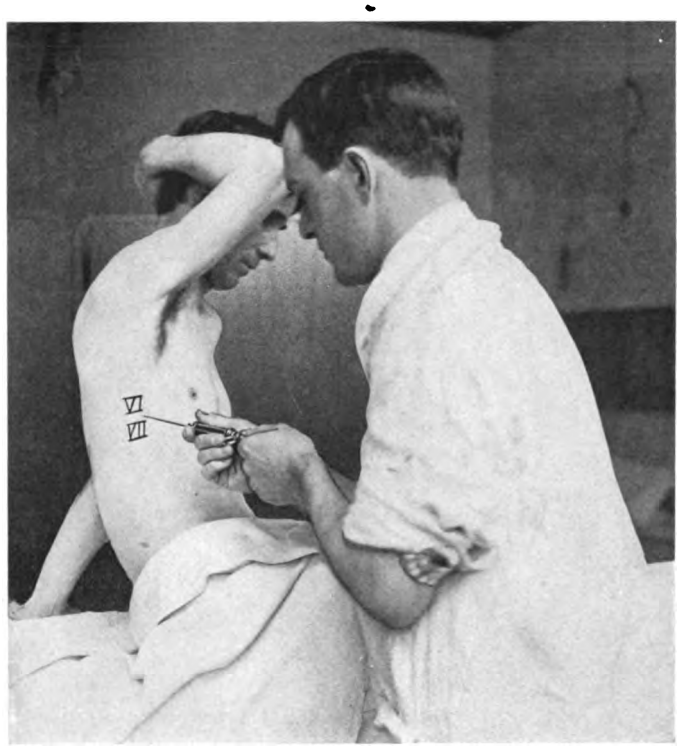

FIG. 143.—METHOD OF PERFORMING EXPLORATORY PUNCTURE OF THE PLEURAL CAVITIES.

After careful disinfection of the area of skin through which the puncture is to be made, the needle should be inserted through either the sixth interspace in the anterior midaxillary or posterior axillary lines. This method can be carried out with the patient either lying down or sitting up, preferably the former. Before inserting the needle, the skin should be pressed against the tissues of the interspace, in order to prevent any slipping and striking of the bone with the point of the needle.

with or without bronchiectasis; (*c*) acute gangrenous abscesses; and (*d*) chronic putrid abscesses, with bronchiectasis. As to the symptomatology of pulmonary abscess, the following is usually the history: A patient who has had pneumonia, for example, of the lower lobe will have his crisis, the physical signs begin to clear up, the temperature

drops, when suddenly the temperature goes up again, becomes of a remittent type, and the sputum becomes more purulent. There may be a distressing cough, accompanied by the expectoration of pus in large quantities. Some elastic fibers may be present in the sputum, but are rare. There are often paroxysms of coughing, with expectoration of several ounces to a cupful of pus. If the abscess cavities

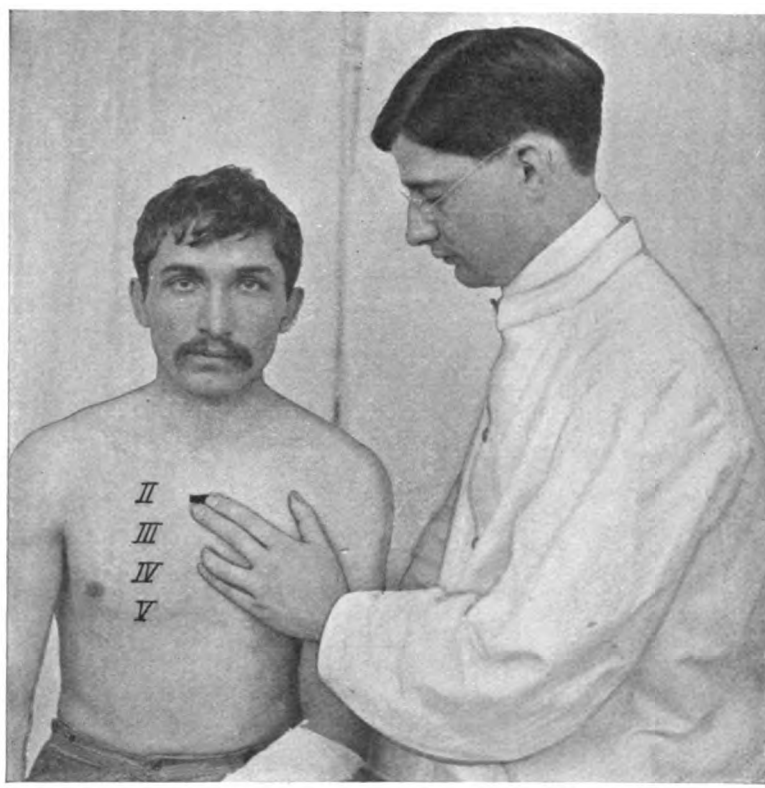

FIG. 144.—METHOD OF COUNTING THE RIBS FOR THE PURPOSE OF DETERMINING THE LEVEL OF FLUID, ETC., IN THE PLEURAL CAVITY.

One usually begins by palpating the angulus Ludovici or prominence at the junction of the first and second portions of the sternum, that is, of the manubrium and gladiolus. By passing the fingers outward one strikes the second rib. From this point down the remainder of the ribs can be readily counted.

do not communicate with a bronchus, there is but little expectoration. There is in all cases emaciation, loss of appetite, and a rapid decline in strength. If the abscess becomes chronic, there may be recurrent attacks of fever, with a great deal of expectoration. Physical examination is rather disappointing. There are few cases in which there are cavity signs present. This is due either to the indirect manner in which the abscess communicates with the bronchus, or to the fact that it

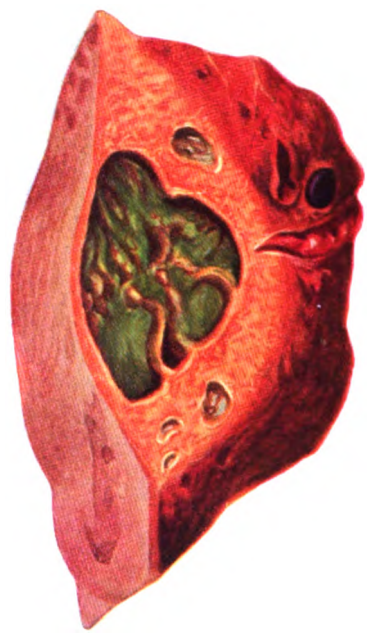

FIG. 144 a.—ILLUSTRATION OF PULMONARY GANGRENE CLOSE TO SURFACE OF PLEURA. Note the greenish color of the wall of the area of pulmonary gangrene and the trabeculæ of surviving lung septa traversing the wall of the cavity.

does not open into one at all. The pulmonary lesions following pneumonia are most frequently in the lower lobes, and this is of some aid. There are no typical physical signs of abscess of the lung owing to the fact that the cavities (whether due to abscess, gangrene, or bronchiectasis) may be near the surface or quite deeply situated, and may or may not communicate with a bronchus. Dullness, decreased respiratory murmur, vocal resonance, and fremitus are present in the majority of cases, but there may be bronchial breathing. The most valuable sign is the presence of rales—large, moist ones, not infrequently metallic in character. Another striking feature is the variability of the physical signs—once dullness, then a tympanitic note over the same spot. A pus cavity, surrounded by aerated lung tissue and not communicating with a bronchus, gives no auscultatory phenomena. Clubbed fingers develop quite early, as do also pressure symptoms on the heart, liver, and spleen. If after a pneumonia the fever either does not disappear or begins again a few days after a crisis, and the sputum and breath become fetid, and the sputum divides itself into the characteristic three layers, gangrene must be suspected. This, as Fränkel has shown, is a frequent sequel of influenza pneumonia. In the sputum of gangrene one can usually find elastic fibers. In bronchiectasis following pneumonia the sputum may be fetid at times, but the odor is not so penetrating and there are no elastic fibers. The physical signs of both pulmonary gangrene and bronchiectasis are usually the same as those of abscess. In a patient with bronchiectasis there is usually a history of long-continued expectoration, with the sudden expectoration of large quantities of pus, at times a cupful. This, however, is not characteristic, for the same may be true of chronic simple abscess. There is said to be more mucus in the sputum of a bronchiectasis, but if there are cavities in the lung tissue due to ulcerations of a bronchiectasis there may be just as much pus as from a simple abscess and, if there is associated gangrene, just as much fetor as in a gangrene. The frequency of hemoptysis in cases of a gangrenous process is due to the fact that the vessels are more apt to pass exposed through the cavity, owing to the more rapid destruction of tissue.

(*a*) The previous history of pneumonia, particularly an influenza pneumonia, and (*b*) the character of the sputum—which in an abscess is of a chocolate color and occasionally contains elastic fiber, and in gangrene becomes more and more offensive as the case progresses—are important points in the establishment of a diagnosis. In bronchiectasis the sputum is at first odorless, but usually becomes foul from the stagnant pus. The localization of the abscess is always

difficult; aspiration is dangerous, the physical signs are not reliable and are often misleading. The *x*-ray is only of confirmatory value, as it shows chiefly thickened areas of lung, and should not be absolutely relied upon. When it shows a shadow at the same point where the physical signs are present, it is of value. The latter may mislead one as to the seat of the abscess, and is of no service in distinguishing between single and multiple foci.

ECHINOCOCCUS OF THE LUNGS.

This localization of the echinococcus is next in frequency to that of the liver and occurs oftenest in the right lower lobe. Clinically it greatly resembles a pleuritic effusion, and a differential diagnosis can be made only by examination of the fluid obtained by exploratory puncture. In the case of echinococcus it is clear, watery, and contains the characteristic hooklets of the worm.

Only large cysts or a collection of smaller ones produce any symptoms. These cause dullness which is more irregular than that of an effusion. There are signs of pressure, such as dyspnea, displacement of the heart and liver, pain, especially upon lying on the diseased side. There is often enlargement of the cutaneous veins over the cyst and widening of the intercostal spaces.

There is no rise in temperature unless the cyst is infected and has ruptured. Then the signs greatly resemble those of a cavity in the lower lobes.

ACTINOMYCOSIS OF THE LUNGS AND PLEURA.

This disease may appear clinically in one of two forms:

(*a*) A peribronchial pneumonic form in which the symptoms resemble those of tuberculosis. The diagnosis can only be made if the ray fungus is found in the sputum.

(*b*) A second clinical form in which the disease has extended into the pleural cavity and chest wall. The signs are those of a pleurisy but without effusion, or there is a board-like infiltration of the chest wall followed by the appearance of subcutaneous abscesses. The spontaneous perforation of the latter leaves sinuses which may be confused with those of tuberculosis. The finding of the ray fungus will clear up the diagnosis.

TUMORS OF THE LUNGS.

Tumors of the lungs are almost always malignant, and rarely primary.

Secondary growths are usually disseminated over both lungs, while primary ones occupy the greater part of one lung. The diagnosis of the presence of secondary tumors depends upon (*a*) the appearance of pleuritic pain; (*b*) cyanosis; (*c*) dyspnea; (*d*) cough, and (*e*) the signs of effusion following a year or more after a primary tumor of the breast, limbs, etc., has been diagnosed as such. A primary growth of the lungs shows unilateral involvement with signs of consolidation, but the tactile fremitus is absent and the breath sounds are diminished in intensity. There is prune-juice expectoration, emaciation, and enlargement of the adjacent cervical lymph-nodes.

SUPPURATIVE PERICARDITIS (PYOPERICARDIUM).

Fluids, whether pus or serum, lying within the pericardial sac cause the same physical signs.

Purulent pericarditis may (*a*) be pyemic in origin, or (*b*) follow a penetrating wound of the pericardium, or (*c*) arise by extension from a neighboring focus.

Perforation of the thoracic wall may occur, giving rise to sinuses or abscesses.

Purulent pericarditis occurring during the course of a septicopyemia cannot be recognized except from the physical signs, or if attention has been called to the heart by the accelerated, feeble, and often irregular pulse.

In the other varieties there are usually repeated chills accompanied by high fever and sweats. The pulse and respiratory rate are rapid. Cases occasionally occur with normal pulse, temperature, and respiration. When an exudate previously serous becomes purulent, there are chills with considerable fluctuations of temperature, pulse, and respiration, accompanied by sweats, a rapid emaciation, and leukocytosis.

The physical signs of pyopericardium are bulging of the precordial space, especially in children, the apex-beat cannot be felt, the area of cardiac dullness is greatly increased and pear-shaped, the base being downward, and the heart sounds are very weak.

Exploratory puncture of the fourth and fifth left interspaces, one inch from the sternal margin, shows the presence of pus. The xiphocostal route is, however, used by many, the needle being inserted at

the right xiphocostal angle. There is no danger of wounding the liver or diaphragm, because these are depressed in pyopericardium (Fig. 145).

AFFECTIONS OF THE MEDIASTINUM.

Two conditions of this region frequently require to be recognized by the surgeon as well as by the physician. These are inflammatory affections and tumors.

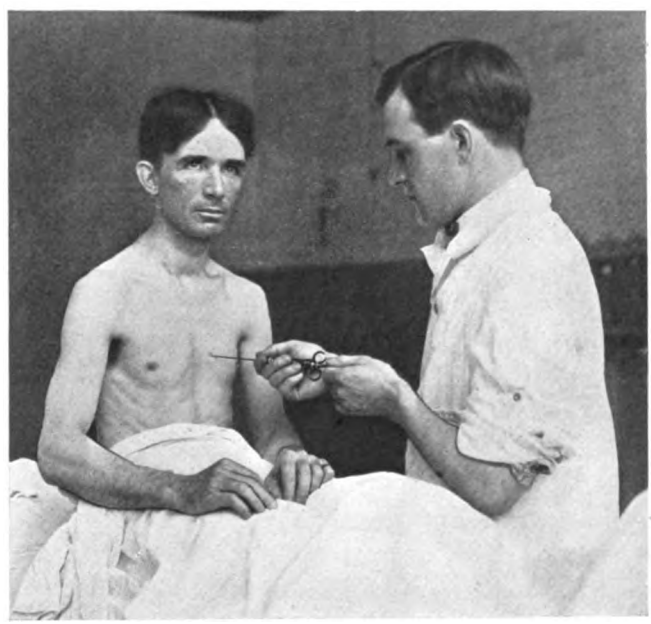

FIG. 145.—METHOD OF PERFORMING EXPLORATORY PUNCTURE OF THE PERICARDIUM, IN ORDER TO DETERMINE THE NATURE OF A PERICARDIAL EXUDATE.

The patient can be thus explored either in a recumbent or upright position. The needle should be inserted in either the fourth or fifth interspaces close to the sternum, great care being taken not to insert it too deeply.

INFLAMMATORY PROCESSES.

These may be either acute or chronic. The former are caused by the ordinary pyogenic organisms and arise by extension of suppurative processes in the neck or rarely from an acute osteomyelitis of the ribs or sternum. From the neck, pus may reach the mediastinum either along the carotid sheath or along the previsceral or retrovisceral spaces. The symptoms of acute mediastinitis are severe pain and a feeling of oppression behind the sternum radiating to the shoulders. This is accompanied by fever, chills, sweats, rapid pulse, and other signs of

a septic infection. The diagnosis may be made from these symptoms, taken in conjunction with the history of a preceding infection in the adjacent parts.

Chronic inflammatory processes are almost always due to tuberculous disease of the bronchial lymph-nodes and are impossible to recognize unless they rupture into the bronchus, aorta, or esophagus.

TUMORS OF THE MEDIASTINUM.

All tumors of the mediastinum cause somewhat similar symptoms. Their severity depends upon the size and nature of the growth.

The most frequent conditions which thus appear with signs of intrathoracic pressure are the following:

Benign Affections.	Malignant Affections.
1. Retrosternal goiter.	1. Carcinomata.
2. Dermoid cysts.	2. Sarcomata.
3. Echinococcus cysts.	3. Hodgkin's disease.
4. Aneurysms of the arch of the aorta.	
5. Fibroma.	

The diagnosis in the case of the malignant affections depends (*a*) upon the greater rapidity with which the symptoms of pressure appear, (*b*) the more frequent association of pleuritic effusion, and (*c*) in many cases the history of primary growths situated elsewhere in the body.

The symptoms in general of mediastinal tumors are:

1. Engorged veins on the anterior and lateral portions of the thorax, sometimes accompanied by cyanosis and edema of the skin (see Fig. 146).

2. A marked dyspnea, associated often with a harsh, brassy cough.

3. Symptoms of pressure on the recurrent laryngeal nerves cause abductor paralysis of one or both vocal cords, usually the left.

4. Dysphagia through pressure on the esophagus.

5. Dullness over the upper portion of the sternum or adjacent portion of the thorax (Fig. 146).

6. In some cases the *x*-ray shows a distinct shadow.

7. The heart and lungs may be displaced.

8. There may be a bulging which may or may not pulsate. If it does, it has the forcible expansile pulsation of an aneurysm (Fig. 138).

9. Palpation of the suprasternal notch and of the deep cervical nodes may confirm the suspicion of a tumor.

When an aneurysm has not eroded the chest wall it may be almost impossible to differentiate it from a tumor. The cyanosis and venous enlargement are more marked in tumor and these symptoms are more

progressive. The most valuable signs of aneurysm are the diastolic shock to be felt and often heard over the sac, and the radiating pains to the arms and neck.

Dermoid or echinococcus cysts may occasionally be recognized by finding hairs or hooklets respectively in the sputum. A case of dermoid cyst has been recently reported by Senn in which the diagnosis was made by finding hair in the sputum.

FOREIGN BODIES IN THE AIR PASSAGES.

The diagnosis of foreign bodies in the larynx, trachea, or bronchi depends (*a*) upon the history, (*b*) upon the appearance of certain symptoms of disturbances in function, and (*c*) the results of examination with the *x*-ray, the laryngoscope, and the bronchoscope (Fig. 91).

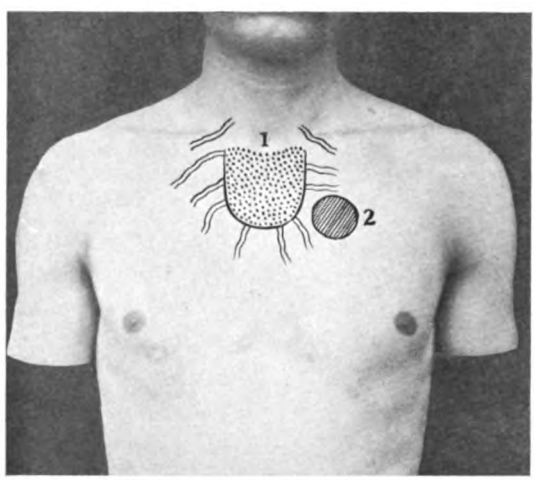

FIG. 146.—LOCATION OF AREA OF DULLNESS IN MEDIASTINAL TUMOR AND OF PROMINENCE IN ANEURYSM OF THE ASCENDING ARCH OF THE AORTA.

1, Area of dullness over manubrium in a case of sarcoma of the mediastinum. The outlines running toward it represent the dilated veins of the skin of the thorax. 2, This figure is placed to the left of the most frequent seat of prominence due to aneurysm of the ascending portion of the arch.

In the majority of cases there is a history of the aspiration during an inspiratory effort of one of four varieties of foreign bodies.

(*a*) Round or conical bodies—*e. g.*, coins, buttons, tin whistles, and bullets.

(*b*) Sharp bodies, as pins, needles, tacks, and splinters.

(*c*) Vegetable substances which swell, such as seeds or beans.

(*d*) Vegetable substances which do not swell, as wheat, etc.

The symptoms vary greatly. In some cases there are frequent attacks of asphyxia. Especially is this the case with the first class referred to and in the initial period. In other cases these attacks of suffocation may be absent. If the body lodges in the right bronchus, as is most often the case, there is a diminution or even complete loss of respiratory sounds and movements on the same side. Over the point

of its arrest sibilant and sonorous rales may be heard. Sharp bodies at times cause localized pain, while larger obstructing bodies cause a sense of pressure. Cough is quite frequently present, and the expectoration may be bloody from erosion of the bronchi.

After noting the history and the symptoms an examination should be conducted with the laryngoscope. If this results negatively an *x*-ray picture is taken. If the latter is also negative the patient should be anesthetized and the Killian bronchoscope employed to find the location of the foreign body.

In the absence of a history one must at times suspect the presence of a foreign body from the symptoms of a circumscribed bronchopneumonia or bronchiectasis or abscess formation without other causes.

DISEASES OF THE BREAST.

INFLAMMATORY PROCESSES.

These may be of four varieties: (1) Acute puerperal mastitis, (2) acute mastitis of infants, (3) traumatic mastitis, and (4) chronic mastitis.

1. **Acute Puerperal Mastitis.**—This occurs most frequently during the first months of lactation. The acute inflammatory process may be located in one of three places (see Fig. 147):

(*a*) In the subcutaneous tissue of the areola.

(*b*) In the gland parenchyma proper.

(*c*) In the retromammary space.

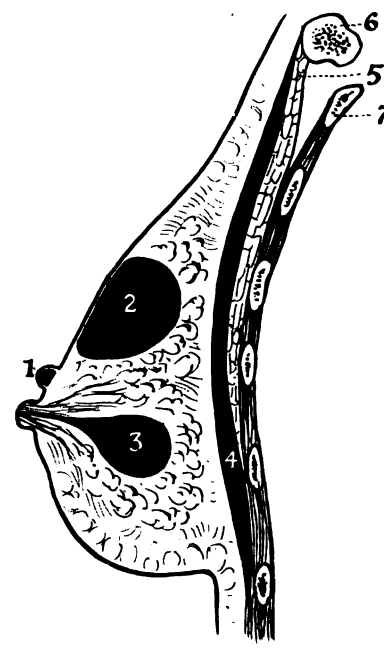

FIG. 147.—SEATS OF VARIOUS FORMS OF SUPPURATION IN MASTITIS.

1, In subcutaneous abscess of areola; 2, large parenchymatous abscess approaching surface of breast; 3, seat of suppuration in early stages of ordinary parenchymatous mastitis, showing how infection is transmitted from nipple along milk ducts; 4, retromammary abscess, lying between breast and pectoralis major muscle; 6, cross-section of clavicle; 7, cross-section of first rib (modified from Duplay).

The diagnosis of the first named is simple. An area of redness and painful swelling of the areola occurs which is at first hard and then becomes soft. Infection of the gland proper, to which one usually refers in speaking of mastitis, most often follows a small painful fissure or crack in the nipple. Not infrequently the disease begins with a chill; a rise of temperature to 103° or 104°, and severe pain in the breast

in a woman in whom there is the history of a preceding fissure. The breast becomes extremely tender to the touch and the severe pain radiates toward the axilla.

In the early stages there are distinctly indurated and usually multiple areas to be felt in the breast, which can be distinguished from the nodules due to stagnation of milk, or so-called "caking of the breast," by the more severe inflammatory symptoms, such as pain, fever, etc.

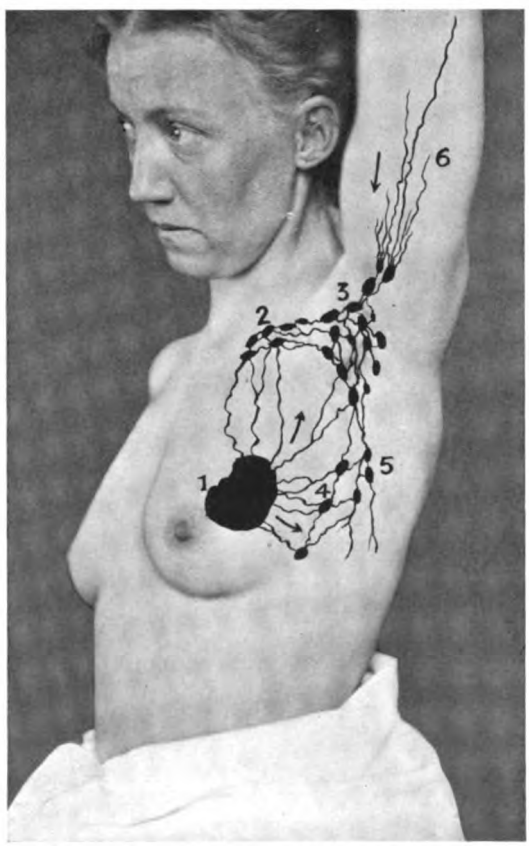

FIG. 148.—LYMPHATICS OF FEMALE BREAST.

1, Carcinoma in outer upper quadrant; 2, supraclavicular lymph-nodes; 3, axillary lymph-nodes; 4, nodes along the lower border of pectoralis major; 5, nodes along the latissimus dorsi; 6, lymphatics of arm. The arrow between 1 and 3 shows the direction of the lymph-current from the breast toward the axillary and supraclavicular nodes; the arrow between the breast and 4 shows the direction toward the corresponding nodes. The arrow from 6 to 3 shows direction of lymph-current from arm infections toward the axillary nodes.

Another point of differentiation is the fact that massage and proper support will be followed by speedy disappearance of symptoms in the "caked" breast, while in the true mastitis they persist and increase in severity.

In puerperal mastitis, in addition to the severe pain in the breast, induration, and rise of temperature, there is a painful enlargement of the pectoral and axillary lymph-nodes (Fig. 148). After a few days of the above symptoms the indurated areas become larger and approach the overlying skin. This becomes red and tender, and soon evidences of fluctuation can be obtained, showing that abscess formation has occurred. If after one of these foci has been opened the temperature persists, abscesses elsewhere must be present with retention of pus.

There are cases of puerperal mastitis in which a discharge of pus continues from multiple foci months after the abscesses have been opened. These are the result of a venous congestion due to allowing the breast to sag by not being sufficiently compressed and supported.

The retromammary form of acute mastitis is not frequent. It can be recognized by the absence of foci in the areola or parenchyma, although there is marked swelling along the periphery of the breast, accompanied by pain and high fever. Fluctuation appears at the lower margin. At times chronic retromammary abscesses are met with, due in the majority of cases to tuberculosis of the ribs.

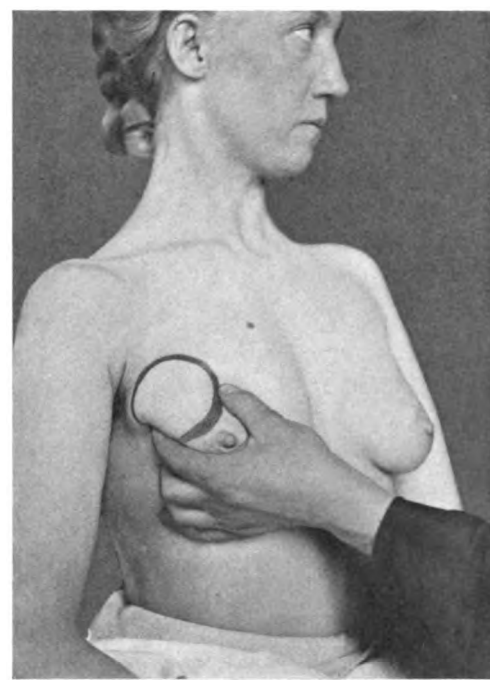

FIG. 149.—METHOD OF PALPATING A TUMOR OF THE BREAST (CYST).

2. **Mastitis Neonatorum.**—During the second to fourth week painful enlargement of the breast occurs in both male and female infants. The breast enlarges to the size of a walnut, is quite hard and tender. This enlargement generally disappears within a short time, but may rarely go on to suppuration, giving rise to redness of the surface and fluctuation.

3. **Traumatic Mastitis.**—After a blow or fall upon the breast of non-pregnant women the organ becomes enlarged, quite painful, and may be accompanied by slight rise of temperature. The diagnosis may be made from the history, the local tenderness, and the frequent general enlargement and palpation of tender indurated areas in the parenchyma.

Chronic Mastitis.—This condition is one which has been described by various writers under different names. Koenig has called it "chronic cystic mastitis"; Reclus describes it as "maladie cystique"; Virchow, as "diffuse fibroma"; others have termed it "chronic inter-

stitial mastitis"; and, finally, the term "diffuse fibroadenoma" has been given to it.

From a pathologic standpoint[1] there are three types:

1. A low grade of inflammation with desquamation of the glandular epithelium and the formation of cysts. This is the form described by Koenig as a chronic cystic mastitis.

2. Those of a more adenomatous type described by Schimmelbusch and Reclus.

3. Transition cases. In these the breast may show a diffuse fibroadenomatous condition, but in certain areas a malignant change, *i. e.*, to carcinoma, has taken place. In thirty cases examined microscopically by Greenough[2] such a malignant change had occurred in three.

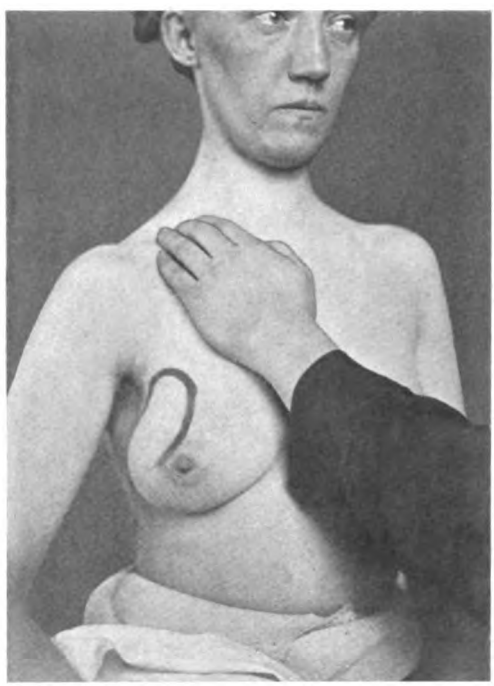

FIG. 150.—PALPATION OF SUPRACLAVICULAR LYMPH-NODES IN THE FEMALE, IN CASE OF SUSPECTED CARCINOMA OF THE BREAST.

This condition occurs predominantly in women who have borne children, but not nursed them, and especially often just before the menopause. It may, however, occur in nulliparæ. In some cases there is an apparent exacerbation at the time of menstruation, new nodules appearing and the breasts becoming painful, the condition subsiding rapidly in the menstrual intervals. Clinically, one can feel a number of flat leathery nodules in one or both breasts, which may be quite sensitive. The patients will often state that the nodules become painful during the menses, accompanied by an enlargement of the axillary and pectoral lymph-nodes (Figs. 150 and 151).

If a cyst of any size (Fig. 149) is present, it feels tense and elastic.

[1] Curtis and Wood: "Medical News," August 13, 1904.

[2] Greenough and Hartwell: "Journal of Medical Research," June, 1903.

If a number of smaller cysts have been formed they feel like beans or shot (Curtis). The principal affection from which it must be differentiated is carcinoma.

This question is especially apt to arise if one or more large cysts have formed. The condition can be, however, distinguished from carcinoma by the following features:

1. Chronic mastitis is usually bilateral, or if not, there are many nodules in a single breast which are frequently quite tender.

2. The nodules, if cystic, have a distinct smooth, rounded form, and unless very tense show fluctuation.

3. The size and tenderness of the nodules often increase during menstruation.

4. The axillary nodes, if enlarged, are soft and tender.

5. The progress of the disease extends over years, unless large cysts are present.

There are a few exceptions; for example:

1. Cases in which there is marked induration and sharp demarcation.

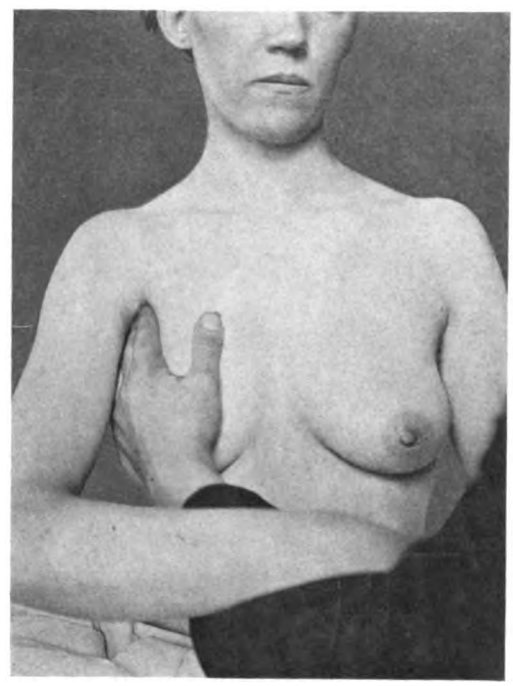

FIG. 151.—PALPATION OF AXILLARY GLANDS IN THE FEMALE.

2. Cases in which carcinomatous changes have already occurred (transition cases), either in one of the breast nodules or in the axillary nodes alone.

In such cases it is absolutely impossible to differentiate between a chronic cystic mastitis and carcinoma until marked retraction and fixation of the nipple and marked induration of the tumor and of the axillary nodes have occurred.

TUBERCULOSIS OF THE BREAST.

Of 100 reported cases of this rare condition, only 65 have been examined microscopically. It involves the gland most frequently at

the period of life (twenty to forty) of its greatest activity. The course is a very chronic one. It either occurs in (*a*) a nodular form; (*b*) as a cold abscess; (*c*) confluent form (most common); (*d*) miliary.

The diagnosis is rarely made before either an abscess has formed or sinuses exist. Usually the case is supposed to be a fibroadenoma in the nodular form or is diagnosed as a chronic cystic mastitis (especially in the more confluent form) before operation. Sinuses, if they exist, have the typical bluish undermined edges of tubercular lesions.

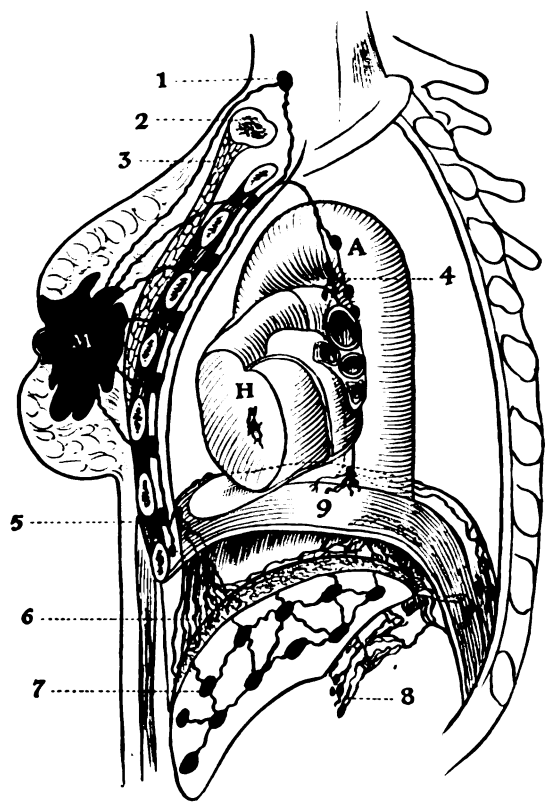

FIG. 152.—RELATION BETWEEN LYMPHATICS OF FEMALE BREAST AND THOSE OF MEDIASTINUM AND LIVER.

M, Carcinoma of breast, causing retraction of nipple; 1, lymph-nodes of supraclavicular fossa; 2, cross-section of clavicle; 3, pectoralis major muscle; 5, lymph-nodes along the internal mammary artery; A, aorta; 4, lymph-nodes at bifurcation of trachea; these may cause dyspnea and cough after carcinoma of breast; H, heart, seen in section; 6, lymphatics of upper surface of liver, which receive the lymph from the mediastinal nodes through the diaphragm; 7, metastatic foci in the liver; 8, lymph-nodes at porta hepatis; 9, lymph-nodes, along aorta (modified from Kuttner and Duplay).

In every case the axillary lymph-nodes are enlarged, but if these are absent the diagnosis may be very difficult.

Simple cysts resulting from chronic mastitis are more circumscribed, fluctuate much sooner, are often painless, and do not enlarge the axillary nodes. When the cysts are small and tender, the differentiation is very difficult. In tuberculosis there is, however, early axillary lymph-node enlargement.

From the scirrhus form of carcinoma this condition can be distinguished by the fact that tuberculosis occurs in younger persons, is never as indurated, and there are more apt to be multiple nodules.

From actinomycosis it can be distinguished by finding the ray fungus in the yellow granules and by the thickened indurated skin.

HYPERTROPHY OF THE BREASTS.

This condition can be readily recognized, owing to the enormous bilateral increase in the size of the breasts. It occurs most often at puberty or shortly thereafter. It may be simulated by a retromammary lipoma, but this is only unilateral. The breast may increase so rapidly in size that within a year it increases ten to twenty pounds, or even more, in weight, and extends down as far as the knees.

A hyperplasia of the male breast occurs on either one or both sides, and causes pain and discomfort.

FIG. 153.—RETRACTION OF NIPPLE IN A CASE OF CARCINOMA OF THE BREAST.
The arrow points downward toward the retracted nipple.

NEOPLASMS OF THE BREAST.

These are best divided into two great classes, the benign and the malignant. To the former belong the fibroadenoma, with its special forms, the fibroma intracanaliculare, and the papillary form.

To the second or malignant group belong the sarcoma and carcinoma.

BENIGN NEOPLASMS.

Fibroadenoma of the Breast.—Pure fibromata and pure adenomata are very rare. The majority of these tumors contain both forms of tissue, but usually more of the fibrous than of the glandular.

The chief diagnostic points are:

(*a*) Age. They generally occur between twenty and thirty.

(*b*) Growth. As a rule, the increase in size is very slow and gradual. In some cases they remain dormant for many years, and then suddenly increase in size. Apparent recurrence may take place, but these are undoubtedly new tumors.

(*c*) Mobility, consistency, and form. They are usually quite firm and round, or oval. The larger they grow, the softer do they become. The nearer the skin they lie, the more movable are they. As a rule, they are not painful and are never as hard as a carcinoma. When removed, they are found to be distinctly encapsulated.

(*d*) They never cause retraction of the nipple or enlargement of the axillary lymph-nodes.

Even in the unusual pathologic forms of fibroma intracanaliculare, simple or papillary, the same clinical signs above described are retained.

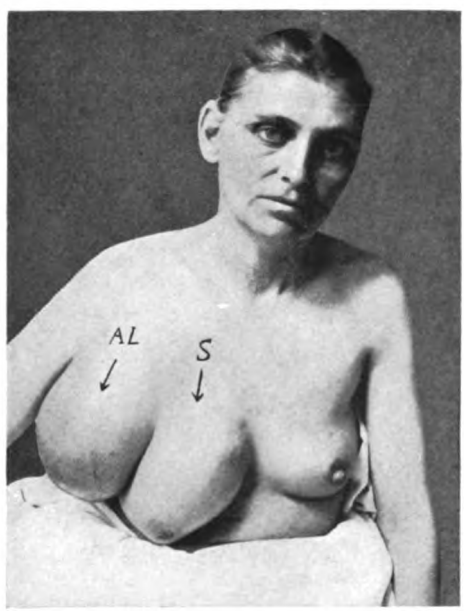

FIG. 154.—ANTERIOR VIEW OF CASE OF SARCOMA OF THE BREAST.

Note the enormous enlargement of the right breast (*S*), and the large tumor of the axilla (*AL*), due to secondary enlargement of the axillary lymph-nodes.

MALIGNANT NEOPLASMS.

Sarcoma of the Breast.—These constitute about 2 to 8 per cent. of all breast tumors and are usually of the round-celled type. They occur before the age of thirty, and are characterized by their rapid growth and the early ulceration of the overlying skin. The entire breast is usually involved, causing it to feel uniformly firm. Enlargement of the axillary lymph-nodes is not frequent, but when present the secondary tumor attains enormous size.

Carcinoma of the Breast.—The best division of this form of neoplasm from a clinical point of view is into a scirrhus or hard, and a medullary or softer variety. Colloid carcinoma may occur, but is relatively rare and cannot be diagnosed as such before operation. The chief diagnostic points of carcinoma are:

(*a*) *Age.*—The medullary form usually occurs in women between thirty-five and fifty-five, while the scirrhus variety occurs after the latter age. Carcinoma more frequently affects the breast of women who have nursed children, or have had infections or chronic cystic mastitis (page 223). There is undoubtedly a direct relation between cancer of the breast and trauma.

(*b*) *Location and Growth.*—The disease usually begins as a single nodule, most frequently in the inner quadrants of the breast. If the carcinoma begins in the ducts instead of the acini, there is early fixation and induration around the nipple.

This duct or tubular form of carcinoma is the one usually found in the male. It is less frequent than the deeper acinous form in the female breast.

The carcinomatous nodule is usually single.

The rate of growth is far more rapid than in the case of benign tumors. In the medullary form this is more marked than in the scirrhus.

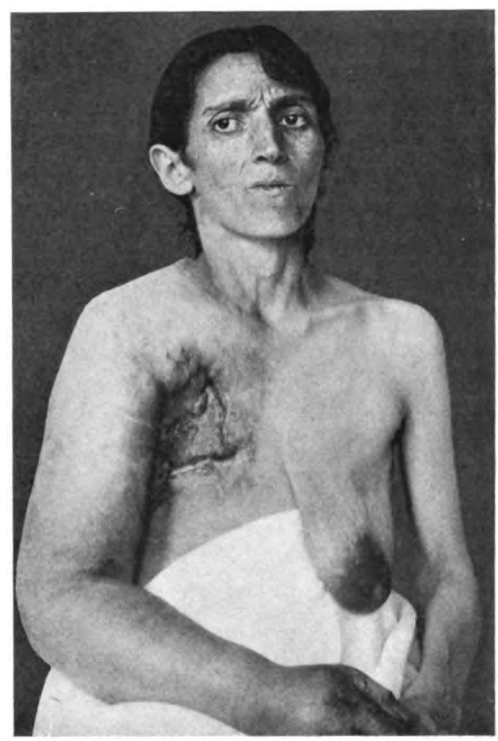

FIG. 155.—EDEMA OF THE RIGHT ARM DUE TO COMPRESSION OF AXILLARY VEINS, TWO YEARS AFTER OPERATION FOR CARCINOMA OF THE BREAST.

Note the great difference in size between the right and left arms.

(*c*) *Mobility, Consistency, and Form.*—In the early stage the tumor is hard and somewhat movable. It soon becomes adherent to the skin (especially around the nipple in the scirrhus form) and to the underlying pectoral muscle (Fig. 152). In the medullary form the tumor is much softer than in the scirrhus form. Ulceration of the overlying skin may occur at an early stage. At first the tumor is more or less rounded and can be distinctly outlined. Later it becomes nodulated and diffuse.

(*d*) *Condition of the Nipple and Regional Lymph-nodes.*—In the scirrhus more frequently than in the medullary form the nipple is both fixed and retracted. Ulceration may occur quite early at this point (Fig. 153). Pain is an early and marked symptom in carcinoma.

There is early enlargement of the axillary and less often of the supraclavicular lymph-nodes (Figs. 148, 150, and 151).

A systematic examination of these regions, as well as of the liver, if

palpable, should be made (Figs. 150 and 151) for evidence of lymph-node and visceral metastasis. The carcinomatous lymph-nodes are very hard and often adherent to each other.

(*e*) *Complications.*—In addition to the early cachexia, cancer of the breast may produce metastases in the following places:

1. In the mediastinal lymph-nodes, causing cough and dyspnea (see Fig. 152).

2. In the lymphatics of the skin of the breast.

The skin of the entire front of the chest has a board-like consistency and has been called "cancer encuirasse" (armor-like cancer).

3. Metastases in the lungs, liver, pleura, and brain.

4. Osseous metastases. If in the long bones, spontaneous fractures may occur after the most trivial injury. If the deposit occurs in the spine or skull, symptoms of pressure upon the spinal cord or brain occur when there has been no suspicion of a metastasis. A so-called *paraplegia dolorosa* is quite characteristic.

5. *Edema of the hand* (Fig. 155) from pressure of carcinomatous lymph-nodes on the axillary vessels.

DIFFERENTIAL DIAGNOSIS OF TUMORS OF THE BREAST.

	Chronic Cystic Mastitis.	Fibroadenoma.	Carcinoma.
Age	Usually before forty, but may occur before menopause, often more painful and larger during menses.	In young women.	Generally over forty, rarely before that age; accompanied by cachexia.
Location and growth	Multiple nodules in one or both breasts. Very slow growth, except in large cysts.	Anywhere. Grow very slowly.	Usually in inner quadrants. Grow rapidly.
Mobility	Not movable in breast unless one or more large cysts—then only moderate mobility.	Freely movable.	Movable in very earliest stage; later adherent to skin or pectoral muscle and fixed in breast.
Consistency and form	Large cysts either are round and fluctuate or are elastic. Smaller multiple nodules feel like beans.	Not as hard as carcinoma; outline rounded and sharp.	Very hard, irregular, and not demarcated.
Condition of nipple, and pain	Very rarely retracted. Tumors often painful, especially at menses.	No change. No pain, as a rule.	Early retraction. Often pain, quite severe and early.
Condition of axillary lymph-nodes and metastases	Earlier enlargement than in cancer. Tender and soft. Often more painful during menses.	Not enlarged, as a rule.	Early enlargement. Induration very marked. Evidence of metastases (see page 230).

CHAPTER IV.

THE ABDOMEN.

AFFECTIONS OF THE ABDOMINAL WALL.

INFLAMMATORY PROCESSES.

Furuncles of the skin of the abdomen do not differ from those found elsewhere. It is interesting to note that they cause early enlargement of the inguinal lymph-nodes which rapidly disappears as soon as the furuncle is incised and drained.

Subcutaneous suppuration is usually secondary to an infected wound or to some more deeply seated infective process. There is more or less induration, so that it is difficult to detect fluctuation. There is also superficial pain, redness, fever, and enlargement of the inguinal lymph-nodes.

In the abdominal wall proper, suppuration may occur in a number of distinct spaces.

1. *Within the sheath of the recti muscles* following typhoid, or, rarely, an injury. The pus can only spread as far as the umbilicus, where it may perforate. The previous history, the location of the swelling, pain, and other inflammatory signs render a diagnosis easy. The swelling is more prominent when the patient lies down.

2. *Retromuscular Suppuration.*—The pus lies in the loose connective tissue between the individual muscle layers or between the transversalis fascia and peritoneum. All of these spaces communicate with each other freely and also with the connective tissue of the pelvis, iliac fossæ, and retroperitoneal space. A special space, known as the prevesical or cavum retzii, is often spoken of as being separated from the retromuscular space by a septum (see Fig. 156), but such a division is not found clinically, pus in one of these spaces spreading by direct continuity to any of the others. With the exception of the rare cases of idiopathic suppuration in the prevesical space, the majority of the cases of suppuration in the intermuscular and retromuscular spaces are secondary. They may be due to a number of different primary causes, which it is well to remember in making a diagnosis.

(*a*) If prevesical, to cystitis or diseases of the prostate or seminal vesicles.

(*b*) If around the kidney, it is the result of an infection of the perinephritic tissue following some renal infection such as perinephritis.

(*c*) If in the retroperitoneal connective tissue of the iliac fossa it may be due (*α*) to suppuration of the deep iliac lymph-nodes following phlegmon of the thigh or an inguinal adenitis; (*β*) to tuberculosis or osteomyelitis of the pelvic bones.

(*d*) It may be due to disease of the ribs or spine or to a spontaneously perforated empyema (empyema necessitatis).

(*e*) Secondary to perforations of the gall-bladder, intestine, appendix, stomach, and cecum. This group includes actinomycosis following primary intestinal disease.

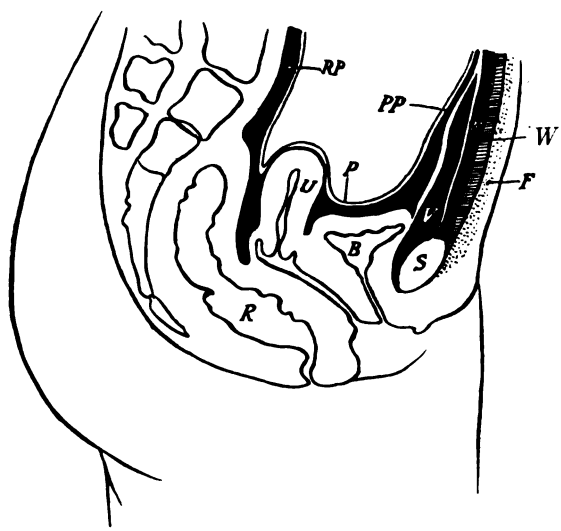

FIG. 156.—LOCATION OF ABSCESSES IN ABDOMINAL WALL, ETC

R, Rectum; *U*, uterus; *B*, bladder; *S*, symphysis pubis; *F*, skin and subcutaneous tissues; *W*, muscles of abdominal wall; *M*, retromuscular abscess; *V*, prevesical abscess; *PP*, properitoneal abscess; *P*, peritoneum; *RP*, retroperitoneal suppuration extending upward from pelvis.

(*f*) Secondary to infections of the uterus (especially puerperal) and of the adnexa. Puerperal infection may cause a pelvic abscess which spreads to the connective tissue of the iliac fossa and retroperitoneal space (see Fig. 156).

(*g*) The pus may collect in the extraperitoneal subphrenic tissue secondary to appendicitis or hepatic abscess. This is comparatively rare.

The diagnosis in all of these is dependent upon the history and the presence of general and local symptoms of suppuration.

Prevesical abscesses (see Fig. 156) give rise to an area of dullness of oval form like that of the distended bladder. There is local pain, tenderness, and fever. When the bladder is emptied the tumor still remains. The pus may rupture into the bladder or into the intestine. The tumor can be felt through the rectum or vagina. Inquiry into the history will usually result in finding a primary focus in the bladder, the generative organs, the bones of the pelvis, or the intestine.

In all of the other forms of suppuration within or behind the abdom-

inal muscles the diagnosis may be made from the appearance of a more or less circumscribed area of induration, accompanied by fever, pain, tenderness, and rigidity of the corresponding portion of the abdominal wall. Careful search will usually elicit the primary source of infection. If there is pus, or even in the case of a tumor in the abdominal wall, both are more prominent when the patient lies down. In the majority of the forms of suppuration in or behind the abdominal wall the diagnosis can be made from the history of a primary infection, the presence of a circumscribed or diffuse infiltration, pain, tenderness, and fever.

TUMORS OF THE ABDOMINAL WALL.

These may occur either in the skin itself or in the deeper layers. Those of the skin are usually *soft pedunculated fibromata* which vary greatly in size and number. Their soft consistency, slow growth, and pedunculation render their recognition easy (Fig. 375). *Pigmented nevi* also occur with considerable variation in size and number. They are of a brownish color, slightly raised above the surrounding skin, and often have long hairs growing from their surface.

Both soft fibromata and pigmented nevi tend to become sarcomatous at times. Such a change can be recognized from the rapid growth of the tumor as well as the tendency to ulceration of the surface. The deeper forms of neoplasms are lipomata and desmoids. *Lipomata* occur as subcutaneous, intermuscular, and subserous growths. The two first named may be recognized by their soft, almost semifluctuating consistency, and especially by their lobulated surface, most marked, as in all lipomata, when the overlying skin is slightly stretched. The subcutaneous lipomata occur most frequently in the median line. They are also lobulated, and cause pain, which is often referred to the stomach.

They may be differentiated from herniæ of the linea alba or umbilical hernia by palpation (Fig. 157). In the case of a hernia there is a distinct thrill on coughing and the contents can be reduced into the abdominal cavity unless they are adherent to the sac. In such cases, and when linea alba herniæ become strangulated, a differential diagnosis from lipomata is almost impossible before operation. The occurrence of subserous lipomata in inguinal and femoral herniæ is frequently found at operations for the radical cure of these conditions, but they are seldom recognized before operation.

Desmoids are peculiar forms of fibroid tumors, occurring chiefly in women between fifteen and fifty who have borne children. They rarely occur in men. The majority are in the front part of the abdomen

below the umbilicus. They are oval in form and vary in size from a hen's egg to that of an adult's head. As a rule, they are hard, but may soften so that cysts are formed which may be hemorrhagic.

They may follow trauma, laparotomy or herniotomy operations, or the prolonged pressure of a belt. They may be painful, especially at the time of the menstrual period. The diagnosis depends on their firm character (the softer cystic degeneration being exceptional) upon the smooth surface, and the fact that they grow in the direction of the corresponding aponeurosis or scar.

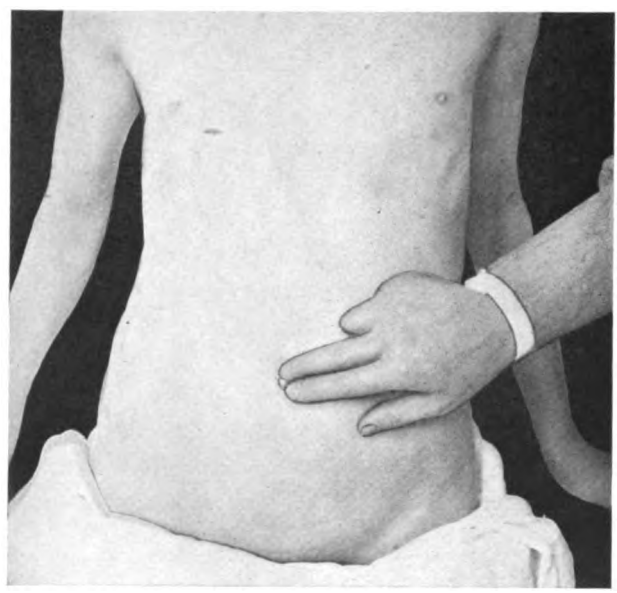

FIG. 157.—METHOD OF DETERMINING THE PRESENCE OF AN UMBILICAL HERNIA.
Two fingers, preferably the index and middle finger, of the examiner's hand are placed over the umbilical region, and the patient is asked to cough, when the impulse can be distinctly felt if the hernia is present.

They may become less prominent when the patient sits up and can be less easily felt than when they lie down. They do not change their position when the patient is turned toward either side, as intraabdominal tumors do.

Differential Diagnosis of Desmoids.—They must be differentiated from an abscess or hematoma of the abdominal wall and from intra-abdominal tumors. A hematoma is gradually absorbed, and an abscess is more sensitive and is accompanied by fever and leukocytosis. In addition, the edges of an abscess are less sharp and there is usually a primary cause (see page 231) to be found.

From intraabdominal tumors and encapsulated exudates there is great difficulty at times in making a differential diagnosis, especially if they have become adherent to the anterior abdominal wall.

If such an adherent intraabdominal tumor be due to carcinoma or sarcoma, there is accompanying cachexia and the history of a rapid growth as compared to the slow growth of desmoids. Other forms of intraabdominal tumors show the characteristics described on page 234.

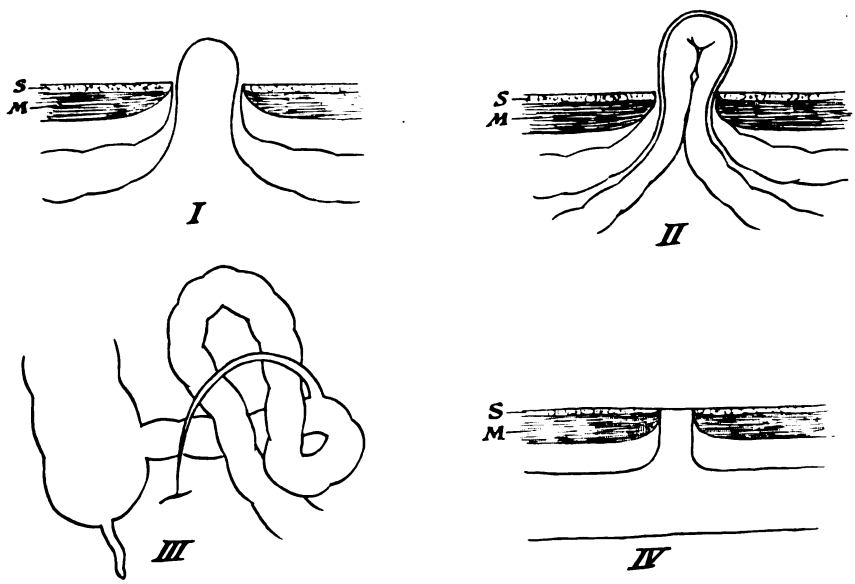

FIG. 158.—MOST FREQUENT CONDITIONS OCCURRING IN CONNECTION WITH MECKEL'S DIVERTICULUM (Miles F. Porter).

S, Skin; *M*, abdominal wall. I. Posterior wall of Meckel's diverticulum prolapsed through umbilicus. II. Hernia of Meckel's diverticulum. A coil of intestine is seen pushing the posterior wall of the diverticulum outward. III. Intestinal obstruction due to Meckel's diverticulum. The latter is seen attached to some point in the abdominal cavity causing strangulation of a coil of intestine which had slipped beneath its point of origin and attachment. IV. Fistula at umbilicus due to patent Meckel's diverticulum.

CONGENITAL CONDITIONS.

These occur most often in connection with Meckel's diverticulum and the urachus. In the former, a number of conditions are found, as follows (Fig. 158):

(*a*) The diverticulum may be patent at the umbilicus with protrusion of the posterior wall of the gut. This may be diagnosed from the presence of a soft reddish tumor covered externally with mucous membrane.

(*b*) There may be simply a fistulous opening, with reddish edges, from which a few drops of mucus having a fecal odor are discharged and through which a fine probe can be passed into the intestine.

(*c*) A hernia of the gut may occur as a complication of the posterior wall protrusion.

(*d*) The diverticulum may be large and patulous at the umbilicus. Such a form can be readily recognized.

(*e*) The diverticulum may rarely be converted into a cyst.

Malformations in connection with the urachus are much simpler. Here a fistula is most often present from which both pus and urine are discharged. Cysts of the urachus occur in the median line between the umbilicus and symphysis, and can be suspected to be of this origin chiefly from the characteristic median location. The connection of a fistula with the bladder may be demonstrated by injecting milk or methylene-blue into it and then catheterizing the patient.

ABSCESSES DISCHARGING THROUGH THE UMBILICUS.

Pus escaping from the navel may have its origin in a number of different sources. It may be the result of a prevesical or retromuscular suppuration dependent on the various primary sources of such infection (see page 231). In addition to the causes in the abdominal wall itself, one must think of intraabdominal causes. In children it is a frequent point of spontaneous discharge of a tubercular peritonitis. Suppurating echinococcus cysts and abscesses resulting from perforations of the various hollow viscera, all are apt to discharge through the navel.

TUMORS OF THE UMBILICUS.

These may be primary and secondary. At times the discovery of the secondary growth at the navel may be the first sign of an intraabdominal malignant disease.

The primary tumors belong to both the benign and malignant forms. Of the former, the most frequent are dermoids and sebaceous cysts, which can be recognized by their soft doughy consistency and slow growth.

The primary malignant tumors are almost always carcinomata and grow rapidly, appearing either in the form of a cauliflower-like growth with firm edges or as an ulcerating surface with typical indurated edges and base. There is also accompanying indurative enlargement of the inguinal lymph-nodes.

The secondary tumors simply cause a hard tumor protruding at the umbilicus, and appear rather as the result of a direct continuation of a widespread peritoneal dissemination than as a metastasis. They are due in two-thirds of the cases to malignant disease of the alimentary

tract or liver, in the remaining one-third to that of the ovaries and uterus.

INJURIES OF THE ABDOMINAL WALLS AND VISCERA.

Our views in regard to the indications for operation have changed so rapidly during the past fifteen years that it has greatly influenced the question of diagnosis. Up to that time an exploratory laparotomy was only indicated in every suspected injury of the abdominal viscera if symptoms of peritonitis had appeared.

At present more progressive surgeons believe that visceral injuries resulting from stab or gunshot wounds, as well as severe crushing injuries, should be diagnosed early enough to be of aid in saving the patient's life, *i. e.*, within the first six to twelve hours.

When such a patient is examined for the purpose of making a diagnosis, a certain more or less fixed routine method should be followed in order to ascertain, as soon after the accident as possible, whether a viscus has been injured. Often such a decision can only be reached if the patient is examined a second or third time in a similar manner one to two hours later.

The routine method is as follows:

1. Ascertain as accurately as possible the exact manner in which the accident occurred.
2. General condition of the patient.
3. Results of local examination.
4. Symptoms of injury of particular viscera.

Before discussing these in detail, it may be stated that injuries in which there is no external wound are just as likely to produce serious visceral lesions, as those in which there is a cutaneous wound. In civil life the former class is far more frequent than the latter, and with the possible exception of those cases in which there is actual prolapse of viscera following the action of some penetrating force, the diagnostic points of both penetrating and non-penetrating wounds are the same, so that they will be discussed together.

1. **History and Mode of Accident.**—In stab wounds it will be of confirmatory value to know the length of blade, the relative positions of victim and assailant, and the direction in which the instrument was thrust in if possible.

In gunshot or shell wounds the size of the bullet or missile is of value. It has been found that small bullets traveling with great velocity do far less damage than larger and more explosive ones. Too much

weight should, however, not be placed upon this difference, since wounds of the hollow viscera may cause as serious results after small as after large perforations.

In the case of subcutaneous injury we can divide them into those in which there is perhaps only slight abrasion or contusion externally, and the graver cases in which there is a hernial protrusion. The modes of injury are, as in the skull, chiefly of three varieties:

(*a*) A circumscribed force or one which has come into contact with the abdomen over a limited area only. As examples of this class may be mentioned kicks, or a fall upon some object, or a blow from a tool like a hammer, etc., thrown at the lower portion of the patient's thorax or over the abdomen proper.

(*b*) A diffuse force or one in which one segment or the entire abdomen has been compressed between two opposing forces. Such action follows accidents like being caught between buffers or in the wreck of a building.

(*c*) An indirect mode of injury such as follows a fall upon the feet or the falling of a weight upon the back.

2. **General Condition of the Patient.**—There are four classes of cases:

(*a*) Those with marked primary shock symptoms from which the patient never recovers, death ensuing in a short time after the injury.

(*b*) Those with marked primary shock symptoms passing imperceptibly into those of internal hemorrhage, either terminating fatally within a few minutes to hours, or the signs of internal hemorrhage continue so that a diagnosis of the injury of a viscus with escape of blood can be made.

(*c*) Cases with practically no general symptoms and in which the suspicion of an abdominal injury only arises from the history of the mode of injury or the gradual appearance of local signs indicating hemorrhage or beginning peritonitis. There are also cases in which the symptoms appear on the second day, or even as late as the tenth day, from dislodgment of a clot.

(*d*) Cases in which there is apparently considerable primary shock which clears up without any local injury being discovered. This last class is the most puzzling from a diagnostic point of view.

Under shock symptoms may be included pallor of the skin and visible mucous membranes; rapid, weak pulse and respiration; cold, clammy sweat; stupor or unconsciousness; lowering of blood-pressure; dilated pupils; and vomiting immediately after the accident.

In making an examination of the general condition of the patient

one should note whether the above symptoms of shock are present or absent. In case they are present and persist for more than a few hours, one must look for local signs of injury. If the patient does not react, one must look for some cause in the abdomen.

Extreme pallor, a weak, rapid pulse with but little tension, thirst, restlessness, shallow respirations, and a decrease in blood-pressure, as determined by the Riva Rocci instrument, indicate internal hemorrhage. If such is the case, it may be impossible to distinguish it from shock except by the absence of unconsciousness, of cold, clammy skin and dilated pupils in hemorrhage (see page 697). There are cases in which the symptoms of both shock and internal hemorrhage appear immediately after the accident, so that it is impossible to distinguish between them until some hours have passed and the hemorrhage symptoms predominate. If the condition is due to hemorrhage the patient becomes paler, more apathetic and somnolent, the pulse gets smaller and more rapid and the respiration shallower, even when there is no peritonitis present. The writer has, on the other hand, seen a number of cases of severe intraperitoneal hemorrhage in which the pallor was not a noticeable feature, the primary anemia having been partially recovered from. These exceptions are particularly mentioned to emphasize the fact, first, that in some cases it is almost impossible to make a diagnosis before operation; and, secondarily, that too much reliance should not be placed on any one symptom.

3. **Local Signs of Injury.**—(*a*) Examination of the skin and abdominal wall. In the case of penetrating wounds the situation of the wound of entrance and of exit, if the latter exists, is of some value in determining which structure has been injured.

In former times great stress was laid upon the fact that many gunshot or stab wounds did not penetrate into the abdominal cavity. At present the opinion of the majority of surgeons is that no time should be wasted in speculating whether or not a missile or knife has penetrated, but exploratory laparotomy should be performed. Under no conditions should a wound be probed or enlarged, however, until the proper aseptic technic and surroundings have been secured in order to make a diagnosis by direct inspection.

In injuries of the abdominal wall or viscera with but slight or no external signs one should note the presence of an accompanying fracture of the lower ribs or of cutaneous hematomata. In the same manner the presence of a palpable gap in the abdominal muscles, with or without the appearance of a swelling having all the characteristics of a hernia (see page 401), is of value.

The most important local signs, aside from those to be seen or felt externally in the early hours (six to twelve hours) after either a penetrating or non-penetrating injury, are:

(*a*) *Muscular rigidity.*

(*b*) *Localized or diffuse pain and tenderness on pressure.*

(*c*) *Dullness in the flanks or above the pubes.*

The muscular rigidity is due to a reflex contraction of the abdominal muscles, called the "defence musculaire" by French surgeons. It is one of the most characteristic symptoms and is quite marked at an early stage over the injured viscus. The same is true for the pain and tenderness on light pressure which usually accompany the rigidity. These symptoms are indicative either (*a*) of peritoneal irritation due to the presence of blood, or (*b*) of peritonitis, due to the escape of bowel or bladder contents. This rigidity and tenderness extend over the entire abdomen. The steady increase in the pulse-rate and in the degree of tympanites, and the onset of vomiting, etc., soon show the presence of a complicating peritonitis. If pain is due to injury to the abdominal wall alone, muscular rigidity is never as marked.

In the early hours after an injury, especially in those cases in which there are practically no signs of shock or internal hemorrhage, one can detect dullness in the flanks or above the pubes. Such dullness, if it changes to tympany when the patient is turned upon the opposite side, means free blood or urine in the peritoneal cavity. If the dullness is only above the pubes and does not vary with change of position it is due to an extraperitoneal rupture of the bladder (see page 243). Unfortunately free fluid can seldom be demonstrated at an early stage owing to the muscular rigidity. At a later stage its presence is obscured by the tympanites. The author has found it most often above the pubes in intraperitoneal hemorrhage.

4. **Symptoms of Injury of Particular Viscera.**—A convenient division of the symptoms of injury of the individual viscera for the purpose of diagnosis is:

(*a*) Those cases in which symptoms of injury of the alimentary canal predominate.

(*b*) Those in which symptoms of injury of the urinary organs predominate.

(*c*) Those in which signs of internal hemorrhage predominate.

Symptoms of Injury of the Alimentary Canal.—*Vomiting.*—Nausea or vomiting continuing for some hours after the receipt of an injury are very characteristic signs of the presence of an injury to the stomach or small intestine. If the vomitus contains blood, it indicates an

injury to the stomach. If the vomiting is bilious in character, a wound of the small intestine should be suspected.

Obliteration of the Liver Dullness.—This sign, if present in the form of tympany replacing a normal hepatic dullness, is of great value. Unfortunately, however, it is rarely present, so that but little weight can be placed upon its absence.

Presence of Evidence of Free Fluid in the Peritoneal Cavity.—As was stated above, the presence of free fluid in sufficient quantities to permit of its detection by percussion is so rare in the early hours of a stomach or intestinal injury as to be of little value. If, however, a changing line of dullness in the flanks and above the pubes can be found, it is indicative of such visceral perforation. One must, however, exclude the possibility of intestinal coils full of fluid feces or the possibility of free hemorrhage giving rise to the same signs.

The most typical symptoms at an early stage of gastric or intestinal perforation are the gradual rise in the pulse-rate and the presence of an increasing leukocytosis. If an increase in the pulse-rate is not due to primary shock or hemorrhage, such an increase is strongly indicative of a beginning peritonitis.

Tympanites.—If in a patient who has sustained an injury of the abdomen in any of the modes above described there is a gradual increase in the distention of the abdomen and other symptoms, such as inability to pass flatus, there can no longer be any question as to the existence of a perforation. As was stated above, in the majority of cases a diagnosis made when tympanites is marked is of comparatively little value from an operative standpoint, since septic paresis of the intestines is already well advanced.

The passage of blood in larger or smaller quantities with the bowel movement is also a positive sign of intestinal injury. If black and tarry in character, it indicates hemorrhage high up toward the stomach or the duodenum. If fresher in color it indicates hemorrhage lower down.

The pain, tenderness, and rigidity of the abdominal wall are often quite localized in gastric or intestinal injury. This is especially true of those cases of appendicitis which apparently seem to follow directly upon the reception of an injury.

Symptoms of Injury of the Urinary Organs.—This includes injuries of the kidneys and ureter.

Injury of the Kidney.—If the wound in the kidney communicates freely with the general peritoneal cavity, it produces the same symptoms of internal hemorrhage as those in which there is perforation of solid

viscera like the liver and spleen, and will be referred to below. Injury of the kidney in which there is no such communication causes pain, and not infrequently, swelling over the lumbar region. The pain is apt to radiate along the ureter into the testis or thigh upon the side of the injury. There is also tenderness over the kidney and considerable rigidity of the lumbar muscles. The most characteristic symptom, however, of injury to the kidney is the presence of hematuria. In bleeding from the kidney the blood is intimately mixed with the urine and accompanied by worm-like clots which are casts of the ureter, whose passage down along the ureter cause the colicky pains just spoken of. The hematuria is, as a rule, most marked just after the reception of an injury, gradually diminishing in quantity. Even the

FIG. 159.—EXTENSIVE DESTRUCTION OF KIDNEY.
The organ is completely lacerated. It occurred in a case of subcutaneous injury of the abdominal wall without external sign. (See text.)

symptom of hematuria may at times be absent, and yet extensive lacerations of the kidney have occurred, as in the case recently observed by the author in which there was pulpification of the kidney without any blood in the urine, as a result of a crushing injury. The ureter was blocked by a large clot so that no hematuria occurred. Fortunately such cases are very rare.

In order to state positively that hematuria is from the kidney the bladder should be washed out and some of the irrigating solution left in the bladder. This rapidly becomes tinged with blood as the latter escapes from the ureter and passes through the catheter which has been left in place. In some cases the above symptoms of injury to the kidney may be accompanied by evidences of displacement of the kidney, as determined by palpation of the abdomen (see Fig. 160).

It is impossible to diagnose an injury of the ureter until a tumor forms along the course of the ureter and is accompanied by diminished secretion of urine and hematuria.

Injuries of the bladder may be intraperitoneal or extraperitoneal. In extraperitoneal tears there are evidences of dullness above the pubis, the area of dullness not changing with change of the position of the patient; or there is bulging toward the rectum at the base of the bladder, to be felt per rectum.

Intraperitoneal ruptures of the bladder cannot be differentiated

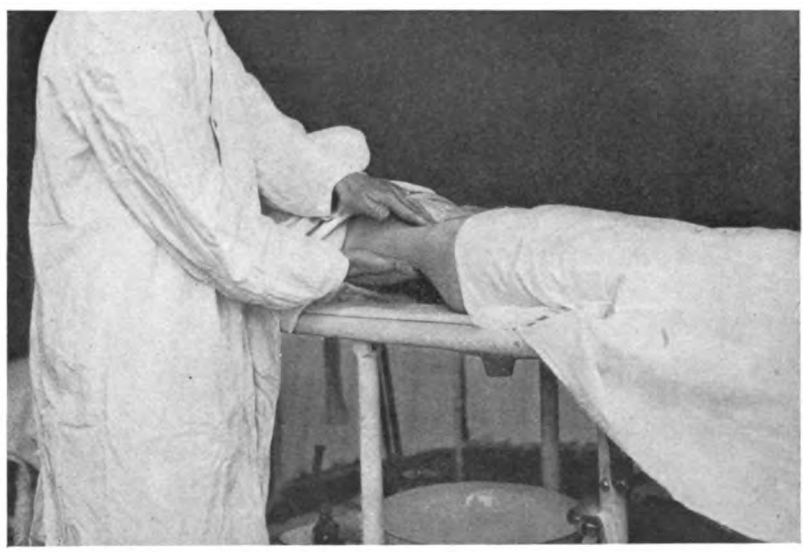

FIG. 160.—METHOD OF EXAMINATION TO DETERMINE ABNORMAL MOBILITY OR ENLARGEMENTS OF THE KIDNEY.

This method is also used in the determination of the presence or absence of an enlargement of the kidney. The right hand of the examiner, when examining the right kidney, is placed behind the patient in a space between the last rib and the crest of the ilium, so that the parts lying behind the kidney can be raised up to meet the opposite hand, which is pressed down upon it. When examining for a floating kidney the lower pole of the kidney can be felt to slip across the hand lying on the anterior surface of the abdomen.

as such except when symptoms of peritonitis appear. A diagnosis at this time, as was stated before, is of comparatively little value from an operative standpoint. In both extraperitoneal and intraperitoneal ruptures of the bladder the catheter can be easily passed into the bladder. The urine is slightly blood-tinged, much less than in injuries of the kidney, and the quantity of urine obtained is very small or there may be none at all.

The injection test for perforation or rupture of the bladder is but little to be relied upon. This test consists in inserting into the bladder

a definite quantity, usually from four to six ounces, of sterile water. If the bladder is perforated, the greater portion or all of this leaks out into the peritoneal cavity or into the extraperitoneal tissue, and a smaller quantity than was put in returns through the catheter. This test is unreliable because the tear or perforation may be valve-like in character, allowing but a small quantity to escape, or the urethra may be torn at the neck of the bladder.

The most reliable signs of injury of the bladder at an early stage are (*a*) the history of and the location of the injury; (*b*) the presence of practically no urine in the bladder when catheterized, and this bloody and in small quantity; (*c*) the pain over the bladder; (*d*) the constant desire but inability to urinate.

When peritonitis has set in, it is impossible to state in any case whether this has been due to perforation of the bladder or of some portion of the alimentary canal. Fractures of the pelvis are often accompanied by injuries of the bladder and urethra (see page 490).

Cases in which Symptoms of Internal Hemorrhage Predominate.—These will be found more or less characteristic of ruptures of the liver or spleen or of the intraperitoneal ruptures of the kidney. Pain, localized tenderness, and rigidity situated over the splenic region, accompanied by evidences of hemorrhage into the peritoneal cavity, are indicative of injury of the spleen. The same symptoms located over the region of the liver, especially if the pains radiate to the shoulders, are typical of injuries of the liver.

In injuries of the liver and spleen, and in those of the kidney in which the blood escapes into the general peritoneal cavity, the diagnosis may be made from these local signs, such as tenderness, rigidity, etc., added to the presence of evidences of a shifting line of dullness in the flanks, *i. e.*, of free fluid in the peritoneal cavity. Icterus, when present, is of great value as indicating an injury of the liver. The presence of free blood in the peritoneal cavity, whether due to an injury of the omentum or of the mesentery, of the deep epigastric artery, or of the liver, spleen, or kidney, causes early symptoms of so-called peritonism or peritoneal irritation. These are similar to those of a beginning peritonitis, but are less rapid in their onset. They consist of gradually increasing pulse-rate, tympanites, and leukocytosis. These, however, gradually subside if the blood remains aseptic and is absorbed.

Injuries of the pancreas cause shock, vomiting, and localized pain over the epigastrium, and often distention of the upper abdomen. Fractures of the ribs accompany the subcutaneous injuries of the liver and spleen in many cases.

ACUTE ABDOMINAL AFFECTIONS.

When called to the bedside of a patient suffering from an acute abdominal condition, every effort should be made to make a diagnosis at as early a period as possible.

This diagnosis should not only include the viscus involved, but the character of the pathologic process.

In the examination of such a case it is well to have a more or less routine method of examination, in order that no organ may be overlooked.

There is no one group of symptoms common to all acute abdominal

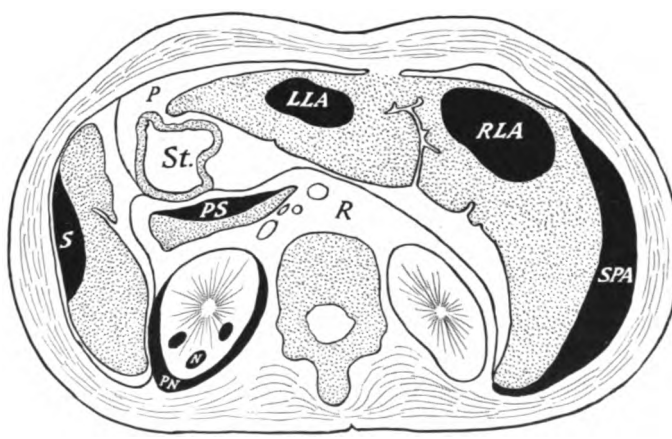

FIG. 161.—LOCATIONS OF VARIOUS FOCI OF SUPPURATION IN ABDOMINAL CAVITY.

SPA, Subphrenic abscess pushing liver away from abdominal wall; *RLA*, abscess of right lobe of liver *LLA*, abscess of left lobe of liver; *PS*, peri-pancreatic suppuration; *N*, location of abscesses within kidney (pyelonephritis); *PN*, location of perinephritic suppuration; *P*, peritoneal cavity; *St*, lumen of stomach; *S*, abscess of spleen; *R*, retroperitoneal tissue.

conditions. On the other hand, symptoms so group themselves that it will be found of aid to divide the cases into four classes. The lines between these are not sharply drawn because occasionally cases apparently belonging to one group will be found to belong more properly to one of the others. For practical purposes, however, such a classification will be found useful clinically, and is as follows:

1. Those in which inflammatory symptoms appear early and predominate.

2. Those in which pain of varying intensity is the prominent symptom. It may be followed by signs of localized or diffuse peritonitis or by the symptoms of intestinal obstruction.

3. Those cases in which the symptoms of intestinal obstruction are the most prominent from the onset.

4. Those in which either shock or hemorrhage or both are marked, and are followed by signs of peritonism (signs of bowel paralysis of milder degree than in obstruction).

The various acute conditions which can thus be classified are:

GROUP I.	GROUP II.	GROUP III.	GROUP IV.
EARLY SYMPTOMS OF SUPPURATION.	PAIN A PROMINENT EARLY SYMPTOM FOLLOWED OR NOT BY SIGNS OF PERITONITIS OR INTESTINAL OBSTRUCTION.	EARLY SIGNS OF INTESTINAL OBSTRUCTION.	EARLY SIGNS OF INTERNAL HEMORRHAGE.
1. Acute cholecystitis.	1. Appendicitis.	All forms of intestinal obstruction.	1. Extrauterine hemorrhage.
2. Hepatic infections. (*a*) Single or tropical abscess. (*b*) Suppurative pylephlebitis. (*c*) Catarrhal and suppurative cholangitis.	2. Gallstones or biliary colic.	(*a*) Strangulation by bands, by adhesions through apertures, or by Meckel's diverticulum.	2. Rupture of aneurysms.
3. Primary forms of peritonitis. (*a*) Acute tubercular. (*b*) Pneumococcus. (*c*) Gonorrheal.	3. Perforation of hollow viscera. (*a*) Gastric ulcer. (*b*) Duodenal ulcer. (*c*) Typhoid ulcer.	(*b*) Volvulus. (*c*) Intussusception. (*d*) By tumors or foreign bodies. (*e*) Adynamic ileus.	
4. Renal infections. (*a*) Pyonephrosis. (*b*) Pyelonephritis. (*c*) Perinephritis. (*d*) Metastatic abscess.	4. Acute pancreatitis. 5. Renal colic. 6. Kinking of ureter in floating kidney (Dietl's crises). 7. Embolism or thrombosis of the mesenteric vessels.		
5. Subphrenic abscess.	8. Torsion of pedicles of ovarian or uterine tumors.		
6. Suppurating echinococcus cysts of the liver.	9. Torsion of spermatic cord.		
7. Pericolitis sinistra.	10. Visceral crises in tabes or in erythema group.		
8. Multiple abscesses of omentum.	11. Angina sclerotica abdominis.		
	12. Referred pain from thoracic or spinal affections.		
	13. Inflammation of intraabdominal portion of vas deferens.		

GROUP I.—EARLY SYMPTOMS OF SUPPURATION.

1. ACUTE CHOLECYSTITIS.

In acute cholecystitis, occurring without gallstones, there is pain referred to the gallbladder region, tenderness and muscular rigidity over the same area, fever, leukocytosis, and an increased pulse-rate. In

addition, an area of dullness can be outlined by percussion and a tumor felt at times by palpation just below the right costal arch.

If the liver is located at a lower level in the abdominal cavity, as the result of a hepatoptosis, or if there is a long Riedel's lobe which has carried the gallbladder with it (Fig. 162), all of the above signs are found at the level of the umbilicus or even below it. If pus has formed in the gallbladder (empyema) the fever is higher and continuous in type, and the leukocytosis quite marked. In cholecystitis complicating typhoid the symptoms are often overshadowed by those of the typhoid itself. Such cases show a distinct Widal reaction.

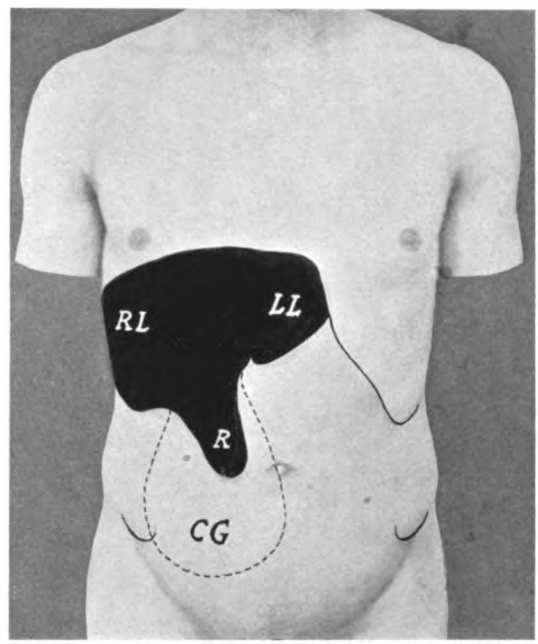

FIG. 162.—RIEDEL'S LOBE OF LIVER AND AREA OF DULLNESS OR TUMOR DUE TO CYSTIC ENLARGEMENT OF THE GALLBLADDER.
RL, Right lobe of liver; *LL*, left lobe of liver; *R*, Riedel's lobe; *CG*, cystically dilated gallbladder.

Differential Diagnosis. — 1. *Appendicitis.*—In appendicitis the tenderness and rigidity are lower down, fever and leukocytosis are not so marked at an early stage, and there is more apt to be severe colicky pain.

If, however, the gallbladder is located lower than normal the differentiation between a cholecystitis and an appendicitis may be very difficult.

2. *Biliary Colic.*—In gallstone colic the same local signs appear as in cholecystitis, but there is less fever, less leukocytosis, and less constitutional disturbance, and the pains are far more severe and radiate to the right shoulder, less often than to the left.

Phlegmonous Cholecystitis.—This grave form of cholecystitis can be recognized by the greater severity of the initial symptoms. The pain in the right hypochondrium is more severe and sudden in its onset than in gallstone colic, and there is far more general disturbance. These latter septic symptoms are rapid, feeble pulse, cold sweats, sub-

normal temperature, collapse, faintness, great prostration, and the early appearance of the signs of a general peritonitis.

2. HEPATIC INFECTIONS.

SINGLE OR TROPICAL ABSCESS.

The occurrence of irregular fever accompanied by chills, sweats, and pain over the liver and enlargement of that organ, in a patient who has previously suffered from dysentery, should lead one to suspect an abscess of the liver. A bulging below the right costal arch will confirm such a diagnosis.

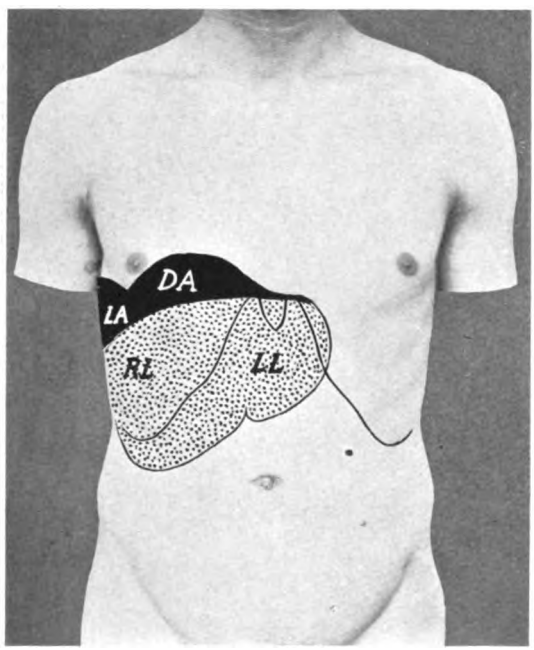

FIG. 163.—AREAS OF DULLNESS FREQUENTLY OBSERVED IN RIGHT-SIDED SUBPHRENIC ABSCESSES, AND IN ABSCESSES OF THE RIGHT LOBE OF THE LIVER.

RL, Right lobe of liver; *LL*, left lobe of liver; *LA*, abscess of lateral subphrenic space; *DA*, abscess of dome of diaphragm.

The pain in abscesses of the right lobe is referred to the right shoulder, and in those of the left side, to the corresponding scapular region.

The fever may be quite regularly intermittent, like a malarial, but is usually quite irregular.

The liver is enlarged in all directions and is tender to the touch. The tenderness may at times be quite localized over the abscess. Exploratory puncture is of great value in confirming the presence of pus. A negative result does not exclude an abscess, as the needle may become occluded or pass through the abscess.

Differential Diagnosis.—1. *Empyema.*—The liver is not enlarged in a downward direction. There are marked signs of compression of the lung if the empyema is a diffuse one and the upper border of dullness is either concave upward or horizontal, while in hepatic abscess it is convex (Fig. 163) and the septic symptoms are more marked. If

an empyema and hepatic abscess coexist a differentiation is impossible. The same is true for an encapsulated diaphragmatic empyema.

2. *Malaria.*—The absence of leukocytosis and the finding of plasmodia serve to distinguish this disease. It must not be forgotten that in some cases of malaria the organisms are not found until after quinin has been administered.

3. *Suppurative Pylephlebitis or Cholangitis.*

4. *Subphrenic Abscess.*—(See page 253.)

SUPPURATIVE PYLEPHLEBITIS.

This most frequently follows appendicitis, toward the end of the attack. It results in the formation of multiple abscesses in both lobes of the liver (Fig. 164). It may often follow what were interpreted clinically to have been mild cases of appendicitis.

FIG. 164.—MULTIPLE ABSCESSES OF LIVER.
Due to a septic pylephlebitis secondary to appendicitis.

If a septic or pyemic condition follows appendicitis either a pylephlebitis or a subphrenic abscess must be thought of. In pylephlebitis there are chills, irregular fever, sweats, jaundice, and a uniformly enlarged and very tender liver. The patients appear to be very septic and soon succumb to the pyemia.

Differential Diagnosis.—1. *From Tropical Abscess.*—The clinical picture is not that of such a severe sepsis as in pylephlebitis, the liver is not so uniformly tender, and there may be bulging at the costal arch.

2. *Suppurative or Catarrhal Cholangitis Complicating Gallstones in the Common Duct.*—There is continuous or intermittent jaundice, a history of colics, and the septic intoxication is never as marked as

in pylephlebitis. If multiple foci of suppuration occur in a cholangitis, it can only be differentiated from a pylephlebitis by the history of an appendicitis in the latter.

3. *Typhoid Fever.*—The fever is almost always continuous, the pulse is slower, chills and sweats are rare, and there is leukopenia. A positive Widal reaction and the typhoid bacilli obtained from a blood culture are characteristic of typhoid.

4. *Malaria.*—The finding of plasmodia, the presence of leukopenia, and the more regular type of intermittent temperature, as well as the lack of local hepatic symptoms, speak for malaria.

3. PRIMARY FORMS OF PERITONITIS.

Acute Tubercular Peritonitis.—This may begin in an acute manner with fever to 103° to 104°, abdominal tenderness, and the symptoms of ordinary acute peritonitis, such as tympanites, etc. In these cases the absence of a cause for the peritonitis and the examination of the lungs and other parts of the body for evidence of tuberculosis will be of aid in making a diagnosis.

Acute Gonorrheal Peritonitis.—This is usually well localized in the pelvis, but may become general. In the former case the inflammatory signs, such as severe pain, tenderness, muscular rigidity, and tympanites, are local. In the general form there is a very acute onset, in which abdominal distention, tenderness, and rigidity are quite diffuse and are accompanied by elevation of temperature and a rapid pulse. The diagnosis may be made from the previous history of leukorrhea or of post-marital infection, or of a preceding pyosalpinx followed by the acute local or general peritonitic symptoms. The fact that the condition spontaneously improves in a few days, instead of being progressive as in ordinary diffuse forms of peritonitis, is also very important.

Pneumococcus Peritonitis.—This occurs almost exclusively in young children of both sexes. It may accompany or follow thoracic conditions, such as pericarditis or empyema, or occur independently.

The diagnosis may be made from the age and the sudden onset of peritonitic symptoms, such as fever, abdominal distention, vomiting, and tenderness, followed in a few days by diarrhea and later by the formation of a tense cystic mass in the hypogastrium accompanied by fever and signs of exhaustion.

4. RENAL INFECTION.

Renal suppuration is usually chronic in its course, but it may appear in such an acute form as to necessitate its consideration here.

The principal varieties of acute renal disease of the suppurative type are:

1. Pyelonephritis.
2. Perinephritis.
3. Metastatic abscesses.
4. Pyonephrosis.

PYELONEPHRITIS.

This may follow suppuration in the lower urinary tract, such as the bladder or urethra, or it may be hematogenous in origin, *i. e.*, conveyed through the blood from distant foci of suppuration. In some cases it manifests itself by a rigor or succession of chills, followed by fever and sweats. There is scarcely any tenderness or pain over the kidney in some cases; in others there are typical colicky pains following along the ureter to the bladder and radiating to the testis and thighs.

The diagnosis in the first class of cases, where there are no local renal signs and the urine is negative, is very difficult and can only be made from the existence of a cystitis or other cause of infection, and the absence of signs of a pyemia or of a malignant endocarditis. In the more localized form the enlarged tender kidney and the ureteral pains, associated with purulent acid urine, are characteristic. In some of these cases the chills and irregular fever are followed by a more continuous type of fever, resembling typhoid, with stupor and delirium, a condition known as *urosepsis*.

Differential Diagnosis.—*Pyemia.*—In this septic condition there are signs of secondary foci in the lungs, spleen, and joints, which are absent in suppurative pyelonephritis, and in pyemia a primary focus is usually to be found.

Septicemia.—In the acute forms septicemia runs a more rapid course, the pulse and respirations are higher, and there is greater prostration.

PERINEPHRITIS.

In this affection there is pain in the lumbar region, at times radiating into the thigh or testes. The pain is usually quite severe, and the corresponding renal region is very tender, rigid, and often edematous. These local signs are accompanied by evidences of deep-seated suppuration, such as chills, fever, furred tongue, vomiting, stupor,

and even delirium. There is often a peculiar lameness; the patient walks with the body bent forward and inclined to the affected side, the thigh being held flexed.

The urine may be normal if the disease be of extraneous origin, or it may contain blood if it follow an injury, or, finally, in a few cases there is pus in the acid urine.

Differential Diagnosis.—1. *Lumbago* is but rarely accompanied by fever or leukocytosis. The pain is most often bilateral and does not radiate to the testis or thigh.

2. *Spondylitis.*—The pain extends around the body; it is relieved by suspending the patient. The tenderness is over the spine itself, which is held in a rigid manner, best seen when the patient is asked to bend forward. There is also but little fever or leukocytosis and the symptoms are more gradual in their onset.

3. *Hip-joint Disease.*—The pain and tenderness are lower down, often referred to the knee. There is limitation of motion at the hip, and when the limb is straightened there is marked lordosis of the lumbar spine. The *x*-ray often shows a pathologic head of the femur.

4. *Appendicitis.*—In those cases in which the appendix is directed down or inward (Fig. 168) the pain is in the right iliac fossa and followed by nausea and vomiting. In perinephritis the pain and swelling are higher up in the iliocostal space. In inflammation in an appendix which lies behind the cecum and ascending colon with its tip directed upward, the rigidity of the abdominal wall, tenderness, and pain may greatly resemble those of a right-sided perinephritis. In appendicitis, however, the pain is usually followed by nausea and vomiting. The rigidity and swelling, etc., of a perinephritis usually extend further back in the iliocostal space.

METASTATIC SUPPURATION OF THE KIDNEY.

If this occurs as a manifestation of pyemia it cannot be recognized except from the localized pain and the sudden pyuria. If, however, as not rarely occurs, abscesses form in one or both kidneys, as the result of a purulent focus elsewhere which has not caused pyemia, the severe pain over the affected kidney, the occurrence of repeated chills and fever, and the tenderness and enlargement of the affected kidney will permit a diagnosis to be made.

PYONEPHROSIS.

This affection is not apt to run an acute course. The enlarged kidney can usually be distinctly felt as greatly enlarged, there is no rigidity of the abdominal muscles, no edema of the skin, and there is

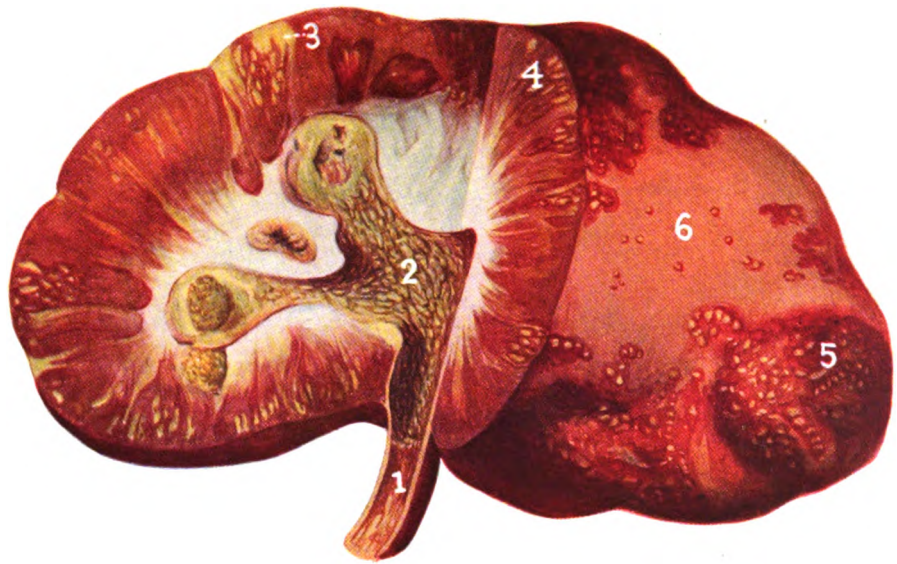

FIG. 165.—SEPTIC PYELONEPHRITIS.

1, Congested portion of ureter; 2, pelvis of kidney covered with pus and granulation tissue; 3, view of cortex in section, showing the streaky appearance given by the yellowish pus foci to the cortex and medulla; 4, similar areas in cortex; 5, view of convex or outer surface of kidney, showing the multiple suppurative foci which occur in groups, with reddish periphery and raised above the level of the surrounding normal cortical tissue; 6, this number is placed in the center of a few isolated miliary abscesses, the yellowish color of which stands out in contrast to that of the lighter shade of the normal cortex.

a history of long duration of the symptoms. In some cases there is a previous history of an obstinate lumbago which was never properly diagnosed as of renal origin. In other cases there is a history of attacks of renal colic.

5. SUBPHRENIC ABSCESS.

(See Figs. 163 and 165.)

This condition most frequently follows appendicitis if situated in the right subphrenic space, and perforations of the stomach or duodenum if located in the left subphrenic space. It may, however, occasionally occur in the latter locality after an acute appendicitis or a diffuse septic peritonitis. The attack of appendicitis need not have been complicated by pus formation and the subphrenic abscess may follow days to months after the attack.

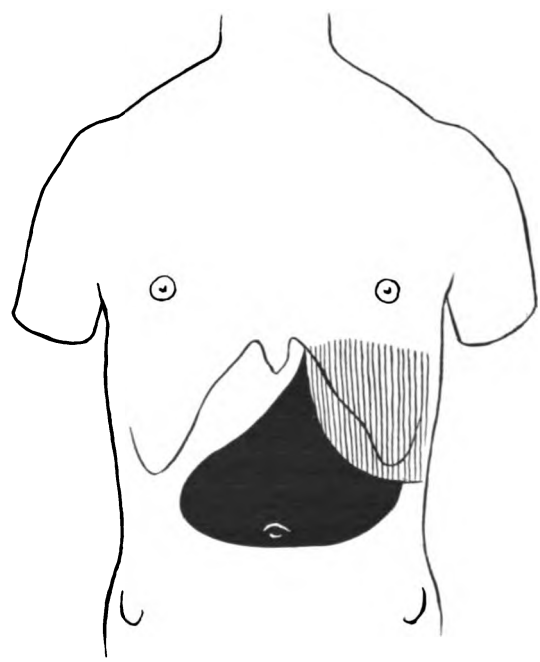

FIG. 166.—AREA OF DULLNESS IN LEFT-SIDED SUBPHRENIC ABSCESS. The dark area shows absolute dullness, the area indicated by vertical lines corresponds to the zone of tympany (A. Martin).

The history of a sudden recurrence of fever and of other signs of suppuration, such as leukocytosis, etc., toward the end of or shortly after an attack of appendicitis associated with pain in the right or left hepatic region, should lead to a search for a subphrenic abscess. In the case of the left-sided abscesses following gastric or duodenal ulcer there is a previous history of pain in the epigastrium and of vomiting of blood, or of copious tarry stools followed by the symptoms of infection.

The diagnosis must be based on the physical signs and the general evidence of deep-seated infection, such as fever, rapid pulse, leukocytosis, etc.

In right-sided subphrenic abscesses the liver is usually pushed downward. Over the abscess there is a continuation upward of liver dullness for a variable distance with a corresponding suppression of pulmonary sounds. A subphrenic abscess may cause a horizontal line of dullness or one that is convex upward. The area of dullness may be more marked at some one point, thus resembling an encapsulated empyema. If gas is present in the abscess, dullness is replaced by tympany and there are succussion sounds, as in pyopneumothorax.

The pain may be strictly localized over the right or left hypochondriac regions or may be diffuse, and not infrequently there is tenderness and rigidity, rarely edema of the overlying tissues.

Differential Diagnosis.—*Empyema.*—This is at times very difficult. Rapid respiration, cough, expectoration, and the history of a preceding pneumonia speak for empyema. The line of dullness in the diffuse form is said to be concave upward, but this may occur in subphrenic abscess as well. Between an encapsulated empyema close to the diaphragm and a subphrenic abscess, differentiation is impossible. The physical signs for both empyema and subphrenic abscess are so nearly alike that greater reliance should be placed on the etiology and character of the pus obtained by exploratory aspiration. The latter is apt to have the peculiar acid fetor of colon bacillus pus, while in empyema there is seldom any odor. Again, in subphrenic abscess the exploratory puncture reveals the presence of pus at a lower level than in empyema.

Abscess of the Liver.—Here the history of a preceding attack of dysentery and the less marked extension of the liver dullness upward are of value. In multiple abscesses of the liver following appendicitis there is greater evidence of sepsis and more general enlargement and tenderness of the liver.

6. SUPPURATING ECHINOCOCCUS CYSTS OF THE LIVER.

These may present the same symptoms and local findings as single or tropical abscesses. There is, however, no history of dysentery, and the occupation of the patient frequently is suggestive in that the disease is much more common in those brought in close contact with sheep and sheep-dogs. In the absence of a distinct tumor and the history or evidence of the presence of similar cysts elsewhere, a recognition of this condition is impossible. When the tumor is distinct, as is often the case, aspiration will frequently show hooklets.

7. PERICOLITIS SINISTRA.

This is a condition of acute infection due either to perforation of the appendices epiploicæ or of the haustra or sacculi of the descending colon and sigmoid flexure. There is sharp pain in the left iliac region, with rise of temperature and vomiting, the same sequence of symptoms so frequently seen in appendicitis. On palpation there is deep tenderness, rigidity of the abdominal wall, and the formation gradually of a tumor in the left iliac fossa accompanied by fever and leukocytosis.

If no localized intraperitoneal abscess forms, the pus, as in one case observed by the author, can escape into the general peritoneal cavity and cause a diffuse peritonitis.

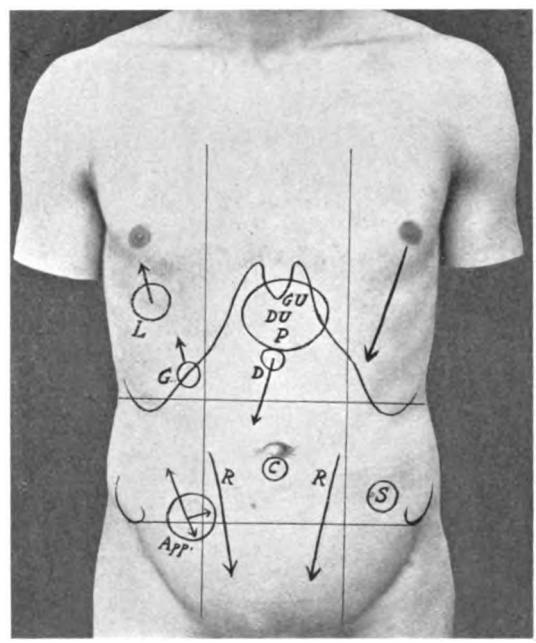

FIG. 167.—MOST FREQUENT DIRECTION OF RADIATION OF PAIN IN VARIOUS ACUTE ABDOMINAL AFFECTIONS.

L and *G*, Gallbladder and hepatic affections; *GU*, and *DU*, and *P*, location of pain in gastric and duodenal ulcers and pancreatic affections; *D*, occasional radiation of pain in duodenal ulcers to right iliac region; *C*, location of pain in ordinary intestinal colics, and in early stages of acute appendicitis; *App*, various radiations of pain in appendiceal inflammation; *R*, radiation of pain in ureteral and renal conditions, along the line of the ureter toward the bladder, testes, and thighs; *S*, location of pain in sigmoiditis, and affections of the descending colon. The arrow pointing downward and inward from the left nipple is to indicate the frequent reference of pain in thoracic affections, to the abdomen.

8. MULTIPLE ABSCESSES OF THE OMENTUM.

This condition may follow abdominal operations, especially those for radical cure of hernia. The clinical history, as observed in one such case by the author, was the following:

Severe pain in that side of the abdomen upon which the wound was situated, with rigidity and tenderness. The temperature varied between 101° and 104° F., there was considerable abdominal distention, some vomiting, and constipation.

A distinct tumor could be felt extending from Poupart's ligament

toward the umbilicus. The greatly thickened omentum in these cases contains a number of small abscesses.

The diagnosis depends upon the signs of localized peritonitis with formation of tumor, following an operation.

Group II.—Pain a Prominent Early Symptom.

In this group all of those acute conditions are included in which the chief symptom is pain. This is accompanied by other signs of involvement of the abdominal viscera. In many of the conditions the pain can be localized fairly well from the onset; in others, such as appendicitis, it is often diffuse at first, becoming more definite in the course of a few hours.

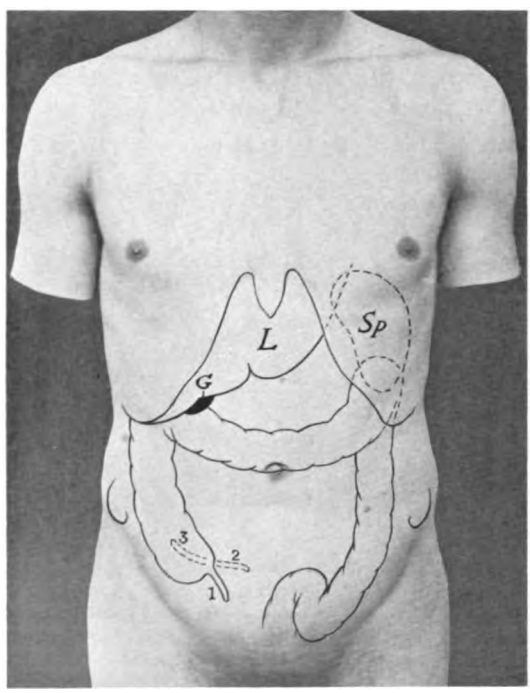

Fig. 168.—Normal Positions of Vermiform Appendix.

1, Pointing downward and inward toward the pelvis; 2, pointing inward and to the left; 3, pointing upward toward the liver, and lying either in front or behind the cecum. *G*, Normal location of gallbladder; *Sp*, spleen; *L*, liver; the letter itself is placed on the left lobe.

1. APPENDICITIS.

Diagnosis.—In every case of appendicitis the diagnosis may be made from an almost constant triad of symptoms:

1. Pain of a sudden, severe, often colicky nature.
2. Nausea and vomiting.
3. Localized tenderness and muscular rigidity.

1. *Pain.*—This is often general at first, but soon becomes localized, in the majority of cases, in the right iliac region. The only exceptions to this rule are:

(*a*) When the appendix is directed upward toward the liver, and especially when it lies behind the ascending colon (Fig. 168), the pain may be referred to the lumbar or right hypochondriac regions.

(*b*) When the appendix points inward or toward the pelvis, the pain is referred either to the umbilicus or to the left iliac region (Fig. 168), and is often accompanied by vesical and rectal symptoms.

2. *Vomiting.*—This accompanies the pain as a primary symptom or follows it after three or four hours.

If the nausea and vomiting persist or reappear at a later period, *they are danger-signals of a beginning peritonitis.*

3. *Tenderness and Muscular Rigidity.*—As a rule, these are most

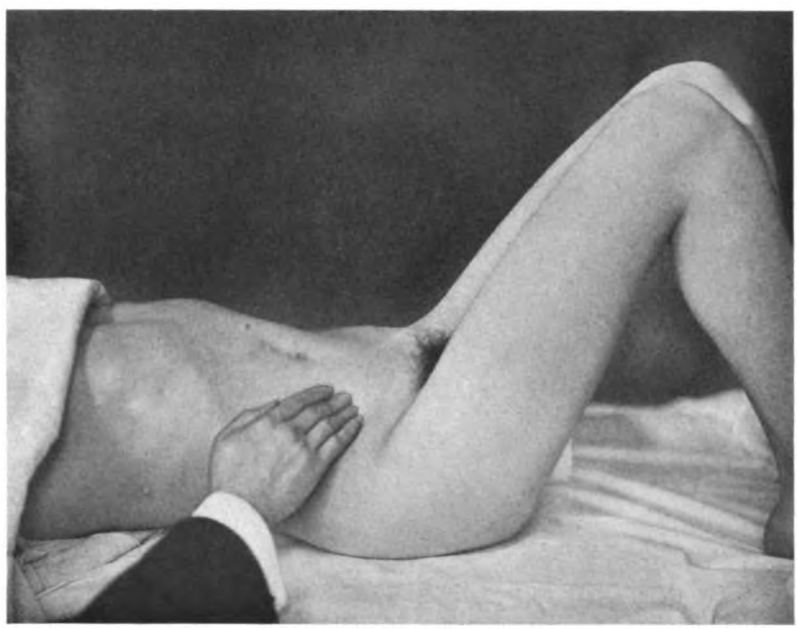

FIG. 169.—METHOD OF EXAMINATION OF THE APPENDIX REGION, WITH THE LIMBS FLEXED UPON THE ABDOMEN.

The limbs should be raised to such a height that the soles of the feet can rest easily on the bed or table. The patient's back should be somewhat elevated, and he or she should be instructed to relax the abdominal muscles by diverting his attention or asking them to open the mouth. Pressure is then made along the right border of the right rectus, with the entire palmar surface of all of the fingers of the right hand, and not with the tips of these fingers.

marked over the right iliac region and are best elicited when the shoulders are raised and the thighs flexed (Fig. 169). The tenderness is quite superficial and manifests itself when the slightest pressure is made. Deep tenderness can be found only with difficulty during the acute stage, owing to the muscular rigidity. The examination should never be forcible. A good plan is to have the patient palpate the abdomen gently with the index-finger and ask him to locate the most tender point. Often the most marked tenderness can be obtained by rectal or vaginal

examination. The rectal method is especially of value in children, where the appendix so often points toward the pelvis.

The muscular rigidity, being due to a reflex contraction, is a very valuable sign when it accompanies pain, vomiting, and tenderness. This symptom is best obtained by gradually and lightly sliding the hand over the suspected region.

If the appendix lies in either of the unusual positions referred to above, the tenderness and rigidity are correspondingly altered in location (Fig. 167).

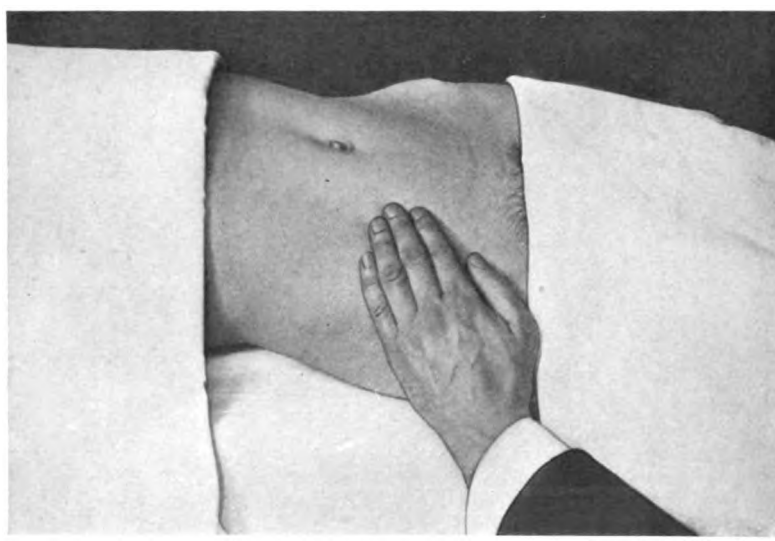

FIG. 170.—METHOD OF PALPATING THE APPENDIX WITH THE LIMBS OUTSTRETCHED.

The fingers are laid flat upon the abdominal wall, the examiner standing to the right of the patient. Either the right or left hand may be used. The appendix may usually be felt on the outer edge of the right rectus muscle, if enlarged, and if the abdominal walls are relaxed. Palpation should be carried out with as large a surface of the fingers as possible, and not by prodding the patient's abdomen with the finger-tips. This method is inferior to that shown in Fig. 169.

Pulse.—In the majority of cases there will be an increase in the pulse-rate with the onset of pain. The rate may be from 80 to 100 for a number of hours. *If it shows a gradual increase in frequency after the first twelve hours it is, as a rule, an ominous sign.* The steady rise of the pulse-rate to 110, later to 120 or higher, especially if it is jerky in character, is of great value in the diagnosis of a beginning peritonitis, especially if nausea continues, or vomiting is repeated and the area of rigidity and tenderness increase and are combined with abdominal distention. In children the pulse-rate is much higher than in adults and a rapid pulse is not always to be relied upon.

Fortunately for the purpose of diagnosis a slow pulse is but rarely met with. The author recalls a pulse of 66 and a temperature of 99.6° in a case of extensive spreading peritonitis following appendicitis. The muscular rigidity, tenderness, and tympanites were so characteristic that a diagnosis could be made from these symptoms alone.

Temperature.—A rise in temperature usually occurs within two to three hours after the beginning of an attack. In the milder catarrhal cases it is not higher than 100° or 101° F., but even this is inconstant. If fever persists and increases gradually during the first forty-eight to seventy-two hours, it generally means an encapsulated abscess. If the temperature drops suddenly, especially if accompanied by a rise of pulse-rate and increase of rigidity, it is significant of gangrene or a beginning peritonitis. Persistent temperature or fever occurring after apparent recovery, signifies some complication like pylephlebitis or subphrenic abscess. The most accurate temperatures are those taken per rectum.

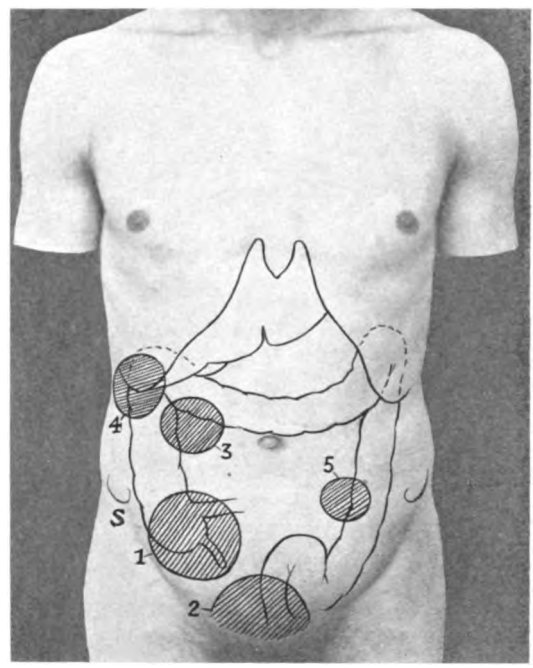

FIG. 171.—MOST FREQUENT LOCATIONS OF INTRAABDOMINAL ABSCESSES FOLLOWING APPENDICITIS.

For subphrenic abscesses, see Figs. 163 and 166. 1, Around cecum and appendix, close to brim of pelvis; 2, pelvic form; 3, around ascending colon and hepatic flexure; 4, retrocecal and colic forms; 5, left-sided forms. *S*, Anterior superior spine of ilium.

Leukocytosis.—Catarrhal appendicitis is accompanied by a mild degree of leukocytosis, rarely above 12,000. An increasing leukocytosis, from 15,000 upward, generally indicates a severe infection. If the count remains stationary, it is indicative of a walling off.

If the leukocyte count decreases gradually in a mild attack, it signifies improvement. If it decreases suddenly after a severe attack, it signifies gangrene, perforation with beginning peritonitis, or the

bursting of an abscess into the general peritoneal cavity. The majority of cases in which perforation or gangrene occurs early, and causes peritonitis, have a low leukocyte count, owing to the lack of resistance on the part of the organism and the overwhelming of the system by the toxins.

Tumor.—As an early sign this is of little value, owing to the fact that the muscular rigidity is so marked in many cases that deep palpation is both difficult and dangerous. In other cases the contracted edge of the rectus is apt to feel like an inflammatory mass. Again there are cases where the omentum wraps itself around the appendix and forms a palpable tumor. When the acute symptoms have subsided, a tumor can often be felt through the less rigid muscles. Rectal examination should never be omitted, especially in children, where the pelvis is shallow and the appendix is more apt to be located in it.

Differential Diagnosis.—*Acute Gastro-intestinal Disturbances.*—In these, as in appendicitis, there is often a history of indiscretion in diet, followed by abdominal pain and vomiting. In acute gastroduodenal catarrh the pain is felt over the epigastrium and is never as severe or colicky as in appendicitis. The nausea and vomiting are far more marked early symptoms, and may be almost constant. There is no true muscular rigidity and but slight, if any, tenderness. In intestinal colic the pain may be as severe as in appendicitis, but is usually referred to the umbilicus and does not become more intense, as it does in appendicitis. There is also no localized rigidity or tenderness and the attack often subsides as soon as an enema is given, while in appendicitis the symptoms become more marked from hour to hour.

In some cases of intestinal colic there is accompanying vomiting, diarrhea, and flatulency. There is an absence of any local rigidity and tenderness and the pains, if present, are more diffuse.

Intestinal Obstruction.—In the first twenty-four to forty-eight hours there is no difficulty in distinguishing this condition from appendicitis. When, however, peritonitis has begun and caused a septic paralysis of the intestines, it is impossible to distinguish them, except from the history.

In intestinal obstruction, if there is any localized pain, it is referred to the umbilicus. A systematic examination of the hernial openings often reveals the cause of the obstruction. Volvulus pains are referred to the left side of the abdomen and early distention of this half of the abdomen is most marked. Obstruction from volvulus, tumors, and bands is more common in adults. In children intussusception is more frequent, and a tumor can often be felt per rectum or in the

A B

FIG. 172.—A, SPECIMEN OF AN APPENDIX SHOWING VARIOUS STAGES OF PATHOLOGIC CHANGES.

1, Gangrene of the mucous membrane; 2, marked catarrhal inflammation of the mucous membrane; 3, cicatricial obliteration of the lumen of the appendix (appendicitis obliterans); 4, greatly thickened muscular and serous coats; 5, inflamed fat of mesenteriolum.

B, GANGRENE OF ALL OF THE WALLS OF AN APPENDIX CONTAINING TWO LARGE ENTEROLITHS.

iliac fossæ, and blood and mucus are passed per rectum. In obstruction the pulse is but little higher than normal until peritonitis occurs, while in appendicitis there is a gradual rise of pulse and temperature from the beginning. The early nausea and vomiting of obstruction recur so frequently as to become the most prominent symptom. The bowels cannot be moved nor can flatus be passed, and the abdominal distention occurs in greater degree, as well as much earlier, than in appendicitis. In appendicitis vomiting occurs quite early, is never stercoraceous, does not recur until peritonitis sets in, and constipation is never absolute.

Typhoid Fever.—In the first two weeks of certain cases of typhoid there is rigidity and tenderness of the right iliac region, accompanied by fever. In the absence of a good previous history such cases are apt to impress one as being an appendicitis. As a rule, however, a differentiation is possible. The pain and rigidity are never as marked in typhoid as in appendicitis; the pulse is out of proportion too, being much slower than in appendicitis. In addition, there is a leukocytosis in appendicitis and a leukopenia in typhoid. The Widal reaction is characteristic of typhoid and is absent in appendicitis unless the patient has had a previous attack of typhoid. If a history can be obtained, it reveals the fact that the disease has been gradual in onset, accompanied by headache, backache, lassitude, and often by epistaxis. The enlargement of the spleen and the steady rise of temperature with a relatively low pulse-rate are characteristic of typhoid.

The differential diagnosis between typhoid perforation and appendicitis is referred to on page 269.

Gastric Ulcer.—This is usually preceded by a history of long-continued pains referred to some particular spot in the epigastrium, increased by the taking of food and often accompanied by hematemesis or melena. The majority of gastric ulcers occur in young women who are anemic and have had sedentary occupations. The examination of the stomach contents shows an increased amount of hydrochloric acid.

Duodenal Ulcer.—There is a history of long duration of pain, occurring in middle-aged men, two or three hours after eating. The pain is felt in the epigastrium, but may be referred to the shoulder or to the right iliac region.

The principal diagnostic points of perforating gastric and duodenal ulcers are discussed on pages 266 and 267. A perforating gastric ulcer can be diagnosed from the previous history, from the location of the pain, and from the presence of rigidity in the epigastrium. The symptoms of collapse and the increase in pulse-rate are

much more marked than in appendicitis. The respiration is rapid and costal in type. In perforating duodenal ulcer the pain is not so typical in its location and is often referred to the right iliac region, but there is no rigidity in this location, as in an appendicitis.

When, after the perforation of a gastric or duodenal ulcer, peritonitis has occurred, and the septic fluid collects in the iliac fossa and pelvis, causing tenderness and rigidity, accompanied by abdominal distention, vomiting, increased pulse-rate, and leukocytosis, a differentiation from appendicitis is impossible, except from the previous history.

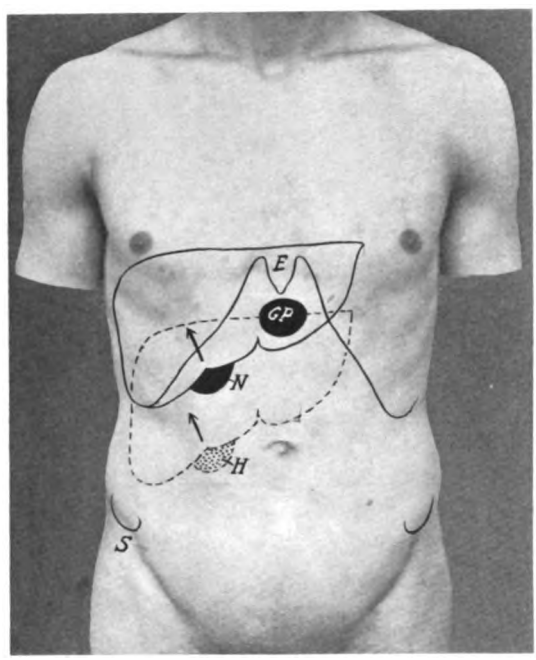

FIG. 173.—LOCALIZED PAIN AND RIGIDITY IN NORMALLY LOCATED AND DISPLACED GALLBLADDER.

N, Normal position of gallbladder and liver; the black arrow indicates the most frequent direction of radiation of pain to the right shoulder; *H*, location of pain, etc., in descended liver; *E*, ensiform process; *GP*, location of pain and rigidity in abscesses of the left lobe of the liver.

Acute Cholecystitis.—The pain in this condition, whether due to gallstones or not, is localized in the right upper quadrant, as a rule, rather than in the right lower, as in appendicitis. The pain is usually more cutting in character and radiates to the right shoulder. Muscular rigidity and tenderness are most marked over the junction of the right rectus and the costal arch. There is often also a history of previous attacks, accompanied, in some cases, by slight or marked jaundice (the latter if common-duct calculi are present), early and repeated vomiting, and chills if an infection of the bile-passages has existed.

In some cases a tender tumor, corresponding to the gallbladder, can be outlined by both percussion and palpation (Fig. 173).

There are cases, such as those referred to later, where a differentiation between cholecystitis and appendicitis is impossible. These are where the gallbladder is at a lower level than normal. If

due to an elongated Riedel's lobe (Fig. 162), the resistant mass of liver tissue can often be felt through the thin and flabby abdominal walls. Similarly, one can outline a descended liver in some cases (Fig. 173).

If pus form in the gallbladder (empyema), the rigidity and tenderness are higher up than in appendicitis. However, leukocytosis and the existence of a tender mass in the right upper quadrant may lead to some confusion with appendicitis complicated by abscess formation in an appendix located high up (Fig. 171).

Acute Inflammation of the Female Adnexa.—This can be best understood by a reference to the following table:

Acute Appendicitis.	Acute Salpingooöphoritis.
1. Muscular rigidity marked.	1. But little rigidity.
2. Pain begins at umbilicus and becomes localized over McBurney's point unless appendix points to pelvis.	2. Pain lower down in abdomen just above Poupart's ligament.
3. Tenderness over right iliac fossa.	3. Tenderness low down over pelvis.
4. Pain followed in a few hours by nausea and vomiting.	4. Nausea and vomiting infrequent.
5. Bimanual examination negative unless appendix in pelvis, then tender mass lateral to uterus.	5. Bimanual examination shows tender mass lateral to or behind uterus.
6. No history of gonorrheal infection.	6. Usually history of infection to be obtained.

When acute appendicitis occurs during the course of an acute inflammation of the female pelvic organs, a differentiation is impossible, except that the pain is most intense over McBurney's point.

Other conditions from which appendicitis must be differentiated are:

1. Renal and ureteral colic (page 270).
2. Pyonephrosis (page 252).
3. Pelvic inflammatory conditions in women.
4. Acute pancreatitis (page 270).
5. Twisted pedicles of ovarian and uterine tumors (page 273).
6. Abdominal crises due to Meckel's diverticulum (page 279).
7. Torsion of the spermatic cord of a normal or undescended testis (page 274).
8. Inflammation of the intraabdominal portion of the vas deferens (page 276).
9. Embolism and thrombosis of the mesenteric vessels (page 272).
10. Acute pleural or pulmonary inflammation (page 276).
11. Dietl's crises due to the kinking of the ureter in movable kidney (page 271).

2. GALLSTONE COLIC.

One of the most frequent acute abdominal conditions is that which is due to biliary calculi.

Diagnosis.—*Pain and Tenderness.*—This is of an excruciating character, exceeding in severity that due to almost every other acute abdominal condition. It is the result of two factors. The first of these is the acute cholecystitis resulting from infection. This pain of the acute cholecystitis is less severe than the second, or pain due to the muscular spasm of the cystic or common duct. This second factor is the chief cause of the pain in biliary colic.

The pain is felt in the right hypochondrium and epigastrium, radiating usually to the right and rarely to the left shoulder. In some cases the pain radiates toward the right iliac region, simulating that of appendicitis.

The entire region between the right costal arch and umbilicus is extremely sensitive to pressure during the attack. If the liver is at a lower level or there is an elongated Riedel lobe, the pain, tenderness, and rigidity may be at the level of the umbilicus or even in the right iliac region itself.

Muscular Rigidity.—This is most marked in the right hypochondrium, but may be at a lower level if the gallbladder is in an abnormal position (see Fig. 173).

Vomiting.—This is an early symptom, consisting at first of mucus, later of bile. It is present almost from the moment of the onset of the pain and recurs frequently during the attack.

Jaundice.—If present at all, it occurs only to a slight degree, in the majority of cases of gallstone colic, due to the passage of a calculus through the cystic duct. Often it can be best seen in the scleræ and on the roof of the mouth. When present in marked degree it signifies the passage of a stone through the common duct.

Fever.—In the majority of cases there is a rise of temperature in gallstone colic, due to the accompanying cholecystitis. If the temperature and other inflammatory symptoms continue after the pain has subsided, an empyema of the gallbladder is to be suspected. If the gallstone colic is accompanied by repeated chills, followed by a marked rise of temperature and a sweat, there is probably a complicating cholangitis.

The finding of gallstones in the stools is, of course, positive evidence of the attack having been one of biliary colic.

Differential Diagnosis.—*Acute Cholecystitis.*—Acute inflammation

of the gallbladder due to causes other than calculi produces less severe pain than a biliary colic. The abdominal rigidity and tenderness is not so marked, so that the enlarged gallbladder can often be outlined by percussion and palpation. There is, however, *no means of distinguishing absolutely a cholecystitis due to calculi and one not due to a simple injection or a catarrhal condition.* In the majority of cases it is the result of calculi.

Renal Colic.—In renal colic the pain usually begins in the back over the kidney and radiates down the ureter toward the testis and thigh of the same side. The kidney is tender on palpation and the urine contains blood and often pus, but is free from bile.

Appendicitis.—There is no initial rise of temperature, the latter usually appearing after a few hours. The vomiting in biliary colic immediately follows the onset, and not after a few hours, as in appendicitis. It is also more frequent during the continuance of the pain in biliary colic. The pain in the latter is more severe than in appendicitis, is located higher in the abdomen, as a rule, and radiates to the right shoulder. The muscular rigidity and tenderness are also higher, being most marked just beneath the costal arch. Appendicitis and cholelithiasis at times coexist, so that the clinical picture is a most confusing one.

Dietl's Crises and Floating Kidney.—A floating kidney may cause biliary colic, jaundice, and vomiting; symptoms of compression of the portal vein usually coexist. A diagnosis can be made only if the symptoms cease when the kidney has been felt and is replaced.

Attacks of severe colic, nausea, and vomiting may occur when the ureter is kinked, through the sudden descent of a movable kidney. The differentiation from gallstones may be made from the fact that the pain radiates along the ureter and the kidney is tender and swollen for some hours after the attack. Often its cessation is followed by a largely increased urinary flow.

Gastric and Duodenal Ulcers.—The pain of a gastric or duodenal ulcer is never as severe as that of biliary colic and it can be more accurately localized in the epigastrium. It begins soon after eating in the case of gastric, and two to three hours later, in that of duodenal ulcer. There is no rigidity or tenderness over the right hypochondrium and no rise of temperature.

3. PERFORATIONS OF ULCERS OF THE STOMACH OR DUODENUM.

The diagnosis of perforations of ulcers in these viscera can be made in the first twelve hours if the previous history is considered in connection with the acute symptoms. In 90 per cent. of perforating gastric ulcers there is a history of symptoms referable to ulcer of the stomach or duodenum, according to Brunner.[1]

Perforating gastric ulcer is more frequent in women (4 to 1), while perforating duodenal ulcer occurs oftener in men (10 to 1). Duodenal ulcer perforates twice as often as gastric ulcer.

The **symptoms** in the majority of cases are so typical that a diagnosis can be made from the following symptoms, taken in conjunction with the previous history:

Pain.—In over 95 per cent. of the cases the pain occurs suddenly and is very severe and stabbing in character, so that the patients cry out, drawing up their limbs, and often become faint. The pain is at first localized by the patient in the epigastrium, but later it becomes more diffuse.

The point of greatest tenderness in five-sixths of the cases of gastric ulcer corresponds to the point of spontaneous or subjective pain; while in duodenal ulcer the tenderness is in the right iliac fossa in the majority of cases.

Muscular Rigidity.—This symptom, as in perforations of other viscera, is, when associated with pain, of great diagnostic importance. As elsewhere explained, it can be found by passing the fingers lightly over the abdomen and not by violently prodding. The abdomen is board-like and often retracted until, after six to twelve hours, the tympany, due to beginning peritonitis, causes it to become gradually distended.

Vomiting.—This occurs in about one-third of the cases, and, as in appendicitis, if associated with pain and rigidity is of great diagnostic value. Vomiting which occurs after the first twenty-four hours is usually indicative of peritonitis. Vomiting, as an early sign, follows perforations of duodenal ulcers far more constantly than that of gastric ulcers.

Obliteration of Liver Dullness.—This symptom is so inconstant that but little reliance can be placed upon its presence or absence. Liver dullness is apt to be diminished or absent through tympanites, so that the sign is of little value. If the abdomen is not distended and there is no liver dullness to be found, it is of value taken in conjunction with the localized pain, rigidity, tenderness, and vomiting.

[1] "Deutsche Zeitschrift f. Chirurgie," Bd. lxix.

Dullness in the Flanks and Right Iliac Region.—A shifting area of dullness found in the flanks within the first twelve to twenty-four hours is of value as indicating free fluid. Even this symptom is apt to be misleading, and, as in the case of the above symptoms, too much reliance should not be placed upon it, owing to the fact that intestinal coils filled with fluid feces may give the same signs.

Pulse.—This remains unchanged in many cases until peritonitis begins, when it gradually becomes more rapid and jerky. In other cases it is rapid, feeble, and irregular from the beginning.

Respiration and Facies.—From the moment of perforation the breathing is almost entirely costal, shallow, and quick, in the effort to avoid movement of the upper abdominal regions. The face and extremities are, in the majority of cases, pale, cold, and clammy; the eyes sunken and the expression of the face one of great anxiety.[1]

Differential Diagnosis between Perforation of Gastric and of Duodenal Ulcer.—In deciding whether the perforation is due to a gastric or duodenal ulcer, the following facts must be taken into consideration.

The majority of cases of duodenal perforation occur in men, especially alcoholics; the seat of the initial pain and point of greatest tenderness is to the right of the median line; often the tenderness is most marked in the right iliac region. There is not nearly so frequently a previous history of preceding digestive disturbances as in gastric ulcer. A previous history of tarry stools and the occurrence of vomiting and pain a long time after eating, suggest duodenal ulcer.

In perforation of a gastric ulcer, the spontaneous pain and area of greatest tenderness are almost always in the epigastrium. Gastric ulcers occur more often in women about the age of twenty, with a prior history of digestive disturbance, pain soon after eating, and not infrequently of hematemesis. It is almost impossible to accurately locate the exact seat of the gastric perforation.

Differential Diagnosis between these Perforations and Other Acute Abdominal Conditions.—Perforations of the stomach from carcinoma, perforation of the gallbladder, and perforation of a tuberculous ulcer of the intestine are so rare that they need only to be mentioned.

Appendicitis.—This is the greatest source of error and is fully considered on page 256. The pain in gastric ulcer perforations differs

[1] In subacute perforations, *i. e.*, those occurring so slowly that a walling off is possible, as first described by Moynihan, all of these symptoms are present, but in far less marked degree.

in its seat from that of appendicitis, while that of many cases of duodenal ulcer more nearly coincides with that of appendicitis in being situated in the right iliac region.

In appendicitis the rigidity is more localized in the right iliac region, and there is seldom a history of digestive disturbances or of pain after eating or hemorrhage from the stomach or bowels.

Gastralgia.—There are no objective symptoms. The pain is relieved by pressure, has been present on previous occasions, does not last as long, and occurs in neurotic persons. There is no history of hematemesis or of melena.

Angina Sclerotica Abdominis.—This relatively rare condition has been mistaken for perforation. In both there is sudden onset of pain, quick pulse, and collapse, but in angina the pain is higher and passes off more quickly.

Gallstone Colic.—The pain is less severe and not so sudden, is confined to the gallbladder region, radiates to the right shoulder, there are often chills and rise of temperature. The colic attacks pass away or the pain is intermittent. The gallbladder can often be palpated and there is often a previous history of similar attacks. The other conditions from which these perforations must be differentiated are discussed elsewhere in this chapter. They are: Acute pancreatitis (page 270); thoracic affections (page 276); embolism and thrombosis of the mesenteric artery (page 272), etc., lead poisoning, renal colic, and torsion of abdominal tumors.

TYPHOID PERFORATION.

Perforations of typhoid ulcer usually occur in the third week of the disease. The diagnosis in the majority of cases can be made by careful observation of a sudden change in the patient's condition, accompanied by sharp pain in the right iliac region, muscular rigidity, tenderness, and a sudden rise in pulse-rate and respiration.

In patients who are apathetic all of these symptoms are apt to be overlooked, and the first signs which will call attention to the possibility of a perforation are the change in the expression of the face, rigidity and tenderness of the abdomen, gradually becoming diffuse, the rise in pulse-rate and the appearance of tympanites.

The same may be said to be true for typhoid perforations in children where collapse, severe abdominal pain, uncontrollable vomiting, tenderness, and distention are all much less marked than in adults.

Another condition which may prevent making an early diagnosis in

typhoid perforation is to be found in the distention of the abdomen which not infrequently accompanies the more severe cases.

If a diagnosis of perforation has not been made from the characteristic pain, muscular rigidity, and tenderness of the right iliac region, accompanied by an increased pulse-rate, fall of temperature and collapse, then a diagnosis must be made from the symptoms of beginning peritonitis. These are, in such cases, general abdominal tenderness and rigidity, repeated vomiting, and gradually increasing abdominal distention, if the latter has not existed before the onset of the pain. The loss of liver dullness is so inconstant a symptom as to be of little value in making a diagnosis of perforation. In many cases the blood-count may be of aid, frequently the normal leukopenia of typhoid being replaced by a gradually increasing leukocytosis.

Differential Diagnosis.—*Hemorrhage.*—The symptoms of hemorrhage from a typhoid ulcer of the ileum may simulate those of perforation and the two may coexist. Both produce symptoms of collapse, such as sweats, rapid pulse and respiration, sunken eyes, etc. But hemorrhage is not attended by such marked pain, tenderness, or rigidity in the right iliac region, and in an hour or two blood is passed with the bowel movement. If there is no reaction from the collapse symptoms, and abdominal tenderness, rigidity, and distention begin to appear, the case should be looked upon as one of perforation, either accompanied by or independent of hemorrhage, as the case may be.

Appendicitis.—Vomiting is more apt to accompany the initial pain in appendicitis, and there is not apt to be such an amount of collapse in the early hours of an attack as is the case in intestinal perforation.

Cholecystitis.—This usually occurs at a somewhat earlier period in the course of typhoid than does a perforation, and is accompanied by the characteristic pain, muscular rigidity, and tenderness just below the costal arch, and not over the right iliac region. There is also at times a mass to be palpated or dullness to be elicited at an early stage.

Suppurating Mesenteric Glands.—Every case described during the past few years of suppuration and rupture of the mesenteric glands occurring during typhoid and simulating perforation, has had symptoms of pain, collapse, rapid pulse, etc. The muscular rigidity, however, is not so well localized, as a rule, in the right iliac region, nor are general abdominal tenderness and distention so likely to follow, as in genuine typhoid perforation.

4. ACUTE PANCREATITIS.

The occurrence of sudden severe pain in the epigastrium, accompanied by symptoms of collapse and by vomiting, should lead one to diagnose an acute pancreatitis, if the other acute conditions which occur in the upper abdominal region can be excluded.

In addition to the above triad of symptoms, there is muscular rigidity and tenderness over the epigastrium, and when in two or three days this subsides somewhat, a tender mass can be felt here. If suppuration occurs a rise of temperature persists after the subsidence of the acute symptoms, and with it a leukocytosis. In many cases, however, death occurs on the second to fourth day of the disease. In the acute cases there is marked constipation, but this is not so absolute but that flatus can be passed by the aid of an enema. There is also fat in large quantities in the stools.

There is a subacute form in which the symptoms are all less violent. There is a constant dull epigastric pain, loss of flesh, and the vomiting is less severe. There is diarrhea instead of constipation, pus and blood appearing in the fetid stools. If an abscess has developed there is a very tender epigastric tumor accompanied by chills and fever.

Differential Diagnosis.—*Biliary Colic.*—The symptoms of this at times precede those of acute pancreatitis in many cases.

Phlegmonous Gastritis.—This is a rare condition, but very acute and fatal. The symptoms are very much the same as those of an acute pancreatitis, but the pain is not as severe; there is high fever and early signs of general peritonitis. The onset is more gradual and the vomitus contains pus and blood.

5. RENAL COLIC.

Symptoms.—In a typical case the pain is intense, causes faintness and collapse symptoms, such as feeble, rapid pulse, cold, clammy skin and extremities. The pain is paroxysmal and begins usually in the back over the kidney, radiating along the ureter to the testis or labia and thigh.

At the onset, in addition to the pain and collapse, there is often a chill and vomiting. The attack may last three to five days and then suddenly subside.

The urine during the attacks contains blood, which can at times only be found by the aid of the microscope. Frequency of micturition accompanies the attacks. The passage of the calculus during or

shortly after the attack is confirmatory evidence. Should the calculus slip back, or should the attack be due to a twisted ureter, an unusual amount of urine often follows the subsidence of the pain.

The diagnosis of atypical cases of renal colic and the diagnosis of renal calculus in general are discussed on page 365.

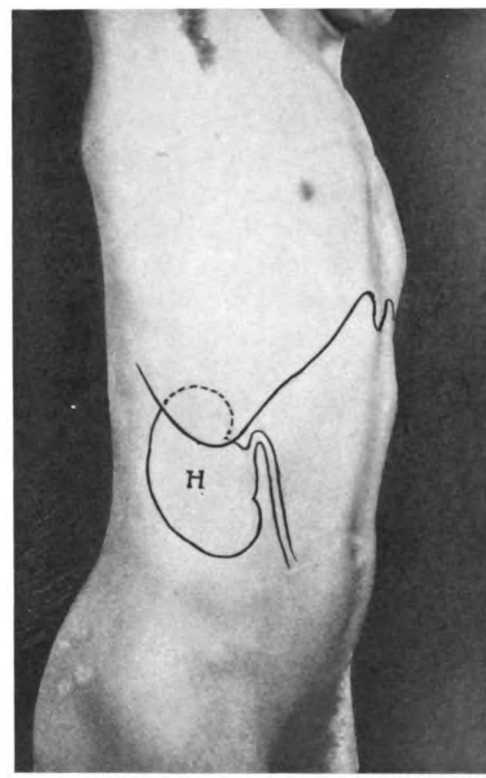

FIG. 174.—LATERAL VIEW OF RELATIONS IN INTERMITTENT HYDRONEPHROSIS OCCURRING IN A FLOATING KIDNEY, DUE TO KINKING OF THE URETER.

H, Enlarged kidney. Note the kinking of the ureter. (This is the cause of the symptoms in Dietl's crises.)

6. DIETL'S CRISES.

These are attacks of acute abdominal pain, first described by von Dietl of Vienna, accompanied by nausea, a chill, and vomiting which are the result of the kinking or bending upon itself of the ureter in movable kidney (Fig. 174). The pain may be quite severe and usually radiates along the ureter, as in renal colic. During the attack the kidney is swollen and tender, this condition lasting several hours. In some cases a distinct hydronephrosis develops during the attacks. Blood is present in the urine only after the attack has subsided, and is accompanied by polyuria, while during the attack there is diminished secretion of urine.

The diagnosis may be made from the palpation of the swollen, tender, displaced kidney, and the fact that when it is replaced the symptoms cease.

There is but little abdominal rigidity, no fever or leukocytosis, and the condition occurs most frequently in multiparous women.

Differential Diagnosis.—*Renal Colic Due to Calculi.*—In renal colic due to calculi the symptoms of pain radiating along the ureter,

nausea, vomiting, etc., are the same as in Dietl's crises. The pain, however, is much more severe and apt to be accompanied by symptoms of collapse, such as cold, clammy sweat, rapid pulse, etc. There is also blood in the urine during the attacks, while in kinking of the ureter it is only present at the end of the attacks.

If, however, the attacks of kinking of the ureter follow in rapid succession, blood is found in the urine all of the time and a differentiation is very difficult. Renal colic is less apt to be accompanied by enlargement of the kidney.

Gallstones.—The pain is located higher up in the abdomen, is much more severe, and there is rigidity and tenderness over the region of the gallbladder. The pains radiate to the shoulder. If the patient is laid on the left side, the movable kidney can be more distinctly palpated because the gallbladder rolls away.

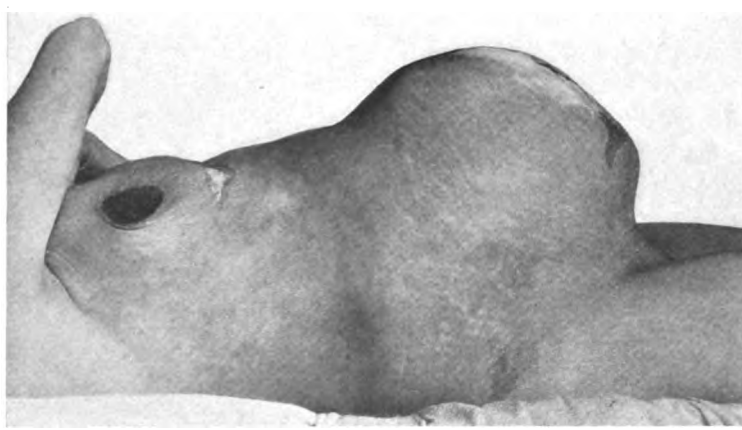

FIG. 175.—PROMINENCE OF ABDOMEN AS RESULT OF TYMPANITES FOLLOWING THROMBOSIS OF THE SUPERIOR MESENTERIC ARTERY IN A WOMAN WITH A PENDULOUS ABDOMEN.

7. EMBOLISM AND THROMBOSIS OF THE MESENTERIC VESSELS.

An acute abdominal condition which is far more frequent than was formerly thought follows the occlusion of the mesenteric vessels (Fig. 176).

Clinically it is impossible to distinguish embolism of the superior or inferior mesenteric artery from thrombosis of the mesenteric veins.

Both conditions produce, as a rule, very acute symptoms. In some cases they resemble those of intestinal obstruction; in another class of cases, peritonitis is simulated.

Embolism occurs in both sexes after middle life, secondary to endo-

carditis or to atheroma of the mesenteric vessels. Thrombosis may be primary, following acute infective processes, especially of the appendix. It may occur secondary to any hepatic condition which causes portal stasis.

In but few cases has it been possible to make a diagnosis, nor is this absolutely necessary, since the symptoms are so acute that an exploratory laparotomy is indicated, even if a probable diagnosis has only been made.

The disease begins in one of two ways. (*a*) Symptoms which simulate intestinal obstruction, with or without peritonitis. This form begins with colicky abdominal pain followed by nausea or vomiting and absolute constipation, so that not even flatus is passed. The abdomen soon becomes so distended, rigid, and tender that examination becomes very difficult (Fig. 175). (*b*) Symptoms of hemorrhage from the intestine. In this form the symptoms of early bowel paralysis are not so marked, but there is great prostration, severe colicky pain, and frequent bloody stools.

Differential Diagnosis.—This is impossible in the majority of cases, except that embolism occurs after middle life. It must be differentiated from perforations of gastric and duodenal ulcers, from acute cholecystitis (page 266), appendicitis (page 256), etc., and the various forms of intestinal obstruction.

8. TORSION OF THE PEDICLES OF OVARIAN AND UTERINE TUMORS.

The presence of such a tumor may reveal itself for the first time when the pedicle has become twisted. The onset is sudden, with severe colicky pain referred to the pelvis, accompanied by vomiting and slight muscular rigidity. If the tumor becomes gangrenous, these primary symptoms are rapidly followed by those of a spreading peritonitis. The rigidity and tenderness, which were at first present in only the lower part of the abdomen, become general. The pulse-rate increases rapidly and abdominal distention becomes marked, and the patient septic.

The diagnosis may be made by a pelvic examination and the palpation of the tumor mass and its pedicle. Without the use of an anesthetic, such examination can only be made with difficulty, owing to the muscular rigidity. In some cases a history of gradual enlargement of the abdomen, preceding the acute attack, can be obtained.

After a septic paralysis of the bowels has occurred, the case cannot be differentiated from peritonitis due to other causes, unless the vaginal examination shows the presence of a tumor and its pedicle.

Differential Diagnosis.—*Appendicitis.*—In the early hours, if the tumor is located on the right side, there may be some resemblance. The palpation of a tumor will, however, at once exclude an appendicitis, since such a large inflammatory mass does not form in so short a time. Later on such a mass may resemble appendicitis with abscess formation, but the tumor is more elastic and there is more general abdominal rigidity and tenderness, as well as other symptoms of a spreading peritonitis.

9. TORSION OF THE SPERMATIC CORD.

This may occur in an imperfectly or in a normally descended testis (Fig. 232). It usually follows heavy lifting, etc. The onset is very sudden, greatly resembling that of a strangulated hernia. The attack begins with severe pain in the region of the testis, far greater than in an ordinary epididymitis, accompanied by collapse, vomiting, constipation, great local tenderness, and swelling. The principal condition from which it must be differentiated is a strangulated hernia. This is as follows (Eccles):

	Torsion of Cord.	Strangulated Hernia.
History	Probable of strain.	Often of strain.
Position of testis	Often imperfectly descended.	Usually fully descended.
Shock	Moderate.	Often severe.
Vomiting	Slight and not persistent.	Severe and persistent.
Constipation	May be present.	Is absolute.
Tenseness of swelling	Not marked.	Marked.
Impulse on coughing	None.	None.
Condition of cord	Tender, twisted, and swollen.	Not to be felt.

10. VISCERAL CRISES.

These may occur either as a complication of tabes or of an angioneurotic edema.

Those due to tabes may at times be so severe as to fully simulate some of the previously named acute conditions, such as appendicitis, perforation of ulcers, gallstone colic, or even intestinal obstruction.

In patients at or above middle age, especially males, who have such symptoms, the possibility of visceral crises of tabes must not be overlooked, and other evidences of the disease searched for.

In the most typical cases there are severe epigastric pains, repeated vomiting, great prostration, and rapid pulse. The attack may terminate fatally in a short time, or continue for several hours or even for days and recur from time to time.

Crises are also associated with various manifestations of skin affections of the erythema group, and with attacks of angioneurotic edema. There is severe abdominal pain which may last for hours. One case, described by Osler,[1] was mistaken for renal colic. The pain

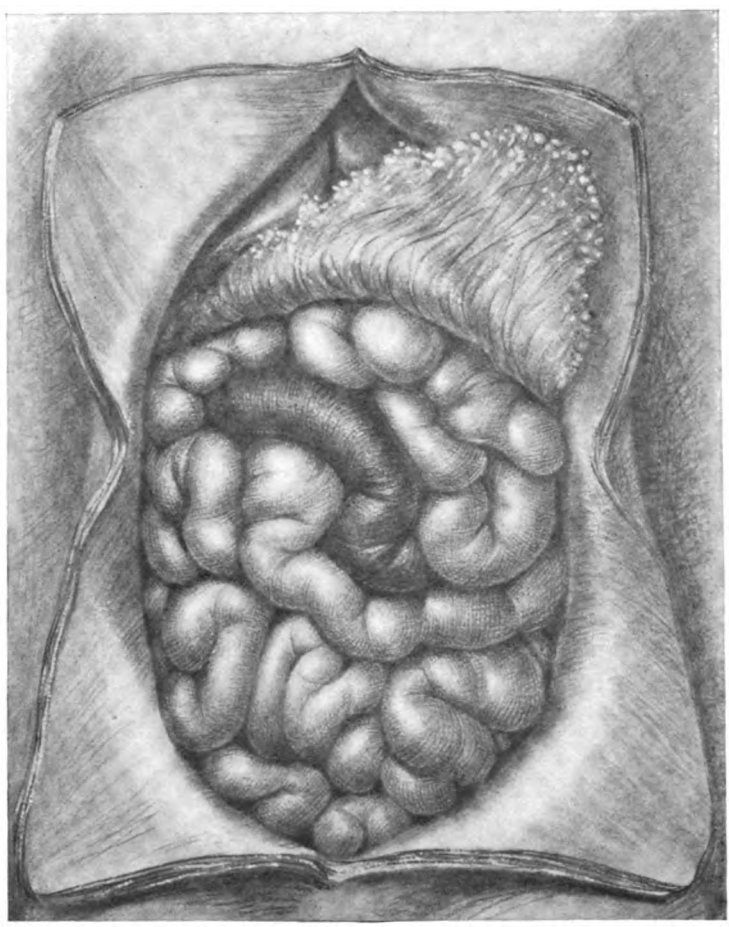

FIG. 176.—GANGRENE OF A SINGLE LOOP OF SMALL INTESTINE DUE TO EMBOLISM OF MESENTERIC ARTERY (Kenerson).

is sometimes accompanied by nausea and vomiting, in other cases by diarrhea, and in still others by the passage of blood.

The diagnosis can only be made from the history of the cutaneous affections or of repeated attacks of sudden edematous swelling in various parts of the body.

[1] "American Jour. Med. Sciences," Jan. 1, 1904.

11. ANGINA SCLEROTICA ABDOMINIS.

This occurs in elderly people in the form of attacks of severe pain in the epigastrium. It is due to an atheromatous condition of the vessels of the splanchnic area and must be differentiated from lead colic and from the crises of tabes. The attacks may be accompanied by diarrhea. The stool at times contains large quantities of blood.

12. REFERRED PAIN FROM SPINAL AND THORACIC CONDITIONS.

Spondylitis, and tumors of the spinal cord, of its membranes, or of the vertebræ, may cause severe abdominal pain, which is referred to the terminal filaments of the spinal nerves of the corresponding segment in the abdominal wall. The pain is seldom as acute as in true abdominal affections, and is not accompanied by muscular rigidity or tenderness. Examination of the spine for evidences of spondylitis (page 684) will soon reveal the nature of the referred pain. Examination of the nervous system and the history of the case will eliminate tumors of the cord or spinal column.

Thoracic Conditions.—Cases of both pneumonia and pleurisy occur, in which there is complaint of severe pain in the abdomen at the onset of the disease. This is especially true in children. There may be rigidity of the abdominal muscles on the side affected. In pneumonia there is a history of a chill. The acute onset is followed by dyspnea, and marked increase in respirations and pulse-rate. The pain is seldom as well localized as in the acute abdominal conditions, nor is the muscular rigidity as circumscribed and constant.

There is one form of pleurisy (diaphragmatic) which simulates acute abdominal affections very closely. The breathing is shallow and costal, the pain is severe and referred to the upper abdominal region, as in perforations of gastric and duodenal ulcer, acute pancreatitis, etc.

Objectively but little can be found and a differential diagnosis is difficult in the early hours. The case should be watched for several hours before a final diagnosis is made.

13. INFLAMMATION OF THE INTRAABDOMINAL PORTION OF THE VAS DEFERENS.

Severe pain, of a colicky nature, referred either to the right or left iliac regions is the initial symptom. It is later accompanied by nausea or vomiting, as a forerunner of epididymitis or orchitis.

When this condition exists on the right side, it may be mistaken for an appendicitis. Especially when it precedes the orchitis of mumps, one must avoid this error.

In gonorrheal cases, the diagnosis may be made from the urethral discharge, which often ceases suddenly before such an attack. When it follows mumps, the previous history is of value.

The most tender point is not over the middle of the right iliac region (McBurney's point), as in appendicitis, but is deeply situated over the middle of Poupart's ligament or deep down in the pelvis. Rectal examination is of great aid in making a differentiation.

Group III.—Early Signs of Intestinal Obstruction.

ACUTE INTESTINAL OBSTRUCTION (ILEUS).

In every case before a definite diagnosis of intestinal obstruction is made three points must be considered:

1. What symptoms indicate intestinal obstruction?
2. What is the probable nature and seat of the obstruction?
3. What other symptoms might simulate it?

1. **Symptoms of Intestinal Obstruction.**—The most typical ones are:

(*a*) Absolute constipation.

(*b*) Constantly recurring vomiting finally becoming fecal.

(*c*) Pain of varying intensity and location.

(*d*) Gradual or sudden distention of the abdomen.

(*e*) Gradually increasing pulse-rate.

(*f*) Visible peristalsis and the presence of a tumor.

(*g*) Collapse symptoms, such as sunken eyes, anxious face, cyanosis, pallor, dyspnea.

If a patient, suffering from a sudden attack of abdominal pain, has constantly recurring vomiting, and every effort to secure the passage of feces or flatus results negatively, a diagnosis of intestinal obstruction may be made.

The three symptoms common to all forms of abdominal obstruction are:

1. Absolute inability to secure the passage of feces or flatus.
2. Vomiting first of mucus, then of bile, and lastly of fecal matter.
3. Pain.

Constipation is often the first symptom. Before declaring it absolute, however, high rectal enemata should be given, with the patient lying on his back with hips elevated. The fountain syringe or irrigator

does not need to be raised more than three feet above the patient. An ordinary high rectal tube is inserted almost its full length, the fluid being allowed to run through the tube during its insertion into the rectum. The temperature of the liquid should never be above 110° F. and the quantity used should not exceed two quarts in adults and one and one-half pints in children. To test the passage of flatus most accurately it is best to keep the outer end of the tube under water and thus observe the escape of bubbles of gas as they leave the tube.

If no morphin has been given, and all the fecal matter below the obstruction has been washed out, and there is no escape of flatus or feces on repeating the enema, the conclusion can be drawn that some obstruction either of adynamic or mechanical nature exists.

The only exception to the statement that absolute constipation is one of the most important diagnostic signs of intestinal obstruction occurs in those cases of intussusception in which sufficient lumen remains in the center of the invaginated gut to permit the passage of frequent liquid fecal stools. The diagnosis in such cases must be made from the other special signs of intussusception, referred to below.

Vomiting.—The most characteristic emesis is that occurring either with or independently of pain, but so frequently repeated that nothing is retained.

Fecal vomiting does not usually appear until the third or fourth day. Therefore a diagnosis must be made at an earlier period to be of value in saving the patient's life by operation.

The vomiting which accompanies the pain of other acute abdominal affections, such as appendicitis, is primary, *i. e.*, it occurs perhaps once or twice within the first few hours after the onset of pain, but is not frequently repeated unless peritonitis sets in.

In intestinal obstruction the emesis begins rather innocently at first, as in the affections of Group II, but constantly recurs, so that anything which is swallowed remains in the stomach but a short time.

The vomitus is at first composed of the food ingested before the attack began, mixed with mucus. Later it consists of the bilious vomit, so frequently seen in acute gastroenteritis, though more frequently repeated than in the latter. After a variable time, usually the third to fourth day, it becomes of a brownish-black color and of fecal odor. Emesis is then almost constant.

Pain as a diagnostic sign varies greatly. It is most marked in obstruction due to volvulus, to bands, or to protrusion through external or internal hernial apertures.

There are cases in which but little pain is present and the diagnosis

must be made from the absolute constipation, constant vomiting, and gradually increasing tympanites.

The pain is at first sharp and colicky in character. Later it becomes more or less continuous, until, the paralysis having become complete on the third or fourth day, pain ceases.

A gradually increasing distention of the abdomen is characteristic of intestinal obstruction. Its distribution over the abdomen varies according to the seat of the obstruction, and is referred to in detail later. The pulse-rate does not, as a rule, increase as steadily as in peritonitis. In some forms of obstruction, however, such as intussusception, the pulse-rate is rapid and weak from the beginning.

Peristaltic waves may, at times, be seen traveling in an opposite direction from the normal during the first forty-eight to seventy-two hours. This is to be seen quite easily before the abdominal distention is too great, provided there is not too much fat in the abdominal wall.

A tumor is palpable in many cases in which the acute symptoms follow those of chronic stenosis of the bowel, of long duration. It can also be felt in cases of intussusception along the transverse colon, in the left iliac fossa, or per rectum.

The symptoms of collapse appear gradually in the majority of cases, usually about the third or fourth day. Rarely, they appear suddenly, at an earlier period, in cases of volvulus.

Probable Nature and Seat of the Obstruction.—Every patient should be examined before operation to ascertain these facts. Such examination should include:

(*a*) The previous history.

(*b*) The physical examination of the abdomen itself.

(*c*) Rectal and vaginal examination.

STRANGULATION.

History.—Strangulation most frequently occurs in adults who have a previous history of attacks of abdominal pain, a previous attack of peritonitis, an operation on the abdominal viscera, or a recognized hernia. The previous history may, however, throw absolutely no light on the present condition, especially in those cases in which strangulation by bands derived from Meckel's diverticulum occurs. The previous existence of a hernia is of value, since strangulation of only a portion or the whole of a coil of intestine (acute partial enterocele) may give rise to the same symptoms as though the entire lumen of the gut were obstructed.

Abdominal Pain.—This is usually quite severe and of a colicky

nature. In the case of strangulated hernia it is most marked in close proximity to the hernial opening.

Nausea and Vomiting.—These occur quite early and are more marked in this form of intestinal obstruction than in any other except volvulus. Vomiting becomes fecal from the third to the fifth day.

Constipation.—This is absolute in strangulation. Enemata given in the early hours bring away some fecal matter; after this they result negatively.

Shock.—This is quite marked, as a rule, although it may not appear until the second or third day of the obstruction.

Examination of Abdomen.—The distention of the abdomen appears quite early, being especially marked in the central portions of the abdomen if the small intestine is involved, and in the lateral portions if the large intestine is obstructed. Peristalsis may be seen in the early hours, through a thin abdominal wall. It can often be artificially elicited by light tapping on the abdominal wall.

VOLVULUS.

This can rarely be diagnosed before operation.

Previous History.—It occurs most often in adults, especially those suffering from chronic constipation. At times there is a history of previous attacks of peritonitis.

Pain.—Pain is often severe from the beginning, and in some cases quite accurately localized to the left of the umbilicus. It is very severe and colicky in nature.

Nausea and Vomiting.—These do not occur as early as in strangulation and the vomitus becomes fecal on the third or fourth day.

Constipation.—This is more marked at an early period than in any of the other forms of obstruction, owing to the fact that the large intestine is involved.

Shock.—This does not occur as early as in strangulation or intussusception, but may come on quite suddenly on the third or fourth day, and be extreme in character.

Examination of Abdomen.—Visible peristalsis may, at times, be seen on the left side of the abdomen, beginning at the point of obstruction and traveling upward and downward along the line of the transverse colon. The distention of the abdomen is much more extensive than in obstruction of the small intestine by strangulation. It is especially marked along the lateral aspects of the abdomen, often being horseshoe in outline, corresponding to the course of the colon.

INTUSSUSCEPTION.

The following are the most characteristic diagnostic points of intussusception, according to Hess, who has collected them from 1028 cases.

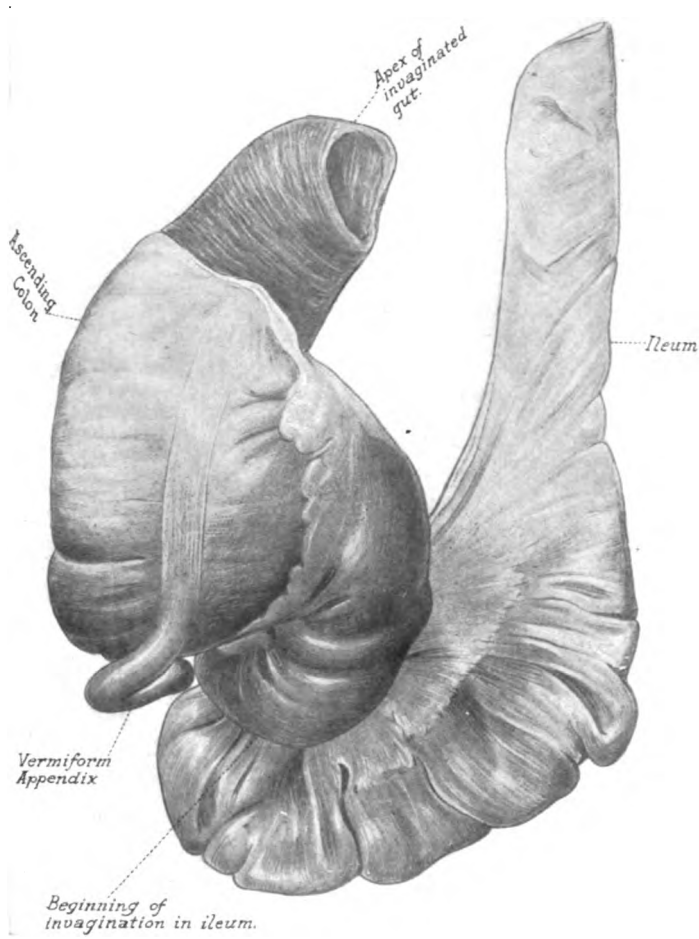

FIG. 177.—INTUSSUSCEPTION.

The illustration was made from a specimen of intussusception in an adult, in which the clinical picture was that of an appendicitis. It is of the iliac variety, in which one portion of the ileum has been invaginated into the other, the latter representing that portion of the ileum which is in close proximity to the ileocecal valve. The difference in color of the invaginated mucous membrane, which was deeply congested and hemorrhagic, is well shown.

Previous History.—There may be a history of some intestinal disturbances, rarely one of abdominal trauma, but in the majority of cases the first symptoms appear very suddenly.

Abdominal Pain.—First symptom without premonition, colicky in

character, uninterrupted at onset, later intermittent. In children inability to localize it.

Nausea and Vomiting.—Nausea and vomiting occur either simultaneously with the pain or immediately after. May be continuous or occur at intervals.

Evacuations of the Bowels.—In acute cases we usually have one or more evacuations of fecal matter. After this, if occlusion is complete, there is complete absence of the passage of fecal matter and flatus. Hemorrhagic evacuation is one of the most constant symptoms of invagination. It varies from a few streaks to a profuse hemorrhage, which may cause death.

Prostration.—Prostration is sudden in development and out of proportion to the other symptoms present.

Tumor.—This is the most important physical sign from the diagnostic standpoint. In 197 cases in which there is a complete history, 183 gave the history of the presence of an abdominal tumor. The presence of a rectal tumor was noted in 35 cases and an absence of same in 38 cases. The most frequent seat of the tumor is the region of the sigmoid flexure. The tumor is relatively very movable.

Meteorism.—Meteorism is usually slow in development and its absence is of diagnostic import. It depends upon the degree and seat of the obstruction.

Tenesmus.—Tenesmus is much more frequently present than is meteorism. It is especially severe in intussusception of the sigmoid and rectum.

Condition of the Abdomen.—Characteristic symptoms or signs, recognizable on the abdomen superficially, are usually absent.

Fever.—Fever occurs in about 40 per cent. of all cases of invagination in which the symptom is mentioned. Its presence is to be expected when complications have taken place.

Obstruction from Tumors or Foreign Bodies.

History.—An obstruction from gallstones is to be suspected in elderly women, especially if there has been a history of prior attacks of gallstone colic. Obstruction from tumors can only be suspected if there is a previous history of gradual loss in weight, or if symptoms of chronic stenosis, like those referred to on page 341, have been present for some time before the symptoms of complete obstruction occurred. The symptoms of obstruction from tumors or foreign bodies appear rather insidiously in adults, as compared with those due to strangula-

tion or volvulus. There is but little pain and abdominal distention is much more gradual in its onset.

Pain and vomiting are not marked or severe, as a rule. The peristalsis is very distinctly visible through the thin abdominal wall in this form of obstruction. The constipation is absolute, however.

Rectal and vaginal examinations are of the greatest value in adults in this form of obstruction for the purpose of determining the presence or absence of impacted feces or the presence of a pelvic tumor which causes compression of the intestine. In this form of obstruction there may be apparent relief, consisting in the passage of feces and flatus, and then recurrence in the form of symptoms of absolute obstruction.

Adynamic Ileus.

A form of intestinal obstruction due to acute paralysis of the muscular fibers of the intestinal coats is called adynamic ileus. It may follow laparotomies, injuries of the spinal cord in the dorsal region (see page 668), or may appear without any apparent cause. It is not due to a septic paresis of the intestine, but the result of inhibition of nerve impulses. The diagnosis differs only in the history and absence of objective findings from the other forms of obstruction.

Differentiation.—The principal conditions from which acute intestinal obstruction must be differentiated are the various affections mentioned under Group II. It is often very difficult to differentiate acute ileus from a spreading or general peritonitis, after the occurrence of bowel paralysis in the latter condition, usually on the second or third day. This difficulty is due to the fact that in both there is absolute constipation, incessant vomiting, great prostration, and rapid pulse. There is, perhaps, less rigidity and less pain in these advanced cases of intestinal obstruction than in those of peritonitis. Of great diagnostic import is the presence of a history pointing to an appendicitis or some similar condition, and of like importance is the finding of a strangulated hernia, or other causes of intestinal obstruction. In the early period, *i. e.*, in the first twenty-four to thirty-six hours, the following differential points are of value:

	Acute Peritonitis.	Acute Intestinal Obstruction.
1. Rigidity	Uniform and marked.	Not so marked.
2. Abdominal distention.	Gradual.	Rapid except in intussusception.
3. Visible peristalsis	Not present.	Often visible in early hours.
4. Pulse	Gradual increase in frequency.	Rapid increase in frequency.
5. Vomiting	Present at first but does not recur until third day.	Incessant from beginning, becoming fecal.
6. Constipation	Some results from enemata in early hours.	No result except in fecal impaction.

Other conditions from which intestinal obstruction must be differentiated are:

Acute Pancreatitis.—In this the constipation is not complete. Vomiting never becomes fecal. The rigidity is confined to the upper half of the abdomen and the shock and severe pain in the epigastrium are present from the onset.

Acute Enteritis.—In this there may be repeated vomiting and pain at the umbilicus; there is usually diarrhea present or it is possible to secure bowel movements by means of enemata. The pulse does not increase in frequency as the hours pass, except when the diarrhea is very copious. Abdominal rigidity is, as a rule, not present.

Perforation of an Ulcer of the Stomach or Intestine.—As in pancreatitis, the symptoms of shock and pain are more severe and sudden from the beginning. There is often a previous history of ulcer and the symptoms of peritonitis gradually develop.

Thrombosis and Embolism of Mesenteric Artery.—The symptoms of this condition, when there is no blood passed with the bowel movement, resemble greatly those of acute obstruction, and it is impossible to make a diagnosis before operation, but the possibility of embolism occurring in a person suffering from arteriosclerosis must be borne in mind. Aside from this, the history will throw but little light on the diagnosis.

The symptoms of paralysis of the gut in this condition are so rapid in their onset that it is impossible, in the majority of cases, to distinguish between this condition and obstruction from mechanical or dynamic causes.

Finally, it may be said that the *diagnosis of intestinal obstruction often cannot be made at the first examination in the early hours. But the examination should be repeated from hour to hour,* and if no bowel movement has occurred or the enemata are unsuccessful, and the vomiting continues, accompanied by rise of pulse-rate and abdominal distention, no delay should be permitted in performing an exploratory laparotomy. Such an operation, delayed more than forty-eight hours, during which the patient is becoming toxic from the absorption of stercoraceous material and suffering from the shock of intestinal obstruction, usually proves fatal.

Group IV.—Early Signs of Internal Hemorrhage.

RUPTURED EXTRAUTERINE PREGNANCY.

There is often a history of a long period of sterility, followed by a partial or entire cessation of menses for one or more periods, and the

signs of pregnancy with expulsion of decidua per vaginam from time to time.

The rupture of such a pregnancy may be diagnosed from the sudden onset of severe abdominal pain, accompanied by collapse, in a woman having the above history.

The face and visible mucous membranes are very pale, there is great restlessness and thirst, repeated attacks of syncope, and a rapid, weak pulse. The abdomen is uniformly rigid and tender, but not as marked as in a peritoneal infection. Distention gradually increases and may become quite marked. Bimanual examination may reveal a tender mass lateral to the uterus or in the culdesac of Douglas.

ABDOMINAL TUMORS.

When we examine a patient with an abdominal tumor two questions present themselves:

1. Which viscus is involved?

2. What is the nature of the tumor?

These two questions cannot be answered without careful consideration of all of the data at hand.

These data are acquired as follows:

1. A detailed history is taken.

2. The great probability of tumors of certain viscera occurring in the corresponding locations.

3. The results obtained from an examination of the abdomen augmented by certain tests and procedures to be described.

1. **History.**—In considering the history one must not fail to note the age, habits, venereal history, prior illnesses, previous operations, gain or loss in weight, rapidity of enlargement of the abdomen, and any other symptoms accompanying the presence of the tumor. These are referred to again in connection with the individual forms of tumors.

2. **Probabilities of Tumors of Certain Viscera Occurring in Corresponding Locations.**—The normal location and other characteristics of each abdominal viscus must be borne in mind. This is of considerable aid in making a diagnosis, since in the case of any tumor we must first think whether it corresponds in location to some normal viscus. We can often identify certain tumors by their resemblance in outline, edge and consistency to such a normal viscus. This is especially true at an early period of the development of the tumor.

Many tumors of the gallbladder, liver, spleen, and kidney, correspond in both their position and shape to the normal organ (Fig. 178).

An overdistended urinary bladder may be mistaken for an abdominal tumor unless the normal location and shape, when it is full, are remembered.

It is not to be denied that certain organs, if situated in a part far away from their normal location, may be normal in size or be markedly altered and not be recognized as belonging to these viscera. Thus a normal-sized spleen may be displaced so as to lie in the right iliac fossa, or a kidney be located in the pelvis.

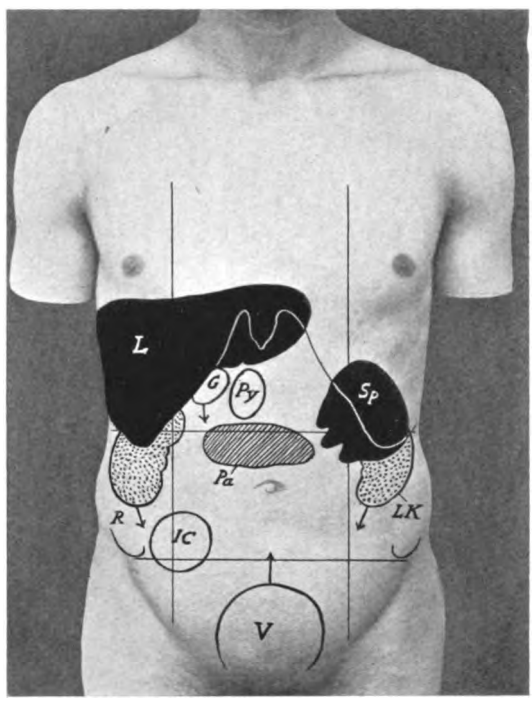

FIG. 178.—MOST FREQUENT LOCATIONS OF VARIOUS TUMORS OF THE ABDOMINAL VISCERA.

The black arrows indicate the directions in which they grow: *L*, Liver; *G*, gallbladder; *Py*, pylorus; *Pa*, pancreas; *R*, right kidney; *LK*, left kidney; *Sp*, spleen; *IC*, ileocecal tumors; *V*, tumors due to distended bladder, ovarian cysts growing upward, fibroids of uterus, etc.

These are exceptional cases, and yet it is these very unusual forms which render the diagnosis of abdominal tumors a difficult problem which in many cases only an exploratory laparotomy solves.

3. **The Results Obtained from the Abdominal Examination and its Adjuncts.**—This should be undertaken in a systematic manner by the usual methods of physical diagnosis, especially inspection, palpation, and percussion. The necessity of rectal, vesical, and vaginal examination should never be forgotten. In addition, it is necessary to have a good working knowledge of all that chemical and microscopic analysis will reveal. Lastly, inflation of the stomach and colon will throw much light on the diagnosis.

Under certain conditions examination of the abdominal cavity is rendered very difficult. These conditions are:

1. Rigidity of the abdominal wall. This is especially the case in

infants and young children, in nulliparæ, in muscular male adults, or where inflammatory changes are present. It may be necessary to give an anesthetic to overcome this resistance.

2. A great amount of fat in the abdominal wall. This is one of the greatest obstacles, and is not always overcome, even though the abdomen be relaxed or an anesthetic be given.

3. The presence of free fluid in the peritoneal cavity.

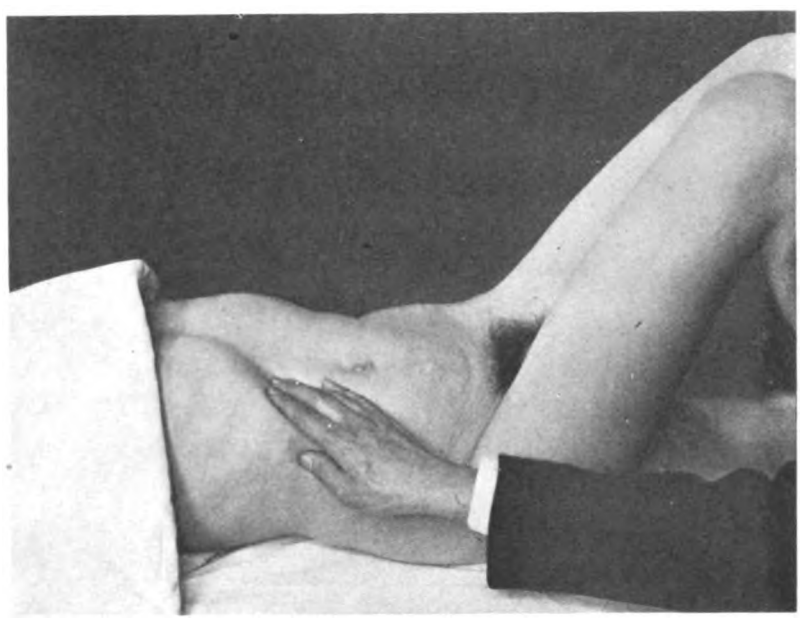

FIG. 179.—METHOD OF PALPATING THE GALLBLADDER OR PYLORUS.

The patient should be laid upon the back with the shoulders slightly raised and thighs flexed upon the abdomen, so that the soles of the feet rest squarely upon the bed. The examiner should approach the patient from the right, laying the hand flat upon the abdomen, and insert it gradually deeper while the patient is instructed to breathe, and thus relax the abdominal wall.

In such cases it is often necessary to tap the abdomen and examine the patient before the fluid has had an opportunity to reaccumulate.

4. The presence of a considerable degree of tympanites.

5. The presence of a distended bladder.

In general, the best posture for examination is with the patient lying upon the back, with the shoulders raised and thighs flexed upon the abdomen. Certain special postures and methods are described with the form of tumor in which they are of use.

I. *Inspection.*—This shows us the following:

(*a*) The dilatation of the superficial veins. This may indicate

obstruction in the portal circulation if central, and in the vena cava inferior if lateral (Fig. 188).

(*b*) The color of the skin. A change involving the color of the entire body, for example, jaundice in carcinoma of the pancreas (Fig. 186) or anemia in malignant conditions, may occur.

(*c*) Where the enlargement, if visible, is located, *i. e.*, ascites causes a general widening, while ovarian cysts enlarge the lower portion of the abdomen. Tumors of the spleen or kidneys enlarge their corresponding lateral regions. A dilated stomach or a pancreatic cyst causes a prominence around the umbilicus.

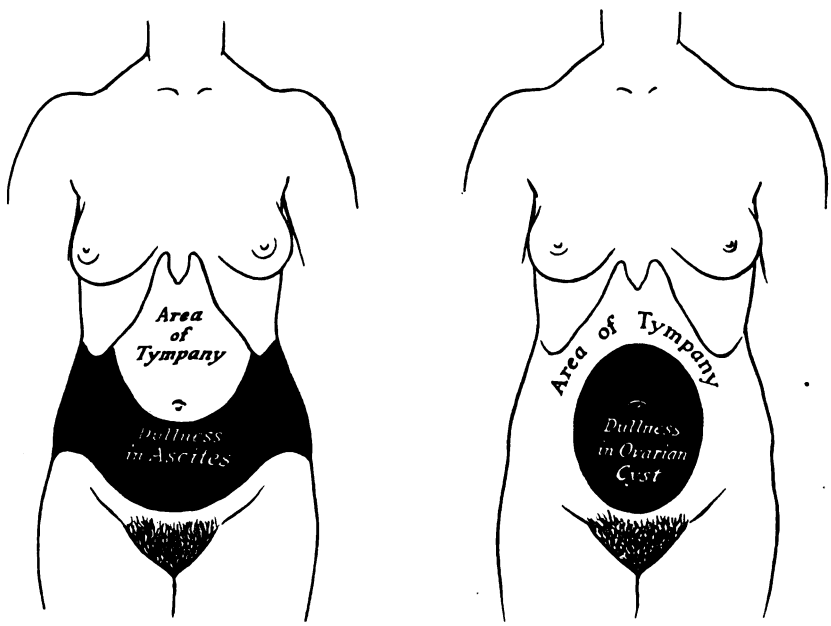

FIG. 180.—AREAS OF DULLNESS AND TYMPANY RESPECTIVELY IN ASCITES AND OVARIAN CYST.

II. *Palpation.*—The warm hands should be laid flat upon the abdomen (Fig. 179), deeper pressure being made gradually. For renal tumors bimanual palpation is necessary (Fig. 160). Ballottement is useful for deep tumors.

Palpation reveals:

(*a*) The respiratory mobility of the tumor. Tumors of the stomach, liver, and gallbladder and kidneys move up and down with respiration unless they are fixed by adhesions. Tumors of the ovary and uterus do not move with respiration.

(*b*) The passive mobility of the tumor. Tumors of the large intestine and mesentery and long pedunculated ovarian and uterine

tumors have an almost unlimited range of mobility. The same is true for a movable spleen, but is rarely so for a tumor of the pylorus, kidney, or suprarenals. Retroperitoneal tumors arising from the pancras and glands have but little passive mobility. This also holds for inflammatory tumors like encapsulated exudates (Fig. 192).

(*c*) The presence or absence of fluctuation.

(*d*) The consistency, size, and nature of the surface and edges of the tumor, and whether there is pulsation, genuine or transmitted.

III. *Percussion.*—This will aid in distinguishing ascites from an ovarian cyst, the former causing dullness in the flanks and tympany in the center, and the latter the opposite (Fig. 180).

Percussion will also help in distinguishing tumors with fluid or solid contents, and lying close to the abdominal wall, from those behind coils of intestine or the stomach.

IV. *Auscultation.*—This is of little value except in the differentiation of a pregnant uterus from other abdominal tumors or in the diagnosis of aneurysm.

Inflation of Stomach or Colon.—This is of great aid in the diagnosis of tumors of the stomach, large intestine, and of retroperitoneal tumors (kidney, pancreas, adrenals, lymph-nodes, etc.).

The results obtained from this method of diagnosis are described below.

TUMORS OF THE STOMACH.

These are almost always due to a carcinoma, rarely to a sarcoma.[1]

The only forms of cancer of the stomach which can be felt through the abdominal wall are those which are situated at the pylorus alone or which involve the entire anterior wall as a massive infiltration.

Tumors of the stomach, especially those of the pylorus, show distinct respiratory, and a marked range of passive mobility (Fig. 181)

If the stomach is at a lower level, as the result of a gastroptosis or of a dilatation, there is but little respiratory mobility in the tumor. The same is true if adhesions exist.

Minkowski has shown that if one grasps a gastric tumor during inspiration and holds it, the expiratory upward movement can be prevented.

Pyloric tumors move to the right and downward when the stomach is inflated, those of the anterior wall move downward, and both varieties become less accessible to palpation when the stomach is inflated.

[1] The subject of diagnosis of gastric carcinoma is taken up in detail on page 335.

Tumors of the stomach are most frequently felt in the epigastric and umbilical regions, but may be situated at a lower level if a gastroptosis or dilatation (Fig. 181) is present. This can be elicited by inflation. One can often cause peristaltic waves to pass across the stomach toward the tumor, if dilatation exists, by gently tapping upon the organ.

Gastric tumors are usually hard and smooth, but may be quite nodular. They are tender on palpation.

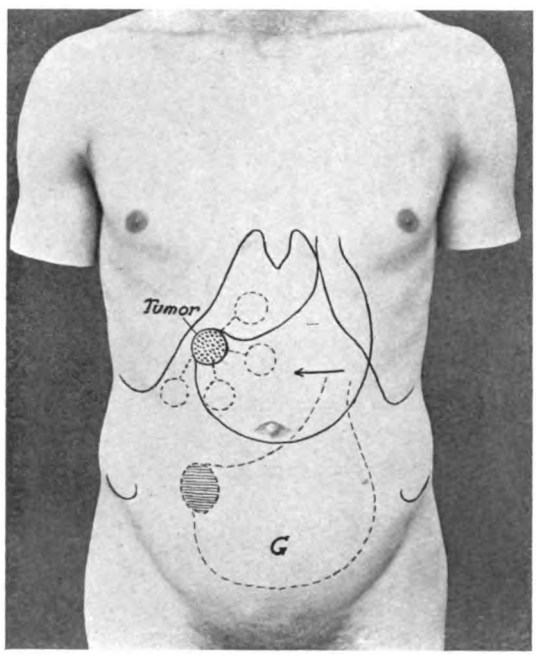

FIG. 181.—MOBILITY OF PYLORIC TUMORS.

The dotted circles of the upper figure represent the range of mobility of some pyloric tumors resulting from carcinoma of the stomach. The black arrow shows the direction of peristaltic waves. *G*, Location of stomach and of pyloric tumors in latter right iliac region, in cases of gastroptosis, or of extreme dilatation of the stomach.

The diagnosis of whether such a tumor is a gastric carcinoma can be made if the accompanying symptoms referred to on page 335 are present, and by excluding the following forms of tumors.

Differential Diagnosis.—1. *Pancreatic Growths.*—The normal pancreas in elderly persons with thin, relaxed abdominal walls often feels like a gastric cancer.

Neoplasms of the head of the pancreas may also simulate carcinoma of the stomach. If the stomach and colon are both inflated, the pancreatic enlargements disappear (Fig. 182).

In pancreatic disease there is often an accompanying glycosuria, and stools containing free fat and undigested meat particles (see page 299). There may also be ascites, icterus, and hepatic enlargement (Figs. 186 and 187).

2. *Tumors of the Transverse Colon and Duodenum.*—Those of the former, cause obstruction symptoms. They disappear when the stomach is inflated, and become more prominent when the colon is inflated. In

addition, there is an absence of pathologic change in the gastric contents analysis.

Tumors of the duodenum cannot be distinguished from those of the stomach, but while hydrochloric acid is absent in the vomitus of the latter, it is usually present in the vomitus of tumors of the duodenum.

3. *Carcinoma of the Gallbladder.*—Icterus is usually present. There is no lateral mobility and no respiratory fixation as described above. There are rarely any dyspeptic disturbances or signs of a dilated stomach. A history of previous gallstone attacks is usual.

4. *Tumors of the Left Lobe of the Liver.*—These become very prominent beneath the abdominal wall when the stomach is inflated (see page 297).

5. *Perigastritic Thickening Around an Old Ulcer of the Stomach.*—The induration may be so marked as to simulate a carcinoma. The course of the case is much slower, there is a history of ulcer, and the stomach contents will show hyperchlorhydria. It usually occurs in younger individuals, as compared with carcinoma, which is most frequent in the aged.

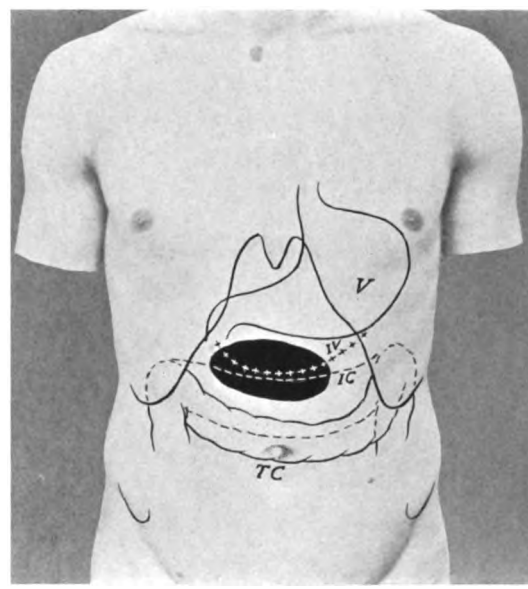

FIG. 182.—LOCATION OF PANCREATIC CYSTS BEFORE AND AFTER INFLATION OF COLON AND STOMACH.

V, Stomach before inflation; *TC*, location of transverse colon before inflation. The black oval area represents the pancreatic tumor, which may be quite prominent before inflation of the stomach and colon, but disappears when the latter procedure is used. The white dotted lines, *IV* and *IC*, represent the locations of the inflated stomach and colon respectively, overlapping the pancreatic tumor.

TUMORS OF THE LIVER.

I. CORSET LIVER.

Through the pressure of a corset, a lobule of the liver may become almost completely separated from the remainder of the organ and simulate other tumors of the upper abdomen. It occurs most frequently

in the right lobe. A deep groove or furrow divides the liver proper from the supernumerary lobe which contains, instead of liver tissue, only blood-vessels and bile-ducts. The majority of these tumors cause no symptoms, but they become so far separated as to seem like a neoplasm having no connection with the liver. It may drag the gallbladder with it, just as does an elongated Riedel lobe (Fig. 162). As a result of this, the gallbladder may be found at the level of the umbilicus or even lower.

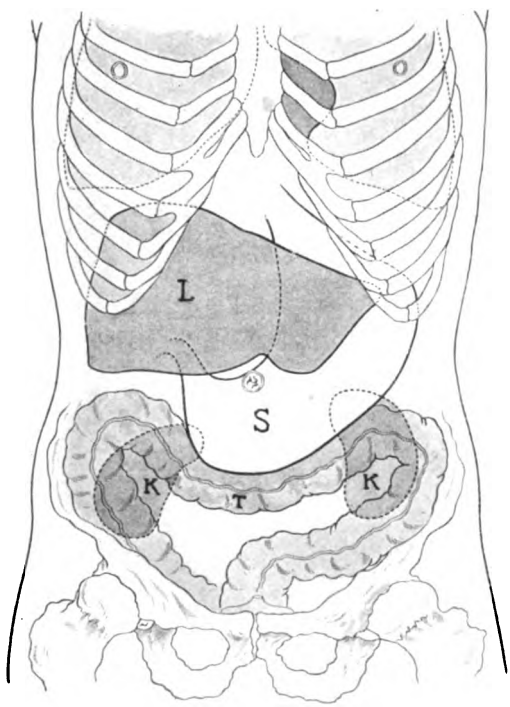

FIG. 183.—FRONT VIEW OF A CASE OF GENERAL ENTEROPTOSIS (R. C. Coffey).

L, Liver outline on surface, showing marked descent; S, stomach; note the fact that the lesser curvature lies at the level of the umbilicus, and the greater curvature midway between the umbilicus and symphysis; K, right and left kidneys, showing marked downward displacement; T, transverse colon, also markedly prolapsed.

If the tumor is freely movable, or if the bridge connecting it with the liver is very thin, there may be great difficulty in diagnosis. The same is true for those cases in which a coil of intestine lies between it and the liver.

The diagnosis, in those cases in which the groove between the accessory lobe and the liver is not deep, is easy, if one can feel this transverse depression and observe that the tumor moves with the liver during respiration.

Differential Diagnosis.—*Floating Kidney.*—This can be better felt from the lumbar region, while the corset lobe is most distinct anteriorly. If the colon is inflated, it lies in front of the kidney (Fig. 191).

A movable kidney can be replaced upward and backward toward its normal position, and, on the other hand, can be pushed further

down than the corset liver. If the patient is laid upon the left side, one can separate the sharp lower edge of the liver from that of the kidney, which is more rounded or blunt. If enteroptosis exists, the diagnosis may become very difficult, since movable kidney may be present at the same time.

Renal Tumors.—These often have the shape of the normal kidney and lie behind the inflated colon. The dullness over the renal tumor is not continuous with that of the liver, as in a corset lobe, but tympany due to the overlying intestines exists. The lower edge of the renal tumor is not as sharp and lacks the notches often present in a corset lobe.

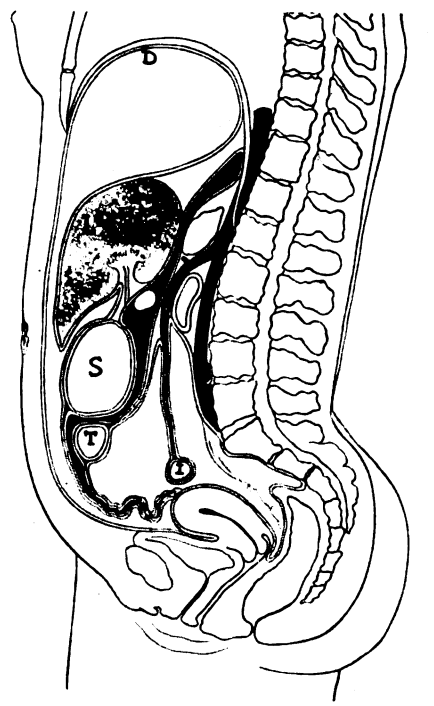

FIG. 184.—SAGITTAL SECTION IN MEDIAN LINE OF A CASE OF GENERAL ENTEROPTOSIS (R. C. Coffey).

D, Under surface of diaphragm; the blank space between D and L (liver) is the space formerly occupied by the liver before its descent; S, prolapsed stomach; T, prolapsed transverse colon; I, prolapsed coil of ileum; note elongation of the mesentery as the result of the prolapse.

II. FLOATING LIVER (HEPATOPTOSIS).

A liver which has descended in the abdominal cavity may simulate a tumor of the right side. It may sink to the pelvis. It can usually be replaced into its normal position. On palpation, one can usually distinguish the sharp lower edge and the notch between the right and left lobes (Fig. 183). It is ten times as frequent in women as in men, especially in those with flabby, relaxed abdominal walls. The consistency of the tumor is that of the normal liver. The normal liver dullness is replaced by tympany, but reappears when the organ is put into its normal position. It may cause at times attacks of pain like biliary colic, radiating to the right shoulder. Usually it causes a feeling of fullness in the abdomen and digestive disturbances. The diagnosis may be very difficult if ascites coexists. It would be necessary to perform paracentesis first.

Differential Diagnosis.—*Floating or Movable Kidney.*—The hepa-

tic tumor is larger, more superficial, has the characteristic sharp lower edge, is notched, and there is an absence of normal liver dullness until the tumor is replaced.

The renal tumor has the outline of the normal kidney and lies behind the colon, when this is inflated (Fig. 191).

Tumors of the Liver Itself.—In carcinoma the surface is irregular and often umbilicated, and the liver, if enlarged much downward, also extends upward to its normal level at the sixth rib. The same is true for hydatid cysts.

Tumors and Cysts of the Omentum.—These, though movable, cannot be replaced to the same extent from above downward as a floating liver, and are separated by tympany (intestines) from the dullness of the normally placed liver.

III. Echinococcus Cysts of the Liver.

This condition usually occurs in a unilocular form and is most often in the right lobe, causing a localized bulging on the surface and giving rise to a marked tumor. The liver is enlarged, and if the cyst is near the upper surface, it pushes the diaphragm upward. The normal liver dullness is increased upward in a circumscribed manner, as in a pleural effusion, but differs from it by having respiratory movement.

When the cyst lies near the lower border of the right lobe it causes a tumor, resembling a distended gallbladder or renal enlargement. When the cyst protrudes from the anterior surface of either the right or left lobe, it causes a marked localized bulging. These latter forms rarely give a sense of fluctuation, and the peculiar hydatid thrill, so pathognomonic when found, is an inconstant sign. The presence of echinococcus can be suspected from the presence of a localized tumor with absence of constitutional signs, such as fever, unless, as rarely occurs, suppuration has taken place.

The diagnosis can be positively made only if the characteristic scolices or hooklets are found in the clear, watery contents. Exploratory puncture is dangerous and should be replaced by a laparotomy for diagnostic purposes. An *x*-ray is of great aid in confirming a diagnosis of echinococcus if calcification has occurred.

Differential Diagnosis.—1. Echinococcus cysts of the anterior surface must be differentiated from the following:

(*a*) *Cystic Disease of the Liver.*—The elevations are usually small and multiple. If large, they can be differentiated from echinococcus cysts by exploration only.

(*b*) *Carcinoma.*—Here there is cachexia, umbilication of the tumors (Fig. 185), and the tumors are harder and multiple.

(*c*) *Abscess of the Liver.*—If no fever is present the differentiation may be very difficult, but in abscess the tumor is not so hard or tense. Usually, however, fever and other septic symptoms are present in hepatic abscess, and there is a history of dysentery to be obtained. If a hydatid cyst suppurates the diagnosis from primary liver abscess is almost impossible before operation.

2. When the hydatid cyst projects from the lower border.

(*a*) *From a Dilated Gallbladder.*—This tumor of the gallbladder is pear-shaped, it can only be separated from the edge of the liver with difficulty and is also more movable than an echinococcus cyst.

(*b*) *Permanent or Intermittent Hydronephrosis.*—In the intermittent form there is a history of alternating disappearance and presence of the tumor, the former associated with polyuria. A permanent hydronephrosis will have more or less the form of the normal kidney, project more in the lumbar region, and lie behind the inflated colon (Fig. 191). If the patient is laid upon the left side the echinococcus cyst is less prominent.

3. When the echinococcus cyst is on the upper border of the liver.

(*a*) *From Pleuritic Effusion.*—The diagnosis can only be made by finding the hooklets in the fluid removed by exploratory puncture. An upper border of dullness, not unlike that found in subphrenic abscess, occurs in the case of an echinococcus cyst of the upper surface of the liver; *i. e.*, the upper border is convex upward either in front or behind (Fig. 163), while in pleural effusion it is almost horizontal (Fig. 140).

(*b*) *From Hydatids of the Lung and Pleura.*—A differentiation is almost impossible if situated on the right side. Hemoptysis and cough are more frequent in hydatids of the lung.

(*c*) *From Subphrenic Abscess.*—Here the history of a primary cause of suppuration, *e. g.*, in the appendix, and the presence of fever, etc., are of aid. If the abscess contains gas there is tympany instead of dullness, and the *x*-ray will not show a shadow, as in hydatid. Exploration will reveal the absence of hooklets and the presence of pus.

IV. Cystic Disease of the Liver.

This condition, resembling congenital cystic disease of the kidneys (Fig. 192), is often present with the latter condition, and should be suspected if the liver and both kidneys are enlarged in a patient having uremic symptoms. The surface of the liver is nodular and some of the many cysts may be large enough to simulate hydatids. In such a

case a differentiation is impossible without a microscopic examination of the wall of the cyst and its contents.

V. Syphilis of the Liver.

There are three forms of syphilis which are of interest from a surgical standpoint.

1. Cases of large gummata resembling neoplasms.

2. Cases of division of the right or left lobes or both into multiple lobules as the result of cicatrization following gummatous infiltration.

3. Cases with irregular fever and gumma formation resembling hepatic suppuration.

4. Cases resembling gallstones.

The first point in the case of gummatous enlargements is to identify the tumor as belonging to the liver, then to ascertain the presence of syphilis elsewhere or a previous history of the disease, and finally to observe the disappearance of the tumor under antisyphilitic treatment. If a gumma softens and fever is present, one cannot differentiate it from a hepatic abscess, in the absence of a syphilitic history.

The chief condition from which a lobulated luetic liver must be distinguished is floating kidney. The latter has a much greater range of mobility, has the form of the normal kidney, and can be best felt by bimanual palpation (Fig. 160). Inflation of the colon shows the tumor to lie behind the distended large intestine.

Rarely obstructive jaundice, with attacks of biliary colic, may follow the pressure of a gumma, or the traction of syphilitic cicatrices on the portal fissure (Rolleston, Billings).

VI. Malignant Neoplasms of the Liver.

Sarcoma and carcinoma both occur as primary and secondary growths in the liver. The primary are quite rare and cannot be distinguished clinically from the secondary forms. The stomach (Fig. 204), colon, gallbladder, and breast (Fig. 152) are the most frequent seats of the primary growths, in cases having secondary cancer of the liver. Sarcomata are most often secondary to primary melanosarcomata of the uveal tract and of the skin.

The diagnosis of malignant disease may be made from the onset of cachexia, the rapid enlargement of the liver, and the palpable, hard, umbilicated tumors (Fig. 185) of the liver edge. In a patient who has a primary growth elsewhere, the diagnosis is positive; but in one in whom no such focus can be found, the diagnosis is a very probable one.

At times, especially in the case of primary sarcomata, one lobe may

FIG. 185.—METASTATIC CARCINOMA OF THE LIVER SECONDARY TO THE PRIMARY CARCINOMA OF THE STOMACH SHOWN IN FIG. 204.

Note the umbilicated centers of each nodule. This illustration assists in forming a conception of the innumerable metastases from a comparatively insignificant primary carcinoma.

be enormously enlarged and its surface smooth and firm. From their location, such tumors can be diagnosed as being hepatic in origin, and inflation of the stomach will render them more prominent.

In addition to the above symptoms, there are marked jaundice (even cholemia with hemorrhages into the skin and from the mucous membranes), ascites, evidences of metastases in the peritoneum, and often febrile manifestations.

Differential Diagnosis.—1. *Cirrhosis of the Liver.*—The nodulation of the surface is never as marked and umbilicated as in carcinoma. If ascites is present, as is the case in both affections, the fluid should be removed before palpating the liver. The jaundice is not as deep in cirrhosis. Rapid enlargement of the liver and marked cachexia speak for malignancy. A search for a primary focus of cancer or sarcoma should always be made. The spleen is usually enlarged in cirrhosis, but is rarely so in malignant disease.

2. *Syphilis.*—Gummata are usually not as hard as carcinomatous nodules, there is a history of syphilis, and the constitutional disturbance is slight. The course is much more chronic.

TUMORS OF THE GALLBLADDER.

The two chief affections which might be mistaken for other abdominal tumors are hydrops and primary malignant disease of the gallbladder.

Hydrops.—Distention of the gallbladder occurs as the result of blocking of the cystic duct, followed by the accumulation of secretions, and the formation of a tumor which varies greatly in size. It may be quite movable or fixed by adhesions. There are three degrees of distention:

(*a*) Those in which the tumor is of relatively small size.

(*b*) Cystic tumors of great size extending to the left of the median line.

(*c*) Cystic tumors filling the greater part of the right side of the abdomen (Fig. 162).

The diagnosis in the first class may be made from the fact that there are but few subjective symptoms, although a history of one or more attacks of biliary colic is often obtainable. Its outline can often be seen through a thin abdominal wall. It can be felt to be attached to the liver above, is in close contact with the anterior abdominal wall, and has a wide range of mobility.

Palpation and percussion are often very unsatisfactory, for the

reasons that unless adherent the tumor is so movable that it cannot be readily grasped, and, again, instead of dullness there is tympany from the underlying intestines. If the abdominal wall is quite relaxed, its lower rounded border may be distinctly felt as a tense elastic body, especially if one hand be placed posteriorly and the other in front, as in palpating the kidney (Fig. 160).

Inflation of the stomach makes the tumor more prominent and pushes it to the right, while inflation of the colon pushes it upward, unless, as rarely occurs, the colon is adherent between the tumor and the abdominal wall. Exploratory puncture is dangerous.

The larger forms of cystic tumors of the gallbladder which fill the greater part of the right half of the abdomen are infrequent, and can be recognized from the history, from their great mobility, smooth surface, their pyriform or cucumber shape (Alban-Doran), and the fact that they have their pedicle at the liver, instead of in the pelvis as ovarian cysts do. If adhesions exist there may be great difficulty in diagnosis. There is often distinct fluctuation in these large gallbladder retention-cysts.

Differential Diagnosis.—1. *Floating Kidney.*—This always retains the characteristic outline of the kidney. It can be replaced toward the renal region. Inflation of the colon causes it to disappear while the gallbladder tumor is pushed upward.

2. *Growths in the Stomach and Intestines.*—These can be distinguished by the difference in the symptoms and by the results of inflation of the colon and stomach.

3. *Echinococcus Cysts or Malignant Tumors Projecting from the Lower Edge of the Liver.*—These are much more irregular in outline, harder, and not movable except with respiration.

4. *Distention of the Gallbladder Following Cancers of the Pancreas.*—In this, it may distend to a quite marked size, but there are an accompanying cachexia, ascites, and deep jaundice (Fig. 186). Exploratory incision shows the head of the pancreas infiltrated and enlarged.

Malignant Disease of the Gallbladder.

This frequently follows cholelithiasis, and should be suspected if a hard mass is found in the right hypochondriac region following a history of gallstones in an elderly patient with persistent jaundice. The tumor is usually nodulated, rarely smooth, and is very hard in consistency. This [illegible] the nodular surface, and the rapid appearance [illegible] icterus and ascites, serve to distinguish it from

cholelithiasis; but in the latter the organ may be indurated so that a diagnosis is often not made until the abdomen is opened. The pains in cancer are not sharp and colicky, but of a dull character. If fever and colicky pains appear, they indicate an infection of the carcinomatous gallbladder. The course is a very chronic one.

PANCREATIC TUMORS.

Inflammatory tumors in the epigastric and umbilical regions due to peripancreatic suppuration following an attack of acute pancreatitis were referred to on page 270.

Other tumors due to pancreatic disease may be divided into three classes.

(*a*) Those due to chronic pancreatitis.

(*b*) Cysts.

(*c*) Neoplasms.

CHRONIC PANCREATITIS.

Although the majority of these cases can be recognized only at operation or autopsy, it is important to know that marked induration can follow chronic pancreatitis. At times it is possible to recognize the tumor through the intact abdominal wall during life, and in one case of the author's such a tumor was mistaken for a carcinoma of the head of the pancreas. The diagnosis of chronic pancreatitis can rarely be made. Even when the abdominal cavity is opened, as in the case just mentioned, the induration is difficult to distinguish from that of carcinoma, and the diagnosis can only be made from the subsequent clinical course. The tumor is palpable and is located in the epigastrium to the right of the middle line. In the cases observed by Riedel and in my own case the tumor had so great a range of respiratory and passive mobility as to be mistaken for a gallbladder full of calculi. If, in addition to such a rarely palpable induration, jaundice, fatty stool, glycosuria, and emaciation are present, chronic pancreatitis can be diagnosed. There is often a history of biliary colic, of gastroduodenal catarrh, or of gastric duodenal ulcer.

Differential Diagnosis.—1. *Gallstones in the Common Duct.*—In this condition there is the history of frequent attacks of biliary colic at first without jaundice, chills and fever, but later accompanied by these symptoms. The absence of tumors speaks also for gallstones in the common duct.

2. *Cancer of Head of Pancreas.*—The jaundice is deep and constant,

the liver and gallbladder are greatly enlarged, and ascites is present. Emaciation is also more rapid. In some cases only exploratory incision will aid in making a diagnosis. As mentioned above, palpation of the tumor will, at times, give misleading information, since the induration in choronic pancreatitis may be as great as in carcinoma. More

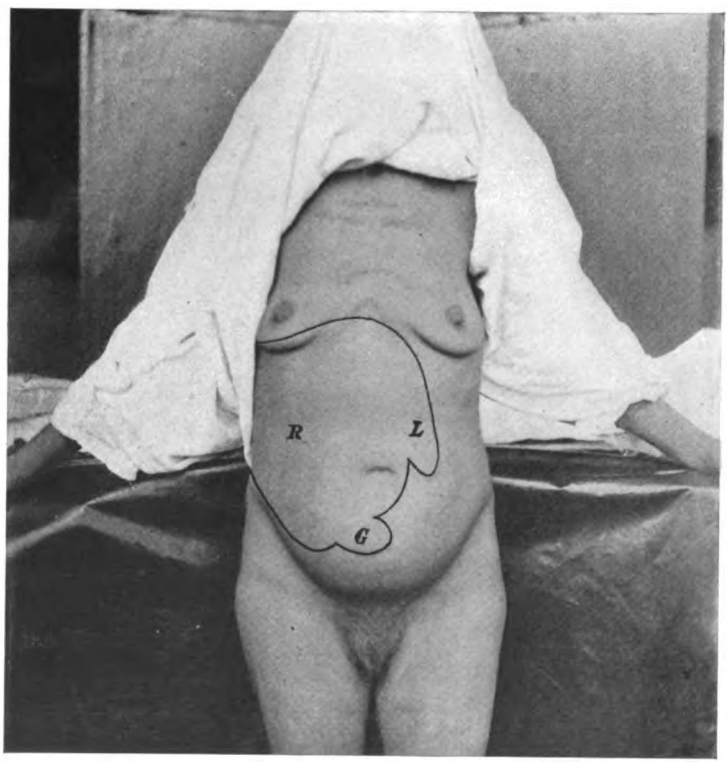

FIG. 186.—FRONT VIEW OF CASE OF CARCINOMA OF THE HEAD OF THE PANCREAS.

The area of liver dullness is outlined in black. *R*, Right lobe of liver; *L*, left lobe of liver. The notch between the two lobes could be distinctly palpated to the left of the median line at the level of the umbilicus. *G*, Enormously distended gallbladder easily palpable through the abdominal wall. Enormous size of the liver was due to passive hyperemia and to secondary deposits in the liver parenchyma. The yellowish color of the skin was due to pressure on the common duct.

reliance is to be placed on the presence of deep icterus and ascites, which speak for malignancy.

3. *Gallstones in the Gallbladder.*—There is tenderness over the gallbladder, (Figs. 167 and 173) and the history of attacks of biliary colic. The tumor is seldom as hard as that of a chronic indurative pancreatitis and does not disappear when the stomach and colon are inflated, as the pancreatic induration does.

Pancreatic Cysts.

These cause a bulging in the median line of the epigastric region (Fig. 182) or between the middle line and left costal arch. In sixteen cases Koerte found the tumor below the navel, and in eleven cases Koerte and Neumann,[1] his assistant, have observed right-sided pancreatic cysts lying near the kidney (Fig. 191) and simulating renal tumors.

There is an area of dullness over the tumor. The epigastric bulging is smooth, tense and rounded, and may vary in size from time to time.

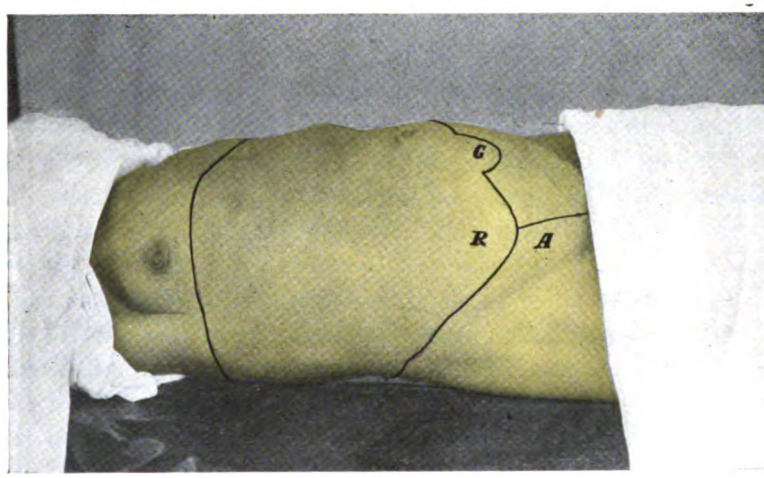

Fig. 187.—Side View of Case of Carcinoma of the Head of the Pancreas.

Yellow tint of flesh due to obstruction of common duct, as it passes through head of pancreas to reach the duodenum. *G*, Enormously distended gallbladder which could be distinctly felt through the abdominal wall. Its contents were cystic on account of the long-standing obstruction of the common duct. *R*, Lower border of right lobe of liver, which is enormously enlarged on account of secondary deposits. The upper level of liver dullness is shown just below the level of the nipple. *A*, Area of dullness due to free fluid in peritoneal cavity due to pressure upon portal vein.

Such tumors have no respiratory or passive mobility, and inflation of the stomach and colon causes them to disappear, the former lying above and the latter below it (Fig. 182), unless one of the following rare positions of the cyst occurs:

(*a*) The cyst lies above the stomach and pushes the latter downward.

(*b*) It may be behind the transverse colon.

(*c*) It may lie below the transverse colon.

(*d*) It may lie behind the ascending colon (Fig. 191).

In these positions the cyst is often quite mobile.

[1] "Deutsche Zeitschrift f. Chirurgie," Bd. lxxiv.

The diagnosis may be made from the above special characteristics of the tumor, from the mode of onset, the accompanying symptoms, and the analysis of its contents when obtained at operation.

The modes of onset are chiefly three:

1. Gradual.—With loss of weight, symptoms of indigestion, and colicky pains like those of gallstones.

2. Sudden.—After blows on the upper abdomen.

3. No preceding trauma or symptoms mentioned under 1.

After the cyst begins to develop the patient may either have severe pain and vomiting or show no symptoms other than the gradually increasing distention of the abdomen. Jaundice, hematemesis, and diarrhea are occasionally present. In the urine sugar is often found; in the feces, an excess of fat and undigested meat may be found. The fluid should never be obtained for analysis by exploratory puncture, but only during a laparotomy. The most important diagnostic feature is that the fluid in a pancreatic cyst digests fibrin and albumin.

Differential Diagnosis.—*Echinococcus Cysts of the Liver.*—The tumor in these is continuous with the hepatic dullness, while in pancreatic cysts there is an area of resonance between the tumor and the liver, which is increased when the stomach is inflated. When the pancreatic cyst lies above the stomach these signs are of no value, but this form of pancreatic cyst is much more movable than is an echinococcus cyst.

Retention-cysts of the Gallbladder.—These were discussed on page 297. The chief points are their greater mobility and the continuation of dullness from the liver to the tumor.

Renal Cystic Tumors.—If, as shown in Fig. 191, the tumor lies behind the colon, a differentiation is impossible, and even after operation the fluid may fail to show any characteristic ferments in such cases. In general, however, renal tumors are accompanied by colicky pains along the ureter, by urinary changes, and give rise to more bulging of the ileocostal space. In the most frequent location of pancreatic cysts (Fig. 182) the colon when inflated lies below the tumor and not in front of it.

Ovarian Cysts.—When these have a long pedicle they may simulate a pancreatic cyst. The presence of both ovaries in the pelvis will exclude ovarian tumor.

Bimanual pelvic examination in the Trendelenburg position will show that the tumor has no relation to the ovaries. The history will show that the tumor first appeared in the epigastrium. Upon inflation of the colon, the ovarian lies below and the pancreatic cyst above it, except in those rare cases where these latter lie below the colon.

Mesenteric Cysts.—The history is of great value. Appearance of the tumor after an injury or following colicky pains speaks for a pancreatic cyst, as do fatty stools, glycosuria, undigested meat fibers in the feces, and emaciation. The mesenteric cyst is more movable, lies below the umbilicus, and when the large bowel is inflated the transverse colon lies across the tumor. Only when a pancreatic cyst has developed between the layers of the transverse mesocolon is differentiation impossible.

Neoplasms of the Pancreas.

Primary carcinoma of the head of the pancreas is the most frequent form of new-growth. The diagnosis may be made from the following symptoms:

1. Severe pain in the epigastrium, radiating through to the back. It is either continuous (a dull ache) or intermittent (agonizing).
2. Jaundice. This is present except in cancer of the body or tail.
3. Distention of the gallbladder and enlargement of the liver (Fig. 186).
4. Ascites.
5. Early cachexia.
6. A palpable tumor in the epigastrium which becomes less noticeable when the stomach is inflated.
7. Free fat and undigested meat fibers in large quantities in the feces.
8. Albuminuria—rarely glycosuria.

Differential Diagnosis.—1. *Gallstones in the Common Duct.*—The jaundice is more sudden in its appearance and often accompanied by irregular chills and fever. There is often a history of frequent previous attacks of biliary colic without jaundice and the gallbladder itself is tender to the touch. On inflating the stomach and colon the tumor will not disappear, as pancreatic tumors do. Ascites and cachexia speak for malignant disease of the pancreas.

2. *Chronic Pancreatitis.*—In the absence of ascites and jaundice, it is impossible to differentiate this from carcinoma except by the fact that in the latter there is early and much more marked cachexia. The induration in chronic pancreatitis often feels as hard at operation as in cancer of the head of the pancreas. In the latter, however, the condition becomes progressively worse, while in chronic pancreatitis it improves as soon as stones in the common duct are removed.

3. *Carcinoma of the Pylorus.*—The tumor is much more mobile than in cancer of the pancreas, there is a predominance of gastric symptoms with evidences of dilatation, and changes in the gastric

juice. A cancer of the pylorus will not be accompanied by jaundice, ascites, and changes in the stool, and the tumor will move to the right when the stomach is inflated instead of becoming concealed, as does one of the pancreas.

4. *Carcinoma of the Colon.*—This may be accompanied by ascites, but there are no changes in the stools, or jaundice, as in cancer of the pancreas. The tumor is more movable than that of the pancreas and does not disappear when the colon is inflated. There are often distinct stenosis symptoms.

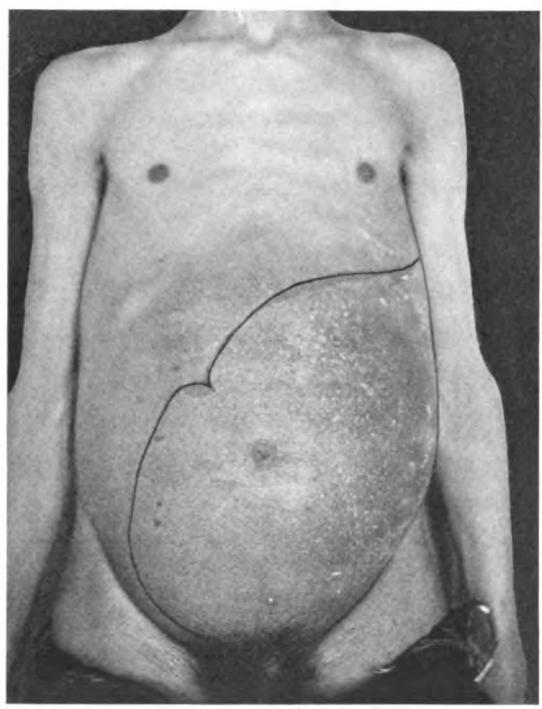

FIG. 188.—ENLARGEMENT OF ABDOMEN AS THE RESULT OF A LEUKEMIC HYPERTROPHY OF THE SPLEEN.

The dark color of the skin of the abdomen is due to the repeated application of the *x*-ray.

TUMORS OF THE SPLEEN.

The normal spleen cannot be palpated except in very thin and relaxed patients and then only indistinctly. The conditions which most often give rise to splenic tumors are:

1. Floating spleen.
2. Splenic enlargements due to leukemia, pseudoleukemia, malaria, or acute splenitis.
3. Neoplasms, including echinococcus cysts.

Floating or Wandering Spleen.—This condition is frequently present as a part of a general enteroptosis (Fig. 183), or is often associated with left-sided floating kidney. A tumor may be found which has caused practically no symptoms except a slight dragging sensation. Quite rarely the tumor may give rise to acute symptoms, such as pain, vomiting, muscular rigidity, and tenderness, due to strangulation or twisting of its pedicle.

A wandering spleen is most often found in the left iliac region,

resting in the iliac fossa. Less often has it been found in the right iliac fossa and pelvis. In the latter situation it may cause obstruction.

A diagnosis is made by the palpation of the characteristic notches (Fig. 189) along its anterior border, its smooth surface, and the absence of the spleen in its normal place. It can be distinguished from floating kidney by the fact that the latter can be replaced to the renal while the spleen disappears behind the costal arch unless held by adhesion. A floating kidney lies behind the colon, has the outline and rounded lower pole of the normal kidney, and in addition is much less movable than a floating spleen.

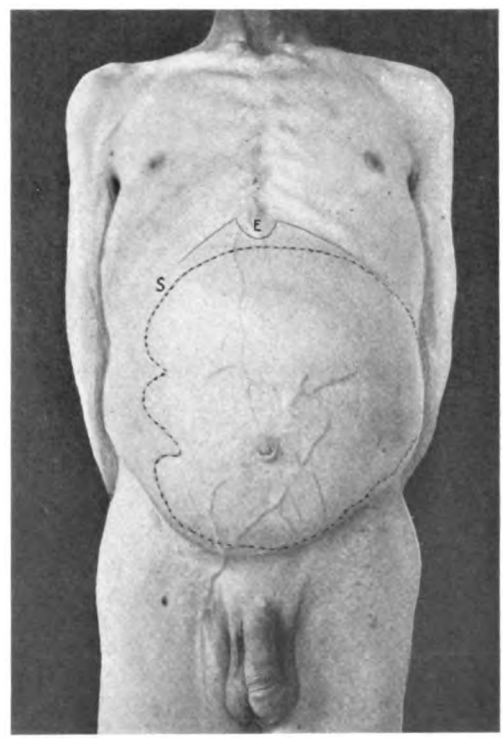

FIG. 189.—ANTERIOR VIEW OF THE CASE OF SARCOMA OF THE SPLEEN SHOWN IN FIG. 190.

The outlines of the spleen have been marked with a dotted line. Observe the notches on the right margin of the tumor, characteristic of splenic tumors. E, Ensiform process in costal arch. Observe the formation of a well-marked caput medusæ.

Enlargements of the Spleen.—These are described at length in text-books of medicine. The writer has seen a number of cases in which such spleens, enlarged as the result of general diseases, such as leukemia (Fig. 188), pernicious anemia, pseudoleukemia, chronic malaria, and syphilis, have been mistaken for neoplasms of the spleen.

In every case of splenic enlargement of long standing one must remember the above causes and examine the blood or search for a cause elsewhere than in the spleen.

Another cause of enlarged spleen is that found in splenomegaly or Banti's disease, which may or may not be associated with anemia. For full descriptions of the various forms of this disease the reader is referred to the various treatises on internal medicine.

There are certain physical signs by which all of these enlargements may be recognized as splenic, viz.:

1. They retain the general outline of the spleen.

2. They have its notched anterior border.

3. They lie in front of the inflated colon and not behind it, as do renal tumors.

4. They have respiratory mobility.

(*a*) **Echinococcus of the Spleen.**—This is very rare and causes an enlargement of the spleen which can seldom be diagnosed before opera-

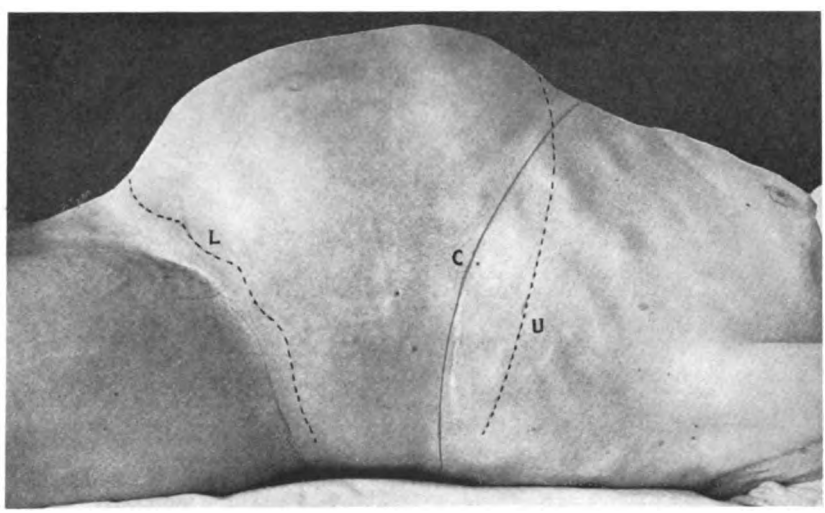

FIG. 190.—LATERAL VIEW OF ABDOMEN OF SAME PATIENT AS SHOWN IN FIG. 189, WITH SARCOMA OF THE SPLEEN.

L, Lower palpable border of tumor; U, upper border of tumor as outlined by percussion; C, costal arch.

tion. Occasionally fluctuation may be felt and the tumor recognized as one of the spleen.

Sarcoma of the Spleen.—Both primary sarcoma and carcinoma of the spleen occur, but of the two, the former is the more frequent. The tumor occupies the left half of the abdomen, extending downward from beneath the left costal arch (Fig. 189). It lies quite superficially, has a nodulated, hard surface, and often retains the characteristic notches of the anterior border of the spleen (Fig. 189). Its rapidity of growth, its hardness, and the accompanying cachexia are diagnostic of the malignant character of the tumor. It lies in front of the inflated colon and does not give rise to hematuria, as does a malignant renal tumor. It also causes early peritoneal metastases which can be felt as separate tumors.

TUMORS OF THE INTESTINES.

There are three places in the abdominal cavity where tumors which have their origin in the small and large intestine may be felt. These are, in the order of their frequency:

1. Rectum.
2. Sigmoid flexure.
3. Cecum and ascending colon.

The rarer seats of a tumor are the appendix, duodenum, ileum, and jejunum.

Unfortunately for the purposes of diagnosis, a palpable tumor is a rather late sign of malignant disease of the intestine, so that it should be made from the other signs and methods referred to on page 308. Those of the rectum are discussed on page 359. At this point the diagnostic points of intestinal tumors *per se* will be discussed whether due to neoplasms or inflammatory conditions.

1. **Inflammatory Tumors.**—These are the result of one of two affections, viz.: tuberculosis and actinomycosis. They are almost always found in the cecum. Quite rarely tumor-like inflammatory masses appear around the sigmoid as the result of perforation of the appendices epiploicæ.

(*a*) *Ileocecal Tuberculosis.*—In this a vertical, sausage-shaped, hard tumor is found in the right iliac region whose tuberculous nature is often not suspected. The diagnosis frequently made before operation is that of a carcinoma. The tumor is quite fixed and more sensitive to pressure than a carcinoma, and is not quite as hard. There are also periodic attacks of severe pains, as the result of an enterostenosis, and alternating diarrhea and constipation is a quite common symptom. Rarely symptoms of acute intestinal obstruction arise. The disease occurs, as a rule, at an earlier age than carcinoma; there is often fever and it is not accompanied by as much emaciation as is the malignant process. The finding of blood in small quantities is more characteristic of carcinoma than of tuberculosis.

(*b*) *Ileocecal Actinomycosis.*—This localization of the ray-fungus gives rise to a tumor-like mass greatly resembling that of ileocecal tuberculosis. The mass is, however, more commonly attached to the abdominal wall, which is indurated. In the absence of a history of a focus of actinomycosis elsewhere it is impossible to make a diagnosis until sinuses have formed, in the pus of which the characteristic ray-fungus is found. The tumor is as fixed, but not as tender as in tuberculosis. It is not as hard nor does the general nutrition suffer as much

as in carcinoma. The latter usually appears at a more advanced age (above forty), although there are exceptions to this. The condition is usually accompanied by some fever. The administration of potassium iodid or of copper sulphate, as recently recommended by Bevan,[1] may aid in making a differential diagnosis, since these cause an improvement if the tumor is the result of an actinomycotic infection.

2. **Neoplasms of the Intestines.**—Benign tumors are relatively rare and can seldom be diagnosed before operation. They give rise, if large, to symptoms of chronic stenosis and may cause intussusception. Of the malignant growths, sarcoma occurs in about 6 per cent. of the cases, the remainder being due to carcinoma.

The most frequent locations, according to recent statistics of Tuttle,[2] in 2432 cases, exclusive of the stomach, are as follows:

Rectum	1690 cases.
Cecum and ascending colon	283 "
Sigmoid	182 "
Transverse and descending colon	160 "
Appendix	60 "
Ileum, jejunum, and duodenum	69 "

The clinical picture varies according to the seat of the growth, but is generally that of a stenosis of the bowel.

Cancer of the Duodenum.—The symptoms are so closely allied to those of a pyloric cancer as to be indistinguishable, even when a tumor is palpable, which is usually not the case until late in the disease.

Cancer of the Remaining Small and Large Intestine except Rectum.—The diagnosis of cancer anywhere between the duodenum and rectum is usually to be made from a combination of certain general and local symptoms. The general signs are a gradually increasing anemia and cachexia for which no other cause can be found. These, when associated with intestinal disturbances in a person above forty, should always lead to the suspicion of a malignant growth. On the other hand, there are cases in which the general and local symptoms are so latent that a suspicion of malignancy is not aroused until a tumor which has all the physical characters of an intestinal one, is found during an abdominal or pelvic examination. Quite rarely cases of carcinoma of the intestine have an acute onset accompanied by fever, and a diagnosis is made only at operation, for what was thought to be an acute inflammatory condition. The chief local diagnostic points are:

1. *Symptoms of Stenosis.*—These are increased visible peristalsis

[1] "Journal American Med. Association," Nov. 11, 1905.

[2] "Medical Record," Nov. 4, 1905.

and severe, griping, colicky pains, often referred to a particular spot and relieved as soon as flatus has been passed per rectum. Often, however, the patient does not pass any gas after these colicky pains, and this is quite characteristic of stenosis.

2. *Condition of the Bowel Movements.*—Obstinate constipation is present in the majority of the cases. This condition often alternates with diarrhea, which may be a prominent early symptom, especially when accompanied by the frequent but unsuccessful desire to go to stool. The nearer the cancer is to the rectum, the more marked is this tenesmus. The feces may be ribbon-like if the stenosis is low down. The appearance of pus, blood, and mucus in the stools is of great value if a dysentery can be excluded.

3. *Tumor.*—The chief characteristic of intestinal tumors is their great mobility. This is especially true of those of the small intestine, sigmoid, and transverse colon, less so of those of the cecum or of the hepatic and splenic flexures. The latter can often be best felt by gradually pushing the hand under the costal arches.

The tumors are very hard and nodular. They may appear to be larger at one examination than at another, owing to the fact that feces collect on the proximal side, from time to time. The hardening of the tumor caused by the contraction of the hypertrophied musculature on the proximal side of the stenosis, followed by a gurgling sound due to passage of gas through the stenosis, may often be felt and heard.

Ascites may be an early symptom, accompanying a tumor of the colon.

Differential Diagnosis.—The conditions from which cancer of the small and large intestine must be differentiated depend upon their respective locations. They are as follows:

Those of duodenum and transverse colon....	Cancer of pylorus, of head of the pancreas.
	Tumors of omentum and mesentery.
Those of hepatic flexure.....	Cancer of gallbladder.
	Tumors of liver.
	Tumors of right kidney.
Those of splenic flexure.....	Tumors of spleen.
	Tumors of left kidney.
Those of cecum and appendix.....	Actinomycosis and tuberculosis of cecum.
	Post-appendiceal induration.
Those of sigmoid flexure.....	Tumors of ovary and uterus.
Those of jejunum and ileum.....	Non-malignant strictures.
Those of all parts of colon.....	From fecal impaction and gallstones.

TUMORS OF THE PERITONEUM AND MESENTERY.

Tumors of the Mesentery.—*Cystic Tumors.*—Cysts constitute the majority of mesenteric tumors; the proportion of solid to cystic tumors being as 1 to 4.

The smaller cysts have a wide range of passive mobility and rarely cause any symptoms. The larger ones cause a bulging in the umbilical region and are not as freely movable. These larger ones push the intestines aside and cause symptoms of stenosis, and in some cases even complete obstruction. They may give the sense of fluctuation. These cysts may be of dermoid, hydatid, serous, bloody, or chylous nature, and are often adherent to the neighboring viscera.

Both the smaller and larger varieties of mesenteric tumors may be suspected from the presence of a tumor in the umbilical region, from the fact that they are not adherent to the abdominal wall like omental tumors, and, lastly, their extreme mobility, except when very large.

They must be differentiated from the following:

Tumors of the omentum	These are usually adherent to the anterior abdominal wall.
Pancreatic cysts	These show some disturbance in the pancreatic secretion and lie behind the inflated stomach and colon.
Retroperitoneal cysts	These are immovable and lie behind the inflated colon.
Ovarian cysts	By elevating the pelvis, one can feel the pedicle of these tumors connected with the uterus.
Movable kidney and hydronephrosis	These retain the outline of the kidney, lie more laterally, and behind the colon.
Encapsulated tuberculous peritonitis	This may greatly resemble a mesenteric cyst as shown in Figs. 195, 196, but when the patient lies down the enlargement tends to become flatter, while the cysts retain their convex surface.

Tumors of the Omentum and Peritoneum.—These, as in the case of the mesentery, are either cystic or solid. Both become adherent quite early to the abdominal wall. Echinoccocus cysts constitute the most frequent variety of cystic tumors, while carcinoma occurs most often in the form of a solid tumor. Carcinoma may occur both as a primary and secondary growth. The latter follows cancer of the stomach and intestine. The diagnosis may be readily made if there is a history of a primary growth; but if there is none, it must be made from the presence of certain symptoms.

Lipomata are the most frequent form. They do not fluctuate,

although they may yield a sense of pseudo-fluctuation. They grow quite rapidly and cause early stenosis symptoms.

If the omentum is chiefly involved, a transverse, very hard tumor is to be felt at or above the umbilicus. It is adherent to the anterior abdominal wall and accompanied by ascites and progressive emaciation. Multiple hard tumors are to be felt, if the parietal peritoneum is also involved, and these are accompanied by ascites.

The transverse tumor may occur both in tuberculous and simple proliferative peritonitis. These, however, occur at a younger age than does carcinoma and emaciation is not nearly as marked. The nature of the fluid in cancer is usually hemorrhagic, but this may also be the case in tuberculous peritonitis.

TUMORS OF THE KIDNEY.

The best method of examination of tumors of the kidney is by palpation of the abdomen, with the patient in a recumbent position, the knees flexed and shoulders elevated (Fig. 160), one hand placed over the corresponding renal region, while the other presses the abdominal wall in gradually but firmly, using the entire palmar surface of the hand and not the finger-tips alone.

Another method which is not as frequently used is that recommended by Israel, which consists in having the patient lie upon the healthy side while the renal region is palpated bimanually on the diseased side. In patients who are not too stout, and whose abdominal walls are relaxed, the lower pole of the kidney may be normally felt a little above the level of the umbilicus at the external border of the rectus abdominalis.

Abdominal tumors which are due to abnormal conditions of the kidney may be divided into four classes:

1. Congenital displacements and malformations of the kidney.
2. Movable kidney.
3. Diseases which are accompanied by enlargement of the kidney, such as hydronephrosis, pyonephrosis, pyelonephritis, tuberculosis, nephrolithiasis, and neoplasms.
4. Tumors which are due to neoplasms of the kidney.

1. Congenital Displacements and Malformations of the Kidney.

(*a*) It is practically impossible to diagnose a congenital displacement of the kidney before operation. Such kidneys do not give rise to symptoms unless enlarged through inflammation, and their presence in such abnormal places as the pelvis is seldom suspected. I have seen two

such cases. In one of these the kidney was located over the promontory of the sacrum, and caused some pain, the etiology of which was not clear until the kidney was discovered at operation. In the second case the congenitally displaced kidney was found incarcerated between the pregnant uterus and the rectum and was the cause of the severe dystocia. One may suspect that an abdominal tumor is a congenitally displaced kidney if ureteral catheterization is performed and it is found impossible to catheterize the ureter upon the side of the suspected kidney tumor. Such obstruction may be due to other causes, such as stricture of the ureter, etc., and the diagnostic value of ureteral catheterization is therefore not great.

(*b*) Congenital malformations of the kidney, such as horseshoe kidney, cannot be diagnosed before operation, unless some change such as a hydronephrosis supervenes, when it may cause a tumor lying transversely at the middle of the pathologically situated kidneys, which can be diminished by compression and which is found to be retroperitoneal.

2. Movable or Floating Kidney.

Eighty-five per cent. of movable kidneys occur in women. The diagnosis may be made from the presence of a movable tumor having the typical form of the kidney, with convex outer and concave inner borders, and the round, blunt, lower pole. This tumor, like all renal tumors, usually lies behind the inflated colon. It can be readily brought to the anterior abdominal wall and then can be replaced toward the renal region. An interesting point is that such abnormal mobility is often associated with a general enteroptosis.

In addition to the tumor itself, the cases may be divided clinically into three classes:

(*a*) Those in which the tumor is not accompanied by any symptoms referable to the kidney.

(*b*) Those in which the symptoms are those of a drawing pain in the lower abdomen and lumbar region, which may become colicky and radiate down the ureter, accompanied by evidences of nervous dyspepsia and constipation. The pain decreases when the patient lies down.

(*c*) Those cases which, in addition to the tumor, give the history of recurrent attacks which have been termed "Dietl's crises," and described on page 271. Such an attack is characterized by severe pain, chill, nausea and vomiting. The pain radiates along the ureter. There is but little urine passed during the attack, but following it there is

polyuria. During the attack itself the kidney may be greatly enlarged and tender, but this disappears with the acute syndrome. The urine contains red blood-cells in moderate quantity after the attack, and not during it, as occur in renal colic.

Differential Diagnosis.—(*a*) Movable kidney must be differentiated from a *corset liver*. This is very difficult if they are both present on the right side. Diagnosis is aided by laying the patient on the opposite side, as recommended by Israel, when one can separate the lower edge of the liver, which is always more or less sharp, from the kidney.

(*b*) From the *cystic tumors of the liver* and *enlarged gallbladder*. These have a distinct respiratory mobility, and are much nearer the surface than a kidney. They cannot be replaced into the renal region like a floating kidney, and the tumor itself is continuous with the liver, while in the case of the kidney, especially when the colon is inflated, there is an area of tympany between the tumor and the kidney.

(*c*) *Tumors of the Colon and Stomach.*—Here the history of the case will show, either the symptoms of a pyloric stenosis or an enterostenosis, and there will be more or less emaciation. The inflation of the colon or of the stomach will show more accurately the relation of the tumor to these structures, and in the case of the pyloric tumor, examination of the stomach contents will throw additional light.

(*d*) *Pedunculated Ovarian and Uterine Tumors.*—Their connection with the uterus through the ovarian ligament can be determined by bimanual examination; the floating kidney shows the characteristic form and can be readily replaced.

3. Diseases which are Accompanied by Enlargement of the Kidney.

Pyonephrosis and pyelonephritis have been discussed on page 252. Tuberculosis and nephrolithiasis are taken up on page 363.

Hydronephrosis.—This causes a tumor which is either constantly prominent, or is intermittent in its presence. This latter form is most often accompanied by floating kidney, recognition of which enables the diagnosis of the condition. The hydronephrotic enlargement of the kidney, like all renal tumors, appears from beneath the costal arch in the lateral aspects of the abdomen. Bilateral palpation enables the tumor to be brought either nearer to the abdominal wall or to become more prominent posteriorly in the space between the last rib and the crest of the ilium. If the hydronephrosis is a recent one, the tumor itself is firm. If it is of longer duration, distinct fluctuation may be found. The tumor lies behind the inflated colon, has a marked degree of mobility, and its surface is uniformly smooth.

The *differential diagnosis* of this form of renal enlargement has been discussed under the subjects: echinococcus of the liver; cystic enlargement of the gallbladder; cysts of the pancreas; ovarian tumors; tumors of the spleen, and neoplasms of the kidney, from all of which it must be differentiated. In renal tumors it may be said, in general, that they lie behind the colon, and this assists in the diagnosis.

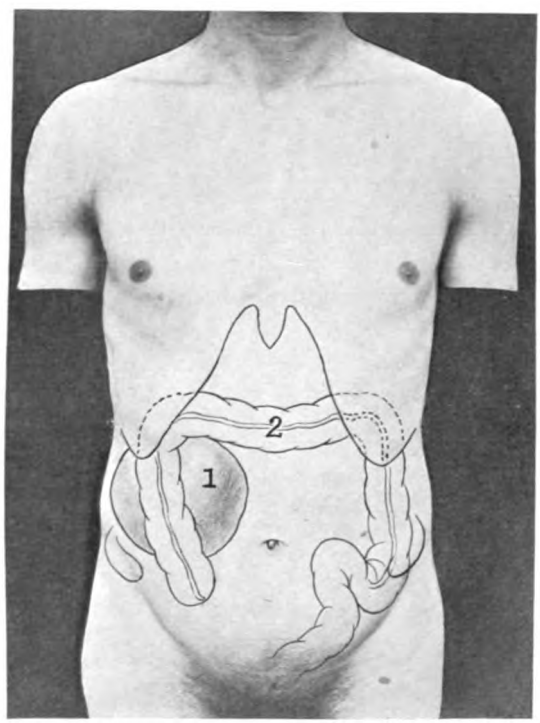

FIG. 191.—RELATIONS OF RENAL TUMOR OF RIGHT SIDE TO INFLATED COLON.

1, Renal tumor; 2, transverse colon; the inflated ascending colon lies in front of the tumor. A similar retroperitoneal condition may be due to unusual position of a pancreatic cyst simulating a renal tumor.

RENAL NEOPLASMS.

Neoplasms of the kidney which may be recognized clinically are of two varieties:

1. Polycystic kidneys (Fig. 192).
2. Malignant tumors.

1. Polycystic Kidneys.

The diagnosis may be made from the association of one or more of the following symptoms and physical findings.

(*a*) The presence of bilateral tumors with nodulated surfaces, having all of the characteristics of renal tumors as given on page 315. Quite rarely a tumor is only to be felt on one side. A palpable tumor is present in 25 per cent. of all cases.

(*b*) The symptoms of a chronic interstitial nephritis, viz., high-tension pulse, cardiac hypertrophy, large quantities of urine with low specific gravity containing a trace of albumin and few casts. Rarely uremic coma occurs.

Differential Diagnosis.—These cases can be differentiated from *chronic interstitial nephritis* with attacks of hematuria by the fact that the hematuria in nephritis is never as severe as in polycystic disease, and

the further fact in that in the latter bilateral, palpable tumors are present in 25 per cent. of the cases.

From *hydronephrosis* it can be distinguished by the unilateral occurrence, the smooth surface and greater regularity of a hydronephrotic tumor.

2. Malignant Tumors.

The diagnosis of a malignant neoplasm of the kidney may be made from a consideration in each case of five factors which vary greatly in value and in frequency.

These are:

1. Hematuria.
2. Pain.
3. Tumor.
4. Cachexia.
5. Metastases.

1. *Hematuria* occurs in about 70 per cent. of all cases as the first

FIG. 192.—EXTERNAL VIEW OF CONGENITAL CYSTIC KIDNEY. (See text.)

symptom. The hemorrhage occurs spontaneously, independent of exercise, may be quite large in amount and last for months. Quite often casts of the ureter, in the form of worm-like clots, are found in the urine.

The hematuria of renal calculus is increased or caused by exercise, is never as great in amount as in tumor, does not last as long, and is usually accompanied by colic.

In tuberculosis the hematuria is small in amount, not influenced by exercise, and accompanied by pus and tubercle bacilli in the urine.

The hematuria of polycystic kidney is rarely as profuse as that of malignant tumor and does not last as long and is accompanied by the signs of high vascular tension and polyuria.

Hematuria in chronic nephritis is rarely as marked; there are never worm-like clots, and one finds, in addition, the cardiovascular changes characteristic of this disease.

It is impossible to distinguish the hematuria known as *essential* or *idiopathic* from that due to malignancy unless tumor or cachexia is present. This form of hematuria, however, runs a more chronic course.

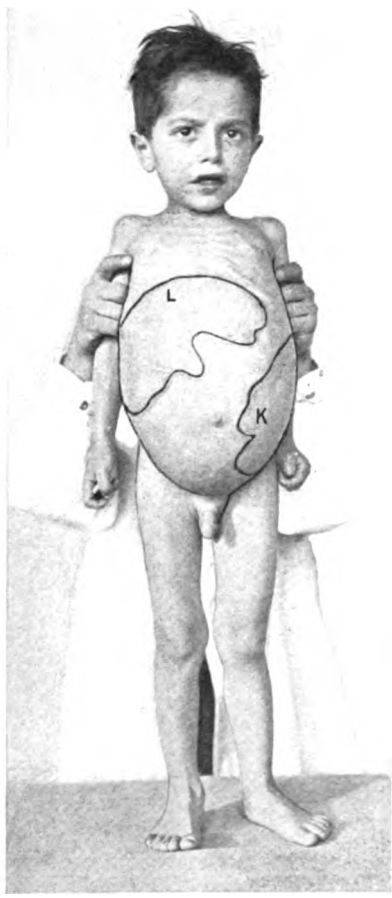

FIG. 193.—ANTERIOR VIEW OF A CASE OF SARCOMA OF THE KIDNEY IN A BOY OF FIVE.

K, Outline of kidney; L, outline of greatly enlarged liver.

2. *Pain.* This is very rarely the first symptom. When present, it is of a dull, dragging character, referred to the lumbar regions and radiating to the thigh. During an attack of hematuria the passage of the worm-like clots causes typical renal colic in the case of renal tumors.

3. *Tumors.* The majority of cases in adults are hypernephromata or sarcomata, while in children the latter form predominates. The physical characteristics of such renal tumors may be summed up as follows:

(*a*) The colon when inflated, lies in front of, or on the inner side of the renal tumor. The latter may be pushed so far inward by a large mass that there is no tympany over the tumor when the colon is inflated (Fig. 191).

(*b*) The tumor can best be palpated by the bimanual method shown in Fig. 160. By alternately raising the posterior and depressing the anterior hand during expiration, the size, consistency, and character of the surface may be ascertained. A second method is to lay the patient on the healthy side and then palpate bimanually.

(*c*) The general outlines of the kidney may be retained. These are the

concave inner and convex outer borders, and the blunt, rounded, lower pole.

When the tumor is quite localized in the lower pole, or very large, the resemblance to the normal shape is absent.

(*d*) Renal tumors cause a fullness in the space between the last rib and the crest of the ilium (iliocostal space). They lie nearer the anterior abdominal wall than does the normal kidney.

(*e*) The tumor may be so large as to occupy almost the entire abdominal cavity, as in the case shown in Figs. 193 and 194, so that it is impossible to determine from which organ the tumor has its origin.

(*f*) Benign tumors, with the exception of single and multilocular cysts, seldom give rise to palpable tumors. Malignant tumors cause an irregular round mass with a nodular surface and rapid growth. If

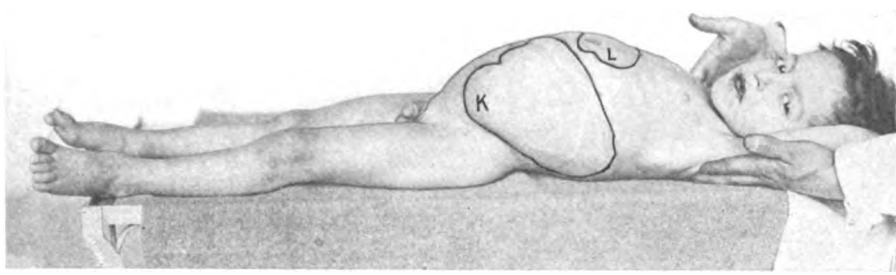

FIG. 194.—SIDE VIEW OF SAME CHILD SHOWN IN FIG. 193 (SARCOMA OF THE KIDNEY).
K, Outline of kidney on the abdominal wall; L, left edge of enlarged liver.

retrograde changes or softening are marked, the tumor may feel like a cystic one.

(*g*) Renal tumors when small have a moderate range of passive but practically no respiratory mobility.

4. *Cachexia.* This is usually not marked until the tumor attains a large size (Fig. 193). Emaciation is more rapid and marked in children (Fig. 193) than in adults. One must distinguish the marked anemia resulting from hematuria from a cachectic condition. Occasionally a renal tumor is accompanied by quite marked elevations of temperature.

5. *Metastases.* There are no symptoms which are characteristic of the growth of the renal tumor into the renal vein or vena cava. One should always bear in mind the tendency of malignant tumors to locate secondary foci in bones. This must always be thought of when symptoms occur, referable to the extremities, in a patient suffering

from hematuria and cachexia, since the metastasis may be the first symptom.

Differential Diagnosis of Renal Neoplasms.—1. *Retroperitoneal Sarcoma.*—These lie nearer the median line and cause but little displacement of the colon. When they are large they may involve the kidney so that a differentiation is impossible.

2. *Ovarian Tumors.*—The pedicle may often be felt to be connected with the uterus or adnexa. The intestines lie above and to its outer side (Fig. 180). The ovarian tumor, unless very large, can be traced to the pelvis, while a renal tumor appears to come from beneath the costal arch and causes bulging of the loin.

3. *Splenic Tumors.*—These, if large or when the characteristic shape is obliterated, may be impossible to differentiate (Fig. 189). If smaller, the characteristic notched edge and smooth surface aid in distinguishing them. In addition, the splenic tumor lies in front of the inflated colon and is not accompanied by hematuria.

4. *Tumors of the Liver.*—When the renal tumor is moderately large a zone of resonance is found between it and the liver. The renal tumor causes more bulging of the lateral aspects of the abdomen, is accompanied by hematuria and blood-casts of the ureter. Hepatic tumors lie more anteriorly and in front of the colon, unless the latter is adherent to their anterior surface.

ASCITES.

The presence of free serous fluid in the peritoneal cavity may either simulate or obscure the existence of abdominal tumor so that it is necessary to recognize the physical signs caused by such fluid. These are:

1. Widening of the abdomen.

2. A wave-like impulse, upon tapping with the fingers of one hand, felt by the other hand laid flat upon the opposite side of the abdomen.

While the patient is lying on his back percussion shows the median portions to be tympanitic (Fig. 180). This is the opposite of the percussion findings in ovarian cyst (Fig. 180), unless the latter is accompanied by ascites. When the patient lies on one side, the opposite flank becomes tympanitic, but this changes to dullness when he is rolled upon his back again.

The diagnosis of an ascites is confirmed by inserting a trocar in the median line midway between the navel and symphysis pubis, and obtaining a clear straw-colored fluid of low specific gravity containing a small amount of albumin.

In tuberculous and carcinomatous processes the fluid is at times hemorrhagic, but this is inconstant. In these cases a multilocular condition may exist and more than one puncture may be necessary to obtain the fluid. In chylous ascites the fluid is milky.

Having ascertained the presence of an ascites, one must attempt, either before or after the removal of the fluid, to determine its cause. This may be local or general.

Local:

(*a*) Obstruction of the portal circulation, due to:
- Cirrhosis of the liver.
- Neoplasms of the liver.
- Abdominal tumors which compress the inferior vena cava or portal vein.

(*b*) Tuberculous or simple proliferative peritonitis.

(*c*) Neoplasms of the peritoneum.

(*d*) Tumors of the abdomen—especially ovarian cysts, uterine fibroids impacted in the pelvis, etc.

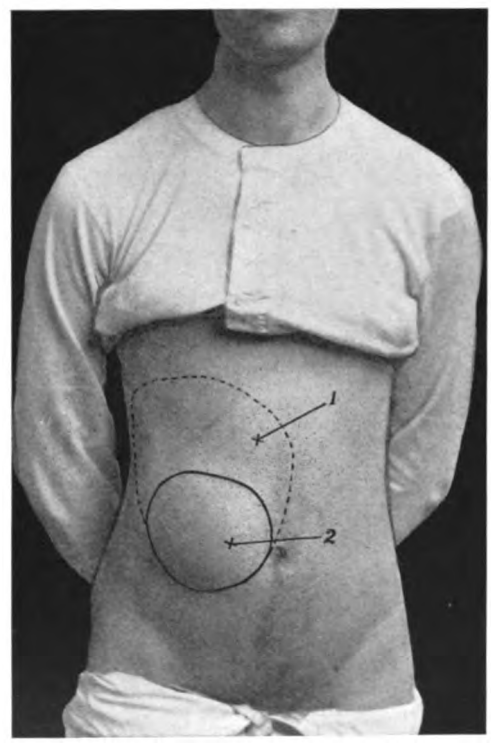

FIG. 195.—THE AREAS OF DULLNESS IN A CASE OF ENCAPSULATED INTRAPERITONEAL FLUID.

This illustration is the front view of the patient shown in Fig. 196. 1, Indicates the size of the encapsulated abscess, which was of a tuberculous nature, lying between the abdominal wall and the agglutinated coils of intestines within the peritoneal cavity, extending upward between the right lobe of the liver and the thoracic wall. 2, Indicates the area of external prominence on account of which the case was at first thought to be one of hydronephrosis.

(*e*) Obstruction of receptaculum chyli or duct leading from it.

General:

(*a*) Cardiac affections.

(*b*) Renal diseases.

(*c*) Chronic pulmonary diseases such as emphysema or sclerosis.

TUMORS DUE TO INFLAMMATORY EXUDATES OR TO TUBERCULOUS PERITONITIS.

Tumor-like masses may follow many of the acute and chronic abdominal affections, especially appendicitis and inflammations of the female pelvic viscera. The tumor-like induration around some gastric ulcers is referred to on page 335. Massive exudates often bind adjacent coils of intestine together in such a manner as to closely simulate neoplasms on palpation. The history of a preceding inflammation is of the greatest aid in making a diagnosis in these cases. Often some tenderness and muscular rigidity coexist.

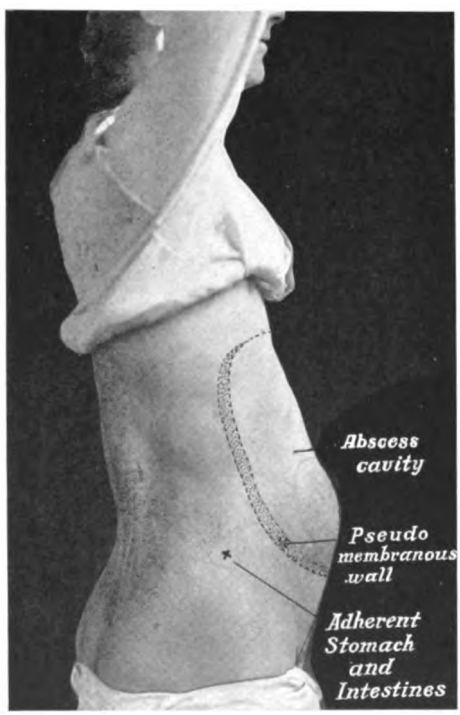

FIG. 196.—ENCAPSULATED TUBERCULOUS PERITONITIS.

Shaded area indicates the false membrane found at the time of operation, which separated the abscess cavity from the stomach and intestines, which were adherent to each other, and pushed to the posterior and left portions of the abdominal cavity. This is the side view of the same case represented in Fig. 195.

Tuberculous peritonitis is more fully discussed on page 343. It may give rise to tumors simulating those having their origin from the various viscera referred to in this section in one of four ways.

(*a*) Encapsulated exudates (see Figs. 195 and 196).

(*b*) Through puckering of the omentum. This causes a transverse, hard, elongated tumor, lying just above the umbilicus, although it has been found in the right iliac region.

(*c*) In an occasional case, after an ascites has been tapped one can feel the tumor due to contracted and adherent coils of intestine (Fig. 197).

(*d*) The presence of tumor-like masses in children due to enlarged tuberculous mesenteric glands with or without accompanying ascites.

The diagnosis may be made if there are tuberculous foci elsewhere, especially of the cervical lymph-nodes. When this is accompanied by

emaciation and evening rise of temperature, the diagnosis is rendered almost certain, but both of these may be absent, as in the case shown in Figs. 195 and 196. The tumors are often accompanied by pains and digestive disturbances in tuberculosis. One should never omit a rectal and vaginal examination. The history of tuberculous environments or of eating the flesh or milk of tuberculous cattle is of value also.

TUMORS DUE TO ANEURYSMS OF THE ABDOMINAL AORTA OR ITS BRANCHES.

Aneurysms of the abdominal aorta and its larger branches may give rise to palpable tumors which, in general, are readily recognized. When

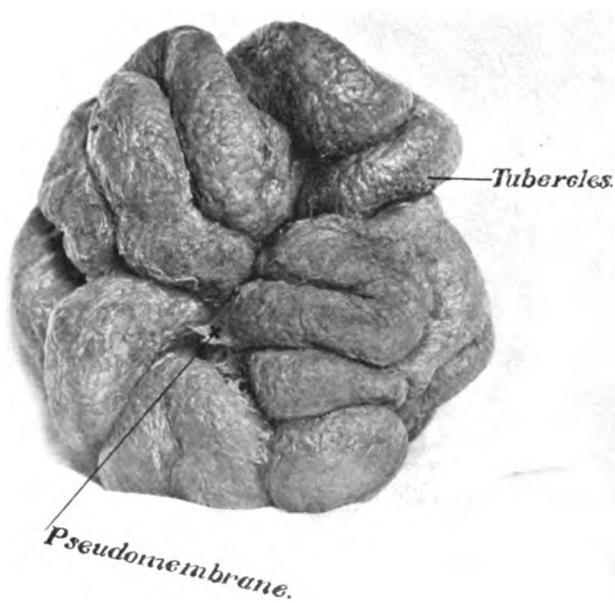

FIG. 197.—COILS OF INTESTINE IN A CASE OF TUBERCULOUS PERITONITIS.

The label pseudomembrane leading to a cross shows how these false membranes bind the different coils of intestine to each other. The serous surfaces of the various coils show innumerable tubercles covered by this false membrane.

grasped between the thumb, on one side, and the fingers on the other (Fig. 385), these tumors have an expansile pulsation and a systolic thrill. Auscultation shows a systolic murmur. These signs may, however, be rather indistinct if the aneurysmal sac is nearly obliterated. Under such circumstances the tumor can be recognized as being aneurysmal only by exclusion (Fig. 199).

In the majority of cases it is impossible to diagnose aneurysms of the cœliac axis, or its branches, or of the renal arteries. When palpable, however, they show the same signs as do those of the aorta.

The writer recalls one case of aneurysm of one of the branches of the superior mesenteric artery which caused a very mobile tumor whose nature was not recognized before operation.

Aneurysms of the iliac arteries are often easily palpable (Figs. 198 and 199). Those of the external iliac cause a firm, immovable tumor in the iliac fossæ whose nature can be determined by the presence of the characteristic expansile pulsation, of a thrill and murmur.

FIG. 198.—VIEW FROM RIGHT SIDE OF TUMOR OF ABDOMEN (*T*) DUE TO AN ANEURYSM OF THE EXTERNAL ILIAC ARTERY.

Note the prominent varicose veins over the region of the trochanter. This is the same case as shown in Fig. 199.

Differential Diagnosis.—An unusually marked pulsation of the abdominal aorta occurring in neurasthenics is often erroneously diagnosed as an aneurysm. It lacks the typical expansile pulsation of an aneurysm and the thrill is absent.

Tumors of the pylorus or pancreas lying over the abdominal aorta may have apparent pulsation through the transmission to them of the arterial movements. When the patient is placed in the knee-chest position, these tumors of intraperitoneal origin lose this pulsation.

They lack the expansile character of aneurysm, and one can usually recognize their nature by the other signs, such as the tests, etc., described.

Pulsating tumors filling up the entire iliocostal space and lateral abdominal regions are usually due to the rupture of an abdominal aneurysm into the retroperitoneal tissues.

ABDOMINAL TUMORS HAVING THEIR ORIGIN IN THE PELVIC VISCERA OR BONES.

Only those tumors are mentioned in which the enlargement is sufficient to cause the growth to rise out of the pelvis.

1. **Distended Urinary Bladder.**—In both sexes the enormously distended urinary bladder (Fig. 178) has been mistaken for a neoplasm. Ascites, an encapsulated exudate, and ovarian cysts are also among the tumors with which it has been confounded.

The diagnosis may readily be made from the history, shape of the tumor, and its position in the median line (Fig. 178), aided, where necessary, by catheterization, which is followed by the disappearance of the tumor. Wherever any question exists, and, in fact, to aid palpation of

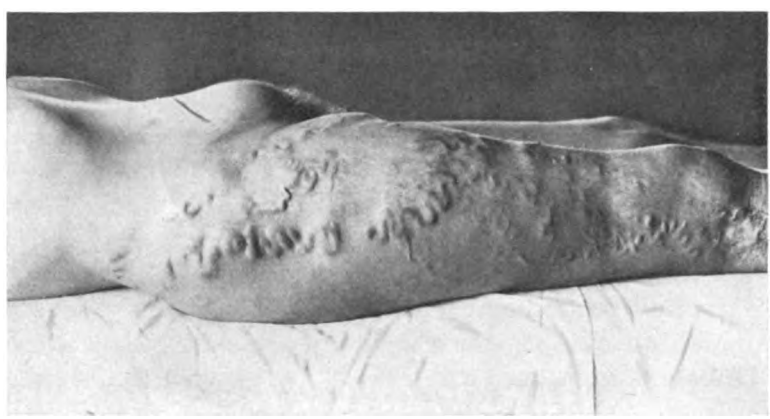

FIG. 199.—LATERAL VIEW OF TUMOR OF ABDOMEN DUE TO ANEURYSM OF THE EXTERNAL ILIAC ARTERY CAUSING PROMINENCE IN RIGHT ILIAC REGION.
Note the extensive varicose veins along the outer aspect of the thigh.

tumors of the lower half of the abdomen in general, the patient should be catheterized.

2. **Osteosarcomata.**—Sarcomata arising from the inner aspect of the os innominatum must be suspected, if the tumor is found in the iliac fossa, is fixed, hard, and gives the history of rapid growth.

3. **Neoplasms of Lymph-nodes.**—Tumors arising from the lymph-nodes lying along the pelvic brim are rare and are accompanied by evidences of a primary growth or by inflammatory symptoms. They may often be palpated through the rectum or vagina.

4. **Tumors arising from the pelvic viscera of the female** are the following:

1. Pregnant uterus.
2. Large uterine myomata which extend into the abdominal cavity.

3. Pedunculated uterine and ovarian tumors.
4. Large ovarian tumors.

The possibility of the presence of the first named condition must never be forgotten in the diagnosis of tumors of the lower half of the abdomen and the signs of pregnancy must be sought for.

Large uterine myomata are in general of round form and firm consistency. They may, however, be quite soft and give a sense of fluctuation. They can usually be moved with the body of the uterus and if submucous are accompanied by severe menstrual and intermenstrual hemorrhages. When interstitial, no symptoms are produced except those due to an enlarged uterus.

Pedunculated Ovarian and Uterine Tumors.—These may have such a long pedicle as to permit the tumor to be moved or palpated, as the case may be, from the pelvis to the costal arch, unless they are fixed by adhesions, under which circumstances it is almost impossible to recognize their nature before operation. If not thus fixed, bimanual examination will often reveal the pedicle and its relation to the pelvic viscera.

Larger Ovarian Tumors.—These, unless colossal, can be recognized by the fact that they rise out of the pelvis, and their pedicle can often be traced toward the uterus, especially by bimanual examination.

They cause contrasting physical signs to those of ascites unless accompanied by the latter. These signs are prominence and dullness over the pubes and in the median regions, but tympany in the flanks (Fig. 180).

The diagnoses of the various smaller pelvic tumors arising from the uterus and adnexa are not considered here, as they are fully discussed in the special books on gynecology.

DISEASES OF THE ESOPHAGUS.

STRICTURE OF THE ESOPHAGUS.

The esophagus extends from the level of the cricoid cartilage to the cardiac end of the stomach. The beginning is 15 cm., the termination 40 cm., from the teeth (Fig. 200). There are certain points where the esophagus is normally constricted, and these must be borne in mind when an examination with bougies for a suspected stricture is made. These narrow points are (Fig. 200):

1. At the beginning, opposite the cricoid or 15 cm. from the teeth.
2. Opposite the bifurcation of the trachea or 26 cm. from the teeth.
3. Where it penetrates the diaphragm or 37 cm. from the teeth.

Methods of Examination.—The most frequently employed method of examination for esophageal stricture is the use of graduated bulbous bougies passed in the manner shown in Fig. 201. Instead of the flexible bougie with olive tip, one can use a gum-elastic stomach-tube. The

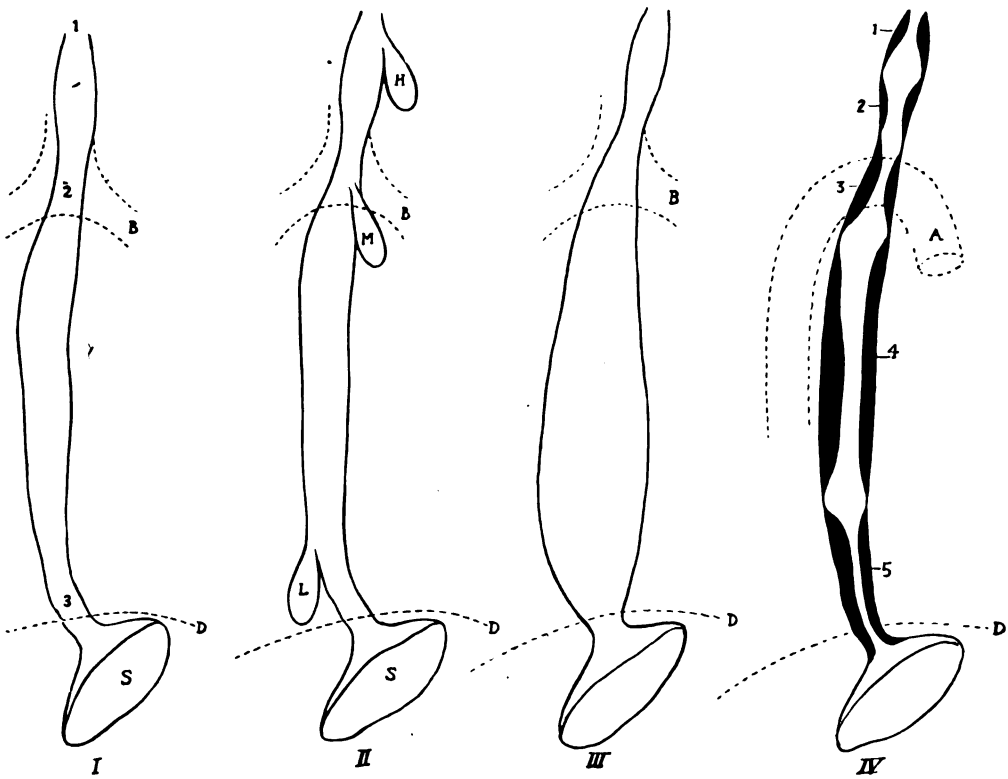

FIG. 200.—NORMAL AND PATHOLOGIC CONDITIONS OF THE ESOPHAGUS.

In all of the diagrams B represents the bifurcation of the trachea into the two main bronchi; D, is the diaphragm, and S, cardiac end of the stomach. I, Normal esophagus: 1, Showing the normal point of narrowing at its junction with the pharynx; 2, opposite the bifurcation of the bronchi; 3, at the diaphragm. II, Location of most frequent diverticula of the esophagus: H, Cervical form of pulsion or pressure diverticulum; M, location of traction diverticulum opposite bifurcation of trachea; L, location of diverticulum close to cardiac end of stomach. III, Sacculated condition of esophagus or so-called idiopathic dilatation as the result of spasm of the cardiac end of the esophagus (cardiospasm). IV, Diagrammatic representation of most frequent seats of stenosis or stricture of the esophagus: A, Arch of aorta; 1, stenosis as a result of carcinoma of the lower end of pharynx and beginning of esophagus; 2, stenosis as a result of pressure from tumors of the neck; 3, stenosis as a result of aneurysm of the arch of the aorta; 4, stenosis as a result of caustic or lye strictures; these latter may extend along the entire length of the esophagus; 5, stenosis as a result of carcinoma of the lower end of the esophagus and cardiac end of stomach.

patient should be seated on a low chair with head bent backward. Holding the patient's tongue down with the index-finger of the left hand, the bougie is passed directly back to the posterior wall of the pharynx, where the resistance prevents further progress in that direction. The bougie or

gum-elastic stomach-tube is then directed downward, great care being employed to avoid perforating a carcinomatous area or a diverticulum. It is advisable to begin with a large size and reduce the caliber if it is impossible to pass the first one. The esophagoscope has been employed for the purpose of locating strictures by Gottstein and others, but requires great dexterity and familiarity with it, so that for general purposes we rely on the above two methods.

When a genuine resistance is met the bougie is withdrawn and the distance of the stenosis from the teeth is noted.

Other methods of locating strictures, such as auscultation posteriorly while the patient swallows water, are seldom employed and are not so

FIG. 201.—METHOD OF PASSING ESOPHAGEAL BOUGIES IN ORDER TO DETERMINE THE LEVEL OF A STRICTURE.

Note how the patient's head is held slightly backward, the left hand being placed upon the forehead, while the right hand grasps the bougie in a manner similar to that of holding a penholder, no force being used.

reliable as the passage of bougies. In every case it is advisable, in addition to instrumental examination, to insert the index-finger into the pharynx, because one may be able to palpate a malignant growth at the beginning of the esophagus. An attempt should be made to recognize not only the location but also the nature of the stricture if one exists.

Within recent years bismuth and similar substances which give a shadow in a skiagraph have been employed to locate strictures of the esophagus, and also in cases of diverticula and dilatation. The patient is given about one ounce of bismuth subnitrate mixed with bread or potato and instructed to swallow it. The substance lodges above the point of stenosis, as shown in Fig. 202, causing a distinct shadow in

cases of dilatation. One gets a spindle-shaped shadow corresponding to the extent of the dilatation. Another method, to be referred to below, is also used, and this consists in having the patient swallow a bag filled

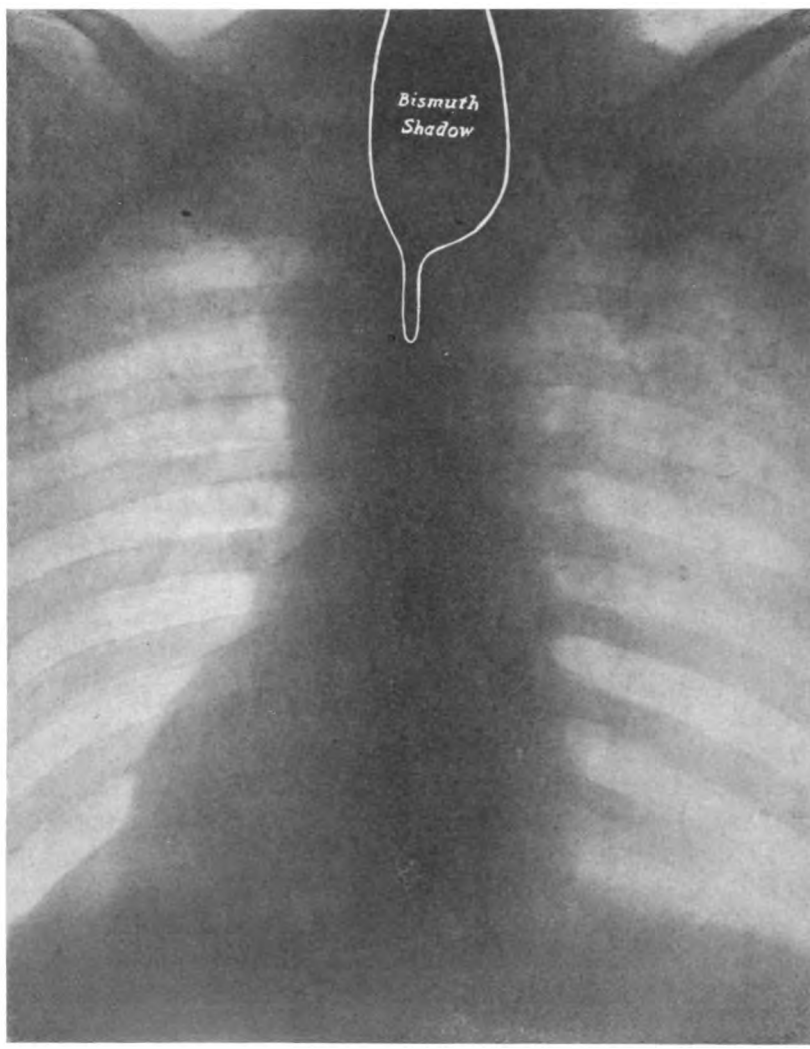

FIG. 202.—X-RAY OF A CASE OF STRICTURE OF THE ESOPHAGUS OPPOSITE THE BIFURCATION OF THE TRACHEA. The outlines of the bismuth shadow have been traced in white.

with shot, which gives rise to a shadow at the point of stenosis or within the sac of the diverticulum.

Diagnosis.—The diagnosis of esophageal stricture in general may be made from the following:

1. History of difficulty in swallowing accompanied by the regurgitation of food or mucus, often mixed with blood.

2. History of some etiologic factor mentioned below under the head of cicatricial or extra-esophageal or malignant causes. The exclusion of a neurotic cause of the stenosis must always be made.

3. The results of the local examination with the bougies, stomach-tubes, esophagoscope, or an *x*-ray after bismuth has been swallowed.

The diagnosis of the cause of the stricture may be made by excluding the following in their order:

1. *Cicatricial Strictures.*—These give the history of having swallowed caustic liquids or having had some disease which could produce esophageal ulcerations, such as syphilis or typhoid fever. The bougie meets a firm resistance which responds readily to treatment by graduated bougies.

2. *Strictures due to Pressure from External Causes.*—This group includes pressure upon the esophagus from aneurysm of the arch of the aorta, enlarged cervical or retrosternal goiter, especially when malignant, enlarged cervical and bronchial glands, tumors of the neck or mediastinal tissues, rarely pericardial effusions, and lastly by esophageal diverticula.

It is unnecessary to consider the diagnosis of these various extra-esophageal causes of strictures here, as they are discussed under the respective headings.

3. *Carcinomatous or Malignant Strictures.*—This is by far the commonest cause of stricture of the esophagus in patients above forty, and especially after the age of fifty years.

The dysphagia common to all strictures appears in carcinoma, gradually accompanied by progressive emaciation and loss of strength. The other symptoms vary according to the situation of the carcinoma.

(*a*) If at the beginning of the esophagus (Fig. 200) there is immediate regurgitation of the food and early enlargement of the cervical lymph-nodes. In one case recently seen the patient consulted the writer in regard to the tumor of the neck before the dysphagia had become sufficiently marked to attract his attention.

(*b*) If the cancer is situated at the level of the bifurcation of the trachea, hoarseness and aphonia are marked.

(*c*) If situated close to the cardiac end the regurgitation of food occurs much later, often ten to fifteen minutes after being swallowed.

The bougie is arrested at the beginning of the carcinoma and *no force should be employed in passing through it.* A sudden improvement in the stenosis symptoms, points to ulceration of the cancer. Late sequelæ of malignant stricture are perforations into the pleural cavity or mediastinum.

4. *Spasmodic Stricture.*—This fourth variety of stricture is comparatively rare and can usually be distinguished from the cicatricial, extra-esophageal, and malignant forms by the history and the physical examination. The spasmodic strictures occur in nervous hysterical women, but may occur in elderly men, and are often associated with hypochondriasis or true hysteria. The bougie is often temporarily arrested at the point of spasm, but by waiting a short time it can be passed through the stricture readily, especially under anesthesia.

DIVERTICULA OF THE ESOPHAGUS.

There are two varieties:

1. Traction diverticula situated on the anterior wall opposite the bifurcation of the trachea. They are caused by cicatrices resulting from bronchial lymph-node or pleuropericardial inflammation, drawing the anterior wall out.

This form cannot be diagnosed unless, as rarely occurs, food collects within the sac so that a pressure diverticulum is formed.

2. Pressure diverticula occur in three places:

(*a*) In the pharynx, causing at times a tumor in the neck, referred to on page 177, which can be emptied when filled with food. This is the most frequent form.

(*b*) At the bifurcation of the trachea developing from a traction diverticulum.

(*c*) Just above the diaphragm.

The diagnosis of a diverticulum of the pharynx may be readily made if there is a history of a tumor of the neck, most often on the left side, which develops during eating, can be emptied by pressure, and is accompanied by the regurgitation of food. A bougie is arrested at the cricoid and may be passed into the sac and freely moved about, so that the tip can be felt in the neck. If situated lower down, other means of diagnosis are employed, and the condition must be differentiated from stricture and dilatation of the esophagus, because in all three the symptoms of regurgitation of food are present.

The methods of diagnosis at present employed to differentiate these three varieties of pressure diverticulum are:

1. The use of bismuth or similar shadow-producing substances and a skiagraph. If the patient is allowed to swallow a bag of bird-shot or a mixture of bismuth and bread, it often enters the diverticulum and gives rise to a distinct shadow.

2. A bougie enters the opening of the diverticulum, if the latter is

full, and is arrested there, but meets with no obstruction and passes into the stomach, if the sac is empty. This intermittent arrest of the bougie is characteristic of deep-seated diverticula.

One tube can at times be passed into the diverticulum and a second alongside of it into the stomach. If different colored fluids are poured into them separately, they will return unmixed.

3. The esophagoscope often shows the opening of the diverticulum, but, as stated above, its employment requires considerable skill and practice. A deep-seated diverticulum is distinguished from a stricture by the fact that the arrest of the bougie is intermittent in the former and constant in the latter. (See method 1, above.) It may be differentiated from a diffuse dilatation either by the skiagraph or the Rumpel test, which is as follows:

A tube with lateral openings is passed into the stomach, while a second one is passed into the diverticulum. If there is dilatation, colored fluid poured into the tube at the point of enlargement will flow through the lateral openings into the stomach. If a diverticulum is present nothing will flow out of the tube in the stomach, while from the tube in the diverticulum all the fluid poured in will be recovered.

IDIOPATHIC DILATATION OF THE ESOPHAGUS.

This frequently follows a spasm of the lower end of the esophagus. The lumen may become enormously dilated, so that when a bougie is passed it meets with no obstruction but has a very wide range of motion. A skiagraph taken after the ingestion of bismuth often shows a spindle-like shadow. The esophagus will hold 500 Cc. of fluid instead of 100 Cc. of fluid. In the majority of cases the patients suffer from difficulty in swallowing, and from regurgitation of food soon after eating or several hours later. There is great fetor and a feeling of oppression in the thorax which is only relieved by vomiting. The regurgitated food contains no HCl, but an excess of lactic acid.

FOREIGN BODIES IN THE ESOPHAGUS.

These may be divided into those which are rough and those which are smooth. The former cause both obstruction and injury to the wall of the esophagus, while the latter only cause obstruction. If situated high up near the opening of the glottis, foreign bodies, like chunks of meat, may cause asphyxia. If they are smaller they give rise to attacks of cyanosis and suffocation. If the foreign body is sharp it causes pain which is often referred to the sternum.

The diagnosis may be made from (*a*) the history, in the majority of cases; (*b*) examination by the various methods to be mentioned; and (*c*) the symptoms of dysphagia, pain, and appearance of periesophageal abscesses due to perforation of the wall and infection of the surrounding connective tissue.

The **methods of examination** are (*a*) the passage of an olive-tipped bougie, which is arrested where the foreign body is lodged unless its convex surface lies in the concavity of the anterior wall.

(*b*) Esophagoscopy.

(*c*) A skiagraph is very valuable if the foreign body is a metallic one.

(*d*) The finger should be inserted into the beginning of the esophagus and the laryngeal mirror used.

OTHER ABDOMINAL CONDITIONS.

In the preceding sections an effort has been made to group affections as they present themselves when we are called to the bedside of a patient to make a diagnosis.

As stated in the preface, it was thought by the author that such a grouping more nearly meets with clinical conditions than would one in which the injuries or diseases of each viscus were discussed separately.

It is impossible, however, to consider every condition under the heads of Traumatisms, Acute Affections, and Tumors of the Abdominal Viscera, so that it will now be necessary to take up the remaining diseases which are of interest from a surgical standpoint.

SURGICAL DISEASES OF THE STOMACH.

DILATATION OF THE STOMACH.

This occurs acutely, as a postoperative condition (see Chapter on Post-operative Complications), or in a chronic form. The latter results from congenital or acquired stenosis of the pylorus.

In **congenital stenosis** the diagnosis may be made from the history and the physical examination. It usually begins in the first weeks of life. The baby is unable to retain any or very little food and vomits very frequently. If the emesis is accompanied by diarrhea with much mucus and undigested milk in the stools, the condition must be differentiated from gastro-enteritis.

It is possible to see the peristaltic waves passing across the epigastric and umbilical regions when the stomach is filled.

If in addition to the constant vomiting and visible peristalsis one is

able to palpate a mass just below the right costal arch corresponding to the hypertrophied pylorus, the diagnosis is certain. Unfortunately, in many of the cases the peristalsis and tumor are not detected until the disease is well advanced. This condition must always be borne in mind when there is a history of repeated vomiting immediately after the ingestion of food in emaciated infants, whether breast-fed or bottle-fed.

Acquired stenosis is most often the result:

(*a*) Of stricture or adhesions following the healing of a round ulcer.

(*b*) Of malignant disease of the pylorus.

(*c*) Of gastric atony.

The diagnosis of gastric dilatation, whether congenital or acquired, is readily made from the following:

Vomiting is the most prominent symptom. At varying intervals, ordinarily every two or three days, an enormous quantity of liquid mixed with undigested food, and of an offensive odor is brought up. In the intervals there is complaint of oppression after eating, eructations of gas, and thirst. Tetany may occur as an early symptom.

When the stomach is full one can easily demonstrate a splashing sound on succussion. The outlines of the distended organ are often visible and peristaltic waves can be seen passing across it toward the pylorus. When the stomach is inflated with air the outlines become very plain. In *gastroptosis* both the lesser and greater curvatures are at a lower level, while in dilatation the lesser remains almost normal, although the greater may even be as low as the symphysis pubis. A history of many years' duration, preceded by severe pain after eating and either melena or hematemesis, speaks for ulcer as the cause of the obstruction. Rapid emaciation, absence of HCl in the vomit, palpation of a tumor, speak for malignancy. Adhesions rarely cause a marked degree of dilatation.

Gastric and Duodenal Ulcer.

Symptoms.—In many cases the presence of this condition is not suspected until there is hemorrhage from the stomach or bowels or symptoms of perforation occur (page 266). In other cases there is a characteristic group of symptoms from which the diagnosis is made. They are as follows:

Pain.—This is either felt soon after the ingestion of food in gastric, or one to two hours later in duodenal ulcer. The pain is usually well localized in the epigastrium, but may radiate to the back and sides. During the painless interval there is tenderness on pressure over the epigastrium.

Hemorrhage.—This may be latent and only be found by examination of the stomach contents. In many of the cases of acute ulcer, the hemorrhage is profuse and is vomited as bright red fluid blood. This may occur only once or be repeated at intervals for years. In duodenal ulcer the patient may suddenly collapse, or feel faint and pass large quantities of tarry blood in his stools.

Dyspeptic Symptoms, Nausea and Vomiting.—The degree of the symptoms of indigestion varies greatly. They may be insignificant or very marked. Vomiting one to four hours after eating is frequent in gastric ulcer, and in both the stomach contents frequently show hyperchlorhydria.

Differential Diagnosis.—*Gastralgia.*—The area of tenderness is more localized in ulcer and present during the intervals of the attacks of pain. Hyperacidity is a more constant finding in ulcer, while in gastralgia it may be present or there be deficient HCl. In many cases of ulcer there is a history of hemorrhages and of dilatation. Dyspeptic symptoms and vomiting in the intervals of pain are more characteristic of ulcer.

Carcinoma of the Stomach.—This is considered elsewhere (page 335).

Epigastric Hernia.—This is referred to on page 420.

Gallstones.—The attacks of pain, as a rule, occur independently of the ingestion of food, are located over the region of the gallbladder, and are accompanied by rigidity. The attack of biliary colic begins suddenly and the pain is far more severe than that of ulcer. It radiates to the right shoulder, and the vomiting which accompanied it persists after the stomach is empty. If the ulcer, as is most often the case (Fig. 203), is situated on the posterior wall near the pylorus, there is a localized tender spot between the right costal margin and middle line, unless a gastroptosis exists, while in gallstones the tenderness and pain are further to the right (Fig. 167).

Ulcer of Stomach versus Ulcer of Duodenum.—It is almost impossible to distinguish these clinically. Duodenal ulcers are more frequent in men after middle age, the pain occurs one to two hours after ingestion of food and is referred to the right hypochondrium. Intestinal hemorrhage occurs after gastralgic attacks with hematemesis in duodenal ulcer. But all of these may occur in gastric ulcer (which, however, is more common in women under thirty), so that an absolute differentiation is impossible.

Diagnosis of the Complications of Gastric and Duodenal Ulcer.—1. *Perforation* was referred to in the section on acute abdominal affections, page 266.

2. *Perigastric Abscess due to Perforation (Left Subphrenic Abscess).*—The diagnosis is dependent on the history of the ulcer, as given above, followed by acute symptoms of a localized peritonitis, usually of a left subphrenic abscess. There is a history of perforation followed by irregular fever, tenderness over the left upper quadrant of the abdomen combined with physical signs over the lower part of the left side of the chest, as in empyema. Occasionally induration and tenderness are present in the epigastrium. If a retroperitoneal abscess form, the pus may burrow toward the lumbar region and cause fluctuation here. Gas

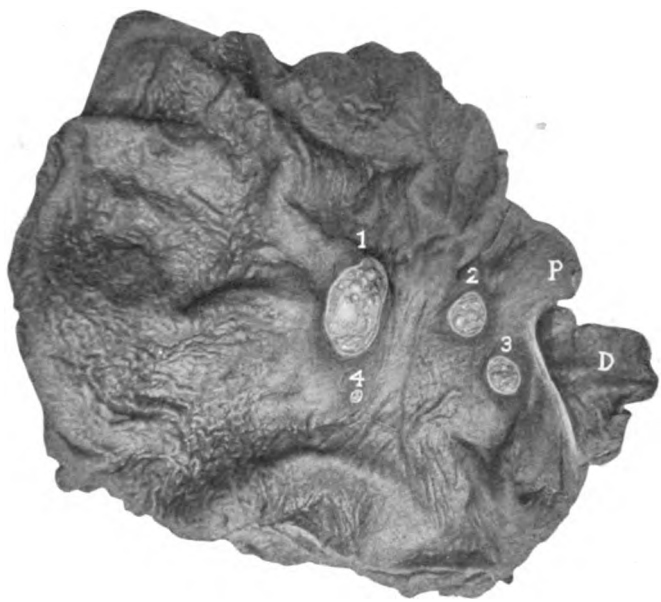

FIG. 203.—MULTIPLE ULCERS OF POSTERIOR WALL OF STOMACH.

P, Pylorus. By following the illustration downward from this letter, one can note the rather sharp demarcation between the gastric mucous membrane, on which the ulcers are situated, and the duodenum, shown at D. 1, 2, 3, and 4 are typical round ulcers showing great variation in size, situated on the posterior wall of the stomach.

is more frequently present in left than in right subphrenic abscess, so that above the dullness there is tympany. Unless there is an accompanying pleuritic effusion, breath sounds are heard above the upper level of dullness and there is respiratory mobility. The three zones of normal lung resonance, tympany and dullness are well shown in Fig. 166.

3. *Hour-glass Stomach.*—This follows cicatrization of an ulcer. The diagnosis may be made from the following signs and tests as given by Moynihan:

First, when fluid is introduced into the stomach it seems to disap-

pear altogether, and is not returned through the tube. Second, when the stomach is washed out, until the fluid returns clear, there is a sudden, unlooked-for gush of foul or often putrid fluid. Third, on distending the stomach with carbon dioxid, the bubbling and gushing of fluid through a narrow chink can be heard with a stethoscope. Fourth, there may be a distinct visible or palpable sulcus separating two dilated cavities.

Perigastric Adhesions.—These may be recognized by symptoms of chronic indigestion or pyloric obstruction of slight degree, by slight tenderness over the epigastrium, and the occasional presence of palpable tumor. There is often a history of gastric ulcer (in 40 per cent. of the cases) or of gallstones, or less frequently of tuberculosis. The tumor may resemble that of cancer, but is never accompanied by the progressive emaciation of the latter condition. The course is very chronic and is frequently accompanied by evidences of biliary stasis and absorption.

Carcinoma of the Stomach.

The presence of this condition is diagnosed if, in a patient above the age of forty, with or without the history of ulcer, signs of digestive disturbances appear accompanied by pain, anemia, loss of weight, and vomiting.

The most important points in making a diagnosis are:

(*a*) The history of steady, progressive loss of weight.

(*b*) The presence of a secondary anemia, both red corpuscles and hemoglobin being reduced.

(*c*) Pain. This is an early and important symptom according to Osler, and was present in 130 to 150 cases. At first only a heaviness after eating is noticed, but later it is of a dull, gnawing character referred to the epigastrium. There is marked local tenderness.

(*d*) Vomiting. This is also very constant. It occurs earliest when the tumor is near the pylorus, from one to two hours after the taking of food. At first it is infrequent, but later is almost constantly present.

(*e*) Hemorrhage. This rarely occurs as bright red blood, but most frequently in smaller quantities, giving the vomitus the typical "coffee-ground" appearance.

(*f*) Stomach contents. An analysis of the stomach contents after a test meal has been given should be made on several occasions at short intervals in order to draw accurate conclusions.

The constant absence, or great reduction of hydrochloric acid and the presence of lactic acid are strongly indicative of cancer. Unfortunately, these data are often so late in their appearance as to be of little value unless present quite early.

On the other hand, carcinoma may exist although hydrochloric acid is present. The latter is the condition frequently found in cases of carcinoma developing upon a round ulcer (Fig. 204).

The presence of the Oppler-Boas bacillus is of slight value, but the detection of lactic acid in the stomach contents after a Boas test meal is of greater value. The constant presence of blood intimately mixed with the gastric contents is also of great importance, especially if vomited alone; as hydrochloric acid is absent in cases of chronic gastritis or atrophy of the mucosa, the value of the presence of blood is apparent.

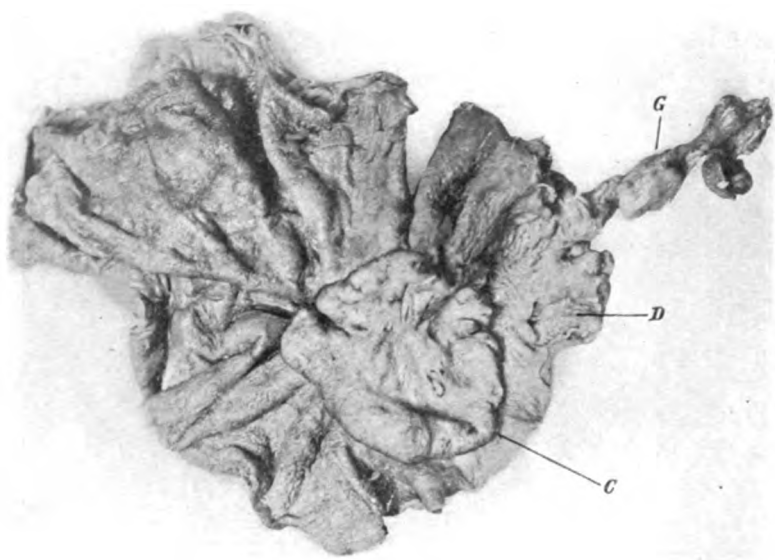

FIG. 204.—CARCINOMA OF STOMACH DEVELOPING UPON ROUND ULCER.

This is the primary tumor whose metastases are seen in the liver in Fig. 185. *C*, Observe the sharp demarcation between the carcinoma and the surrounding normal mucous membrane of the stomach. *D*, Mucous membrane of duodenum. Observe the proximity of the carcinoma to the pylorus. *G*, Lymph-nodes along gastrohepatic omentum.

(*g*) Tumor. This is the most important symptom, but, like the changes in the stomach contents, is often only present at a late stage. The surface is usually smooth.

Unless adhesions exist a tumor of the stomach is freely movable (Fig. 181) and is best felt when the stomach is empty. Usually the tumor is located in the epigastric or umbilical regions, but in gastroptosis may be in the right iliac region (Fig. 183). The presence of an ascites may render the palpation of a tumor impossible until the fluid is aspirated, and this should, of course, be done.

GALLSTONES.

Many cases of cholelithiasis are either not recognized during life or they are found as an accessory condition in operations for other intra-abdominal lesions.

Cases in which a diagnosis is possible, occur clinically in different forms, as follows:

1. Those seen during an attack of biliary colic or of empyema of the gallbladder.

2. Those showing evidences of a complete occlusion of the cystic duct by a calculus.

3. Symptoms of common duct calculi with or without accompanying infection.

4. Cases seen in the interval between active symptoms pointing to the bile-passages.

The diagnosis of the first and second classes of cases has been referred to on pages 247 and 297, respectively.

3. **Common Duct Stones.**—A stone passing through the common duct may give rise to colic which cannot be distinguished, during the attack, from that due to the passage of one through the cystic duct. The most frequent location for common duct calculi is near the ampulla. The diagnosis must be made between one of two forms, according to whether the lumen is completely or incompletely occluded.

(*a*) Those causing complete obstruction. These are rare and may be recognized by the fact that the jaundice is deep and constant and there are no evidences of intrahepatic infection, as in the next group. They must be differentiated from new-growths pressing on the common duct by the absence of emaciation, and of symptoms indicative of cancer of the pancreas (page 303) or of the pylorus (page 335).

(*b*) Those causing incomplete obstruction due to a ball-valve action of the calculus. This is the more frequent form and is often accompanied by attacks of pain and chills at irregular intervals followed by high fever and a sweat. Jaundice becomes marked and the liver may be enlarged and tender. In a late stage the gallbladder itself is contracted in the majority of cases. A ball-valve-like common duct stone may, however, occur without infection of sufficient intensity to cause symptoms. The diagnosis may then be made from the history of previous attacks of biliary colic and by variations in the intensity of the jaundice.

Differential Diagnosis.—These attacks of rigors, etc., so closely resemble those of malaria that a mistake in diagnosis has often been made. *Malarial paroxysms* occur with more regularity and are less frequently

accompanied by jaundice, which, when present, is not deep. Nor is pain over the hypochondrium present, and unless quinin has been given, plasmodia can be found. There is also no leukocytosis in malaria, and the spleen is enlarged. Exceptionally plasmodia are not found until quinin has been given.

The presence of jaundice between the chills, and of clay-colored stools, should always direct attention to the possibility of gallstones, for which the stools must be searched.

The diagnosis of *suppurative cholangitis* has already been referred to (page 249). The septic intoxication is more marked, the fever is of a more continuous type, the liver is enlarged and tender, and recovery does not occur.

4. **Diagnosis During the Interval.**—It is this class of cases in which the recognition of the condition is often most difficult, for one has only the history and the results of the physical examination upon which to make a diagnosis.

History.—This is of the greatest importance, since many cases assumed for years to be gastralgia, indigestion, or intestinal colic, or even gastric ulcer, are now found to be cases of gallstones.

The history should be directed toward the following points:

1. Has pain been present at any time? If so, one should secure a detailed description of the attacks and compare it with those of typical biliary colic.

Such paroxysms of pain are less frequently observed than is a dull aching pain referred to the gallbladder. This dull pain is increased by taking food, but is relieved by vomiting or by pressure over the gallbladder.

The biliary colic pain is acute in its onset, very severe, and disappears suddenly, while the dull pain above referred to is more or less continuous. Radiation to the shoulders occurs in both of these varieties of gallstone pain.

2. What alimentary symptoms have accompanied the pain? In the majority of cases there is a history of nausea and vomiting, accompanying the more severe variety of pain, or there is a history of long-continued digestive disturbances with dull pain over the gallbladder. Jaundice occurs so rarely in gallstones that its absence in the history must not permit one to think of excluding gallstones. This is especially true of stones in the gallbladder and cystic duct. Jaundice, if of slight degree, is difficult to detect. A good plan is to look at the roof of the mouth at the back of the hard palate, where it is often visible, if nowhere else. It is also important to inquire in regard to the presence or

absence of bile in the stools. The jaundice due to carcinoma of the head of the pancreas or to a calculus completely obstructing the common duct is persistent and progressive.

3. Have fever, chills, and sweats been present at any time? Irregular paroxysms of these three symptoms, especially if accompanied by jaundice which varies greatly in degree, speak for common duct stone. Continued fever with but slight remissions indicates an empyema of the gallbladder.

Physical Examination.—*Palpation of the Gallbladder Region.*—

FIG. 205.—METHOD OF EXAMINATION TO ELICIT TENDERNESS OF GALLBLADDER (Moynihan).

One can often detect hypersensitiveness of the gallbladder by pressing the fingers down upon the gallbladder as shown in Fig. 179 or by the method described by Moynihan and shown in Fig. 205. In the latter procedure, while sitting to the right of the patient, the left hand is laid over the right side of the patient's chest so that the thumb lies along the costal arch. As a deep breath is taken the thumb is pressed upward toward the under surface of the liver. In addition to the hypersensitiveness there is frequently rigidity of the upper end of the right rectus.

Diagnosis of the Location of Calculi if Arrested Temporarily or Permanently.—*Stones in the Gallbladder.*—These either cause no

symptoms or they are those of an acute or a chronic cholecystitis. The diagnosis of the former is taken up on page 246. That of the latter is made from the presence of the dull, localized pain just described above, and digestive disturbances.

Stones in the Cystic Duct.—These cannot be distinguished from those of the gallbladder unless a tumor is palpable which can be recognized as due to a hydrops of the gallbladder (page 297), and this is not frequent. During the passage of a stone from the gallbladder into and through the cystic duct the symptoms are, for both, those of biliary colic.

Stones in the Common Duct.—Pain accompanied by distinct rigors, irregular fever, jaundice which varies in degree, and emaciation are characteristic of these calculi.

Stones in the hepatic duct or intrahepatic bile-passages cannot be recognized as such clinically.

APPENDICITIS (CHRONIC).

The diagnosis of acute appendicitis and its differentiation from other abdominal affections has been discussed on page 260. There is a form of inflammation of the appendix whose clinical course differs somewhat from the acute.

In this class of cases the patient has had an acute attack which was either not diagnosed or not operated upon. From time to time attacks of pain in the right iliac region occur of just sufficient severity to direct the patient's attention to them. The pain is usually of a dull aching character and incapacitates the patient for work for a day or so. It may be sharp and colicky in character, lasting, however, only a few minutes. To the latter class the term appendicular colic has been applied.

To those cases in which mild attacks of dull pain occur the term "chronic appendicitis" seems best fitted. Digestive disturbances, mucous stools, flatulency, and alternating constipation and diarrhea are often associated with the pain. On palpation a somewhat tender, elongated mass can often be felt in the appendix region, and the patient will usually refer the pain to this point. There is no accompanying rise of temperature or leukocytosis. If adhesions exist between the adjacent coils of intestine, there are indefinite colicky pains which radiate from the ileocecal region toward the rest of the abdomen. In palpating these cases to confirm the diagnosis, one will often feel a cylindrical mass in the right iliac region, which feels like a chronically inflamed appendix. This mass can be followed upward and downward much further than an appendix, and a similar mass is always to be felt in the left iliac region.

These cylindrical tumors are the markedly contracted cecum and ascending colon on the right, and the descending colon on the left side, respectively. The condition is often to be found in thin individuals, especially in neurasthenics who suffer from a chronic mucous colitis, so frequently accompanying a chronic appendicitis.

The differentiation of these chronic appendicitis cases, in women, must be made from chronic inflammatory conditions of the adnexa, and this usually can be done by careful bimanual examination; if necessary under an anesthetic. In addition, the pain of appendicitis is, as a rule, higher up than that arising from the adnexa. If much inflammatory exudation has occurred, it may be impossible to differentiate these two conditions, and they often coexist.

From gallstones these cases of chronic appendicitis can generally be distinguished by the fact that the tenderness in gallstones is just beneath the costal arch unless a Riedel lobe or hepatoptosis is present (Figs. 162, 183). In appendicitis the tenderness and tumor are in the right iliac region, at McBurney's point, or along the lower half of the right border of the right rectus.

CHRONIC INTESTINAL OBSTRUCTION (ENTEROSTENOSIS).

Total occlusion of the intestine means a complete obstruction to the passage of feces, either through paralysis of the muscular fibers or owing to mechanical causes. The former, or paralytic ileus, is most often due to septic peritonitis, but may at times result from non-septic (neuropathic) causes.

The diagnosis of this neuropathic or paralytic form of intestinal obstruction can rarely be made if due to non-pyogenic causes. If caused by septic infection, the clinical picture is that of an acute peritonitis. The latter has been discussed in connection with its most frequent cause. Intestinal obstruction as an acute process is taken up in connection with the other acute abdominal affections, since the diagnosis of its existence must be made in connection with that of these conditions, in the majority of cases.

By chronic obstruction of the intestine (*enterostenosis*) is meant a chronic incomplete interference with the passage of feces. If, as not infrequently occurs, the occlusion of the lumen becomes complete, the clinical picture changes to that of acute intestinal obstruction (see page 277).

The only exception to the above statement is in those cases of strangulated hernia in which only a portion of the wall has been caught in the

hernial opening (acute partial enteroceles). Although the lumen is not completely occluded from an anatomic point of view, yet the symptoms are the same as those in which the obstruction is complete and acute in its course.

Diagnosis.—The diagnosis of intestinal stenosis is made from a study of the history, the symptoms, and the physical examination, which conform closely to the following:

1. *Constipation.*—This is often the first symptom and may exist for a long time alone. The patient begins to notice that a movement of the bowels is difficult without a purgative. Not infrequently the constipation alternates with attacks of diarrhea. Constipation is an early symptom in stenosis of the large but a very late one of the small intestine.

2. *Colic.*—Often this is the earliest symptom directing attention to the possibility of a stenosis. The attacks of pain may be quite severe or very mild. The pain is oftenest localized at the seat of the stenosis, but may be quite diffuse. These paroxysms of pain are often accompanied by vomiting.

3. *Visible Peristalsis.*—When vigorous peristaltic waves can be seen passing across the abdomen accompanying colicky pains, the diagnosis of enterostenosis is easily made. The loops above the stricture remain distended but a short time and can often be grasped by the hands of the examiner.

4. *Tympanites.*—The degree of abdominal distention varies according to the completeness of the stenosis. It may become so marked as to cause considerable dyspnea. Unsuccessful efforts to pass flatus when the abdomen is more or less distended should direct the attention of a physician toward the possibility of an enterostenosis.

5. *Condition of Feces.*—The presence of obstinate constipation, alternating at times with diarrhea, has already been mentioned. If the obstruction is low down, diarrhea may be almost constantly present. Blood and pus in the feces are often found, but are not pathognomonic of an enterostenosis. If ribbon-like bands of fecal matter are constantly passed they are of great value in making a diagnosis.

6. The *examination of the abdomen* for a palpable or visible tumor, and bimanual examination *of the rectum and pelvis in general* in both sexes, should be a matter of routine in every case. In high-seated rectal strictures due to carcinomata, proctoscopy is often the only means of making an early diagnosis (see page 358).

7. The *history* of the case may throw some light on the probable seat and nature of the process. Progressive loss in weight accompanied by symptoms of enterostenosis speak for malignancy (page 341).

8. One should inquire carefully for a history of syphilis, of tuberculosis, of previous typhoid, of dysentery, or of operations involving the various abdominal viscera, including the rectum.

In regard to the diagnosis of the seat of the stenosis, the localization of the pain and of the peristalsis may be of aid, in addition to the facts learned from abdominal and pelvic examination.

TUBERCULOUS PERITONITIS.

In general, it may be said that tuberculous peritonitis occurs in five forms.

1. As part of a general miliary tuberculosis. As a rule, these cannot be diagnosed during life.

2. As a latent disease whose presence is only discovered accidentally at an operation for other conditions.

3. An acute form with tenderness, rigidity, fever, etc., or as a slower form resembling typhoid. Both of these have been described in the section on acute abdominal affections (page 250).

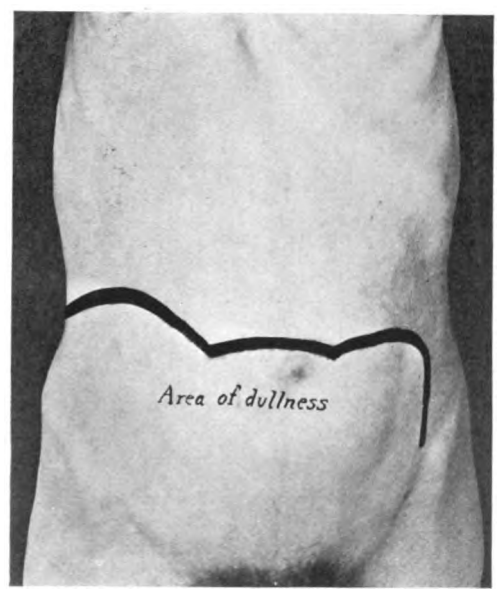

FIG. 206.—AREA OF DULLNESS IN EXTENSIVE ENCAPSULATED TUBERCULOUS PERITONITIS.

4. Those in which there is either an encapsulated exudate, or the formation of a firm mass resembling an abdominal tumor. These have been considered in the section on abdominal tumors (page 307), but will be enumerated again:

(*a*) Tumors due to rolling up, also called "puckering of the omentum."

(*b*) Encapsulated exudates (Figs. 195, 196).

(*c*) Tumors due to retraction, thickening, and adhesion of adjacent coils of intestine (Figs. 195, 197).

(*d*) Tumors due to enlarged mesenteric glands in children.

5. The ascitic form of tuberculous peritonitis.

The last named cases present the clinical picture of free fluid in the peritoneal cavity. In this variety the amount of fluid is usually not as great as in ascites due to cirrhosis of the liver and there is a great tendency to early encapsulation. If a pleurisy or other evidences of tuberculosis exist, the diagnosis is easy, as in the case shown in Figs. 206 and 207. There is often a previous cervical lymph-node infection, or a suspicious family history.

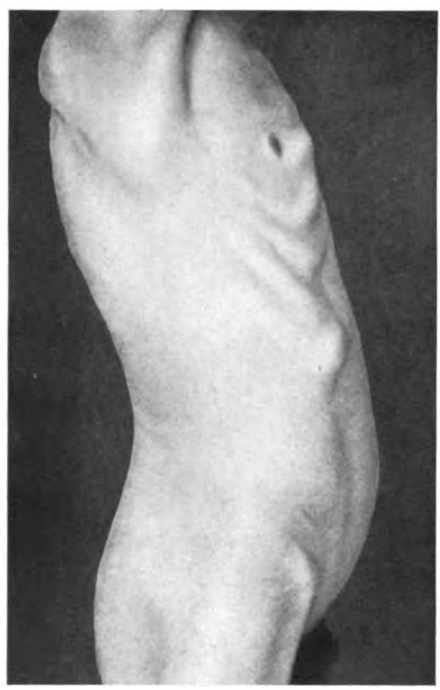

FIG. 207.—LATERAL VIEW OF ABDOMEN IN A CASE OF TUBERCULOUS PERITONITIS.

Same case as shown in Fig. 206. Note the prominence of the lower half of the abdomen corresponding to the area of dullness shown in Fig. 206. Also observe the emaciation.

In addition to the ascites, there is always more or less tympanites, so that the distention of the abdomen is greater than the amount of fluid, as evidenced by the dullness, would lead one to assume. There is often but little, if any, fever in the ascitic forms. There is usually more or less emaciation, although there are many exceptions. The presence of an encapsulated exudate, in addition to the free fluid, is quite diagnostic of tuberculous peritonitis. The use of tuberculin may clear up the diagnosis in doubtful cases, but it should be employed rarely.

Differential Diagnosis of the Ascitic Form.—*Ascites Due to Cirrhosis of the Liver.*—An alcoholic history and the presence of a splenic tumor, as well as the more marked enlargement of the superficial veins, speak for cirrhosis. The ascitic fluid in cirrhosis is clear, watery, with low specific gravity, and contains only a trace of albumin, while in tuberculosis it contains more albumin and is often flocculent. The presence of encapsulated exudate also speaks for tuberculosis as well as slight evening rise of temperature. The inoculation of guinea-pigs with positive results or the use of tuberculin makes the diagnosis absolute.

Carcinomatous Affections Involving the Peritoneum.—In this con-

FIG. 208.—SECTION OF A COIL OF THE ILEUM FROM CASE SHOWN IN FIG. 206 ILLUSTRATING THE PATHOLOGY OF TUBERCULAR PERITONITIS.

Note the yellowish raised miliary tubercles between which the intestine is markedly hyperemic. The veiled appearance of the upper half is due to the fact that in this portion the pseudo-membrane has not been stripped off from the underlying tubercles. This membrane is shown in a wrinkled or rolled up manner at about the middle of the picture.

dition the fluid is often hemorrhagic. Emaciation is much more rapid, and after the fluid has been evacuated tumor masses can be felt, which are harder and more nodular than those due to any tuberculous process.

THE RECTUM.

METHODS OF EXAMINATION.

The methods generally employed are: (*a*) Inspection; (*b*) Palpation; (*c*) Use of Specula.

(*a*) **Inspection.**—The best position for examination of the anus and lower portion of the rectum is in one of three positions. Where one is not provided with assistance, as in ordinary office work, the genupectoral position is in general the best. For hospital work, or where one has an assistant, the examination is best conducted with the patient in the lithotomy or in Sims' (semiprone) position. For the examination of the upper portion of the rectum the extreme knee-chest (genupectoral) posture is most suitable.

(*b*) **Palpation.**—This should never be omitted as a portion of the routine of diagnosis of abdominal conditions, and especially where symptoms pointing to rectal disease are complained of. The examination is best conducted in either the recumbent, or knee-chest position, the well oiled index-finger being used. A box of rubber finger-cots or some heavy rubber gloves for this purpose should be a part of the armamentarium of every physician, since one can palpate almost as well through these as with the unprotected finger.

(*c*) **Use of Specula.**—There are many different kinds of rectal specula in use, but a solid bivalve speculum which tapers and opens one side is the best. The examination will be greatly aided by the use of either an electric head-lamp or of a head-mirror with reflected light.

For the examination of the upper portion of the rectum the use of a proctoscope is indispensable.

A speculum should always be well oiled before being introduced and be slightly warm. The bivalve specula must never be rotated after being introduced, but preferably introduced a second time if it is desirable to examine a different portion of the rectum.

For the demonstration of affections of the lower half of the rectum when the patient is anesthetized, the Sims or Simon vaginal specula are very valuable. The use of other instruments may be necessary in making a diagnosis of special affections, such as that of probes in anal fistula or of graduated bougies to determine the caliber of strictures. The latter are best passed with the aid of the proctoscope.

History.—Before beginning the examination every patient's history should be taken as accurately as possible, as follows:

1. *Pain.*—What is its character? Is it sharp, lancinating, burning, throbbing, or only a sensation of pressure?

Relation to bowel movements? Is the pain intermittent? is it independent of the movements? does it precede, accompany, or follow them? How long does the pain last? Is it felt in the rectum or around it, or does it radiate?

2. *Bowel Movements.*—Does constipation or diarrhea exist? Is the stool formed or loose? is it ribbon-like? is the odor marked?

3. *Escape of Blood, Pus, etc.*—Does mucus, pus, or bloody discharge exist? How often does this occur, in what quantity, and does it accompany defecation or occur independently? Is the blood black and tarry, is it fresh and red, or are the feces merely streaked with blood?

4. *General Condition.*—Whether any organic disease of the heart, liver, or kidneys exists? Has the patient a family or personal history of carcinoma, tuberculosis, syphilis, or gonorrhea? Does any other pelvic condition exist?

5. *Character of Protrusion, if Any.*—Does it bleed? Can it be readily reduced? Does it protrude during defecation, or at regular periods?

CONGENITAL MALFORMATIONS.

There are four chief forms of this condition:

(*a*) **Atresia Ani** (No. 1 of Fig. 209).—The anus is entirely absent or only represented by a slight depression. The bowel ends blindly and may be separated from the skin by a thin membrane. This is the most frequent form.

(*b*) **Atresia Ani et Recti** (No. 2 of Fig. 209).—The anus and rectum are not developed. The colon ends as a blind sac at the level of the sacral promontory. There is no indication externally of an anus.

(*c*) **Atresia Recti** (No. 3 of Fig. 209).—The rectum is formed down to the level of the sphincters. The anal portion is normally formed. Both, however, end blindly and may be separated only by a membrane or by a septum of connective tissue which is 1 to 1½ inches (3 to 4 cm.) thick.

(*d*) **Abnormal Opening of the Rectum** (No. 4 of Fig. 209).—The anus is closed and the rectum opens into either the vagina or into the bladder, or even into the urethra.

The diagnosis of which one of these four conditions is present, can seldom be made before operation. As a result of retention of meconium

the abdomen becomes greatly distended and vomiting follows. The latter may be feculent at an early period or only appear late, if a peritonitis has begun. In every new-born child which does not pass meconium within six to twenty-four hours after birth, the anus should be examined. A number of these cases have been operated upon successfully in which such an early diagnosis was made.

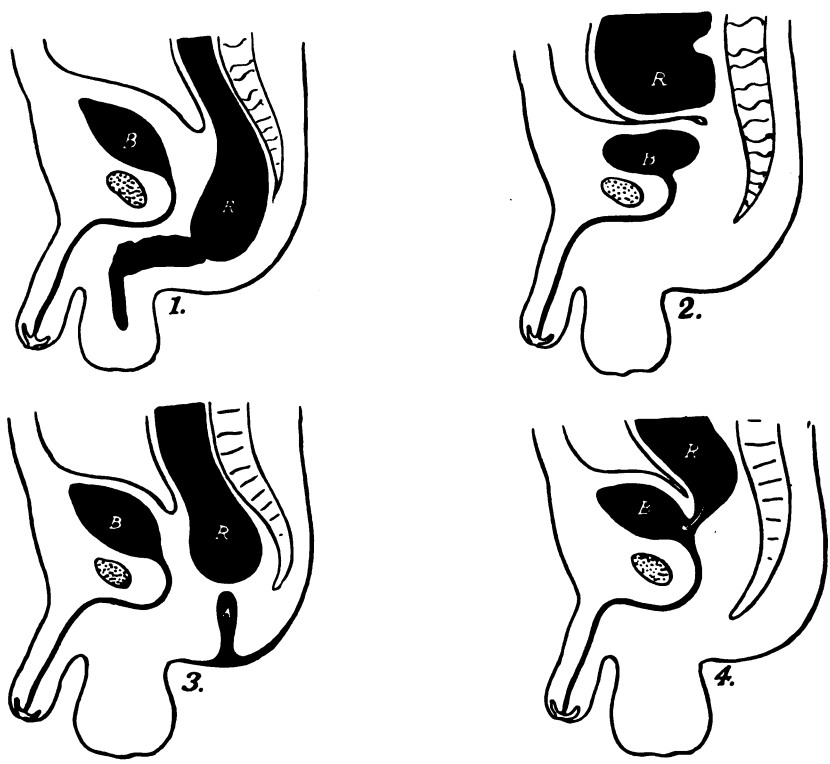

FIG. 209.—VARIOUS FORMS OF CONGENITAL MALFORMATIONS OF ANUS. (See page 346.)

B Bladder; *R*, rectum; *A*, primitive anus. In figure 4 the white arrow shows the communication between the bladder and rectum (Esmarch).

INJURIES OF THE RECTUM.

These may be divided into ruptures and penetrating wounds.

In the former class belong (*a*) those which accompany a fracture of the pelvis, (*b*) those following violent straining during defecation. This is more apt to occur in women who have previously had a rectocele. (*c*) Extension into the rectum of perineal lacerations during parturition.

Penetrating wounds follow stab or bullet wounds, falls upon a picket fence or other sharp object, careless introduction of enema points or of bougies.

In the diagnosis of an injury to the rectum the important points are the history, the accompanying internal or external signs of injury, and the escape of blood or of intestinal coils through the anus or vagina.

Later on there are the signs of infection with the formation of an ischiorectal abscess or of a more diffuse perirectal phlegmon. If the tear passes through the peritoneal attachment the signs of a septic peritonitis appear within a few hours after the injury.

The hemorrhage from a wound or tear of the rectum may be a concealed one, the blood accumulating in the rectum and pelvic colon while the patient shows signs of internal hemorrhage, such as pallor, syncope, rapid empty pulse, restlessness, etc.

In addition to the above mentioned symptoms, a digital examination and the use of a speculum are necessary to confirm the diagnosis.

FOREIGN BODIES IN THE RECTUM.

These may be divided into three classes:

(*a*) Those which have formed within the body, *e. g.*, gallstones, enteroliths, impacted feces. The last named may attain the size of a child's head.

(*b*) Those which have been swallowed, *e. g.*, fish-bones, peach-stones, rings, all sorts of objects swallowed by the insane, such as forks, spoons, nails, balls of hair, etc.

(*c*) Those which are introduced through the anus, either accidentally or with some object in view, such as aiding a bowel movement or in the insane, or in sexual perverts.

The diagnosis may be made in many of the cases if attention has been directed to the rectum through one of the following symptoms:

(*a*) The occurrence of tenesmus accompanied by the passage of blood or mucus in elderly people, who have suffered from obstinate constipation. In others the first signs may be inability to urinate through pressure on the urethra.

(*b*) The occurrence of evidences of an infection of the perirectal tissues.

(*c*) The history of swallowing some foreign body or its introduction through the anus.

One should never neglect under the above conditions to make a thorough digital examination and to combine with it, the use of the speculum.

INFLAMMATORY PROCESSES AND THEIR RESULTS.

These include: (*a*) Pruritus ani, (*b*) proctitis, (*c*) perirectal infection (phlegmons and ischiorectal abscesses), (*d*) fistulas, (*e*) ulcerations, including anal fissure.

Pruritus Ani.—This is often associated with chronic constipation, hemorrhoids, etc., and in some cases, no cause can be found. It causes an intense itching, especially at night. The skin of the anal region becomes of a silvery white color and is greatly thickened. The disease often appears periodically with each menstruation or pregnancy.

Proctitis.—This occurs in an acute and chronic form.

In *acute proctitis* there is (*a*) pain in the rectum radiating to the coccyx, perineum, or thighs. (*b*) Constant straining and the passage of mucus and blood. There is intense pruritus ani. (*c*) Constant desire to urinate. There may be retention of urine. (*d*) Both external and internal sphincters are found markedly contracted when the finger is introduced. The rectum feels hot and is very tender, and if a speculum can be introduced the mucosa is seen to be greatly congested and swollen.

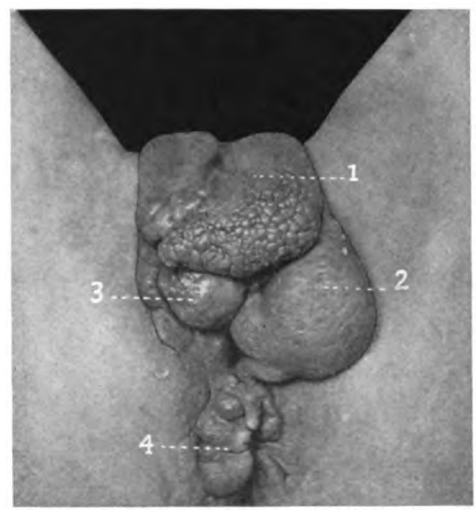

FIG. 210.—MARKED ELEPHANTIASIS OF THE EXTERNAL FEMALE GENITALIA AND SYPHILITIC CONDYLOMATA OF RECTUM.

1, Elephantiasis of the clitoris; 2, elephantiasis of left labium majus; 3, similar condition of right labium minus; 4, syphilitic condylomata of rectum.

Chronic Proctitis.—The most common causes in children are the presence of polypi or of pin-worms; rarely it is due to a congenital syphilis. In adults it either follows an acute attack or is chronic from the beginning, and then is most frequently due to syphilis or gonorrhea, less often to tuberculosis or a prolapse.

There are two forms, a hypertrophic, in which ulcerations and papillomatous excrescences occur on the mucosa, and an atrophic or stenosing form. The two may be combined in some cases. In the latter, which is most often due to syphilis, there is either circumscribed or more diffuse

infiltration of the entire thickness of the rectal wall and of the perirectal tissues, resulting in the formation of strictures (see page 357).

The *diagnosis of the hypertrophic form* may be made if there is a history of a preceding acute attack followed by frequent bowel movements, consisting principally of pus and mucus. This condition may alternate with constipation. In some cases there is but little tenesmus or pain, while in others it is very marked.

Perirectal abscesses and fistulæ very often complicate the clinical picture, especially if the pus cannot readily escape through the anus.

There is in many cases the history of a gonorrhea or the presence of fissures, hemorrhoids, or fistulæ. Examination with the finger or speculum, and in some cases through the proctoscope, will confirm the diagnosis in the hypertrophic form.

From carcinoma, the hypertrophic form can be differentiated by the fact that there is soft mucosa between the individual polypoid elevations. There is also an absence of the marked induration of cancer.

In many doubtful cases a microscopic examination should be made.

Multiple polypi in children and young adults may resemble it, but these are usually larger and there is no ulceration between them. In some cases, if ulcerations exist, it is impossible to make a distinction.

Perirectal Infection.

Diffuse Perirectal Phlegmon.—This may follow insufficient drainage of an ischiorectal abscess or arise through extension of suppuration from neighboring structures like the prostate or uterus.

Most frequently it follows some operation upon the rectum in which infection has occurred.

The diagnosis can be made from the local signs of infection in the tissues around the anus and those of a general infection. These are marked infiltration, redness, pain, and rise of local and general temperature.

In a case recently seen the most marked symptom was a retention of urine through pressure on the urethra. The infiltration may extend over the perineum toward the scrotum and resemble an extravasation of urine, but in the latter there is more involvement of the scrotum, while in perirectal phlegmon the chief external swelling is around the anus. Unless the condition is relieved the septic infiltration spreads and signs of severe general intoxication appear.

Circumscribed Suppuration.—This occurs in other locations than the ischiorectal fossa, and it is often of importance to recognize the exact location of a focus.

These may be divided (Fig. 211) into:

1. Intrasphincteric abscesses, *i. e.*, inside of the sphincter ani.
   (*a*) Subcutaneous.

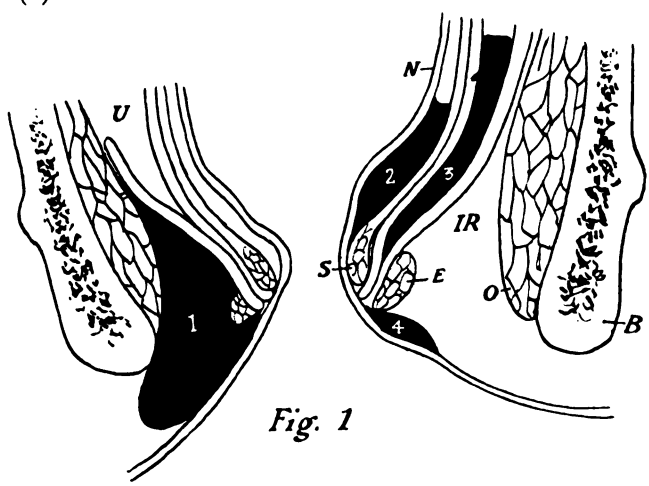

Fig. 1

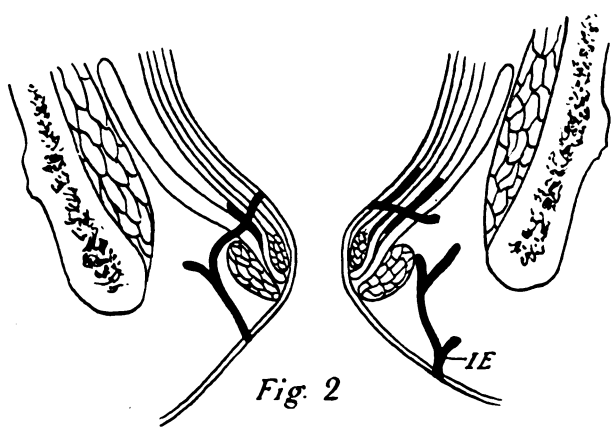

Fig. 2

FIG. 211.—VARIOUS FORMS OF ISCHIORECTAL ABSCESSES AND FISTULÆ.

Fig. 1, Locations of ischiorectal abscesses: *IR*, Ischiorectal fossa; *E*, external sphincter; *S*, internal sphincter; *B*, ramus of ischium; *U*, space above levator ani muscle; *N*, mucous membrane of rectum. The same figures apply to the lower illustration. 1, Most frequent form of ischiorectal abscess, pushing skin of anal region outward; 2, submucous abscess above the internal sphincter; 3, abscess situated above levator ani muscle in pelvic connective tissue; 4, subcutaneous extrasphincteric abscess. Fig. 2, On the left-hand side is seen a complete internal and external fistula. On the right side is seen a fistula situated beneath the mucous membrane and burrowing deeply into the upper portion of the ischiorectal fossa. *IE* of this lower illustration represents an incomplete fistula, having only an external opening.

   (*b*) Submucous.
   (*c*) Both of above combined.
2. Extrasphincteric abscesses (ischiorectal).
3. Abscesses of the superior pelvirectal space (deep-seated).

Diagnosis of Intrasphincteric Abscesses.—The first sign is usually pain referred to the anus, accompanied by tenderness on pressure. Examination with the finger will reveal in the first variety (subcutaneous) an area of quite circumscribed tender induration just beneath the skin and close to the anal margin. In the submucous variety the finger must be inserted through the anus. One then feels a boggy, tender swelling just above the anal margin beneath the mucosa. When these two are combined (submucocutaneous) the external indurated area passes directly over into the one situated within the anal margin.

The local symptoms are accompanied by fever, constipation, malaise, etc.

In many cases the abscesses have already ruptured spontaneously when the patient is examined. One will then find an external fistulous opening which does not lead alongside the rectum, as do the true anal fistulæ. In case a submucous abscess has burst, the opening will be found just above the external sphincter and the cavity lies beneath the mucosa quite superficially.

Extrasphincteric Abscesses.—These are the varieties ordinarily spoken of as ischiorectal. They may follow any of the intrasphincteric forms or arise in the deeper parts of the ischiorectal fossa.

If the infection begins near the skin, the symptoms of suppuration are more marked than if it begins deeply.

There is pain referred to the ischiorectal region in the superficial form, accompanied by tenderness on pressure. The skin over the ischiorectal region becomes red, edematous, and hot, and there are soon evidences of fluctuation.

Frequently the abscess breaks spontaneously.

In the deeper variety the symptoms are often quite obscure at first. There is deep-seated pain accompanied by signs of general infection, such as high fever, prostration, rapid pulse, etc.

If the finger is pressed upon the ischiorectal region either from without or through the rectal wall, there is considerable tenderness. The signs of infiltration of the skin of the ischiorectal region appear at a later period.

If the pus is not evacuated an abscess of the upper pelvirectal space may result, or the pus may travel around the rectum to the opposite ischiorectal region. The abscess may open spontaneously at some distance from the anal margin.

Abscesses of the Superior Rectal Space (Fig. 211).—These may result from suppuration in the prostate, in the periuterine tissue, in the rectum and bones of the pelvis. Abscesses of this space may also be

the result of neglected ischiorectal abscesses, or, on the other hand, abscesses of this space can perforate into the ischiorectal fossa (Fig. 211).

The diagnosis of these abscesses is often very difficult. There is deep-seated pain, fever, and signs of general septic intoxication. Locally there is, in addition to the pain, often retention of urine, constipation, and infiltration of the tissues around the rectum. Through rectal or vaginal palpation one can distinguish the point of greatest tenderness. The differentiation of this variety from abscesses of the prostate, pelvic abscess, or bone suppuration is often very difficult, and at times impossible, except from the history and the fact that the tenderness and induration in this form are most marked in close proximity to the rectum.

Fistula in Ano.

The majority of these follow an infection of the perirectal tissues with abscess formation, whether due to the ordinary pus organism or the tubercle bacillus.

The common varieties are shown in Fig. 211. They are:

1. *Complete.* The external opening is located either close to the anus or at some distance away in the gluteal or perineal regions. The internal opening is usually posteriorly, at the junction of the two sphincters, seldom above it.

2. *Incomplete internal.* There is only an inner opening leading into a blind sinus. These are infrequent.

3. *Incomplete external.* The sinus in the majority of cases lies just beneath the skin, and it is formed from one of the intrasphincteric variety of abscesses described on page 352. There are, however, a number of these which are the result of a complete fistula in which the inner opening has closed.

The rarer varieties of fistulæ are:

(*a*) Complete internal (both openings internal).

(*b*) Complete external (both openings external to the rectum).

(*c*) Rectovaginal and rectovesical.

(*d*) Horseshoe. (The sinus runs around the rectum like a horseshoe. There are often many external openings and branch sinuses running in all directions.)

The diagnosis of a fistula is not difficult if an external opening exists from which pus is discharged. This may cease for a time but reopen again.

The incomplete internal fistulæ cause some pain on defecation and the discharge of pus.

In order to demonstrate the course of a fistula a flexible probe should

be used, aided by the finger inserted into the rectum. *One should never use any force in passing a probe along the tract.*

In the majority of fistulæ the inner opening is located posteriorly, about half an inch above the anus, and can be felt as a depression, or more often a slight elevation. The opening may in rare instances be at any point. At times the injection of methylene-blue into the external opening or the injection of bismuth followed by the taking of an *x*-ray picture (Beck) will aid in finding the inner one.

The presence of openings on both sides of the anus indicates a horse-shoe fistula.

In incomplete internal fistula one feels an induration on inserting the finger into the rectum and a depression where the fistulous opening is located. For the diagnosis of these, the use of a speculum is usually necessary. Tuberculous fistulæ usually accompany the same disease elsewhere, and the external opening is large, lined by pale, flabby granulations, and the edges are bluish and often undermined. Non-tuberculous fistulæ may, however, exist in phthisical patients.

Anal Fissure.

The most prominent symptom of this condition is pain of a severe character on defecation. On account of this pain there is marked constipation. The other symptoms are intense pruritus and reflex disturbances, such as increased desire to urinate. The diagnosis can be made from the severity of the pain on defecation and from the local examination. The latter will often show an acute inflamed external hemorrhoid, the "sentinel pile," on the inner side of which the painful ulcer or fissure can be seen.

In some cases digital examination is necessary. The sphincter will be found tightly contracted and the finger or probe can be made to touch every point until the painful spot is found. The latter is slit-like and has somewhat hard edges.

Non-malignant Ulceration.

These may be (*a*) traumatic, (*b*) catarrhal, following acute or chronic proctitis, (*c*) dysenteric, (*d*) gonorrheal, (*e*) tuberculous, (*f*) syphilitic, (*g*) varicose.

The chief symptoms of all of these are the same as those of a chronic proctitis, viz., the discharge of pus and blood accompanied by diarrhea. The evacuations are usually accompanied by tenesmus and hemorrhage in a greater or less degree.

The diagnosis can be made (*a*) by taking an accurate history; (*b*)

by a careful examination of the rest of the body for evidences of syphilis, tuberculosis, etc.; (*c*) by a local examination. In almost all varieties there is marked contraction of the sphincter. In syphilis ulceration is most frequent in the tertiary stage, and especially marked in the lower part of the rectum. The same is true for gonorrhea. Both cause marked infiltration of the rectal walls and multiple ulcerations.

Tuberculous ulcers have an irregular shape, are of large size, have undermined edges, and the base is not indurated. It is most frequent around the anal margin or close to the external sphincter and is often accompanied by a fistula.

In some cases of rectal ulceration an exact diagnosis of its nature is very difficult, if not impossible.

HEMORRHOIDS.

These are usually divided into:

(*a*) External (covered by skin).

(*b*) Internal (covered by mucous membrane).

(*c*) Combination piles (*a* and *b* combined).

It is important from a diagnostic point of view to distinguish:

(*a*) Those which are secondary to pregnancy, diseases of the heart or liver, uterus and adnexa, or to tumors of the rectum or prostate.

(*b*) Those which are primary.

The diagnosis of hemorrhoids can be readily made in the majority of cases. In the uncomplicated cases the patients complain of a feeling of weight, of an itching or burning sensation and occasional tenesmus. There is but little pain unless an ulcer or a fissure coexists. If internal hemorrhoids prolapse there is some pain until they are returned.

In many cases the patient's attention is first directed to the rectum on account of frequent bleeding. The latter may be quite profuse or be small in amount and occur with every bowel movement, so that the patient becomes quite weak and anemic.

External hemorrhoids are usually visible upon simply exposing the anal region. Internal hemorrhoids are seldom to be seen unless the patient strains or they protrude during defecation or they have become inflamed.

External hemorrhoids are either soft, fleshy, bluish masses, or firm skin tags which cannot be reduced. If of the softer variety they can be caused to disappear by pressure, but the mass rapidly reappears. Internal hemorrhoids are covered with dark red, swollen membrane.

They may be single or multiple, the latter forming a fringe around the anal margin when they are protruded.

Allingham distinguishes three kinds of the internal variety—capillary, venous, and arterial. The first named are deep red, bleed readily and profusely. The venous are quite large, firm, of a pale livid color, do not bleed much, and readily protrude. The arterial are firm, large, bleed readily, and the blood spurts as from an artery.

Of these, the capillary and arterial are rare, the venous being the common variety.

The complications of hemorrhoids are thrombosis, inflammation, strangulation, and sloughing.

Thrombosis usually occurs in the external variety. The hemorrhoid becomes very hard and greatly enlarged. It causes the patient great discomfort and frequent attacks of tenesmus.

Inflammation most often complicates the internal variety. The hemorrhoids become very painful and firm and remain protruded.

Sloughing and strangulation are rare complications.

PROLAPSE.

This condition of protrusion of the rectum is quite frequent in children and in old people, but may occur at any age. It is more frequent in women than in men, associated in the former with general enteroptosis and uterine prolapse. The most common form is a prolapse of the mucous membrane only. This is called a partial prolapse and usually occurs in children.

A complete prolapse of all the coats (Fig. 212) occurs less frequently than the partial form. It is the usual form in adults.

The diagnosis of prolapse is easy. The protrusion embraces the entire circumference of the bowel and is of reddish color with a depression in the center. The partial prolapse of children can be readily reduced and protrudes only when the child strains as at a stool, etc. The complete prolapse remains out most of the time and the mucous membrane becomes very sensitive and bleeds easily. The condition can be distinguished from hemorrhoids by the fact that in the latter the protrusion is irregular and one can feel the separate, soft, dark blue, hemorrhoidal tumors. Epithelioma of the anus feels quite hard and cannot be reduced. The surface is often ulcerated or covered with cauliflower excrescences. An intussusception, when it protrudes, may resemble a prolapse. The finger when passed around the edge of the protrusion will find a groove or sulcus between the skin and the mass, while in prolapse this is absent.

STRICTURES OF THE RECTUM.

These may be divided into annular and tubular, according to whether the stenosis is circumscribed or more diffuse. For diagnostic purposes a good division is into:

1. Extrinsic, caused by pressure from without, as from cancer of the prostate or rectum or from pelvic exudates, or tumors of the bones of the pelvis.

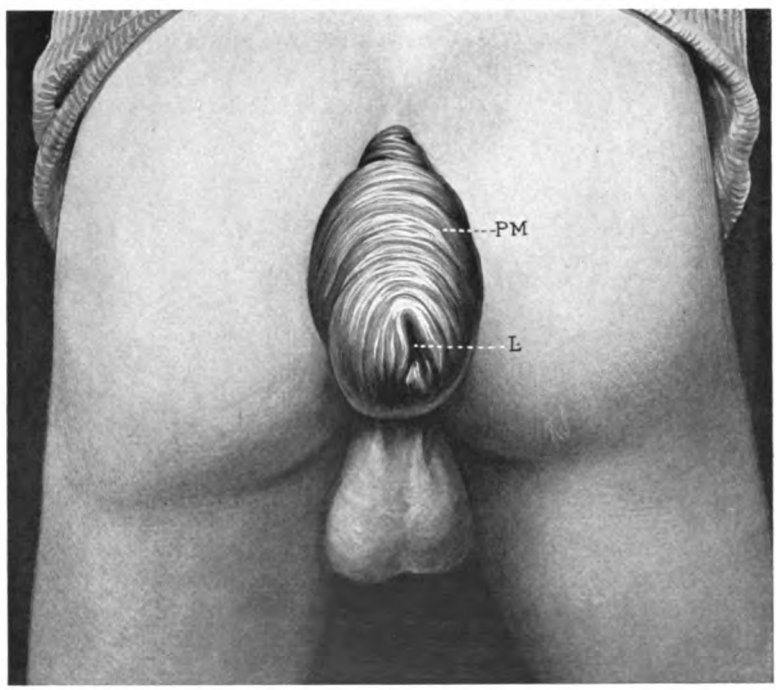

FIG. 212.—COMPLETE PROLAPSE OF THE RECTUM.
L, Depression corresponding to lumen of rectum; PM, prolapsed mucous membrane of rectum.

2. Intrinsic, due most often either to (*a*) syphilis, (*b*) carcinoma, or (*c*) gonorrhea.

Congenital, traumatic, dysenteric, and tuberculous strictures are very rare in their occurrence and their existence is denied by many experienced proctologists.

The diagnosis of the existence of a stricture is not difficult from a consideration of the symptoms and local findings. As to the etiology of any particular case, the question is a more difficult one. The most prominent symptom is constipation, which may increase to complete stenosis, followed by symptoms of intestinal obstruction. In some cases the first symptom is a persistent diarrhea, accompanied by marked

tenesmus. In the non-malignant cases there is a frequent discharge of pus and mucus. Pain is not a prominent symptom, but in the malignant cases there may be marked radiation of pain along the sciatic nerves.

The local examination should be made first with the finger; then, if it is necessary, the speculum or proctoscope may be used. The systematic use of the latter is to be warmly recommended where symptoms of stenosis exist. It should be combined with the examination of the lower rectum with the finger and speculum. One can make an early diagnosis of a high-seated stricture by this means better than by any other.

In making a diagnosis of the cause of the stricture the history is of great value. Syphilis is the cause of the majority of non-malignant strictures, and careful inquiry must be made as to the possibility of an acquired or congenital syphilis. Search should be made for evidence of the disease.

Gonorrheal stricture is more frequent in women and can only be diagnosed from the history and the absence of syphilis. Stricture from extrinsic causes can be diagnosed by the examination of the pelvis, the uterus, the prostate, etc.

To differentiate a non-malignant from a malignant stricture the following table from Ball will be of aid:

DIFFERENTIAL DIAGNOSIS BETWEEN NON-MALIGNANT AND MALIGNANT STRICTURE.—(*Ball.*)

Non-malignant Stricture.	Malignant Stricture.
1. Generally a disease of adult life.	1. Generally a disease of old age.
2. Essentially chronic, and not implicating the system for a long time.	2. Progress comparatively rapid and general cachexia soon produced.
3. The orifice of the stricture feels like a hard ridge in the tissues of the bowel. Polypoid growths, if present, are felt to be attached to the mucous membrane.	3. Masses of new growth are to be felt either as flat plates beneath the mucous membrane and the muscular tunic, or as distinct tumors encroaching on the lumen of the bowel.
4. Ulceration of the mucous membrane may be present, but without any great induration of the edges.	4. Ulceration, when present, is evidently the result of breaking down of the neoplasm; the edges are much thickened and infiltrated.
5. The entire circumference of the bowel is constricted unless the stricture is valvular.	5. Generally, one portion of the circumference is more obviously involved.
6. Pain, throughout the whole course, in direct proportion to the fecal obstruction, and complained of only during defecation.	6. In the advanced stages pain is frequently referred to the sensory distribution of some of the branches of the sacral plexus, due to direct implication of their trunks.
7. Glands not involved.	7. The sacral lymphatic glands can sometimes be felt through the rectum to be enlarged and hard. Inguinal glands hard.

NEOPLASMS OF THE RECTUM.

Polyps.—These are most frequently found in children. They are adenomata, and usually single, with a narrow, long pedicle. Less often they are multiple and sessile.

They may exist for years without causing any symptoms. It is only after they begin to bleed or are caught within the anal orifice that they give rise to symptoms. They may be accompanied by the signs of proctitis (page 349).

Whenever a child strains at stool, without showing evidences of a prolapse, and passes blood frequently, the examining physician should insert the little finger into the rectum and examine the entire circumfer-

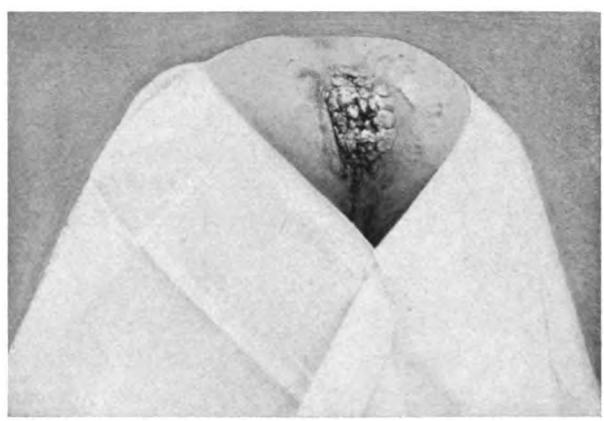

FIG. 213.—NON-MALIGNANT PAPILLOMA OF THE ANUS ("International Text-Book of Surgery").

ence of mucosa. A polyp can be readily recognized as a soft, cherry-like, very movable tumor attached to the mucosa by a narrow pedicle. When they protrude through the anus, their mobility and the presence of a pedicle render differentiation from a hemorrhoid easy. The attachment of the pedicle may be high up in the rectum or even in the sigmoid.

In prolapse the protrusion involves the entire circumference of the anus, has no pedicle, and a distinct tumor cannot be felt.

Broad, sessile polyps occurring in older persons have a tendency to become malignant.

Carcinoma of the Rectum.—This is predominantly a disease of old age, but may occur between fifteen and thirty. There are two forms—the epithelioma of the anus and the adenocarcinoma of the rectum proper. The latter form is thirty times more frequent than the former. Carcin-

oma of the rectum proper arises most often in one of two places: (*a*) In the ampulla, either as a placque-like or as an annular growth; (*b*) at the junction of the rectum and pelvic colon (sigmoid). In the second situation the tumor most often occurs in an annular form. The diagnosis of an epithelioma of the anus is not difficult. It is found either as (*a*) a wart-like, firm tumor with indurated base, involving a variable degree of the circumference of the anal orifice, or as (*b*) a crater-like ulcer with marked indurated edges and base. The age of the patient and the characteristic induration of the growth render a differentiation from ordinary soft venereal warts or hemorrhoids easy. In cancer of the anus there is early induration of the inguinal nodes.

FIG. 214.—CARCINOMATOUS ULCER OF POSTERIOR WALL OF RECTUM.

Observe the papillomatous condition of the edges and the crater-like excavation of the center of the ulcer.

Carcinoma of the rectum proper is more difficult to recognize. There are no characteristic symptoms for this condition, but its presence must be thought of when patients, above forty, complain of diarrhea accompanied by the discharge of pus and mucus, a sensation of weight, pain radiating into the thighs and back, and straining at stool.

In some cases, obstinate constipation alternating with attacks of diarrhea and the occasional passage of blood will be the only symptoms. With both of these clinical pictures there is often a gradual loss in weight and in strength.

If the cancer is located high up near the sigmoid there are indefinite symptoms of enterostenosis, colic-like pains, etc. (page 309). In women such a tumor has been mistaken at times for an ovarian or uterine tumor, or for a displaced uterus. For carcinomata situated in the ampulla digital examination will usually suffice. For those which cannot be reached by the finger, the use of the proctoscope cannot be too

warmly recommended. Bimanual examination under anesthesia is also of great aid for these high-seated cancers. The growth may be felt as a crater-like ulcer with hard edges and base situated only on one side of the rectal wall, or it forms an annular, band-like constriction which causes the rectum to feel board-like and to become firmly fixed to the surrounding structures.

The chief condition from which malignant stricture of the rectum must be distinguished is syphilis. This has been considered on page 358.

RENAL AND VESICAL LESIONS.

THE OLDER AND THE NEWER METHODS OF DIAGNOSIS OF RENAL AND VESICAL LESIONS.

The older methods of diagnosis may be summed up as follows: (1) The clinical picture. (2) The examination of the urine. (3) The objective examination, *i. e.*, palpation, inflation of the colon, etc.

The newer methods include: (1) Cystoscopy. (2) Ureteral catheterization. (3) Chromocystoscopy. (4) Cryoscopy and (5) the phloridzin test. (6) The use of the *x*-ray, with or without the aid of metallic sounds. (7) Electrical conductivity of the urine. (These newer methods are discussed in the chapter upon Methods of Examination.

THE OLDER METHODS OF DIAGNOSIS.

1. **The Clinical Picture.**—This is of value only when the signs are unquestionably those of renal or vesical disease. Symptoms which have been given in the sections upon the diagnosis of these lesions are often deceptive. There may be no pain in renal lesions or it may be referred to the opposite, or healthy kidney. Frequency of urination may be present in both renal and vesical lesions. The pain in both of these conditions may be periodic. As Israel has shown, renal colic may be present both in pyelitis and in acute congestion of the kidneys.

2. **The Examination of the Urine.**—The reaction of the urine is of little value in some cases, because a pyelitis may show an alkaline and a cystitis an acid reaction. In the majority of cases, if blood is present in the urine and is increased by movement, the case is likely to be one of renal colic, whereas a tumor causes spontaneous hemorrhage. This may be reversed (Casper[1]). Again, a severe hemorrhage may be the first symptom of a tuberculosis, or a hematuria can occur without any visible renal lesion. The diagnosis of where pus comes from as deter-

[1] The author is indebted for much valuable information to the excellent book of Casper ("Handbuch der Cystoscopie").

mined by washing out the bladder is also too uncertain. Pus in larger amounts usually means a cystitis, but one cannot draw conclusions from this, since the same may occur in a pyelitis.

One cannot make a diagnosis of the location of a lesion, whether it is vesical or renal, from the presence of the various forms of epithelium in the urine.

3. **Objective Examination.**—Palpation of a renal tumor is of great value, but unfortunately, in many cases of renal calculus, neoplasms, or tuberculosis, one cannot feel anything, especially if the patient be very stout or very thin. The larger of the kidneys may be the hypertrophied one. As was stated on page 305, an enlarged gallbladder or spleen may feel like a kidney. Inflation of the colon should be tried in

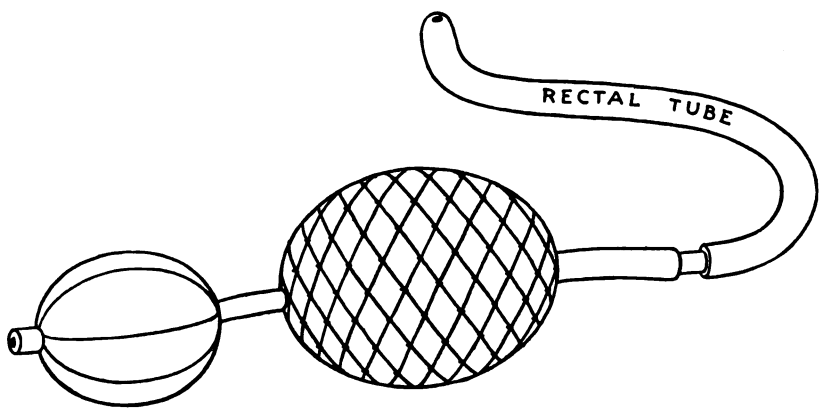

FIG. 215.—APPARATUS TO BE EMPLOYED FOR INFLATING THE COLON FOR DIAGNOSTIC PURPOSES.
The rubber bulb of a Paquelin cautery is joined by means of a glass tube to an ordinary rubber rectal tube.

every case by inserting an ordinary rectal tube into the rectum (Fig. 215) and forcing air through it with the aid of an ordinary bicycle pump or the bulb of a Paquelin cautery. It may, however, be of no value on account of the presence of adhesions or the fact that the colon does not lie in front of the kidney or it may lie over the gallbladder. The lower part of the ureters can often be felt through the vagina.

PYELITIS.

The various causes of this condition must be recalled in making a diagnosis. They are:

1. A cystitis followed by ascending infection of the ureter and renal pelvis. It is most often unilateral.

2. As a complication of renal calculi and of renal tuberculosis. Here it is also unilateral unless the respective condition is bilateral.

3. By extension from neighboring foci of suppuration. Here it is usually unilateral.

4. As a primary condition, *i. e.*, a hematogenous infection.

As will be seen by a reference to these causes of pyelitis, the diagnosis is rather that of the accompanying condition than of the pyelitis itself, in the majority of cases.

Pyelitis may occur in an acute and in a chronic form. Acute pyelitis most often follows ascending infection from the bladder or occurs as a result of hematogenous infection. The diagnosis may be made from the following:

1. Fever. This may be quite irregular and accompanied by recurring chills, or it may be moderate. Often the kidneys are not suspected as the cause of persistent fever, especially in children.

2. Local signs. There are marked pain and tenderness over the kidneys in many cases, but in others there are absolutely no localizing signs of inflammation. Cystoscopic examination shows pus coming from one or both ureters.

3. Urine. There is pus present in large quantities. The reaction may or may not be acid. There is but little albumin present unless a nephritis coexists, and there may be many red blood-corpuscles. The urine is usually decreased in amount and there may be reflex anuria.

Chronic pyelitis is most frequently a complication of renal calculi, tuberculosis, or tumors, or occurs as a complication of a chronic cystitis. If the latter is the cause, a diagnosis of a chronic pyelitis cannot be made unless attacks of acute pyelonephritis occur from time to time, when its presence may be suspected. In the other affections, the diagnosis is made from the cause of the pyelitis.

TUBERCULOSIS OF THE KIDNEY.

It is at present a well accepted fact that the majority of cases are due to hematogenous infection, the disease never being primary in the ureter or bladder.

Clinically there are three modes of onset:

1. Those in which the symptoms of cystitis are present which do not yield to the usual treatment.

2. Those in which the symptoms are those of a chronic pyelitis, *i. e.*, pyuria lasting for years in some cases, before a suspicion of tuberculosis is aroused.

3. Those in which a sudden hematuria is the first symptom.

1. Those with symptoms of cystitis constitute the majority, the patients often being treated for this for a long time. The first and earliest symptom noticed in this class of cases is that there is *increased frequency of urination*, especially at night. Some patients complain of being obliged to urinate immediately, or there is vesical tenesmus and burning at the end of urination and some pain.

2. In the second mode of onset there is a painless pyuria with little or

FIG. 216.—TUBERCULOSIS OF THE KIDNEY IN ITS INCIPIENT STAGE.
1, Caseous broken-down foci at apex of the pyramids in the upper pole of the kidney; 2, miliary tubercles in the cortex.

no bladder irritability, the urine is acid in character and contains tubercle bacilli.

3. In the third class a sudden severe hematuria of brief duration may be the first symptom to direct attention to the kidneys.

Symptoms.—In making a diagnosis one must consider the following symptoms:

1. *The various modes of onset as just described*, so that, in general, pyuria in adults between twenty and forty, preceded or not by signs of bladder irritability, should lead to further examination.

2. *Urinary Changes.*—The reaction is acid, there are but few casts, there is a trace of albumin in the filtered specimen, many pus-cells and tubercle bacilli. In some cases the urine may be quite clear at first. Tubercle bacilli can be best found if several pints of urine are used for

sedimentation and the sediment stained. If this is unsuccessful a guinea-pig should be inoculated.

3. *Pain and Renal Enlargement.*—As a rule, there is but little pain. In some cases there is a dull aching in the lumbar region on one side, for years. In a few cases paroxysmal attacks like renal colic occur, but these are rare.

In the majority of cases there is palpable enlargement of the affected kidney (nineteen in twenty-four cases observed by Israel), to about twice the normal size. Enormous enlargement is infrequent. The kidney, if palpable, is tender, and in thin women one may also feel the greatly thickened ureter as a hard, tender cord.

4. *General Symptoms.*—The entire body should be searched for primary foci. Every patient will show a gradual loss in weight and strength and increasing anemia; this is most marked if both organs are involved. There may be either fever of an intermittent type or a difference of one to three degrees between the morning and evening temperature (hectic type).

The injection of tuberculin is justifiable, and is indicated if tubercle bacilli cannot be found.

5. *Cystoscopic Examination and Ureteral Catheterization.*—The improvements in this direction have greatly aided in making an early diagnosis of this affection possible and their use should never be neglected.

Through the cystoscope one can see ulcerations in the bladder around the ureteral orifices (Kummell). The edges of these are everted, and there is an irregular, dentated, funnel-like ulcer present (golf-hole orifice).

When there are no such vesical changes, only catheterization of the ureters will show the kidney affected, and this can now be done on the suspected side only.

DIAGNOSIS OF RENAL CALCULI.

In some cases renal calculi, like gallstones, may be present without causing any symptoms. There are, in general, two classes of cases:

1. Those in which symptoms directly referable to the kidney appear, as renal colic, hematuria, or anuria.

2. Those in which there are no active symptoms, the so-called quiescent cases.

1. Those in which active renal symptoms appear.

In the majority of these patients it is the occurrence of one or more attacks of renal colic which attracts the attention of the physician. The

first point to determine in these cases is whether the attack had all of the characteristics of a typical renal colic. The second fact is to ascertain by a process of exclusion, whether the attack of pain, etc., might not be due to other renal or ureteral conditions which produce colic.

Renal colic has been discussed on page 270 as an acute abdominal condition. The principal affections from which such an attack must be differentiated have also been referred to These were appendicitis, intestinal obstruction, and gallstones. We must now consider the second question in the diagnosis of active cases, *i. e.*, those producing attacks of renal colic.

FIG. 217.—SPECIMEN OF CALCULOUS PYELONEPHRITIS.

The specimen shows many calculi *in situ* both in the cortex and pelvis of kidney. Note the extensive destruction of the cortex through the suppurative condition following the presence of calculi.

This problem is to exclude all other renal conditions which might cause colic. There are three classes of cases which might cause renal colic. These are: (*a*) Those which produce obstruction of the ureter. These are floating kidney (kinking of ureter), pyonephrosis (plugging of ureter by pus), neoplasms (plugging by blood or tumor masses), tuberculosis (plugging by blood or caseous particles). (*b*) Those which produce colic without obstruction. These are acute congestion, such as occurs in tuberculosis, acute exacerbations of chronic nephritis, pyelitis, hyperacidity of the urine, and nephralgia. (*c*) Colics due to diseases of the ureter, such as ureteritis, strictures, or pressure of tumors from without.

The majority of attacks of renal colic are due to calculi, yet it is well to bear all of these other causes in mind in making a diagnosis. The accompanying symptoms of all of the affections mentioned will usually enable one by exclusion to state that the attack was one of renal colic due to calculi.

In addition to these renal colics, the diagnosis can be made in these active cases from the same symptoms and objective findings as in the quiescent cases.

2. Diagnosis in the quiescent stage, *i. e.*, when no colics are present. These cases occur clinically in two forms.

(*a*) Those in which the symptoms are referred to other organs until a colic or hematuria occurs, *e. g.*, cases treated as floating kidney, cystitis, gallstones, chronic rheumatism, lumbago, intercostal neuralgia, dyspepsia, and uterine or adnexal disease.

(*b*) Those in which there are distinct symptoms referable to the kidneys.

The symptoms of both forms may be one or more of the following:

Pain.—This is either of a continuous or of an intermittent, dull, aching character, referred to the lumbar region, or there is a sensation of weight or pressure. The pain is very commonly spontaneous, but is often increased by exertion, or the pains may occur at a certain hour.

Results of Palpation.—Unless infection has occurred in a calculous kidney, or calculi are combined with a neoplasm or tuberculosis, no palpable enlargement of the kidney is found. According to Israel, such enlargement was found in twenty-two out of thirty cases, due either to septic infection or the result of lipomatous changes.

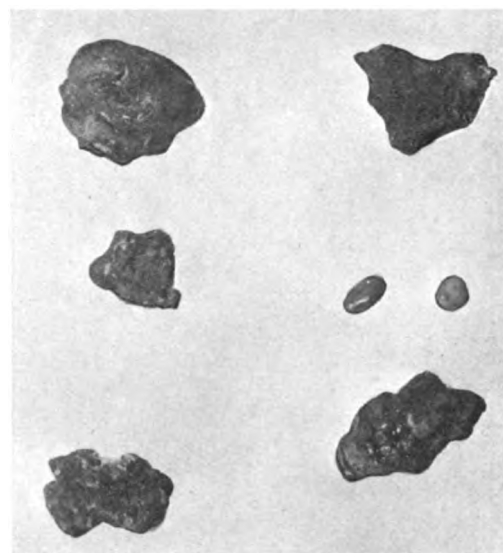

FIG. 218.—RENAL CALCULI AFTER REMOVAL FROM THE KIDNEY.

These are the same as shown in Figs. 217 and 219. Note the variation in size and shape. The round ones, like gallstones of small sizes, can be passed spontaneously, but the irregular ones usually are lodged in one of the calices of the pelvis.

Tenderness of the affected kidney will often be complained of on bimanual palpation. This is most marked at the end of a long expiration. The pain is felt either along the ureter or in the bladder or penis, occasionally in the opposite kidney. The ureter is often tender, especially where it crosses the pelvic brim.

A shaking of the lumbar region or suddenly extending the thigh after it has been flexed on the body will in some cases cause a sharp pain in the affected kidney.

The tension and resistance of the muscles on the affected side is often much more marked than on the opposite one.

Urinary Changes.—Careful search of the urine will at some time show

the presence of red corpuscles. These are generally of the shadow variety, *i. e.*, the hemoglobin has been washed out. There is also a trace of albumin in uncomplicated cases.

The finding of this combination of washed-out red corpuscles and a trace of albumin is the most characteristic urinary finding, according to Israel, in aseptic cases.

If infection of either the pelvis or the kidney has occurred, pus is

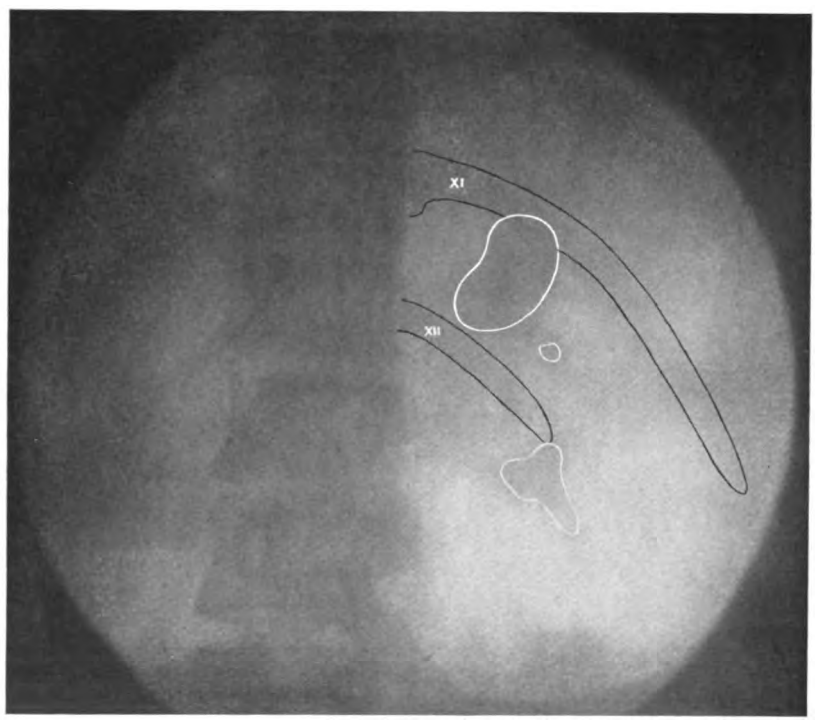

FIG. 219.—SKIAGRAPH OF RENAL CALCULI TAKEN WITH THE AID OF A FOCUSING TUBE.
The shadows of the calculi have been outlined in white. XI, Eleventh rib; XII, twelfth rib.

found in varying quantities. The presence of crystals of uric acid, etc., is of no value.

Hematuria, instead of being microscopic only, may be very profuse and be the first sign of calculus. In such cases a differentiation from tuberculosis, neoplasm, and unilateral or bilateral chronic hemorrhagic nephritis may be very difficult.

In calculus the hematuria is, in general, more dependent on exertion, while in tuberculosis and neoplasms this is not the case. Unless infection has occurred, the urine in tuberculosis is likely to contain both red

corpuscles and pus, and in the latter there are tubercle bacilli. In nephritis there would be casts and a larger percentage of albumin. It is well to remember that both tuberculosis and tumor may be associated with calculi.

The characteristics of the urine in intermittent hydronephrosis have been referred to (page 313).

It is always best to collect the urine for twenty-four hours in every case of suspected renal calculi and examine a centrifugated specimen. One must also remember that the passage of uric acid or oxalate of lime crystals may cause red blood-corpuscles to be present in the urine.

Disturbances in Micturition.—These may be so marked both as to frequency and urgency, that the case is suspected to be one of cystitis. In some cases there is pain on urination referred to the side of the bladder corresponding to the location of the calculus in the kidney.

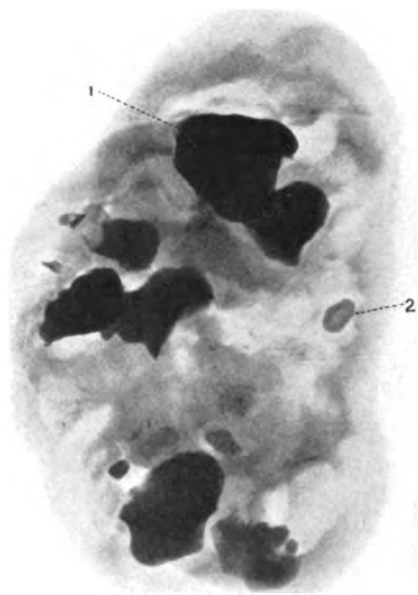

FIG. 220.—X-RAY OF A KIDNEY REMOVED ON ACCOUNT OF EXTENSIVE DESTRUCTION, DUE TO CALCULOUS PYELONEPHRITIS.

The illustration was made by taking the kidney after it was extirpated and laying it upon an *x*-ray plate, and then exposing it to the tube. 1, Renal calculus which casts an intense shadow; 2, small calculus which throws very slight shadow. This is the same kidney as is shown in the *x*-ray, Fig. 219, and illustrates that many renal calculi do not cast a sufficiently deep shadow to be detected in a skiagraph during life. The *x*-ray shown in Fig. 219 reveals only three shadows, whereas the kidney skiagraph taken after extirpation shows many more calculi.

Radiographic Examination.—There can no longer be any doubt that every case of suspected renal or ureteral calculi should be subjected to this method of diagnosis. Instructions as to the preparation of the patient will be found in the special books on this subject.

Calculi differ in the intensity of the shadows which they cause. Oxalate calculi give the sharpest, the urates come next, while phosphatic stones give the least shadow, and pure uric acid scarcely ever gives a shadow.

A kidney may contain numerous calculi and yet only one or two will

give a shadow (Fig. 219). Again, we must not overlook the possibility of calcified mesenteric glands or calcareous deposits simulating the calculous shadows. In the case of ureteral stones, where the error is most likely to occur, this can be eliminated by taking a picture before and after passing a metal ureteral bougie.

At present our standpoint is that with proper apparatus, experience, and not too fat a subject, it is possible to detect both renal and ureteral calculi by this method in the majority of cases. A negative result after repeated exposures excludes the presence of calculi.

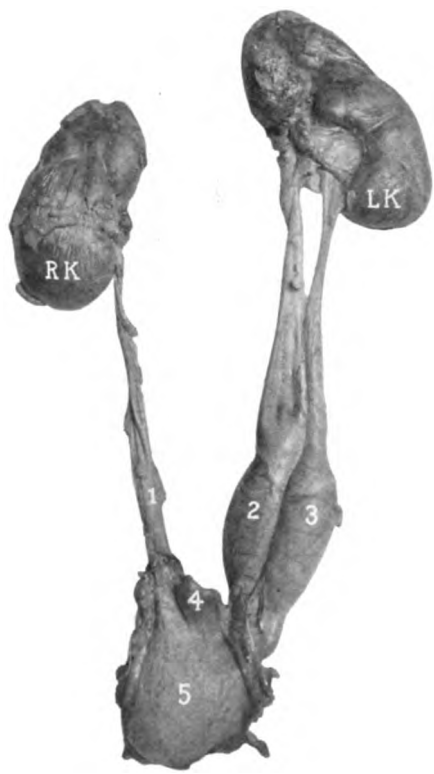

FIG. 221.—SPECIMEN OF DOUBLE URETER FORMATION.

RK, Right kidney; LK, left kidney. 1, Right ureter; 2 and 3, represent the separate ureters present upon the left side; 4, rudimentary uterus; 5, bladder.

Examination of the Bladder and Ureters.—In some cases confirmatory evidence of which kidney the hematuria comes from may be obtained by the use of a cystoscope or the use of the Harris segregator or Luys apparatus. Of these, the cystoscope is the most accurate, but requires the greatest experience and dexterity.

If the hematuria is quite marked ureteral catheterization may be advisable (see page 732).

Anuria.—In some cases a sudden cessation of the secretion of urine may be the first sign of a calculus. Although such a calculus impacted in the beginning of the ureter may be the most frequent cause of anuria, there are other causes which must be excluded, such as bilateral acute or chronic nephritis, obstruction of both ureters by tumors (uterine carcinoma), operations on one kidney and reflex anuria of the opposite one, or anuria due to kinking of the ureter.

The history and accompanying symptoms will usually enable one to make a diagnosis of the cause of the anuria.

THE BLADDER.

CONGENITAL MALFORMATIONS.

Ectopia Vesicæ or Exstrophy of the Bladder.—The most frequent form is the one in which the entire anterior wall of the bladder and the abdominal wall over it is not present.

The posterior wall of the bladder presents itself as a red, easily bleeding mass which projects beyond the level of the surrounding skin (Fig. 222). Associated with it are usually found a non-union of the pubic

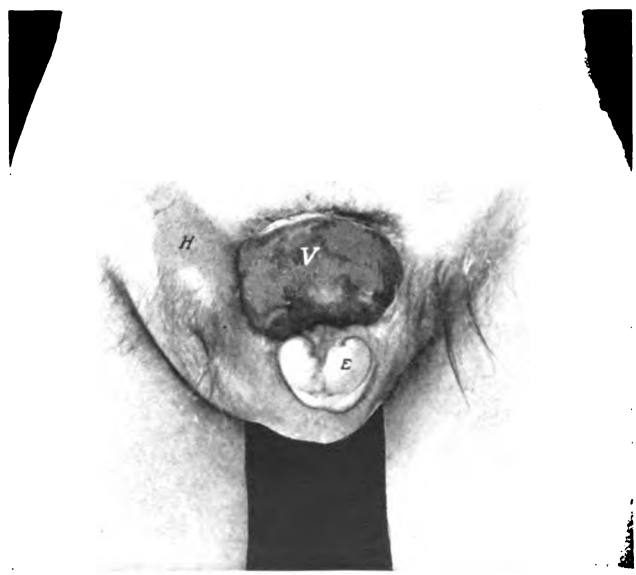

FIG. 222.—VIEW OF ECTOPIA VESICÆ IN SAME PATIENT SHOWN IN FIG. 223.
H, Congenital hernia: *V*, prolapsed posterior wall of bladder; *E*, epispadias.

bones, a lack of development and deformity (epispadias) of the penis, and a congenital hernia (Fig. 223).

The condition can be readily recognized by the red protrusion above the pubis, from which urine constantly escapes, causing irritation of the surrounding skin.

To prove the nature of the protrusion one can lift it up a little and watch the jet of urine escape from the ureteral papillæ and pass fine catheters or probes into these (Fig. 223).

The deformity is more often present in females than in males.

WOUNDS OF THE BLADDER.

The diagnosis of these has been described in connection with injuries of the abdominal viscera in general (page 243).

INFLAMMATION OF THE BLADDER.

Cystitis.—Clinically, the division of cystitis into the acute and chronic forms is the most convenient.

Acute Cystitis.—The most important symptoms from which a diagnosis is made are:

1. *Painful and Increased Frequency of Urination.*—The urine is

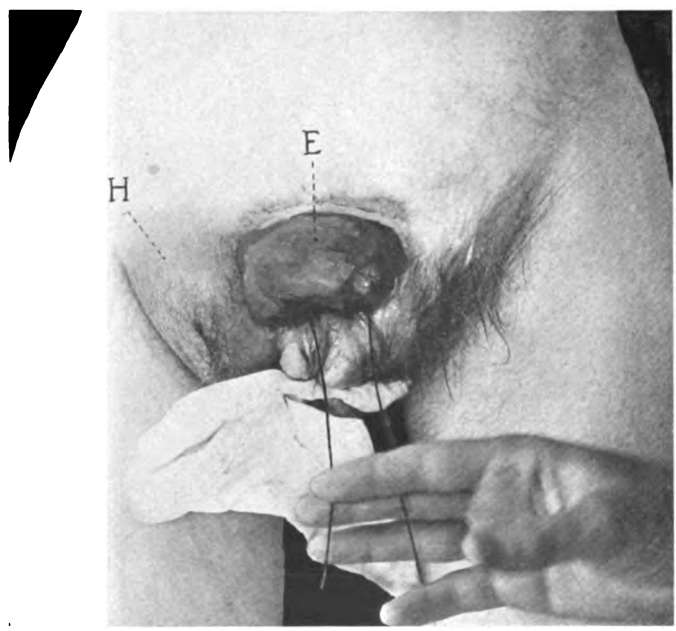

FIG. 223.—ECTOPIA VESICÆ ACCOMPANIED BY EPISPADIAS AND CONGENITAL RIGHT-SIDED HERNIA.

E, Epispadias. Posterior wall of the bladder is seen prolapsed through the hiatus in abdominal wall. H, Congenital right-sided inguinal hernia. Two catheters are shown passing into the left and right ureters respectively. The orifices of the ureters are situated close to the junction of the lower border of the prolapsed bladder with the abdominal wall.

voided at shorter intervals than normal. The patient has the feeling of being obliged to pass the urine immediately after the desire is felt (urgency of micturition). The pain increases with each urination, and the act itself is followed by marked vesical tenesmus, so that the patient in severe cases has an almost constant desire to urinate. Complete retention may occur, only the overflow being involuntarily voided.

2. *Sensation of Weight and Tenderness.*—This is often quite marked in the hypogastric region and perineum.

3. *The Urine.*—In the majority of cases the freshly voided urine is acid, but soon becomes neutral or alkaline. The urine is turbid owing to the presence of large amounts of pus-corpuscles. The more alkaline the reaction, the more marked is the ammoniacal odor and the larger the number of triple phosphates and mucus present.

4. *General Symptoms.*—There is usually a moderate rise of temperature with anorexia and sleeplessness. In some cases the disease is ushered in by a chill followed by a rise of temperature of varying intensity and with irregular exacerbations.

In *diphtheritic cystitis* all of the above symptoms are more marked, especially the pain and ammoniacal urine. The fever runs a course like a typhoid and there are signs of severe sepsis, such as delirium, sweats, and rapid pulse.

Chronic Cystitis.—This arises either from the acute variety or begins as a subacute process which becomes a chronic one.

The symptoms mentioned above are all less marked. Pain is but slight and often consists only of a mild burning sensation on urinating. The increased frequency and urgency of micturition are quite marked, especially after exposure to cold or errors in diet.

After the urine has been passed there is always some residual urine, since the disease is most common where some obstruction exists, such as prostatic hypertrophy or stricture of the urethra or prolapse in women. In those cases which follow an acute cystitis, this residual urine symptom is seldom present. The frequent desire to urinate is especially marked at night.

The urine is often alkaline in reaction, containing much pus, epithelial cells, and triple phosphates.

The complications of acute cystitis are a gangrene of the bladder wall, causing pyemia and death, or the ulceration which may rarely go on to perforation or peritonitis, or an acute pyelonephritis (page 251).

The complications of chronic cystitis are:

(*a*) A pyelitis or pyelonephritis.

(*b*) The formation of abscesses in the bladder wall or of a perivesical phlegmon in front of or behind the organ.

(*c*) The perforation of the diverticula which often form in these cases, causing peritonitis or prevesical abscess (page 232).

(*d*) A chronic condition of septic intoxication called *urosepsis*, from the absorption of toxic products from the decomposing urine. The signs of this are frequently recurring chills followed by profuse

sweats and rise of temperature, vomiting, delirium, and a gradual loss in weight.

Differential Diagnosis of Cystitis.—*Renal Suppuration.*—Although there are bladder symptoms, these appear and disappear without any special cause, while the quantity of pus remains constant and is greater than in a cystitis.

Posterior Urethritis or Prostatitis.—In both of these conditions, as in acute cystitis, there is increased frequency of and painful micturition. The other differential diagnostic points are given on page 381.

TUBERCULOSIS OF THE BLADDER.

This condition is secondary to the same affection in the kidneys in both sexes, or in the male may, in addition, be secondary to a primary focus in the testis with resultant ascending infection. A primary tuberculosis is very rare.

In the majority of cases the disease apparently occurs spontaneously. A hematuria may often be the first symptom, followed by painful and increased frequency of micturition. The blood is passed in large clots and is not intimately mixed with the urine, as it would be in a renal hematuria. In other cases the vesical tuberculosis develops in a latent manner as a complication of a gonorrheal cystitis. The urine in the early stages is acid and there is but little pus; later it is alkaline and there is considerable pus and mucus. Tubercle bacilli may be found in centrifugated specimens if a large quantity of urine is used, or some of the pus can be injected into a guinea-pig.

The diagnosis is easy if the above symptoms are found in a person who has a primary focus of tuberculosis elsewhere which can be readily detected.

Every pyuria or hematuria occurring in young persons without any apparent cause should lead to the suspicion of a vesical or renal tuberculosis. Hematuria due to cancer occurs at an older period, while that due to calculi usually ceases when the patient is kept quiet, while rest has no influence on the hematuria of tuberculosis.

By the aid of the cystoscope one can detect ulcerations at the orifices of the ureters and the neck of the bladder. The presence of renal symptoms and the escape of pus from the corresponding ureter help to confirm the diagnosis. The crucial test, however, is the discovery of tubercle bacilli either by staining or the guinea-pig inoculation test.

VESICAL CALCULI.

The characteristic symptoms of stone in the bladder are pain, hemorrhage, and disturbances of micturition. These are very frequently combined with the symptoms of chronic cystitis, or of hypertrophy of the prostate, so that the clinical picture becomes a complex one.

(*a*) The pain is felt in the end of the penis, especially toward the end of urination, or the pain may be felt at the neck of the bladder, especially upon exertion or sudden jarring of the body. The pains may radiate to the rectum, testis, or thigh.

If the calculus is pointed and becomes fixed in the meatus internus, the pain is often excruciating, and is increased by each vesical contraction.

(*b*) Micturition is seldom normal. There is usually increased frequency. If the stone is small the stream is often suddenly interrupted. In some cases there is enuresis, in others retention of urine, especially if the calculus becomes wedged in the internal meatus. Obstinate enuresis and dysuria are often the first signs in children.

(*c*) Condition of urine. This contains pus and mucus, varying according to the degree of cystitis. Blood in small quantities is often mixed with the urine, especially after any exertion. One specimen may contain blood and the next be perfectly clear. In general, the hematuria is never as marked nor as continuous as in neoplasms or tuberculosis, unless the latter coexist.

In children, prolapse of the rectum and straining at stool or in urination, or the presence of herniæ, should lead to the suspicion of calculi. The history of a previous renal colic may be of great value. The diagnosis of vesical calculus can be confirmed by one or more of the three following methods of examination:

(1) The use of a specially constructed sound called the "Thompson stone searcher" or the ordinary metal urethral sounds of varying sizes.

The bladder should contain two ounces of fluid in children and four ounces in adults, the organ having been previously irrigated with boric acid solution through a soft-rubber catheter. Some 2 per cent. eucain solution is injected into the deep urethra. If the bladder is very sensitive a general anesthetic should be given. If the urine is ammoniacal, the examination should be preceded for a few days to a week, if possible, by daily irrigations and the internal use of urinary antiseptics. The bladder should be systematically explored. The horizontal position with elevation of the pelvis is best suited for these cases.

If the prostate is enlarged, a sound with a much larger curve is necessary. When the sound strikes a stone, there is a sharp metallic click.

A stone which is hidden in a diverticulum or deeply in the retroprostatic pouch is often found with great difficulty. The former may be suspected if the sound only strikes it in one position and cannot be made to pass around the calculus.

(2) Cystoscopic examination. This is an almost infallible method, and is especially valuable in the case of calculi which lie in diverticula, or for foreign bodies in the bladder. Its use may be very difficult if there is much cystitis or marked prostatic hypertrophy.

(3) Skiagraphic examination. This method has been used considerably since the introduction of the *x*-ray. As in the cases of renal calculi, phosphatic, oxalate, and cystin give deep, while urate and uric acid calculi only cause light shadows. The method is only of value if the result is a positive one. No reliance can be placed upon a negative picture.

TUMORS OF THE BLADDER.

These are divided clinically into the benign and malignant. The majority of the former are papillomata made up of long pedicles or sessile, warty tumors with a broad base. They may be single or multiple and are most often situated near the trigone, and not infrequently become malignant in character. Of the malignant, the majority are primary either in the prostate or in one of the neighboring structures (rectum, uterus, etc.). The diagnosis of a vesical neoplasm may be made from the presence of (*a*) sudden hematuria which is not renal in origin, accompanied by pain and disturbances of micturition, and (*b*) the results of the examination of the urine, and of cystoscopic and rectal examination.

(*a*) The hematuria may be the first symptom, as it is of other renal and vesical conditions (calculi and tuberculosis). In tumors it is the first sign of the condition in the majority of cases. If the blood comes from the kidney it is intimately mixed with the urine, has been accompanied by colic, and there are often worm-like coagula. In hemorrhage from the urethra the liquid or clotted blood precedes the voiding of urine. In bladder hemorrhages the first urine contains but little blood, but the amount is gradually increased until pure blood is evacuated.

The hematuria from benign tumors is often intermittent, occurring without any cause, is not increased by exertion, and is bright red. In malignant growths the hemorrhage is more persistent, smaller in amount, and more brownish in color.

Frequency and urgency of micturition are generally absent in smaller

benign and malignant growths. In larger ones there is often great difficulty in micturition and even retention of urine.

Pain is generally absent in papillomata and is not marked in the carcinomata until the infiltration is extensive or the bladder becomes infected. It is then not only present during, but also between, urination.

The discovery of some of the villi of a papilloma is one of the most positive signs, but this is not often found. In the malignant tumors which are primary in the prostate, rectal examination will show a much harder, stone-like enlargement of the gland than is the case in ordinary hypertrophy. In a recent case the writer was led to suspect a malignant prostate from the palpation of very firm lymph-nodes in both inguinal regions of a cachectic man who had bladder symptoms. Rectal examination revealed, in addition to the hard prostate, a stricture due to the extension of the growth around the rectum.

In a recent article on cancer of the prostate, Young [1] calls attention to this stony induration, as well as to a similar condition of the seminal vesicles.

Cystoscopic examination is of great value. It is very difficult to examine the bladder in cases of villous tumor, owing to the hemorrhage, but if this latter is not too great, the view obtained confirms the diagnosis.

In malignant tumors without marked projection above the level of the bladder wall, the diagnosis with the cystoscope is very difficult, but even in these cases it is often confirmatory, especially in disease of the prostate which has invaded the trigone.

Wherever there is any doubt as to the nature of the tumor an exploratory suprapubic cystostomy is advisable in order that an early diagnosis be made.

AFFECTIONS OF THE PROSTATE.

ENLARGEMENT OF THE PROSTATE.

Increased frequency of urination, often first noticed at night, in a man above forty, directs attention to the bladder and prostate. There is not only a desire to urinate more frequently, but a feeling that it must be passed immediately. The act requires longer than usual, and the stream lacks the force of a normal individual.

Retention of urine may begin gradually, the patient being able to pass less and less. It often begins suddenly after exposure to cold, debauches, or voluntary retention of the urine for a long period.

Pain is not a symptom of this condition until a cystitis has begun.

[1] "Johns Hopkins Hospital Bulletin," October, 1905.

Hematuria may at times be very profuse from the varicose prostatic veins around the neck of the bladder. With the above history one can usually confirm the diagnosis by a systematic objective examination.

This should include:

1. Palpation of the prostate through the rectum to determine the extent of the enlargement in this direction, whether one or both of the lateral lobes are involved, and the consistency and nature of the enlargement. A fibrous prostate is but little enlarged and is very firm and fixed. An adenomatous prostate is larger, softer, and more movable.

2. Combined examination by the use of a metal catheter inserted into the bladder, while the index-finger is introduced into the rectum. In passing the catheter the following points, according to Deaver, favor the diagnosis of enlarged prostate. (*a*) Undue depression of the shaft is necessary before the catheter enters the bladder. (*b*) The length of the urethra, *i. e.*, before urine comes, is more than eight inches. (*c*) The catheter is deviated to one or the other side by the unequal lateral lobes. (*d*) If an obstruction is encountered at a distance of more than seven inches from the external meatus, showing that the obstruction is not due to strictures which never occur in the prostatic urethra.

3. Determination of the amount of residual urine by allowing the patient to evacuate the bladder and then inserting either a metal or a special prostatic catheter, known as the Mercier, with a short beak, and allowing the residual urine to escape.

4. A thorough examination of both the quantity of urine passed in twenty-four hours and its constituency.

5. By rotating the metal catheter around in the bladder gently, one can gain an idea of whether it is dilated or contracted, and also whether any calculi exist. A contracted bladder accompanies a fibrous, a dilated an adenomatous prostate.

6. The cystoscope is of great confirmatory value if it can be used, although this may be very difficult.

Differential Diagnosis.—*Cancer of the Prostate.*—The induration of the enlargement as palpated per rectum is more stony and involves the seminal vesicles at an early period in a similar induration.

There is often early, sharp, shooting pain along the inner side of the thighs or along the sciatic nerves. It also causes early cachexia, and cystoscopic examinations fail to detect much enlargement toward the bladder unless a previous benign enlargement has existed. The inguinal glands are also of stony hardness and enlarged. *Sarcomata* are very rare and grow very rapidly.

Polyps of the Bladder (*Fibrous*).—These are quite rare and cause

obstruction symptoms like an enlarged middle lobe. Rectal palpation usually shows an absence of enlargement of the prostate. The frequency of hematuria and a cystoscopic examination will aid in distinguishing it.

Tuberculosis of the Prostate.—This may cause enlargement of, and the formation of nodules in, the prostate. The disease is rarely primary. The diagnosis may usually be made from the presence of the same disease in the epididymis and the fact that it generally occurs at an earlier age than prostatic hypertrophy.

The diagnosis of carcinoma of the prostate has been considered on page 378, while that of tuberculosis of the prostate will be referred to in connection with the same disease in the male productive organs (page 379). Inflammations of the prostate are discussed in connection with their most frequent etiologic factor, viz., gonorrhea (page 381).

INJURIES AND DISEASES OF THE URETHRA AND PENIS.

CONGENITAL MALFORMATIONS.

Epispadias and Hypospadias.—Both of these deformities can be readily diagnosed. In *epispadias* there in an imperfect formation of the upper wall of the urethra (Fig. 222). There are three forms: (*a*) One in which only the glans penis is involved. This is so rare that only three genuine cases have been described. (*b*) The groove extends back to the middle of the penis. (*c*) The most frequent form. This form is usually associated with an ectopia of the bladder and a defect in the pubic symphysis (Fig. 223). The penis and the groove on its upper surface are very short and pass directly over into the bladder defect. *Hypospadias* is much more frequent than epispadias. The deformity is due to a defective formation of the lower wall of the urethra. There are also three forms: (*a*) The gap or groove involves only the glans penis (hypospadia glandis). (*b*) The groove extends back as far as the beginning of the scrotum. The urethral orifice is at the latter point. This form is less frequent than the first named and is called the penoscrotal form. The penis is usually curved down and laterally. (*c*) The scrotum is more or less completely divided into two lateral halves. The urethral opening is in the perineum or in the groove between the divided scrotum (perineoscrotal form). The penis is very short and bent downward and the foreskin, as in the penoscrotal form, shows a wide gap.

CONTUSION AND RUPTURE OF THE URETHRA.

This condition usually follows a fall upon some object like a plank or an axle, these coming in direct contact with the perineum. It may also follow a blow or kick in the same region, or the perineum may be torn as a result of a fracture of the pelvis. The urethra at the bulbomembranous junction is caught between the unyielding pubic symphysis and the object upon which the patient falls. For this reason the tears are most often located at this point.

The probability of a rupture of the urethra must be thought of in every case either of blunt force applied to the perineum, or an injury in which the pelvis is crushed.

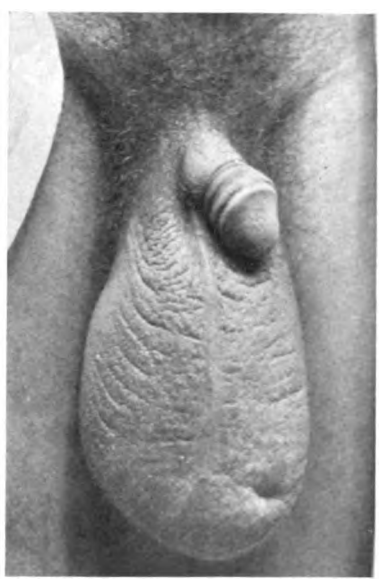

FIG. 224.—ENORMOUS ELEPHANTIASIS OF THE SCROTUM, FOLLOWING TRAUMATIC RUPTURE OF THE URETHRA.

This is the front view of the patient shown in Fig. 225.

The cardinal signs from which a diagnosis can usually be made are:

1. The appearance of a hematoma or of a swelling in the perineum.

2. The escape of blood from the meatus either with or independently of urination. If it occurs with the latter, blood escapes before urine begins to flow.

3. There is either retention of or great difficulty in urinating and the act is accompanied by great pain in the perineum and at the end of the penis. The urine contains coagulated and fluid blood.

4. Urinary infiltration of the subcutaneous tissues, penis, scrotum, and anterior abdominal wall. This causes marked swellings, redness, and tenderness of the corresponding parts, and may be followed by severe septic infection or even gangrene. Such extravasation may occur immediately after the accident or gradually in the course of a few days. In the milder cases of rupture of the urethra there is but little bleeding from the meatus, the urine is almost clear, and there is only a slight amount of perineal swelling.

The diagnosis of the more severe forms depends upon the observation of the large amount of blood from the meatus, the perineal hematoma,

the difficult and painful micturition, and at times the urinary infiltration with accompanying sepsis.

Traumatic rupture of the urethra may be followed by strictures and perineal fistulæ (Fig. 225), whose diagnosis is the same as that of the same conditions when due to gonorrhea (page 381). If a patient gives the history of a fall followed by difficulty of urination, one must always think of a stricture. When a tear of the urethra coexists with a rupture of the bladder and fracture of the pelvis, as in one of my cases, the diagnosis is very difficult, but can usually be made by a careful study of the physical findings.

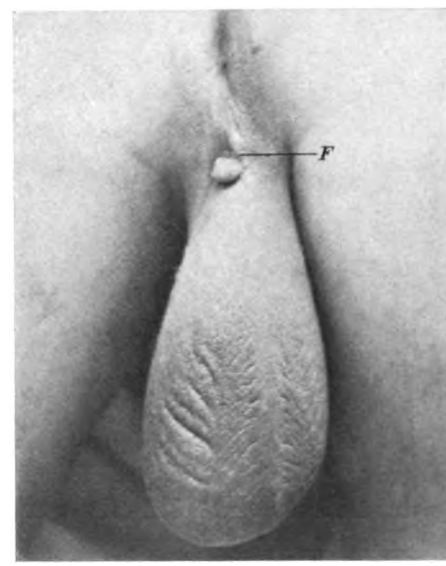

FIG. 225.—POSTERIOR VIEW OF PATIENT SHOWN IN FIG. 224. SUFFERING FROM ENORMOUS ELEPHANTIASIS OF SCROTUM.

F, Opening of perineal fistula, which resulted from traumatic rupture of urethra and stricture subsequent to same.

LOCALIZATION OF PUS IN THE LOWER PORTION OF THE MALE GENITO-URINARY TRACT (FIG. 234).

The question whether pus and detritus, causing the urine to be turbid, originate in the anterior or posterior urethra or in the appendages of the lower urinary tract can be answered in one of the following ways:

The Two-glass Test.—After a patient has held his urine for some considerable time—two to four hours—he is advised to empty some of the urine into one glass, then to stop and to void the balance of the urine into another glass (Thompson test).

In a general way it can then be stated that, if only the first portion is turbid or shows floating shreds or flakes, the pus comes from the anterior urethra alone. If both portions are turbid or contain shreds or flakes, the posterior urethra is necessarily involved in the inflammatory process. Pus production in acute gonorrhea is usually so profuse that the first and second portions will be rendered turbid even if the affection is located in the anterior urethra only. The reason for this is that the posterior urethra does not permit the accumulation of any considerable amount of secretion in its lumen. At the very moment that secretion accumulates,

it flows back into the bladder. In this way the secretion becomes mixed with the urine contained in the bladder.

The first portion of urine voided flushes out the anterior urethra, carrying off the adherent pathologic products. Unless secretion flows back from the posterior urethra into the bladder, the second portion of urine will appear clear. The conclusion to be drawn from this rather crude test must be subjected to the following criticism:

A very thick secretion originating in the anterior urethra may still adhere to the mucous membrane after the first portion of urine has passed. Thus the second portion may also contain flakes of pus that originate in the anterior urethra. Again, at the time of the test there may be very little production of pus in the posterior urethra, so that the second portion of the urine appears clear, although there is still disease in the posterior urethra. The two-glass test is only of value if it is employed repeatedly and at different visits.

The principle of this test can be applied in a more refined manner in the following way: The test is best made early in the day. After the patient has retained his urine for some considerable time, the anterior urethra is washed out with sterile water, either by using a soft-rubber catheter whose tip does not reach beyond the spongy portion of the urethra or by applying a Valentine nozzle without overcoming the resistance of the compressor urethræ. This flushing is continued until the returning fluid appears to be absolutely clear. Then the urine is voided; all impurities contained in this specimen necessarily come out of the posterior part of the urethra.

Another valuable addition to this method is as follows: If it is desirable to gather information as to the question whether secretion comes from the prostate or the seminal vesicles, the anterior urethra is first flushed out in the manner described above. The patient should then pass half of the contents of his bladder. The index-finger is now introduced into the rectum, and the prostate and the seminal vesicles are milked, and the patient then voids the balance of his urine.

The flushing liquid used for the irrigation of the anterior urethra contains the pathologic products of this portion. The first portion of the urine voided contains the products of the posterior urethra. The second portion of the urine voided contains the contents of the prostate and of the seminal vesicles. Pathologic products squeezed out of the seminal vesicles have a characteristic serpentine or twisted shape.

In very chronic cases, which show scant secretion, some additional means must be employed in order to find the seat of pathologic products.

In order to stimulate secretion for twenty-four hours previously to

executing the test, irritating irrigations of the entire urethra are administered—1 to 10,000 bichlorid solution or 1 to 5,000 silver nitrate solution.

At the same time the patient is advised to drink some alcoholic beverage the evening before the examination, such as beer or champagne. The pathologic products from infiltrated portions of the urethra are collected by first introducing an olive-tipped sound; all the places at which the sound shows some engagement are squeezed out over the olive tip by two fingers massaging the urethra from the outside.

The resulting discharge is treated in the manner above described. While it is easy and simple to examine specimens of the discharge microscopically as to their structure, the search for gonococci, particularly in chronic cases, not only calls for frequent examinations of numerous specimens, but even then may be negative.

In all doubtful cases the culture test for gonococci should be employed.

Instrumental Examination.—In all acute inflammatory processes of the urethra instrumental examination is contraindicated. The most convenient instrument for endourethral examination is the elastic bulbous bougie, Guyon's "explorateur à boule olivaire" or bougie à boule. The bougie à boule carries on its slender shaft an olive-shaped head which is conical at its digital end and sharply cut off at its proximal end. The olive, of the most frequently used bougies, has a diameter of 18 to 20, French scale; it is well to have a whole set, these bougies ranging in size from 8 to 26. *In the normal urethra* the bougie passes the anterior part smoothly and without any resistance; at the isthmus the head encounters a slight obstruction; on passing it the patient becomes sensitive to the touch. In the whole length of the membranous urethra the bougie moves slightly engaged; in the prostate it glides easily until we get to the internal orifice, where we feel a slight interference just before it enters the bladder. In some cases the bougie may also be caught in the sinus pocularis.

While passing the prostatic urethra the patient usually has a desire to urinate. The largest diameter of the head of the bougie being at its proximal end, the obstructions of the urethra are felt more distinctly on retracting than when the bougie is introduced. The meatus is often so narrow that we have to cut it for some distance before making an examination. The bulbous urethra is occasionally very wide in the young and often in the old, and catches the end of an inelastic instrument as though it were in a blind pouch. This obstruction may be overcome by stretching the penis. Right behind the bulb is the isthmus, which is usually easy to pass, except in nervous individuals, in whom the membranous urethra is generally hyperemic, and we get reflex spasmodic contrac-

tion of the compressor urethræ. Patience and perhaps a few drops of cocaine solution will overcome this obstruction. Any obstructions in the course of the urethra, except those named above, are pathologic. In strictures we feel friction and unevenness; it feels as if the bougie jumped over a hard string. If a stricture which is too narrow for the bougie to pass has been found, then filiform bougies are resorted to, starting with the smallest number and gradually increasing to larger ones until the diameter of the stricture is found. Many strictures are sharply limited and stand out prominently from the healthy or less infiltrated surrounding mucous membrane of the urethra, and a filiform bougie introduced is just as likely to be caught in a pocket of the mucous membrane as to enter the narrow passage of the stricture somewhere in the middle. It is, therefore, a good plan not to try to pass the stricture with the first bougie introduced; if it catches in a pocket, introduce the second bougie, and so on until either all of the blind pockets are filled out with the bulb of the bougie or until one accidentally enters the stricture.

We can use conical or cylindrical metal sounds instead of the bougie, but they will not give as much information as the bougie. Infiltrations due to chronic gonorrhea are detected by having the sound in the urethra and palpating with the hand on the surface. The membranous and prostatic urethræ can be palpated through the rectum.

From the foregoing, it is clear that the introduction of a bougie into the urethra not only permits us to find out the degree of sensitiveness and smoothness or unevenness of the urethral mucous membrane, but it also gives direct means to determine the length of the urethra. Most convenient for this purpose are Kutner's graduated bougies.

The diameter of the urethra in its different parts can accurately be measured with the end of the urethrometer. The oldest and most frequently employed is that of Otis. Of newer date is the urethrometer of Kollmann; the latter, in addition, can be used as a dilator for short distance.

Urethroscopy.—The pathologic changes in a large percentage of cases of chronic gonorrhea consist in widespread infiltrations of slight degree, but nevertheless they may cause serious disturbances. In other cases the pathologic changes are confined to small, inflamed, suppurating conglomerations of glands or crypts of Morgagni, which, in spite of their small size, are the carriers of virulent infection and the cause of constant discharge of pus. On the other hand, it is not necessary that they betray their presence by any apparent symptoms. There is no secretion and the urine does not contain any filaments for weeks, months, or even years.

Suddenly the patient is attacked by an acute gonorrhea without having exposed himself to infection. Such cases are not rare in every-day practice. The endourethral examination with the bulbous bougie, the sound, and the urethrometer, while otherwise of great service in making a diagnosis, will give little information in these cases; they remain, therefore, a mystery to the insufficiently equipped physician, and this is what gives chronic gonorrhea the name of being incurable. We must first make a correct diagnosis before we can successfully treat a disease. The most important instrument with which to make a thorough examination is the urethroscope.

PHIMOSIS.

This is an abnormal narrowing of the foreskin, so that it cannot be retracted to expose the glans. It is most often a congenital condition, but may be acquired as the result of gonorrheal inflammation or chancroidal ulceration beneath the prepuce.

The chief interest from a diagnostic point of view is in the results of the phimosis. These are: (*a*) Recurrent attacks of balanitis from accumulation of smegma. (*b*) Prolapse of the rectum or a hernial protrusion as the result of straining. (*c*) Formation of preputial calculi. (*d*) It favors the development of an epithelioma through irritation of the secretions.

PARAPHIMOSIS.

Whenever a tight foreskin has been drawn back over the glans penis and is not allowed to slip forward again, a *paraphimosis* results. This is due to the formation of a contraction ring in the retracted foreskin which prevents the blood from returning toward the root of the penis, causing marked swelling. The condition can be readily recognized from this swelling, which lies just behind the corona glandis and is separated from the main body of the penis by a deep groove corresponding to the contraction ring. The longer the paraphimosis lasts, the more swelling, so that the groove or contraction ring may be entirely hidden. It may be followed by gangrene of the foreskin.

BALANITIS.

This is the result of an infection of the inner or mucous layer of the prepuce. The entire prepuce is swollen and tender so that it can only be retracted with difficulty. The glans penis and inner layer of the prepuce are both reddened and ulcerated, and a foul purulent discharge

is present. The retention of secretion may lead to deep ulceration and gangrene of the prepuce. This condition is at times the first sign of the presence of a diabetes.

EPITHELIOMA OF THE PENIS.

This occurs late in life. It occurs usually in one of two forms, either as a cauliflower-like growth (Fig. 226) or as an ulceration with undermined and markedly indurated edges. The former is the more frequent. If it is present with a tight prepuce the diagnosis may be made from the purulent discharge, by palpating the induration through the intact prepuce, and by the indurated, enlarged inguinal lymph-nodes. A little later, when the tumor has penetrated the prepuce, the diagnosis is much easier. The discharge may be the first symptom which calls the patient's attention to his condition.

FIG. 226.—TYPICAL PAPILLARY CARCINOMA OF PREPUCE PERFORATING OUTER LAYER OF SAME.

The second or ulcerative form resembles somewhat the carcinomata of the lip with their crater-like ulceration, indurated bases, and edges.

In the differential diagnosis of the cauliflower form one must consider venereal warts. These are softer and there is no induration of the base or of the inguinal lymph-nodes. *From the ulcerative form* one must differentiate a chancre and a gumma. In neither of these are the edges or base as hard as in carcinoma. In chancre there may be enlargement of the inguinal nodes, but they are never as indurated, and the primary lesion is followed by other secondary symptoms within a few weeks. If any doubt exists, the administration of antisyphilitic remedies will soon clear up a chancre.

In the case of a gumma of the penis the same clinical findings hold

true. The edges or base are never as indurated, there are no enlarged inguinal nodes, and there is usually the history of syphilis or evidence of its presence elsewhere. The administration of potassium iodid should cause a marked difference in the appearance of the ulceration within a week.

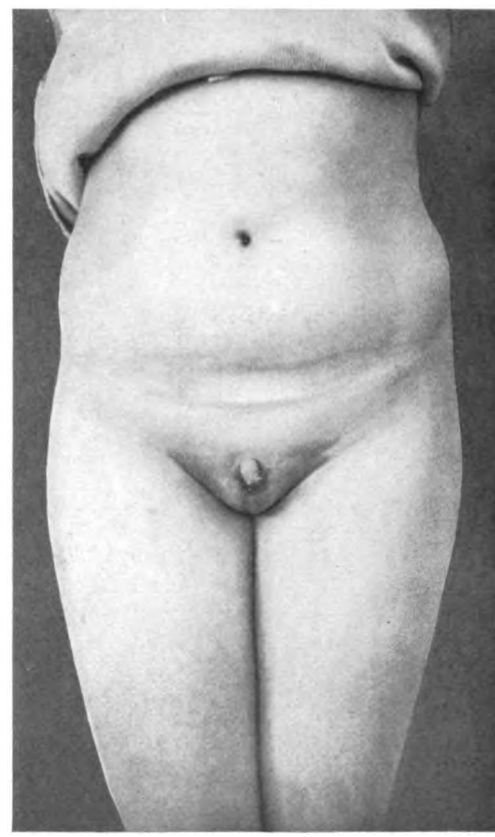

FIG. 227.—INFANTILISM IN A PATIENT, THIRTY YEARS OF AGE, DUE TO NON-DEVELOPMENT OF TESTES, WITH NORMAL DESCENT OF THESE ORGANS.

THE TESTES.

ABNORMALITIES IN DEVELOPMENT.

A lack of development of the testis may occur in an imperfectly or in a perfectly descended testis. It is more frequently associated with the former, but it must not be assumed that every testis which has not reached the scrotum is incapable of producing healthy spermatozoa. The latter property is, however, lacking in the majority of such cases.

Such non-developed testes may not show any perceptible decrease in size, but usually they are much smaller than the normal organ. One can recognize such non-development clinically by the absence of many of the male characteristics, the lack of pubic hair, the infantile size of the penis and scrotum (Fig. 227), the smooth, soft, child-like, hairless skin and fat of the entire body. In some cases this so-called infantilism is accompanied by a high-pitched, almost feminine voice, and in the case shown in Fig. 227 there was a lack of mental development. The term "atrophy of the testis" should be confined to those cases in which the organ has been normally developed, but has undergone retrograde

changes, as may occur after acute inflammations, such as the orchitis following mumps or injuries. Occasionally such atrophy may take place after operations for inguinal hernia, or in a moderate degree as a result of a marked varicocele of long standing.

IMPERFECT DESCENT OF THE TESTIS AND ITS COMPLICATIONS.

If the testis is arrested in its migration from the abdominal cavity to the scrotum, the condition is called non-descent or retention of the testis. If it has pressed through the inguinal canal and then assumes an abnormal position, it is called an ectopia or abnormal descent.

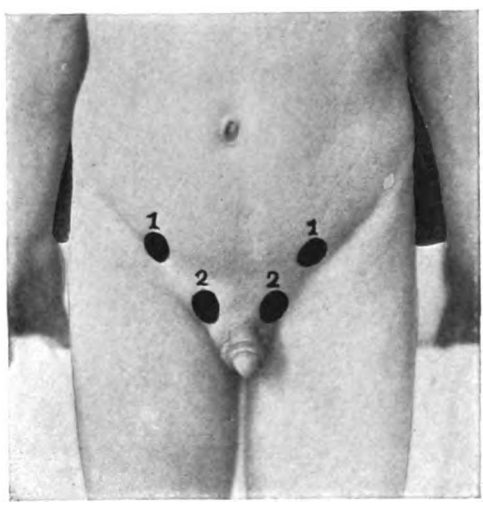

FIG. 228.—MOST FREQUENT LOCATIONS OF TESTIS IN CASES OF NON-DESCENT.

1, Location of testis within inguinal canal; 2, location just outside of external abdominal ring. The third most frequent position (abdominal testis) is not shown in the picture.

In the case of the *retained testis* the organ may be arrested (*a*) within the abdomen, (*b*) in the inguinal canal (Fig. 228), and (*c*) just below the external abdominal ring (Fig. 228). In *ectopia testis* the organ has been found beneath the skin of the anterior abdominal wall, in the femoral region (Fig. 229), in the perineum (Fig. 230), at the root of the penis or toward the anterior superior spine of the ilium.

In examining a child for a retained testis, it must be remembered that children possess the ability to draw the testis, even when normally descended, into the inguinal canal almost as far as the internal ring (Fig. 231).

The presence of a retained or abnormally descended testis may be readily recognized by first palpating the scrotum, when one or both sides will be found empty. Careful search should then be made, in the places where the testes are usually retained or abnormally placed, for a soft, oval, easily movable tumor corresponding to the testis. In children the organs may be retained in the inguinal canal until near puberty and then suddenly descend. An abnormally retained testis cannot be palpated, and the first sign of its presence may be an inflammation.

The following conditions may develop in or accompany a retained or abnormally descended testis:

1. Inflammation.
2. Torsion of the cord (Fig. 232).
3. Tumor formation.
4. Hydrocele and hernia.

1. **Inflammation.**—This is especially apt to occur in an imperfectly descended testis, often from torsion of the cord. The situation of the local inflammatory signs (pain, swelling, etc.) varies according to the location of the organ. The pain is more intense than in inflam-

FIG. 229.—LOCATION OF TESTIS IN FEMORAL REGION (Eccles).
The testis is arrested over Scarpa's triangle; the left side of the scrotum is atrophied.

mation of the normally placed organ, and is apt to be accompanied by nausea and vomiting greatly resembling a strangulated hernia or an inflamed lymph-node if located in the femoral or inguinal regions. If situated within the abdomen the condition may resemble an appendicitis or some other acute abdominal condition.

In inflammation there is an absence of the testis in the scrotum on the affected side, the onset is not as sudden, nor do the nausea, vomiting, or constipation, if present, persist as they do in strangulation. The local tenderness and swelling are also more marked in an inflamed testis and there is more apt to be fever and leukocytosis early.

From an *inflamed lymph-node* the diagnosis is not as difficult.

There is usually some primary focus for the enlarged node to be found, the testis is present on the inflamed side, and the swelling is more superficial than in an inflamed testis.

FIG. 230.—LEFT TESTIS IN PERINEUM OF AN INFANT (Eccles).

2. This has been discussed on page 274.

3. **Tumor Formation.**—It has been commonly believed that tumors were more likely to develop in an imperfectly descended testis, but Eccles, who has examined 854 cases of this condition, believes that malignant disease is not more frequent than in the normally descended organ.

It is well to remember that a gradual enlargement of an inguinal tumor, if the testis on the same side has not descended into the scrotum,

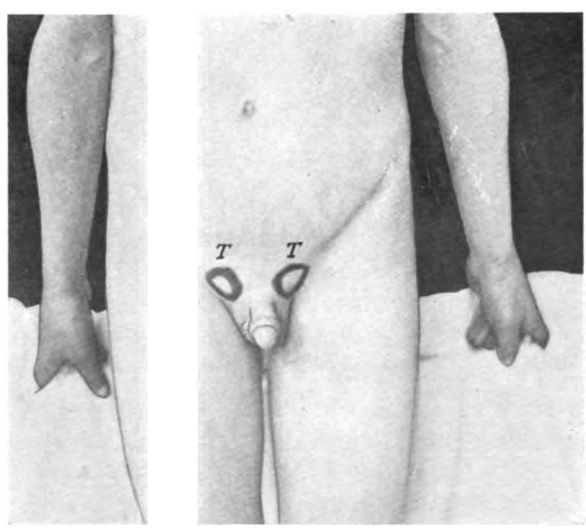

FIG. 231.—NORMAL POWER OF THE CREMASTER MUSCLES IN CHILDREN OF DRAWING TESTIS THROUGH EXTERNAL ABDOMINAL RING INTO INGUINAL CANAL.

T, Testes outlined on surface of both, showing how they were drawn up from the scrotum in a boy of seven, as far as the external abdominal ring. The small size of the scrotum is due to the absence of both testes.

must be regarded with suspicion. The first sign of its malignant character may be the evidence of a distant bone metastasis.

Hernia and Hydrocele in Connection with Imperfect Descent.—Hernia occurs in about one-half of the cases of undescended testis and is most often of the congenital inguinal variety. Hydrocele is also a frequent accompaniment.

FIG. 232.—STRANGULATION OF A TESTIS DUE TO TORSION OF ITS CORD (Eccles).

The darker patches indicate extravasation of blood into its substance. This condition was present in a case of non-descent of the testis, the latter being arrested in the inguinal canal.

INFECTIONS OF THE MALE REPRODUCTIVE ORGANS.

For diagnostic purposes it will be found of service to include the diseases of the vas deferens, seminal vesicles, and prostate with those of the testis and epididymis, since in many of the cases of pathologic conditions of these latter there are co-existing changes in the three first-named structures. This is especially true of gonorrhea (page 382) and tuberculosis.

One of the most important lessons to learn before attempting to make a diagnosis of these conditions is to practise palpation of the same structures either on the non-affected side or in normal individuals. A physician must accustom himself to the consistency and relations to each other, of the body of the testis or orchis proper, and of the epididymis. In the latter one must learn to distinguish the head or upper pole from the tail or lower pole.

The vas deferens should also be palpated and followed toward the external abdominal ring. By rectal examination the normal prostate may be palpated. The seminal vesicles cannot be felt unless enlarged.

The best position for an examination of the testis and epididymis is to palpate the organs of the right side with the left, and vice versâ (Fig. 233).

The chief pathologic conditions of these structures which are of clinical interest can be conveniently divided for diagnostic purposes into two classes, as follows:

Acute (Fig. 235).	Chronic (Fig. 236).
1. *Gonorrhea* most often involves the epididymis and vas deferens, rarely the body.	1. *Tuberculosis* in early stages involves first the head of the epididymis, later the entire epididymis and vas. Rarely does it begin acutely or associated with gonorrheal epididymitis.
2. *Trauma* usually causes enlargement of body of testis or orchis proper, rarely of the epididymis.	2. *Syphilis* in majority of cases involves body or orchis proper. Epididymis rarely involved alone or in conjunction with orchitis. Gumma of vas deferens quite rare.
3. *Enlargement following epidemic parotitis* (*mumps*) always involves body of testis or orchis proper.	3. *Neoplasms*, whether benign or malignant, always begin in the orchis proper or body of testis.
4. *Cystitis of non-gonorrheal origin may be followed by an epididymitis* (especially with enlarged prostate).	
5. *Typhoid and influenza* rarely are followed by an epididymitis.	

The above table holds true for the majority of cases. Cases will be met with, however, in which a tuberculosis may begin very acutely or develop upon an acute gonorrheal epididymitis, or the exceptional cases referred to under syphilis may occur. In general, however, such a table will be found a convenient guide.

The principal diagnostic features of these various affections follow.

Gonorrheal Epididymitis and Orchitis.—This occurs in the second or third week of an acute attack or in the course of a chronic case after the passage of sounds or massage of the prostate.

The epididymis is greatly and uniformly enlarged and tender. The structure rests like a cap upon the orchis, and the latter can be distinctly felt unless an acute gonorrheal hydrocele (periorchitis serosa acuta) coexists; then a double enlargement with a depression between is to be felt (Fig. 235). The existence of an acute urethritis, in the pus of which the gonococcus can be demonstrated, confirms the diagnosis. The temperature varies from 101° to 104° F. The vas deferens is greatly enlarged and very tender. The disease may occasionally begin with severe pain along the intra-abdominal portion of the vas deferens. When an epididymitis sets in, the urethral discharge usually ceases temporarily. The epididymis remains enlarged and tender at times for months after an attack. Abscesses may form, especially after a gonorrheal orchitis.

Less often is the orchis or body of the testis involved in a gonorrheal

inflammation. One can then feel a smooth, oval, tender, scrotal tumor, upon which the epididymis rests, unless an acute hydrocele obscures it.

TRAUMATIC AFFECTIONS.

These usually affect the body of the testis, especially after a kick or blow on the scrotum. The epididymis or vas deferens may occasionally be inflamed after heavy lifting. If they result from lifting some heavy object, the epididymis may be most involved. The diagnosis can be readily made from the history, the palpatory findings, and the exclusion of gonorrheal infection.

FIG. 233.—METHOD OF EXAMINING THE VAS DEFERENS ON EITHER SIDE.

The examination of the right vas deferens or veins of the spermatic can be best carried out by standing either in front or upon the right side of the patient, and grasping the structures between the index-finger and thumb of the left hand. The same method may be followed in the examination of the vas deferens for spermatic veins on the left side by grasping it between the right thumb and index-finger.

TUBERCULOSIS.

This disease most often begins in a slow, insidious manner. A number of cases have, however, been reported of a very acute development, especially in children and young adults. The author has reported a typical case in which it followed an acute gonorrheal epididymitis without perceptible interval.

The testis is usually involved at a later period, so that it is possible at such a time to find that the testis and the epididymis are involved to such an extent as to feel like a continuous body through the scrotum.

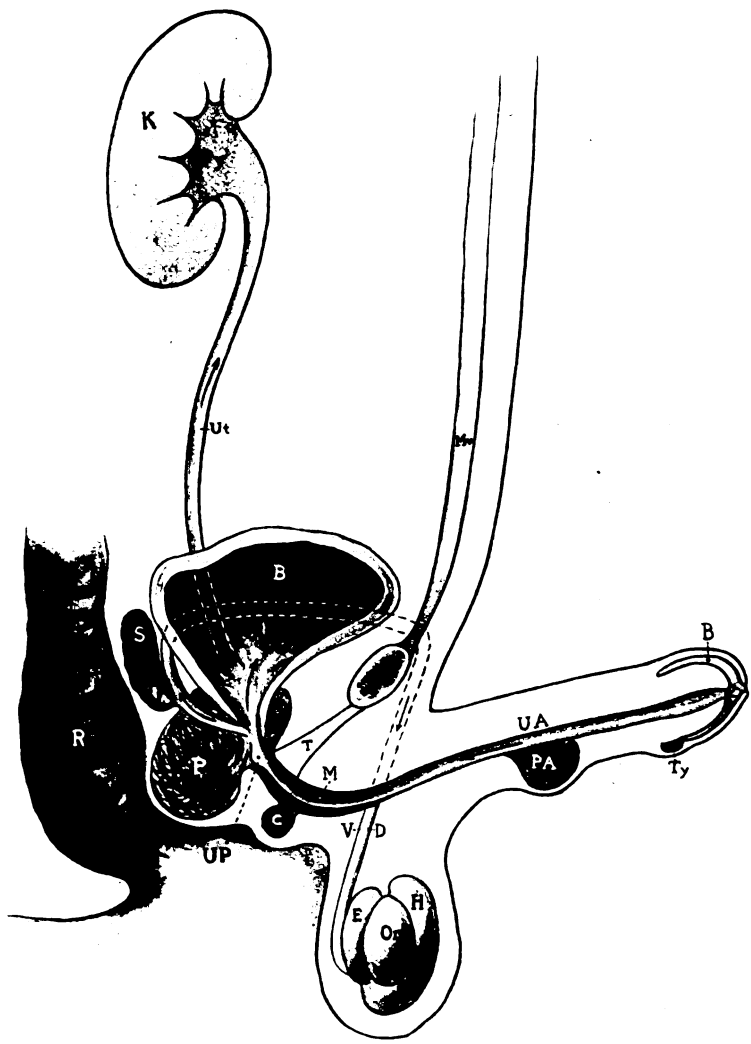

FIG. 234.—LOCALIZATION OF GONORRHEAL INFECTION IN THE MALE GENITO-URINARY ORGANS (SEMIDIAGRAMMATIC).

K, Parenchyma of kidney; Py, gonorrheal pyelitis; Ut, gonorrheal ureteritis; the arrow points the direction in which the infection ascends from the bladder to the kidney; B, bladder wall; the arrow at the neck of the bladder indicates the direction of the infection from the urethra to the bladder (gonorrheal cystitis); UP, seat of posterior urethritis; M, infiltration of urethral walls at bulbo-membranous junction—most frequent seat of gonorrheal stricture; UA, anterior urethra; T, triangular ligament, which divides the urethra into the anterior and posterior portions. Os symphysis pubis, from which triangular ligament is suspended; PA, periurethral abscess; B, balano-posthitis; Ty, inflammation of Tyson's gland; P, seat of prostatic abscess, pointing toward the perineum, involving bulging of the anterior wall of the rectum; R, rectum; the arrow shows the direction in which infection occurs, causing a gonorrheal proctitis; V—D, seat of the vas deferentitis; F, seat of gonorrheal epididymitis; Or, orchis, or body of testis; H, seat of acute gonorrheal hydrocele; Mu, musculature of abdominal wall; S, seminal vesicles, the seat of gonorrheal vesiculitis; the arrow shows how transmission is effected from the posterior urethra to the seminal vesicles and vas deferens, from the latter to the epididymis, etc.

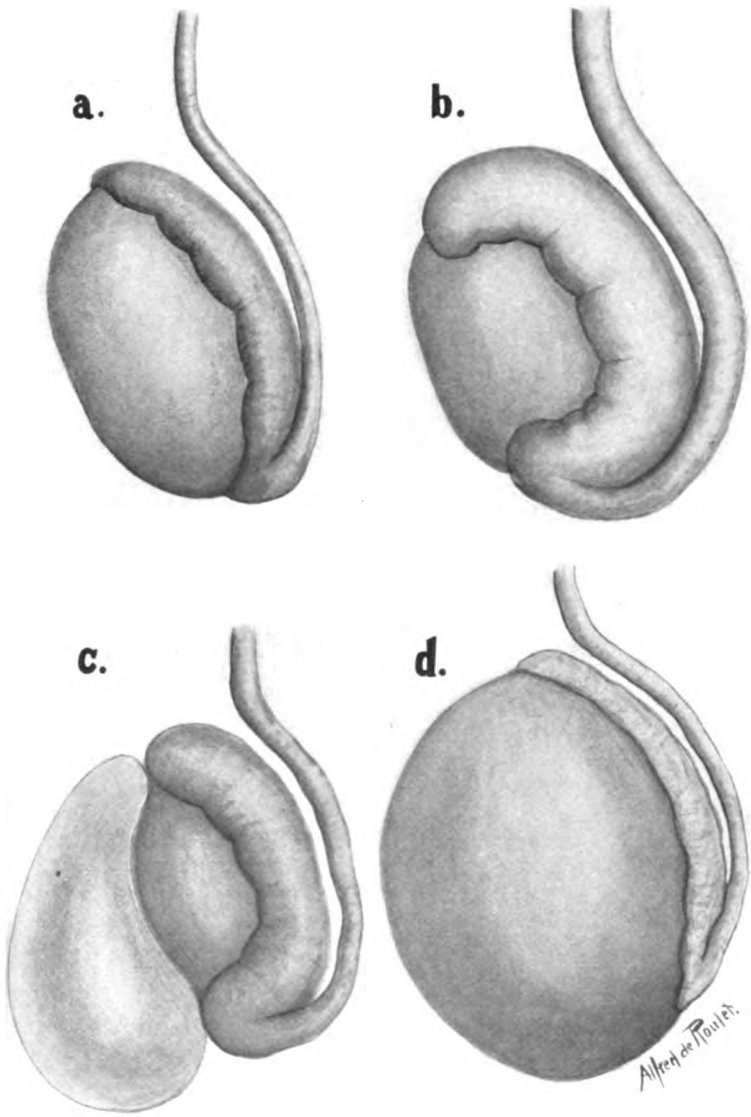

FIG. 235.—DIFFERENTIAL DIAGNOSIS OF ACUTE ENLARGEMENTS OF THE TESTIS AND EPIDIDYMIS.

a, Normal testis. *b*, Gonorrheal epididymitis and vas deferentitis. Note the marked enlargement of the epididymis and spermatic cord as compared to the normal structures, and how the epididymis almost encloses the testis. *c*, Acute gonorrheal epididymitis, deferentitis and acute gonorrheal hydrocele. *d*, Acute orchitis following trauma of the testis, and the characteristic enlargement of the body of the testis (orchis) following mumps, and other infectious diseases.

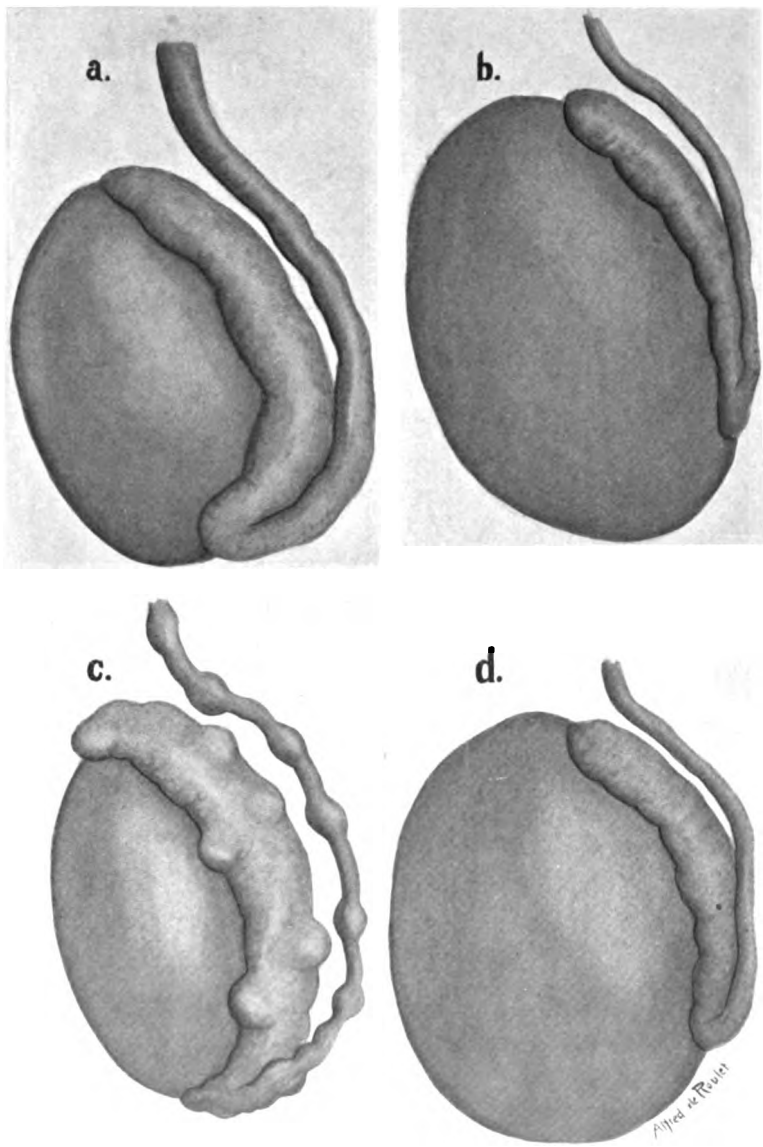

FIG. 236.—DIFFERENTIAL DIAGNOSIS OF THE CHRONIC ENLARGEMENTS OF THE TESTIS AND EPIDIDYMIS.

a, Syphilis of testis. This is one of the two forms in which syphilis affects the testis. In this variety both testis, that is, the body of the testis (orchis), and epididymis are enlarged. (See text.) *b*, Second variety of syphilitic affection of the testis. In this form the orchis or body of the testis is predominantly enlarged, giving rise to a large tumor, syphilitic orchitis, or sarcocele. *c*, Tuberculosis of the testis. This illustration shows the most frequent localization of tuberculosis, especially in its early stages, involving especially the tail of the testis and the vas deferens, in the form of a nodulated enlargement of the former, and a beaded one of the latter. *d*, Tumors of the testis. This illustration shows how tumors, both benign and malignant, of the testis almost exclusively affect the body of the testis.

The disease may follow trauma as well as gonorrheal inflammation or foci of tuberculosis elsewhere. A search for all of these should be made in every case.

In the majority of cases the disease begins slowly. One or more hard nodules can be felt in the upper part of the epididymis, so that it feels very irregular. Later a similar condition of the entire epididymis can be felt and the vas deferens is thickened and bead-like on palpation. Early abscess formation and formation of a sinus in the scrotal skin, with discharge of thick, cheesy pus, speak for tuberculosis. An examina-

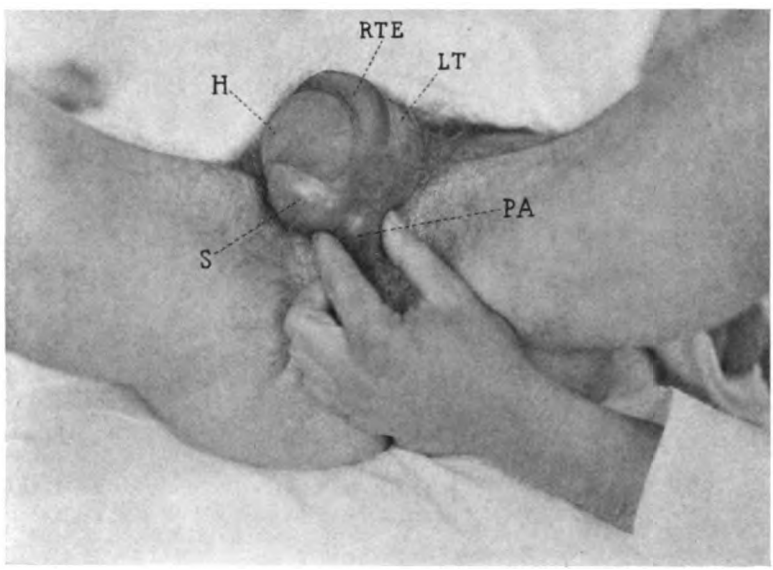

FIG. 237.—COMPLICATIONS FOLLOWING GONORRHEAL URETHRITIS.

PA, Periurethral abscess grasped between the thumb and index-finger; S, collection of serum between periurethral abscess and acute gonorrheal hydrocele (H); RTE, inflamed epididymis of right testis: LT, left testis.

tion of the prostate and seminal vesicles will show hard nodules in many cases. If the disease is advanced, tubercle bacilli may be demonstrated in the urine, as referred to, in the diagnosis of renal tuberculosis. It is rarely necessary to resort to a tuberculin test and reliance can seldom be placed upon a negative result after the use of tuberculin.

Tuberculosis must be differentiated from a chronic enlargement which may be a sequel of an acute epididymitis. The induration of such a chronic epididymitis is usually diffuse and tender, the vas is smooth and firm, and the history of a previous acute gonorrheal attack and examination of the urine will clear up any doubts. In those cases referred

to above, in which the tuberculous condition develops directly upon a gonorrheal, the diagnosis can only be made from the more nodulated outline in tuberculosis, and similar nodules in the vas and prostate, or by the discovery of the tubercle bacilli in the urine or in the pus of a sinus, if one exists.

Syphilis usually affects the body of the testis and but rarely the epididymis. The induration is not nodulated if it affects the epididymis, and the history and the administration of potassium iodid will render a differentiation possible.

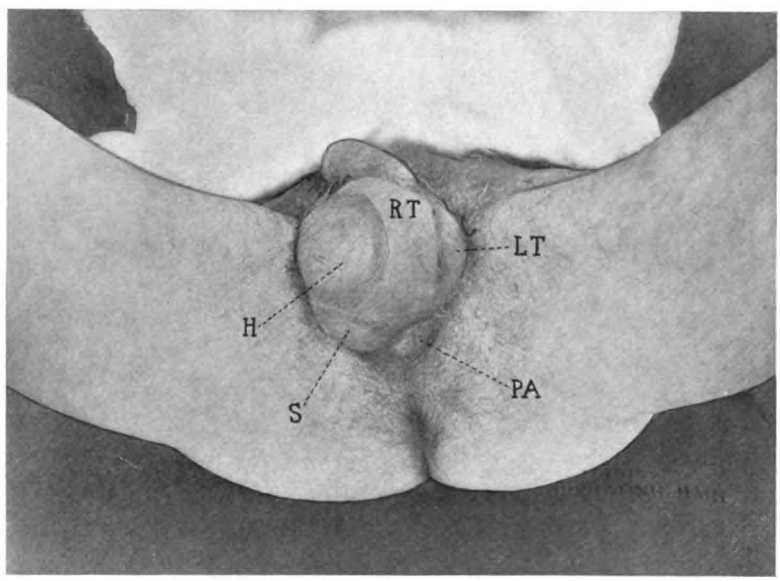

FIG. 238.—VIEW FROM THE FRONT OF CONDITIONS ILLUSTRATED IN FIG. 237.

The limbs of the patient were widely separated in order to take the photograph. PA, Periurethral abscess; S, collection of serum at lowermost portion of scrotum; H, acute gonorrheal hydrocele; RT, inflamed right epididymis; LT, inflamed left testis.

SYPHILIS.

A gradual, almost painless enlargement of the body of one or both testes occurs. An acute onset with pain, is very rare. The enlarged orchis can be readily felt as an oval, smooth, painless tumor in the scrotum. The epididymis and vas are rarely involved. In one case, in which such a complication occurred, I was able to differentiate it from tuberculosis by the absence of nodulation and the more diffuse character of the induration, as well as the history and the absence of sinuses. The existence of a large accompanying hydrocele may at times obscure the existence of a syphilitic orchitis until the fluid is evacuated.

TUMORS OF THE TESTIS AND EPIDIDYMIS.

These may be divided into:

Benign.—(*a*) Spermatocele. (*b*) Adenoma and cystadenoma testis. (*c*) Dermoids and teratoma.

Malignant.—(*a*) Sarcoma. (*b*) Mixed tumors.

SPERMATOCELE.

This form of tumor, which is really a retention cyst of the epididymis, can be felt as a tumor which grows slowly to the size of an adult fist. The tumor either shows distinct fluctuation or is quite tense. It can be felt as either separating the testis proper from the epididymis or it feels like a hydrocele. It can be recognized on exploratory puncture as a spermatocele by its milky contents, which contain spermatozoa.

NEOPLASMS OF THE TESTIS.

In the diagnosis of neoplasms of the testis two questions present themselves: (1) Is the enlargement of the organ a neoplasm? (2) What is the nature of the new-growth?

In answering the first question, it is necessary to first determine by palpation whether the body of the testis or the epididymis is involved or whether the enlargement is one of the tunica vaginalis, *e. g.*, hydrocele, hematocele, etc.

If the enlargement is found to be of the epididymis alone, the question of a neoplasm need not enter into consideration, since the principal enlargements of this structure are due to gonorrhea, syphilis, and tuberculosis (see page 392). If the enlargement is of the body of the testis the chief condition to be differentiated from a neoplasm is syphilis. In cases where there is a clear history of this latter condition the diagnosis will present no difficulties. The syphilitic enlargements are more stationary, showing but little tendency to an increase in size. The only variety of neoplasm which causes such a gradual enlargement of the testis is the *benign adenocystoma*, but even in this form the increase in size is more progressive than in syphilis. The patients will usually give the history of a more rapid enlargement than in the case of syphilis. The administration of potassium iodid for a week will usually clear up the diagnosis in those cases in which the history is not clear and there are no other evidences of syphilis to be found in the body. A malignant neoplasm of the testis can be readily distinguished from syphilis by its rapid growth.

A hydrocele can be differentiated by the absence of enlargement of the body of the testis, by the translucency test (Fig. 239), and by the use of the aspirator or trocar for the withdrawal of some of the hydrocele fluid.

At times it is almost impossible to differentiate a hematocele from a neoplasm of the testis. In the latter the tumor is heavier and there is an absence of inflammation and of syphilis, the latter being the most frequent cause of a hematocele, also called periorchitis hemorrhagica.

The second question to be answered is, What is the nature of the neoplasm? Tumors of the testis may be divided into two great groups—benign and malignant. The benign are the adenocystomata, which are the most frequent, and the rarer forms, such as dermoid cysts. Of the latter only a few cases have been reported. The malignant varieties belong either to the sarcomata proper or to the so-called mixed tumors recently studied by Wilms. The majority of the cases of sarcomata of the testis belong to the small round-celled or spindle-celled varieties. They grow very rapidly, often appear simultaneously in both testes, and spread along the spermatic cord and inguinal lymph-nodes to the retroperitoneal nodes. Metastases appear very early. The mixed tumors contain muscle fibers, cartilage, myxomatous tissue, glandular acini, bone, and blood-vessels in varying proportions and combinations. Many text-books speak of cases of carcinoma, but their existence is denied by other equally good authorities.

Clinically, the only distinction between the benign and malignant neoplasms is their rate of growth. The malignant varieties, especially the sarcomata, cause so rapid an enlargement of the body of the testis that a diagnosis can be readily made. Accompanying this increase in size there is involvement of the spermatic cord and inguinal retroperitoneal lymph-nodes, all of which can be determined by palpation. Sarcomata are most common in children before the age of ten, and again in adults between thirty and forty. In the benign varieties of neoplasms of the testis the oval shape of the testicle is preserved. As the gradual increase in size occurs the surface becomes nodulated and softer in places.

The *mixed tumors* form a clinical group by themselves. They cause, at times, a gradual enlargement of the testis; at others, a very rapid one. After their removal they are most apt to cause metastases in the lungs and bones (Fig. 408).

HERNIA.

A hernia may be defined as the *abnormal protrusion of a viscus from any preformed cavity of the body.* The term is, however, limited to those protrusions in which a portion of the abdominal viscera escapes through openings in the muscular or bony wall.

The opening through which a hernia escapes is called the hernial ring or rings (if there are two, as in the case of the indirect inguinal).

The most frequent varieties of herniæ are the inguinal (73.4 per cent.),

FIG. 239.—METHOD OF DETERMINING THE TRANSLUCENCY OF A SCROTAL TUMOR IN ORDER TO MAKE A DIAGNOSIS OF HYDROCELE FROM THAT OF A SOLID TUMOR OF THE TESTIS OR FROM A HERNIA.

An electric lamp or candle is held on the distal side of the tumor, while the examiner places a roll of paper or a cylinder against the scrotal tumor on the side opposite to that on which the light has been placed. In case of a hydrocele, the light is readily transmitted through it.

the femoral (18 per cent.), and the umbilical (8.47 per cent.). The fraction remaining—*i. e.*, 0.12 per cent. (Eccles)—represents the ventral, obturator, sciatic, lumbar, perineal, vaginal, and diaphragmatic varieties in the order named. The contents of a hernial sac are most often intestines and omentum. Gurgling and tympany speak for the former, while a nodulated surface and dullness on percussion speak for the latter (omentum).

Among rarer contents may be mentioned: (*a*) Ovary (increases in size and becomes more tender during menstruation); (*b*) testicle, feel-

	Reducible Hernia.	Simple Irreducible Hernia.	Strangulated Partial Enterocele.	Strangulated Complete Hernia.	Inflamed Hernia.	Obstructed or Incarcerated Hernia.
Swelling.....	In hernial region.	In hernial region.	Usually none to be felt.	Larger than before and firmer.	Larger than before.	Larger than before.
Impulse.....	Distinct on coughing.	Distinct on coughing.	None.	None.	Present on coughing.	Present on coughing, but less marked.
Reducibility..	Disappears on lying down or manipulation.	Does not disappear after same tests.	Irreducible.	Irreducible.	Generally reducible, but may not be.	Irreducible.
Other local signs.....	Soft if intestine, firmer if omentum.	Usually feels firm and doughy.	Some pain over hernial region.	Dull pain over swelling, later signs of peritonitis.	Redness, pain, local heat.	....
Signs of obstruction...	None.	None.	Not as marked as in complete form. May pass liquid feces and gas; vomiting not so marked.	Colicky pains, absolute constipation; vomiting; later fecal.	But little nausea. No absolute constipation.	Gradual onset; vomiting slight; bowels can be moved. Occurs in aged.
General disturbances..	None.	None.	Not as early as in complete.	Marked and early intoxication.	Fever and leukocytosis.	Slight, no collapse.

ing smooth, firm, and like a plum; (*c*) vermiform appendix; (*d*) urinary bladder; (*e*) uterus or tubes; (*f*) Meckel's diverticulum (Fig. 158); (*g*) rarely the stomach, liver, or spleen.

A hernia is said to be reducible when its contents can be returned into the abdominal cavity upon gentle manipulation or when the patient lies down. It is said to be irreducible when the above tests result negatively.

The following complications of both reducible and irreducible herniæ may occur. They are more frequent in the irreducible variety.

1. The lumen of the bowel becomes obstructed from within through stagnation of feces. This is called an *incarcerated or obstructed hernia.*

2. The sac wall or even the contents (especially omentum) become acutely inflamed from causes both within and external to the sac. This is called an *inflamed hernia*, and if it occurs in the reducible variety, adhesions form and produce irreducibility.

3. *Strangulated hernia.* In this complication there is interference with the passage of feces through the intestinal contents and secondary gangrene of the bowel wall as the result of interference with the circulation.

Strangulation most often follows a sudden increase in abdominal pressure, as in coughing, lifting, straining at stool, etc.

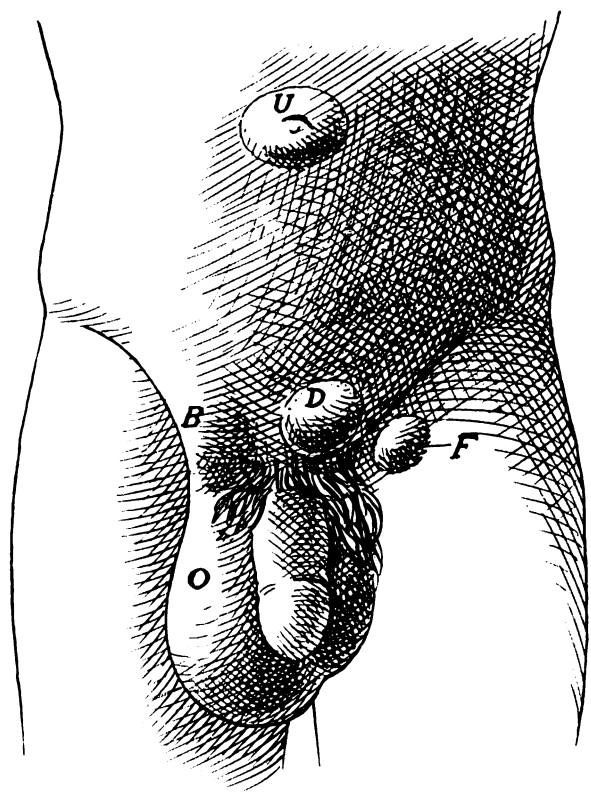

FIG. 240.—LOCATION OF VARIOUS FORMS OF ABDOMINAL HERNIÆ (DIAGRAMMATIC).
U, Umbilical hernia; *D*, direct inguinal hernia; *B*, indirect incomplete inguinal hernia; *O*, complete or scrotal inguinal hernia; *F*, femoral hernia.

The principal diagnostic points of reducible and irreducible herniæ and their complications are given in the table on page 402.

It is very difficult to differentiate between an obstructed and a strangulated, and, again, between an inflamed and a strangulated, hernia, since acute strangulation may occur in an obstructed hernia and the inflammation may spread to the general peritoneal cavity from an inflamed hernia. At the present time operation is indicated in every case of irreducible hernia accompanied by local signs, such as pain, ten-

derness, and constipation, or nausea and vomiting. Hence the above differential points have often only a theoretic value. Emphasis cannot be too strongly laid upon the danger of forced taxis in the efforts to reduce an irreducible hernia for the purposes of diagnosis or treatment, whether or not such a hernia be accompanied by signs of inflammation or obstruction.

In the table on page 402 attention is called to the fact that strangulation of only a portion of the wall of the gut (*acute partial enterocele*[1]) may occur, causing far less marked symptoms of intestinal obstruction than if the whole circumference be strangulated. The same atypical clinical picture may appear if the appendix or, as rarely occurs, a Meckel's diverticulum is strangulated. As in acute partial enterocele, the bowels may move normally or there may even be diarrhea. Here localized tenderness over the hernial region is the most valuable sign. Other atypical forms are: (*a*) When strangulation occurs within the sac or (*b*) where it takes place in a multiloculated sac. In both of these the impulse on coughing may be retained.

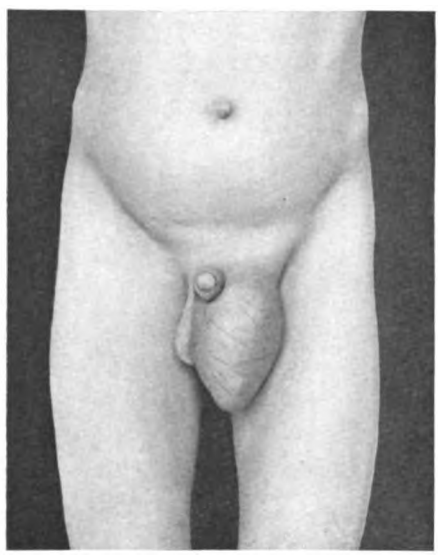

FIG. 241.—LEFT-SIDED CONGENITAL COMPLETE INGUINAL HERNIA IN A BOY OF EIGHT.
Note the location of the testis at the lowermost portion of the scrotum.

Again, two or more irreducible herniæ may coexist, as in the case shown in Fig. 252 (femoral and inguinal). It is then difficult to say which has been strangulated. But in all of these anomalous forms the local tenderness is the most important symptom.

INGUINAL HERNIA.

This may be of three varieties:

1. Indirect or oblique.
2. Direct.
3. Interstitial.

[1] This form of partial strangulation of a gut has also been called a Littré hernia.

1. **Indirect or Oblique Inguinal Hernia.**—As long as the sac and its contents remain within the inguinal canal this form is called an incomplete indirect or oblique inguinal hernia or bubonocele. When the sac and its contents protrude through the external abdominal ring (Fig. 241) into the scrotum, it is called a complete or scrotal hernia.

The incomplete form may be recognized as a swelling which causes

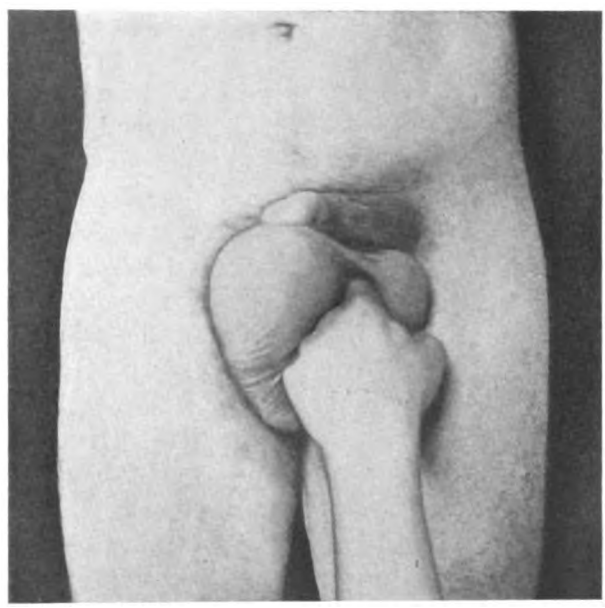

FIG. 242.—METHOD OF INVAGINATING THE SCROTUM IN ORDER TO DETERMINE THE SIZE OF THE EXTERNAL ABDOMINAL RING.

When examining the left external abdominal ring, as in the illustration, the left index and middle fingers of the examiner should be used. This can best be done when the patient stands upon a chair. The scrotum is then invaginated, until the index-finger feels the spine of the pubis, to the inner side of which the oval opening of the external abdominal ring, which in adults normally admits the index-finger, can be distinctly felt. The impulse of a hernia can be best felt in this manner. The patient is instructed to cough while the index-finger is placed in the external abdominal ring.

a prominence along the course of the inguinal canal (from the internal to the external abdominal ring).

The swelling has all of the characteristics of a reducible hernia, viz., that it causes a swelling in a hernial region having all the properties referred to on page 402.

There is a distinct impulse to be felt on coughing (Fig. 242). The swelling becomes more visibly prominent when the patient coughs or strains or stands up. It can be caused to disappear by light taxis or when the patient lies down. The impulse is often best felt by invaginat-

ing the scrotum and inserting the index-finger (Fig. 242) through the external ring into the canal.

When the hernia is of the complete or scrotal variety the position of the swelling at the upper end of one side of the scrotum, passing up into the groin on the outer side of the pubic spine, is typical. It can usually be readily reduced upon lying down and caused to reappear when the patient coughs. The size of the external ring varies according to age, and to some extent in different individuals. In general, it admits the index-finger in adults and the little finger in children. In inguinal herniæ, especially if they are of long standing, the ring will often admit three to four finger-tips. The internal ring cannot be felt. If the hernia has existed for many years, the external and internal rings may come to lie opposite each other, so that after the contents are reduced, the finger inserted through the external ring seems to sink directly toward the peritoneal cavity, there being no posterior wall to the canal. This variety is called a *straight hernia*. An inguinal hernia may be so large that no trace of the penis is to be found (Fig. 243).

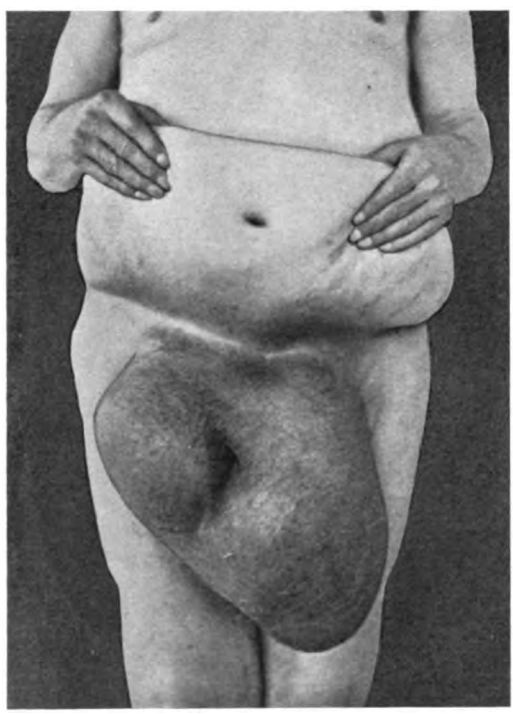

FIG. 243.—ENORMOUS DOUBLE INGUINAL HERNIÆ.

The right was reducible, but the left was irreducible. The depression in the center of the scrotal mass shows the atrophy of the penis, the organ being entirely hidden in cases of large herniæ. The illustration also shows an enormous layer of abdominal fat, which the patient was able to pick up in his hands, in order to have the hernia photographed.

2. **Direct Inguinal Hernia.**—A direct inguinal hernia appears at the outer edge of the rectus and is usually much smaller than the oblique form and more rounded (Fig. 240). It is very difficult to distinguish it from the above mentioned straight hernia, having the same palpatory findings and occurring, like it, in elderly people. It is almost impossible

to state positively that the hernia is a direct one in such cases until at operation the deep epigastric artery is found along the outer border of the sac.

3. **Interstitial Hernia.**—There are three varieties of this form (Fig. 246) and it usually accompanies non-descent of the testis. The first variety is that in which the sac lies between the internal and external oblique muscles. This variety is more common on the right side of the body and causes an oval swelling parallel to and directly above Poupart's ligament. It does not project much from the surface and some of

FIG. 244.—TYPICAL APPEARANCE OF A CASE OF LEFT-SIDED COMPLETE OBLIQUE INGUINAL HERNIA. Note the depression between the lower border of the hernia and the upper border of the testis.

the sac may pass into the scrotum or labium, so that a groove appears between the two parts of the hernia.

In the second variety the sac lies between the external oblique aponeurosis and the skin. The swelling has the same position as in the first form, but there is more projection from the surface.

In the third variety, or properitoneal hernia, there is almost always a part of the sac in the labium or scrotum (Eccles). It is seldom recognized except when strangulated or during radical cure operation.

Unusual Contents of Inguinal Herniæ.—*Hernia of the Bladder.*—This occurs oftener in connection with an inguinal, than in femoral hernia.

The most frequent variety is where the peritoneum covering the bladder forms a part of the sac.

FIG. 245.—METHOD OF PALPATING THE SPERMATIC CORD IN ORDER TO MAKE THE DIAGNOSIS OF COMPLETE OBLIQUE INGUINAL HERNIA AFTER REDUCTION OF THE CONTENTS OF THE SAC. (See text.)

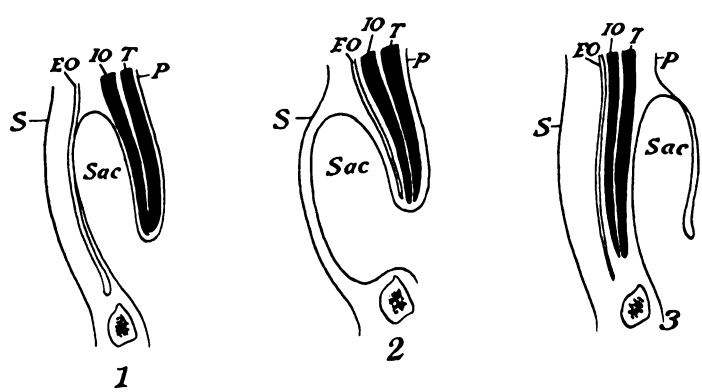

FIG. 246.—VARIOUS FORMS OF INTERSTITIAL HERNIÆ.

1, Subaponeurotic; 2, subcutaneous; 3, properitoneal (Eccles). *S*, Skin; *EO*, external oblique aponeurosis and muscle; *IO*, internal oblique muscle; *T*, transversalis muscle; *P*, peritoneum.

A diagnosis may be made before operation if the patient gives the history of the tumor disappearing during micturition, and if when pressure is made over it, the patient experiences a desire to urinate, or if the

act of micturition ceases suddenly and begins again as soon as the hernial swelling is compressed.

Vermiform Appendix.—The presence of this structure cannot be recognized before operation unless it should become inflamed or strangulated. The symptoms of the latter are less marked than in a strangulation of the intestine proper.

Ovary.—Before puberty its presence may be suspected if an oval, firm, freely movable tumor be found in the inguinal canal or just external to it. Later in life the ovary can only be recognized before operation if a firm body is found in the hernial sac, which swells and becomes quite tender during menstruation.

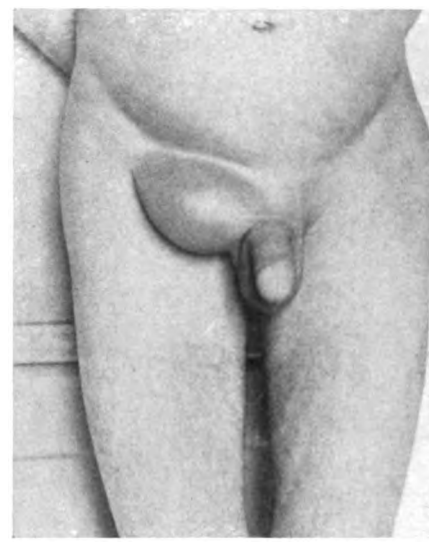

FIG. 247.—INGUINAL HERNIA WITH UNDESCENDED TESTIS.

1. Differential Diagnosis of Inguinal Hernia in the Male.—1. *When Reducible and Complete.*—(*a*) From femoral hernia the following table will best illustrate the chief points of difference:

INGUINAL.	FEMORAL.
1. Emerges on inner side of pubic spine.	1. Emerges on outer side of spine.
2. Inguinal canal filled and pubic spine obscured, when descended.	2. Inguinal canal empty and pubic spine to be felt.
3. Easily recur after reduction.	3. Do not so easily recur.
4. Impulse felt above Poupart's ligament.	4. Impulse below Poupart's ligament.

(*b*) From a congenital or acquired hydrocele and from an undescended testis lying just outside of the external abdominal ring.

In the last named condition the testis of the corresponding side is felt, just beneath the external abdominal ring (Fig. 228), as a firm elastic body a little smaller than the normal testis. There is no impulse on coughing and the swelling cannot be reduced. Not infrequently a hernia is associated with this condition, so that a swelling is felt above the testis, which emerges from the inguinal canal on coughing and disappears upon manipulation or upon lying down.

(*c*) The following table shows the differentiation of a congenital

hydrocele, and acquired hydrocele and a reducible inguinal hernia (see Figs. 239, 245, 249):

	Complete Inguinal Hernia (Reducible).	Congenital Hydrocele.	Acquired Hydrocele.
1. Location.....	Swelling continuous with inguinal region.	Same as in hernia.	Swelling terminates at upper end of scrotum, can feel cord above tumor (Fig. 250).
2. Impulse.....	Distinct on coughing.	No impulse.	No impulse.
3. Translucency....	Not translucent, as a rule. Rarely so, in children (Fig. 241).	Translucent.	Translucent (Fig. 239) unless greatly thickened sac.
4. If reduced.....	Feel gurgling if contains intestine, reappears rapidly on coughing.	Reduction very slow. Reappears slowly.	Cannot be reduced.
5. Relation to testis and cord.....	Lies above or in front of testis (see Fig. 244) and in front of cord.	Same as in hernia.	Lies in intimate relation to testis, latter felt usually below and behind tumor.
6. Palpation and percussion.....	Soft semi-elastic; dull if omentum; tympanitic if intestine.	Harder and more tense; dull on percussion.	Pear-shaped swelling; harder and tense; dull on percussion.

2. *When Complete and Irreducible.*—The following conditions must be considered in making a diagnosis:

In the male:

(*a*) Hydrocele of the tunica vaginalis (acquired hydrocele).
(*b*) Hydrocele of the cord (encysted hydrocele—Fig. 249).
(*c*) Hematocele.
(*d*) Enlargements of the testis.

In the female:

(*a*) Hydrocele of the canal of Nuck.
(*b*) Hydrocele of the hernial sac.

The chief differential points are considered in the accompanying table:

	Complete Irreducible Inguinal Hernia	Hydrocele of the Tunica Vaginalis.	Enlargements of Testis.
Inspection.....	Tumor extends through external ring into inguinal canal.	Tumor terminates below external ring.	Same as in hydrocele.
Palpation.....	Expansile impulse on coughing. Feels soft if intestine; firmer if omentum.	No impulse. Feels tense and elastic.	No impulse. Firm, may be irregular.
Percussion.....	Tympany, if intestine.	Dullness.	Dullness.
Relation to testis....	Testis is below and behind tumor.	Testis cannot be distinctly felt.	Can outline enlargement of body or epididymis.
Translucency.....	Negative except rarely in young children (Fig. 239).	Positive unless tunica greatly thickened.	Negative.

A *hematocele* gives the history of trauma or syphilis, and is not translucent. In an *encysted hydrocele of the cord* one can often palpate the nodules and can ascertain their attachment to the cord.

In a hydrocele of a hernial sac the tumor can be caused to gradually disappear by gentle manipulation and elevating the pelvis.

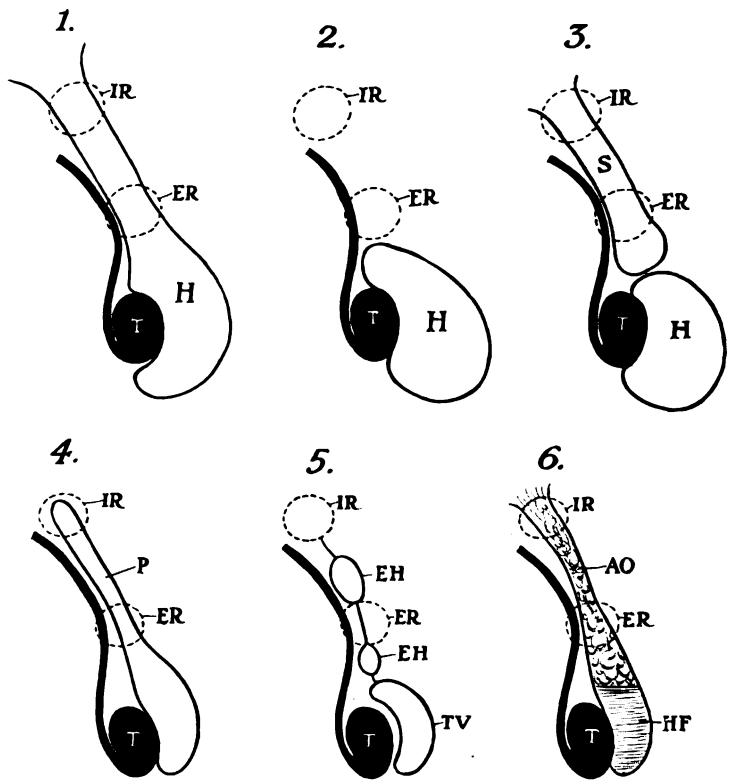

FIG. 248.—VARIOUS FORMS OF HYDROCELE.

IR, Internal abdominal ring; *ER*, external abdominal ring; T, testis and epididymis, shown in black. 1. Congenital hydrocele. The cavity of the hydrocele sac (H) communicates directly with the peritoneal cavity. 2, Typical form of acquired hydrocele: H, Distended tunica vaginalis. 3, Acquired inguinal hernia and acquired hydrocele: S, Sac of hernia; H, hydrocele sac. 4, Hydrocele of funicular process. The process is closed at the internal abdominal ring, but is continuous below with the tunica vaginalis: P, Represents that portion of the sac lying within inguinal canal. 5, Hydrocele of cord: EH and EH, placed respectively within the inguinal canal and just outside of the external ring, represent the two loculi of a hydrocele of the cord; TV, normal tunica vaginalis. 6, Hydrocele of a hernial sac. AO, Adherent omentum; HF, hydrocele fluid in lower portion of sac.

In a hydrocele of the canal of Nuck, which is quite rare, the diagnosis can only be made if there is distinct absence of impulse.

3. *When Irreducible and Incomplete.—In the Male:*

(*a*) From a retained inguinal testis.

(*b*) From various causes of enlargement of the spermatic cord (encysted hydrocele, lipoma).

(*c*) From enlarged and inflamed lymph-nodes.

(*d*) From a lipoma of the groin.

(*a*) An inguinal testis can be readily recognized by its size and consistency. One should palpate the scrotum as a matter of routine in order to ascertain whether one or both testes have failed to descend.

(*b*) From various sources of enlargement of the spermatic cord. An encysted hydrocele is tense and elastic and is intimately connected

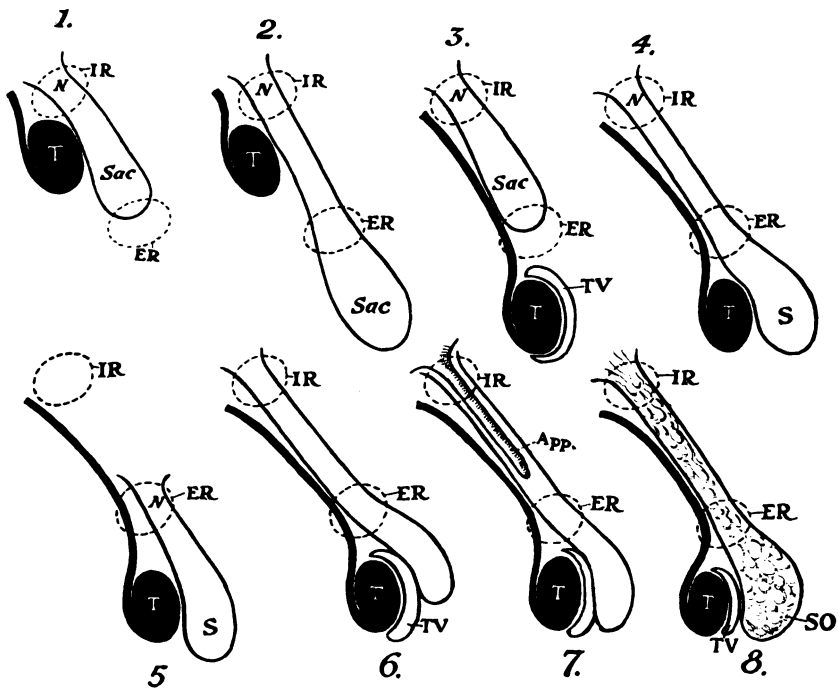

FIG. 249.—CONDITIONS TO BE CONSIDERED IN DIFFERENTIAL DIAGNOSIS OF HERNIA AND HYDROCELE.

T, Testis; N, neck of hernial sacs; IR, internal abdominal ring; *ER*, external abdominal ring; TV, tunica vaginalis; App, appendix vermiformis; SO, omentum adherent to sac. 1, Congenital incomplete inguinal hernia associated with non-descent of testis. 2, Complete congenital inguinal hernia associated with non-descent of testis. 3, Incomplete acquired inguinal hernia with normal testis. 4, Complete congenital hernia with normal descent of testis. 5, Direct inguinal hernia with normally descended testis. 6, Acquired inguinal hernia with normal descent of testis. 7, Acquired inguinal hernia showing appendix as one of the contents of sac. 8, Acquired inguinal hernia with adherent omentum.

with the cord. A lipoma of the cord is rare. It feels soft and doughy and may be lobulated.

(*c*) Enlarged and inflamed inguinal lymph-nodes. These are quite superficial and are tender to the touch. There is often redness of the overlying skin and distinct fluctuation present. In doubtful cases search should be made for a primary source of infection in the external genitalia, lower portion of the rectum and vagina, and lower half of abdominal wall.

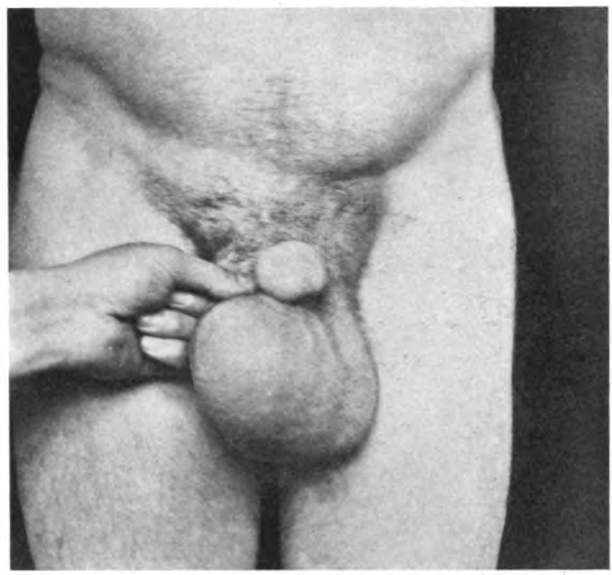

FIG. 250.—ONE OF THE STEPS IN MAKING A DIFFERENTIAL DIAGNOSIS BETWEEN AN ACQUIRED HYDROCELE AND A HERNIA.

Grasping the spermatic cord between the index-finger and thumb, to show that the scrotal tumor does not pass through the external abdominal ring. The hydrocele which was present in this case on the right side remains as a pear-shaped swelling, entirely below the fingers grasping the cord.

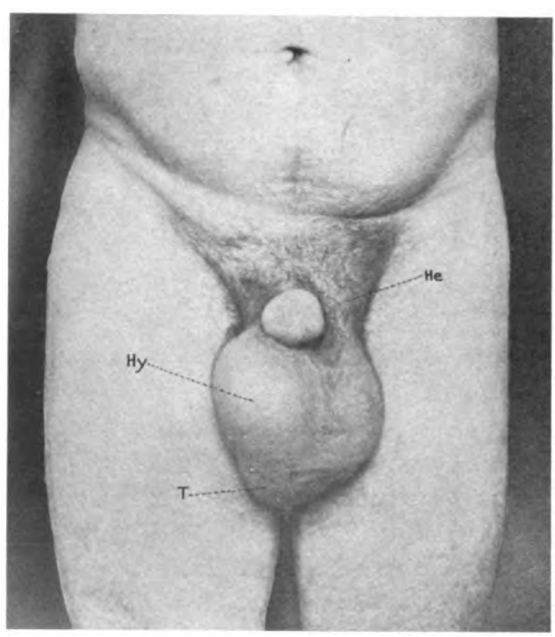

FIG. 251.—HERNIA AND HYDROCELE IN THE SAME PATIENT.

Hy, Hydrocele sac, pushing the testis (T) downward and behind it; He, left indirect complete or scrota hernia. (See text.)

In the Female:

(*a*) Hydrocele of the canal of Nuck is uncommon. In many cases it is present as a reducible swelling in the inguinal region for a long period, and then suddenly cannot be displaced. It may have the latter property of irreducibility from the first in some cases.

It may be a unilocular or bilocular sac. At times it may become inflamed and simulate a strangulated hernia, being accompanied by severe pain, tenderness, and vomiting.

FIG. 252.—INGUINAL AND FEMORAL HERNIÆ ON THE SAME SIDE.

I, Inguinal hernia, of the complete or scrotal type, which can be followed upward to where it enters the internal abdominal ring at the level of the middle of Poupart's ligament; F, femoral hernia. The depression between these two varieties of hernia corresponds to Poupart's ligament.

FEMORAL HERNIA.

A femoral hernia has the following clinical characteristics: The swelling in the majority of cases (Fig. 252) can be seen and felt as lying below or in front of Poupart's ligament and over the inner side of the front of the thigh. The impulse on coughing and the neck of the sac can be felt as lying on the outer side of the pubic spine. The swelling is not so apt to occur so easily when reduced, and after reduction one can feel the pulsation of the femoral artery. The inguinal canal is empty

and no impulse on coughing can be felt after invaginating the scrotum and inserting the index-finger into the external abdominal ring (Fig. 242).

In some cases of femoral hernia the swelling ascends and either lies in front of the inner half of Poupart's ligament or it passes upward and outward toward the anterior superior spine of the ilium. In many of these latter two aberrant varieties of femoral hernia, a differentiation from an inguinal hernia cannot be made except at the time of operation.

It was formerly thought that a femoral hernia was rare in men, and that an inguinal hernia was similarly infrequent in the female. The foregoing statement has been proved by many clinical observations to be incorrect. The two varieties may coexist in the same individual.

A femoral hernia, like an inguinal hernia, may be reducible and irreducible. It is more apt to contain omentum than the inguinal, and hence is more often irreducible. The following combinations may exist (see Fig. 253):

1. It may be completely reducible.

2. It may be possible to reduce the greater portion of the tumor and then a doughy swelling remains which is usually a subperitoneal lipoma (Fig. 253) attached to the fundus of the sac.

3. It may be completely irreducible.

The three chief conditions from which a reducible femoral hernia must be differentiated are: (1) Incomplete reducible inguinal hernia; (2) psoas abscess; (3) a varicose dilation of the internal saphenous vein just before it enters the saphenous opening.

The first three are given in the accompanying table:

	Reducible Femoral Hernia.	Incomplete Reducible Inguinal Hernia.	Varicosity of Saphenous Vein.	Psoas Abscess.
1. Location of swelling.....	Below Poupart's ligament.	Above Poupart's ligament.	Below Poupart's ligament and along course of saphenous vein.	Below Poupart's, but mass also to be felt by deep palpation over Poupart's ligament.
2. Impulse.....	Distinct, and felt below Poupart's ligament.	Distinct and felt above Poupart's ligament.	Indistinct and disappears rapidly; more of a thrill.	Indistinct and only when lying down.
3. Percussion....	Dull, if omentum; tympanitic, if intestine.	Same as in femoral.	Dull.	Dull.
4. Other signs...	Reappears after reduction; when coughs. Reduction backward and upward.	Reappears after reduction (outward, upward, and backward); when patient coughs.	Marked enlargement of entire internal saphenous vein.	Kyphosis and rigidity of spine. Hip flexed.

Occasionally a femoral hernia will contain the urinary bladder.

The diagnosis[1] is rarely made before operation, although suspicion should be directed to this possible contents when urinary symptoms appear in connection with a femoral hernia. The cystoscope may be of aid in showing the relationship of the bladder to the hernia.

An irreducible femoral hernia must be differentiated from (1) an enlargement, of either an acute or a chronic nature, of the lymph-nodes lying over the saphenous opening; (2) from a lipoma; (3) aneurysm of the femoral artery.

1. Inflamed or enlarged lymph-nodes lie quite superficially. If acutely inflamed, there are no symptoms of disturbance in the alimentary canal, such as nausea, vomiting, tympanites, etc., as would be the case in an inflamed or strangulated femoral hernia. Fluctuation is often quite distinct and a primary focus of infection can be found by an exam-

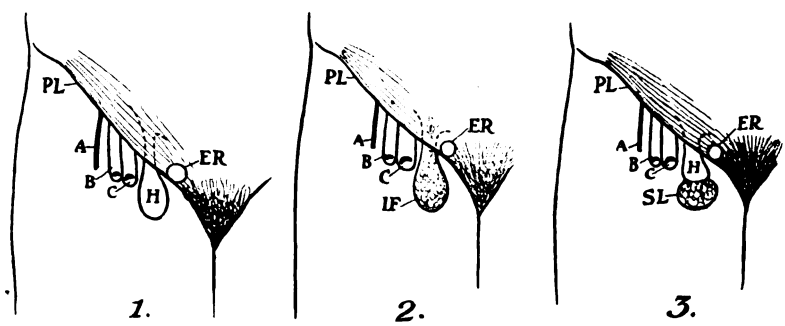

FIG. 253.—NORMAL AND COMPLICATED FEMORAL HERNIÆ.

PL, Poupart's ligament; ER, External abdominal ring; A, anterior crural nerve; B, femoral artery; C, femoral vein; H, hernial sac. 1, Most common form of femoral hernia. The sac lies to the outer side of the external ring and below Poupart's ligament. 2, Irreducible form of femoral hernia, due to adhesions of omentum to interior of sac. 3, A reducible femoral hernial sac to which is attached an irreducible subperitoneal lipoma.

ination of the lower extremity (toes, heel, sole of foot, leg, knee, etc.). The enlarged nodes can be moved upon the underlying tissues, while in an irreducible femoral hernia one can always feel (except in very stout persons) the neck of the sac.

2. A femoral lipoma has no impulse; it is often lobulated, and lies quite superficially. It must not be forgotten, however, that a large lipoma may be attached to an irreducible femoral hernial sac. Under these circumstances a differentiation is impossible before operation.

3. An aneurysm shows a distinct thrill, expansile pulsation, and a rough systolic bruit.

In inflammation of the iliopsoas bursa there is pain on movement of the hip and the swelling and tenderness lie quite deeply.

[1] Karewski: "Archiv f. klin. Chir." Bd. lxxv.

UMBILICAL HERNIA.

There are three varieties of this form of hernia: (*a*) the congenital, (*b*) the infantile, and (*c*) the adult.

Congenital Umbilical Hernia.—This occurs as the result of the non-coalescence of the two lateral halves of the abdominal wall. The most important form of a congenital umbilical hernia is that in which a coil of small intestine or Meckel's diverticulum projects through the base or root of the umbilical cord. If the latter is tied too close to the body, the knuckle of intestine may be cut through and a septic peritonitis result. It is almost impossible to recognize this form unless the base

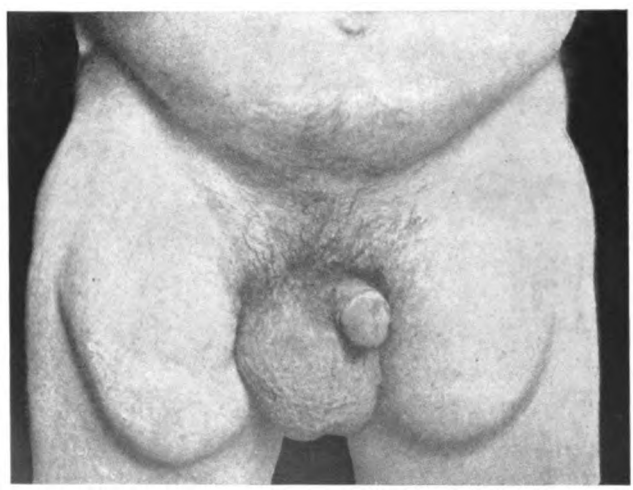

FIG. 254.—DOUBLE FEMORAL LIPOMATA SIMULATING FEMORAL HERNIÆ (Eccles).

of the cord looks broader than normal and can be reduced in size by taxis, the enlargement disappearing with a gurgle.

The other two forms of congenital umbilical hernia are not difficult to recognize. In one form a large swelling is found in which the presence of viscera can be seen through the thin translucent membrane which covers it.

The umbilical cord is found at the summit of the swelling. The swelling usually contains only coils of intestine, but other viscera may be present. In the third form, which is quite rare, there is a complete eventration and the prolapsed viscera lie exposed without even a membranous covering.

Infantile Umbilical Hernia.—These usually present themselves in infants, but may be found even in young adults.

Examination of the umbilical region reveals a conical swelling, over which there is a loose fold of skin. The protrusion is only noticeable when the child coughs or strains. When the swelling is reduced the firm edges of the circular umbilical ring can be felt by inserting the little finger.

Umbilical Hernia in Adults.—Clinically umbilical hernia in adults appears either (*a*) as a small tumor usually lying just above the umbilicus

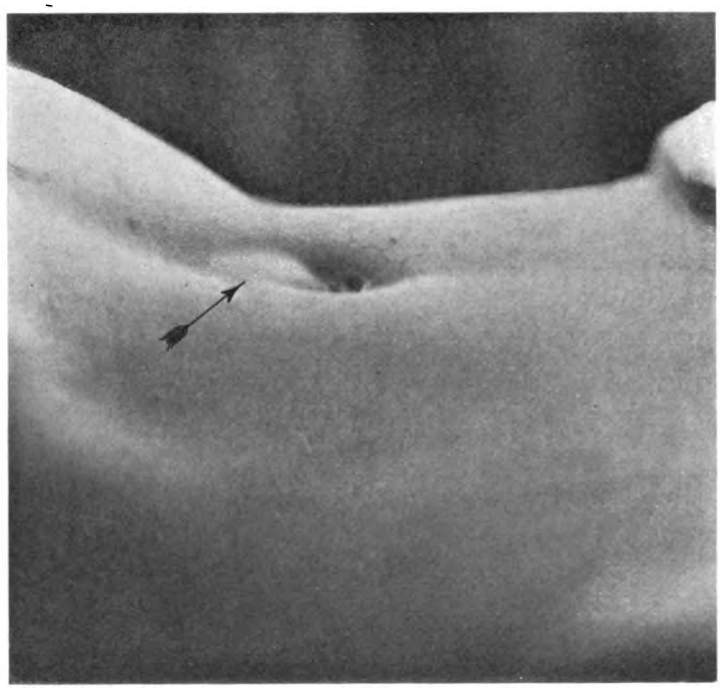

FIG. 255.—VIEW OF AN ADULT UMBILICAL HERNIA IN THE EARLIEST STAGE OF ITS DEVELOPMENT.

This illustration was made while the patient was lying down. The arrow points to the prominence situated just above the umbilicus proper (see text). The photograph was made while the patient was coughing, showing the umbilical hernia at its maximum size.

(Fig. 255), or (*b*) as a larger one which is easily recognized and which pushes the cutaneous umbilicus forward (Fig. 256).

Both forms are more apt to occur in stout persons, but the smaller variety may occur even in lean individuals and be the source of much discomfort. Such small umbilical herniæ may give rise to recurring abdominal pain and various dyspeptic symptoms, and, the hernia being overlooked, the patient is often wrongly treated (D. D. Stewart). The best method of examination for both this variety of adult umbilical and for epigastric herniæ is to inspect and palpate the median line of the

abdomen while the patient coughs, first while standing up (Fig. 256) and then upon lying down. In many of the cases the hernia is associated with a properitoneal lipoma, as in the femoral herniæ. Under these circumstances one sees a protrusion (even if only very slight) upon coughing and feels an impulse. Upon further examination it is found that the swelling does not disappear entirely upon manipulation or upon lying down, but that a soft, often lobulated mass can be felt. The latter is the small properitoneal lipoma attached to the sac.

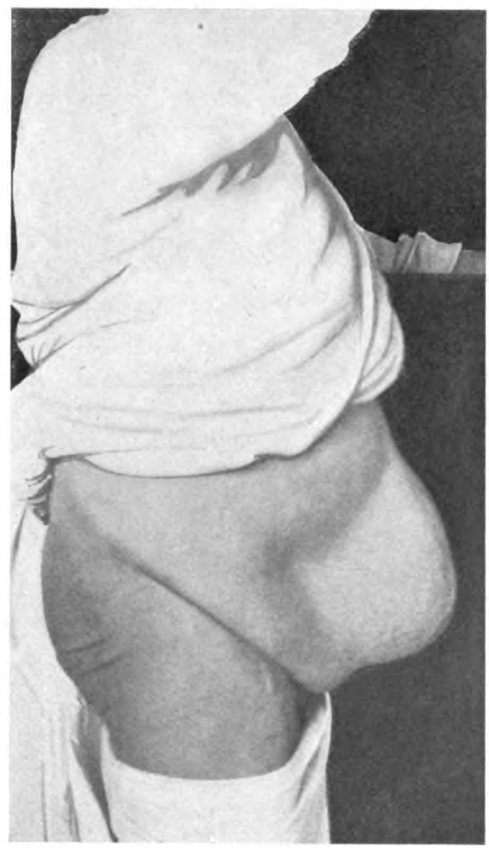

FIG. 256.—SIDE VIEW OF A CASE OF UMBILICAL HERNIA.

The coils of intestine and omental contents of this sac were adherent to the interior of the sac, so that symptoms of incarceration would appear from time to time.

These small umbilical herniæ must be differentiated from fatty tumors of the linea alba. This can be done by the absence of an impulse upon coughing and the fact that manipulation or posture, such as lying down, does not cause the tumor to disappear.

The larger umbilical herniæ present no difficulties of diagnosis. The swelling is rounded or transversely oval and often hangs down toward the symphysis (Fig. 256). The swelling is more often irreducible than the opposite. If the former is the case the tumor feels doughy and lobulated and is dull on percussion. The contents are usually composed of omentum firmly adherent to the sac and coils of intestine. Incarceration and strangulation of these larger umbilical herniæ are not infrequent complications.

If symptoms of intestinal obstruction occur in stout persons one should never fail to examine the umbilical region carefully.

The characteristics of these complications (incarceration and strangulation) have been referred to on page 403.

VENTRAL HERNIÆ.

These occur as an acquired condition, usually in the linea alba or linea semilunaris. They may occur spontaneously, or follow an operation or a trauma such as a penetrating or crushing wound. I have described a case[1] of the traumatic non-penetrating variety in which a swelling with unbroken skin appeared within a short time over the crest of the ilium in a patient who had been crushed between two cars. The abdominal muscles and peritoneum had been torn from the crest of the ilium. The ordinary spontaneous variety of ventral hernia may be found above or below the umbilicus. When they occur in the median line above the umbilicus they are spoken of as epigastric herniæ. They are often the cause, like the small umbilical herniæ, of recurrent abdominal pain and symptoms of digestive disturbance. The diagnosis of these epigastric as well as of the other forms of ventral herniæ is not difficult. In some cases there is no visible swelling and a diagnosis can only be made by passing the fingers along the median line and the semilunar line while the patient coughs. The characteristic impulse and the appearance of a swelling enable one to make the diagnosis. These ventral herniæ may attain such a large size that practically all of the hollow viscera and omentum are contained in them. In very stout persons an enormous overhanging mass of fat will at first sight simulate such a hernia (Fig. 243).

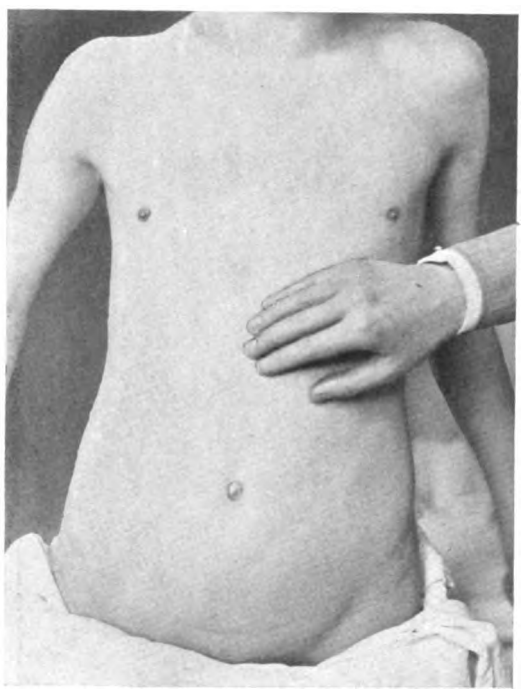

FIG. 257.—METHOD OF PALPATING AN EPIGASTRIC HERNIA.

The finger-tips of the examiner should be placed successively upon different points in the linea alba from the ensiform downward and the patient instructed to cough.

In every case presenting symptoms of chronic gastritis, gallstones, or

[1] "Annals of Surgery," 1904.

ulcer of the stomach one should examine for the presence of an epigastric hernia.

A hernia following a laparotomy can be recognized from the history, the scar, and the signs characteristic of all reducible herniæ, viz., a swelling which disappears, often with a gurgle, upon manipulation or upon lying down, and reappears with an impulse upon standing up or after exertion such as coughing, etc.

RARER FORMS OF HERNIÆ.

Obturator Hernia.—This form can seldom be recognized until symptoms of strangulation appear. The protrusion occurs through the obturator foramen and can occasionally be felt externally just below the pubes on the inner side of the femoral vessels. It may also cause pain, which is referred to the knee along the distribution of the obturator nerve. If strangulation occurs, the condition must be differentiated from rheumatism by the absence in the latter, of symptoms of intestinal obstruction, and from pelvic peritonitis, by the bimanual examination of the pelvis. Obturator herniæ are most apt to occur in elderly females.

Diaphragmatic Hernia.—This has been previously described in connection with injuries of the thorax (page 197).

Lumbar Hernia.—This may occur anywhere behind the linea semilunaris and between the last rib and crest of the ilium. These herniæ may be congenital or acquired, the former often being bilateral. The acquired form may be either spontaneous or traumatic. The former usually protrude through the triangle of Petit, just below the twelfth rib, as a swelling which has all the signs just referred to as typical of a reducible hernia. One must differentiate the spontaneous variety from a lipoma, and from a cold abscess due to disease of the spine.

The traumatic variety may either follow an operation upon the kidney or some crushing injury, such as described under traumatic ventral hernia.

The diagnosis does not differ from that of the spontaneous variety.

Sciatic Hernia.—This occurs through the sacrosciatic foramen, forming a swelling in the gluteal region. Very few cases have been recorded of this variety of hernia. When the hernia is small it may escape recognition unless a careful examination for such symptoms as pain over the gluteal region be made. If the hernia is large it gives rise to a distinct gluteal swelling with a marked impulse on coughing and reducibility with a gurgling sound if intestine is present in it. It must be differentiated from an abscess due to hip disease, from a lipoma, and from an aneurysm.

CHAPTER V.

THE EXTREMITIES.

INJURIES OF THE SOFT TISSUES, BONES, AND JOINTS.

In attempting to make a diagnosis as to the nature of injuries received as the result, either of a recent accident, or of one sustained at some previous period, the following possibilities must be borne in mind, and each one eliminated by a process of exclusion, based upon a thorough examination and history of the case.

These possible injuries and their complications are:

INJURIES OF THE SOFT PARTS.

Location.	Nature.	Possible Complications or Results.
1. Skin and subcutaneous tissue.	(*a*) Penetrating wounds; lacerated, punctured, incised, gunshot.	(*a*) Infection with ordinary pyogenic organisms (streptococci and staphylococci).
	(*b*) Non-penetrating wounds or contusions.	(*b*) Tetanus.
		(*c*) Erysipelas and erysipeloid.
		(*d*) Infection with gas-producing bacilli.
		(*e*) Anthrax.
2. Muscles	Contusions, penetrating wounds, rupture of muscles.	Traumatic myositis, myositis ossificans. Loss of function.
3. Tendons and tendon-sheaths	Lacerated or incised wounds. Rupture of tendon, dislocation of tendons.	Infective tenosynovitis, ganglion. Loss of function.
4. Bursæ	Contusions. Penetrating wounds.	Acute suppurative and non-suppurative bursitis.
5. Blood-vessels	Penetrating wounds or contusions of arteries or veins.	Phlebitis. Gangrene of extremities. Ulcers (trophic). Traumatic aneurysms.
6. Nerves	Contusions or penetrating wounds of nerve-trunks or filaments.	Neuritis. Paralysis of motion or sensation or both.

INJURIES OF THE BONES AND JOINTS.

Location.	Nature.	Complications.
1. Bones	Contusions or penetrating wounds of periosteum. Simple or compound fractures.	Periostitis or necrosis of bone. Infection. Injury of nerve. Injury of vessels. (Gangrene or aneurysm.) Coxa vara traumatica.
2. Joints	Sprains. Penetrating wounds. Dislocations: simple and compound.	Septic arthritis. Injury to cartilages or ligaments. Paralysis of nerves.

INJURIES OF THE SOFT PARTS.

The most important points to be determined in the examination of an injury of the extremities are: (*a*) the location of the injury; (*b*) its nature or extent; (*c*) whether complications exist or not. In order to be able to answer these, a careful history must be taken of the manner in which the accident occurs, next the physical examination of the part involved, as well as the observation of the general condition.

Injuries of the skin consist of either simple or complicated wounds. In the simple variety there is an injury of the skin and subcutaneous tissues alone, either (*a*) in the shape of a lacerated, incised, punctured, or gunshot wound, often called a penetrating wound, or (*b*) a collection of blood in the subcutaneous connective tissue of greater or less extent, called a non-penetrating wound or contusion (bruise).

In the penetrating wounds of the simple variety, there is no difficulty in making a diagnosis. The edges of the wound gape to a variable extent and the subcutaneous fat may prolapse. The amount of bleeding varies according to the vessels severed. If from an artery, it occurs intermittently and is bright red in color. If from a vein, the flow is continuous and of a darker color. If from the capillaries, called parenchymatous hemorrhage, it is steady in character, but the amount is not so great as is that from an artery or vein.

All the penetrating wounds of the skin may be associated with more or less contusion, *i. e.*, laceration of the soft parts with hemorrhage into them, or the latter condition, known as a contusion, may exist without any such penetrating wound.

A *simple contusion* causes a painful swelling of the skin which may either be quite circumscribed or occupy a considerable area. Discoloration of the skin often occurs at a very early period, or may not appear until after some days, the skin becoming at first bluish, then yellowish in color.

Both penetrating and non-penetrating wounds of the skin may be complicated in the following ways: (*a*) There may be an associated injury of the other structures in the limb. (*b*) The injury may be complicated by symptoms of shock or of general anemia from hemorrhage. (*c*) One of the so-called accidental wound infections or other sequelæ may be complicating the clinical picture.

Signs of Injury of Other Soft Parts.—These may often be ascertained by inspection of the wound. In some it will be necessary either to retract the edges or to secure the information through (*a*) the discovery of loss of function of a muscle, tendon, or nerve;

(*b*) through hemorrhage or gangrene resulting from injury of an artery or vein.

If it becomes necessary to examine a wound the utmost precaution should be taken to prevent infection. In the majority of cases the location of the wound in relation to important anatomic structures and the observation of loss of function will suffice, so that a direct inspection of the wound is rarely necessary for diagnostic purposes.

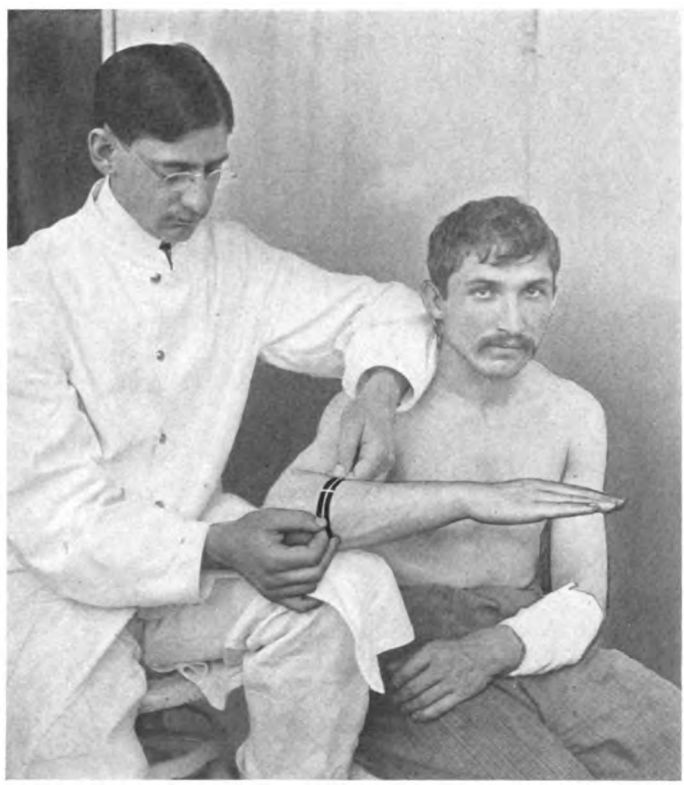

FIG. 258.—METHOD OF MEASURING THE FOREARM IN ORDER TO DETERMINE ATROPHY OF THE SAME. The patient may be examined while lying down. The point for measuring the circumference is at the level of the greatest amount of muscular development of the forearm.

INJURIES OF MUSCLES, TENDONS, AND TENDON-SHEATHS.

Contusions of Muscles.—A contusion of a muscle may be suspected if there is inability to use the muscle combined with localized tenderness and pain shortly after the injury. A little later, such muscular injury can be suspected if there is rapid atrophy, as determined either by palpation or by the measurement of the circumference of the limb

and comparing it with that of the opposite one (Fig. 258). Such loss of function and atrophy of a muscle may be due to injury of the nerves supplying it or to non-use of the limb following bone or joint injuries. The latter are far more frequently followed by atrophy than is an ordinary contusion of a muscle.

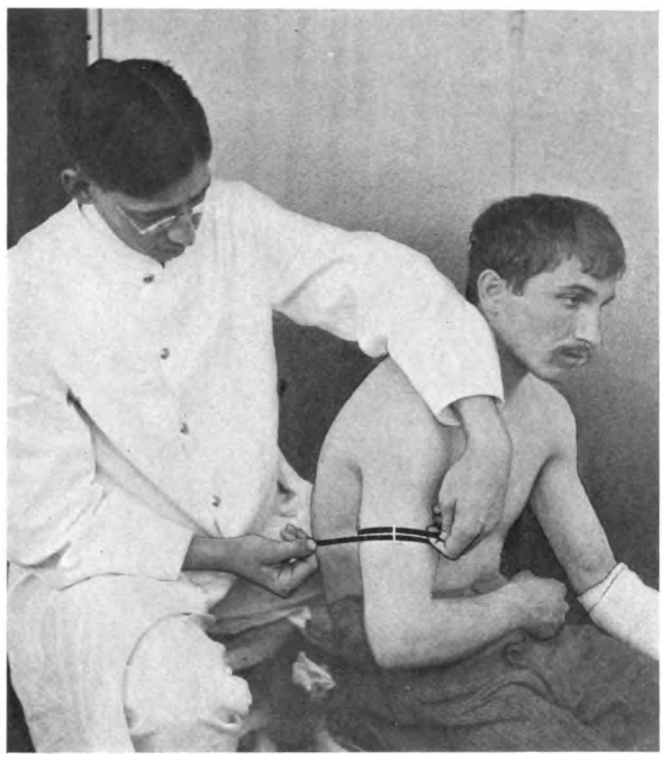

FIG. 259.—METHOD OF MEASURING THE CIRCUMFERENCE OF THE ARM REGION PROPER, IN ORDER TO DETERMINE ATROPHY OF MUSCLES.

This may be performed either with the patient sitting up or lying down. In all of these measurements of the circumference of extremities one of the most accurate methods is to employ a steel tape-measure, and to take as the beginning-point some inch or centimeter measurement which is not too near the end of the tape, and to hold this point opposite some point to which the circumference of the arm may cause the examiner to stretch the tape-measure. The second point is noted, and the distance of the beginning of the tape-measure to the starting-point subtracted from it. For example, if the starting-point chosen was the mark at the end of the one-inch measure, and the second point after the circumference had been measured was eight inches, the circumference of the arm would be the difference, or seven inches.

Another sequel of a muscular contusion is the formation of bone in it, a condition known as *traumatic ossifying myositis* (myositis ossificans traumatica). This condition of ossification between or within the muscles may follow either repeated slight traumas or a single but severe one.

The former are usually associated with certain occupations in which the muscles are subject to frequent injury, as the rider's bone in the adductor longus muscle of cavalry riders.

In both varieties of cases there is to be felt in the muscles a hard bony mass whose formation can be directly traced to the trauma. The presence of the osseous deposit can be confirmed by an *x*-ray examination.

Ruptures of Muscles and Tendons.—These may occur in any of the muscles or tendons of the extremities, but are more frequent in certain ones. Pure muscular ruptures occur oftenest in the biceps of the arm and in the quadriceps extensor of the thigh. Rupture of tendons occurs most frequently in the quadriceps extensor tendon, either above or below the patella. The tendo Achillis and the biceps brachii, either at its upper or lower ends, are next in frequency. These ruptures seldom occur as the result of external violence, but almost always from a violent contraction during unusual exertions.

FIG. 260.—FLEXION CONTRACTURE OF ALL OF THE FINGERS OF THE HAND.
Caused by a crushing injury which opened up the flexor tendon-sheaths.

These ruptures of muscles or tendons may be recognized from a sudden severe pain in the affected muscle or tendon, inability to use it, and the palpation of a gap at the point of rupture.

In the case of muscular ruptures this gap or depression is marked on either side by a prominence formed by the torn ends of the muscle. This gap is soon filled with a clot and becomes less prominent.

In tendon rupture, especially of the lower end of the biceps, ligamentum patellæ, or of the tendo Achillis the gap is very distinct and can be readily felt owing to the superficial positions of these tendons.

Tendons may be pulled away from their points of origin or attachment by violence such as occurs when a hand or foot or the entire extremity is torn off from the remainder of the body. The tendo Achillis

and ligamentum patellæ are often torn from their respective attachments, by sudden and violent muscular movements.

Dislocations of Tendons.—The only tendons which have so far been described as subject to this injury are those of the peroneal muscles and long head of the biceps. The condition can be recognized clinically if during contraction of the tendon the latter is felt as if springing out of its normal location.

FIG. 261.—DIRECT POSTERIOR VIEW OF A CASE OF OLECRANON BURSITIS.

Note the swelling over the olecranon process.

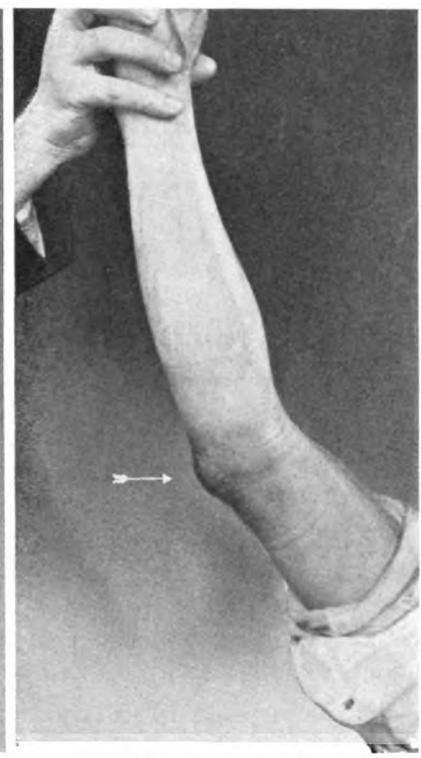

FIG. 262.—LATERAL VIEW OF CASE OF OLECRANON BURSITIS.

The white arrow points to the prominent olecranon bursa.

Herniæ of Muscles.—Either following severe contusions of the muscles with tears of the fasciæ or after penetrating wounds of the latter, a localized swelling appears during contraction and vanishes during relaxation of the muscle. After disappearance of the swelling a distinct gap can be felt in the fascia through which the muscular hernia occurred. This injury is most apt to take place in the muscles of the thigh and leg and can be readily recognized.

Penetrating Wounds of Muscles, Tendons, and Tendon-sheaths.—Penetrating wounds of muscles often occur as a part of complicated wounds of the skin, and can be readily recognized upon inspection of the cut edges or through loss of function of the muscles. If the wounds become infected, a purulent myositis may follow with sloughing of some of the muscle fibers. Tendon injuries occur oftenest on the anterior or posterior surfaces of the wrist or around the ankle and foot. The diagnosis may be made, either from inspection of the wound and observing the presence of the cut ends or by testing for loss of function in the corresponding parts, *e. g.*, inability to flex or extend the fingers or toes.

A partial severing of a tendon is of no significance unless the wound

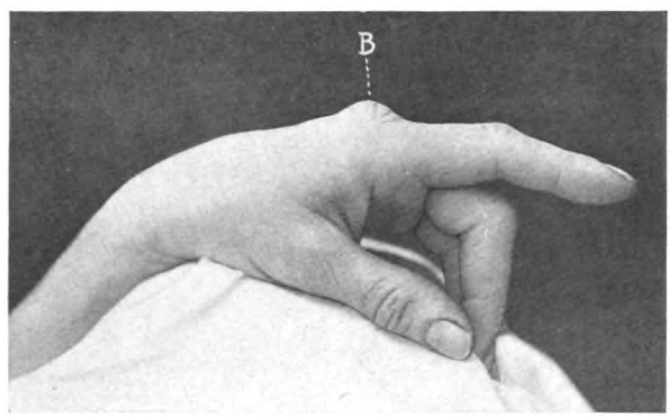

FIG. 263.—BURSITIS OF METACARPO-PHALANGEAL BURSA.
B, Points to prominence due to bursa.

is quite deep. Wounds of the hand in which the tendon-sheaths have been opened with or without laceration of the tendons are of great importance for two reasons: (*a*) the possibility of infection spreading to the forearm; (*b*) the fact that the wound in the tendon-sheath is very prone to adhere to the skin wound, causing serious cicatricial deformities (Fig. 260).

Injuries of the Bursæ.—These may occur either in the form of contusions or of penetrating wounds. In contusions of the bursæ there is rapid swelling, local tenderness, and pain. Suppuration may take place without any communication with the overlying skin being present.

Before infection has occurred, the diagnosis may be made by noting the presence of a painful swelling, which usually fluctuates dis-

tinctly, situated at the locations of the more superficial bursæ, viz., the olecranon (Fig. 261), metacarpophalangeal (Fig. 263), prepatellar, less often the subdeltoid, ischiadic, tendo Achillis, and trochanteric bursæ.

Not infrequently the skin around the swelling shows evidences of extensive contusion.

If infection occurs after a contusion or a penetrating wound of a bursa, the swelling becomes very tender, there is local redness, heat, and infiltration of the overlying skin, as well as the general signs of infection, such as elevation of temperature and pulse-rate, leukocytosis, etc.

A knowledge of the location of the more common bursæ is of great importance clinically (Fig. 265).

Injuries of the deeper bursæ, such as the subdeltoid, iliopsoas, or semimembranous, may, if they suppurate, play a rôle in spreading the infection to the large joints with which they often communicate.

FIG. 264.—DORSAL VIEW OF CASE SHOWN IN FIG. 263 (LATERAL VIEW), OF BURSITIS OF THE METACARPO-PHALANGEAL BURSA OF INDEX-FINGER.

INJURIES OF BLOOD-VESSELS.

Injuries of Arteries.—These may occur in any of the arteries of the upper and lower extremities as the result (*a*) of penetrating wounds with sharp instruments, such as a knife, razor, bayonet, etc. (*b*) In severe contusions of a limb, when an artery like the femoral or brachial is firmly compressed against the pubes or humerus respec-

tively. (*c*) As a complication of gunshot wounds or explosion of shells, etc. (*d*) In extensive crushing injuries of a limb. (*e*) As the result of a simple or compound fracture, a fragment either penetrating the vessel or the wall becoming necrotic from pressure of the displaced fragments upon it (Fig. 266).

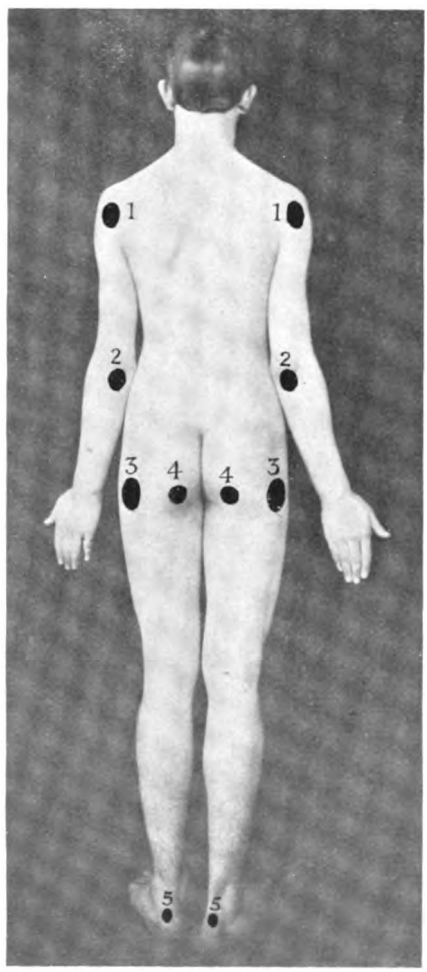

FIG. 265.—LOCATION OF VARIOUS BURSÆ.

1, Subdeltoid; 2, olecranon; 3, trochanteric; 4, ischial; 5, bursa beneath tendo Achillis at its insertion in the os calcis.

The **diagnosis** of an arterial injury is based upon (*a*) certain primary symptoms which immediately follow the injury; (*b*) other signs appearing at a later period, so-called secondary signs. The symptoms indicating an arterial injury which occur *immediately* depend upon whether the vessel has been completely or partially severed and whether the hemorrhage has ceased spontaneously.

If one can observe the characteristic red spurting of an arterial hemorrhage, the diagnosis is easy. The cases are rarely seen at such a time, the bleeding, if it has been severe, either having caused speedy death or the extreme anemia occasioned by great loss of blood results in such slowing of the heart's action, that only a slight flow takes place from the end of the torn artery.

The majority of cases are seen at a time when the hemorrhage has been temporarily checked, either through the feeble action of the heart following the severe loss of blood or as a result of a plugging of the tear in the artery by a thrombus or retraction of the vessel.

If a large wound exists in which the torn vessel can be seen, the diagnosis is also easily made.

Usually a diagnosis depends upon the *recognition of other primary and secondary signs.* The remaining primary signs are: (*a*) the absence of a pulse in the peripheral vessels of the cold and pale limb; (*b*) the presence of a rough rasping murmur, synchronous with the pulse and resulting from the projection of a thrombus into the lumen; (*c*) the appearance of a large hematoma in the neighborhood of the injured vessel accompanied by signs of severe anemia.

The so-called *secondary or late evidences of an arterial injury* are the appearance (*a*) of a traumatic or false aneurysm; (*b*) of beginning gangrene of the limb; (*c*) the occurrence of severe secondary hemorrhage, usually about the sixth to ninth day.

Traumatic or *false aneurysms* are more apt to follow stab than gun-

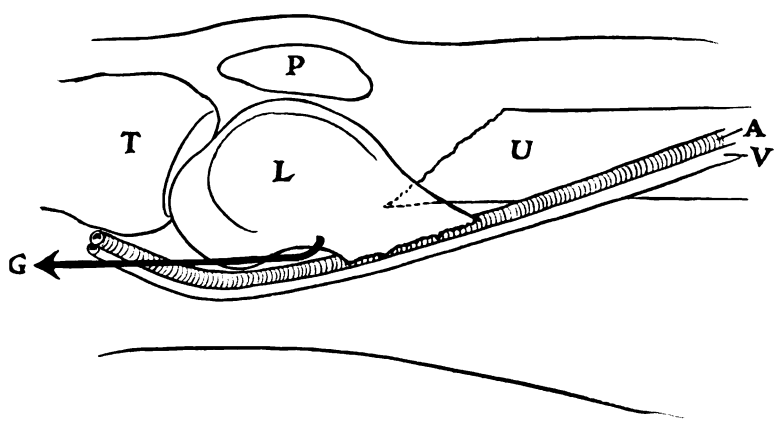

FIG. 266.—SUPRACONDYLOID FRACTURE OF FEMUR.

The illustration shows how the gastrocnemius muscle, whose action is represented by the black arrow, terminating at the letter G, causes the lower fragment to be pulled downward and backward, impinging upon the popliteal artery and vein, and resulting in gangrene of the leg in some instances.

shot wounds. Clinically they can be recognized by the appearance of a swelling in the vicinity of the original wound or proximal to it (Fig. 267), which shows a distinct expansile thrill and a blowing, often rough, systolic murmur. At a later period, varicosities of the superficial veins become very marked. If both artery and vein are injured simultaneously, and this is not infrequent, the symptoms in the early period do not differ, as a rule, from those of injury of the artery alone, except by an increased amount of edema of the limb. Later on, this swelling becomes quite marked and is accompanied by other signs, such as a continuous murmur, which is transmitted in a proximal and distal direction in both artery and vein. There is frequently also distinct venous pulsation and the veins become varicose (Fig. 199).

The arteries most often injured are the subclavian, axillary, bra-

chial, and radial in the upper, and the femoral and popliteal in the lower extremity.

Injuries of the Veins.—With the exception of injuries of the larger venous trunks, these are of less importance and are rarer than the same conditions in the arteries. As in the case of the latter, the diagnosis may be made from certain primary or immediate and secondary or late signs. They may occur as the result of the same causes which were mentioned as producing arterial injury. In addition, the veins are often wounded during operations for the removal of tumors or enlarged lymph-nodes, and rarely during the performance of a herniotomy. The larger trunks most often injured are the subclavian, axillary, brachial, femoral, and popliteal. The *primary signs* of vein injury are: (*a*) Hemorrhage, which is seldom as great as after injury of the corresponding artery, but may be quite severe; it increases when the limb is held down. The blood is of a dark color and flows in a steady stream. (*b*) The entrance of air into the vessels. This rarely occurs in wounds of the veins of the extremities.

FIG. 267.—ANTERIOR VIEW OF PATIENT WITH TRAUMATIC ANEURYSM OF FEMORAL ARTERY AND SECONDARY ANEURYSM OF EXTERNAL ILIAC ARTERY.

(1) The black semicircle below this figure indicates the size of the iliac aneurysmal sac as palpated through the abdominal wall; (2) extent of sac of aneurysm in femoral artery; (3) wound of entrance of knife.

The *late or secondary signs* are (*a*) the formation of an arteriovenous or (*b*) of a varicose aneurysm, if the artery is simultaneously injured (page 433). These are usually the result of stab and gunshot wounds and only occur in the larger vessels of the extremities.

The symptoms of arteriovenous aneurysms vary somewhat according to the relations of the two vessels.

1. If there is a wide communication of an arterial aneurysm with the vein, the pulse is transmitted to the latter, gradually decreasing in intensity from the point of contact in both directions. In addition

to the systolic arterial, there is a continuous rough, sawing, venous murmur, often more marked during the diastole.

2. In an aneurysmal varix compression of the artery above the communication causes the sac to disappear, which is not the case in the first named variety. There is considerable edema of the limb and marked varicosities.

3. If there is a direct narrow communication, between the artery and vein, the only sign is a continuous rasping murmur transmitted along the vein, which ceases when the artery is compressed.

Before leaving the diagnosis of vessel injury, it is desirable to refer briefly to the fact that apparently insignificant wounds, wherever situated, in the body of a class of persons suffering from a condition known as *hemophilia*, may bleed profusely and most persistently. This complication must always be borne in mind in cases of obstinate hemorrhage from comparatively insignificant wounds.

In addition to such unusual hemorrhage from wounds, whether operative or accidental, these individuals often have other symptoms of diagnostic value.

These latter are: (*a*) The occurrence of purpuric spots, petechiæ, or ecchymoses into, or of hematomata beneath the skin. (*b*) Hemorrhages from various mucous cavities, like the stomach or intestine. (*c*) The occurrence of multiple joint swelling as described on page 624.

INJURIES OF THE NERVES.

These may be partial or complete. The former are called *contusions* and the latter *lacerations or solution of continuity*. The nerves of the extremities belong to the class of mixed motor and sensory nerves, hence any injury will cause a disturbance of their function which varies according to the degree of the injury.

The diagnosis may, in general, be made from the following specific signs:

1. Paresis or paralysis of the muscles supplied by the injured nerve or nerves. The paresis or paralysis will be either complete or incomplete, depending upon whether the affected muscle or muscles are supplied by the injured nerve alone or by several nerves.

2. Disturbances of sensation. There may be simple paresthesia or complete anesthesia. If the latter exists, the area will seldom correspond exactly to the normal cutaneous area supplied by the nerve. This is due to the fact that the anastomosis of the nerves of the skin is so free that, within a short period, the neighboring filaments often

assume the function of the sensory endings of the injured nerve. Complete anesthesia usually follows the injury of several nerves of an extremity.

In addition to the disturbances of tactile sense, there is often severe pain along the course of the nerve. This is most frequently the case in those nerves which are gradually compressed, as by a callus or by the end of a dislocated bone. The appearance of pain usually indicates an incomplete solution of continuity. It has been frequently shown that compression of mixed sensory and motor nerves first causes disturbances of the tactile sense and ability to recognize cold, while at a later period there is absence of heat sensation and the appearance of pain.

3. Vasomotor and trophic changes. The former causes redness and local rise in temperature, which are followed gradually by cyanosis and coldness of the limb. The trophic changes are usually most marked in the skin, rarely in the bones and joints unless the injury occurs early in life. The skin becomes smooth and shining, loses its elasticity, and deep ulcerations may occur. There is marked atrophy of the muscles and the joints become stiff and painful.

4. Changes in electrical reaction. In mild forms of contusion due to compression of the nerve there is seldom any change. Even though the paralysis be a complete one, after a contusion there may be no change in the electrical reaction.

If, however, the nerve is completely severed, the response of the nerve toward both faradic and galvanic stimulation begins to sink about the second day, and ceases completely by the end of the second week. The affected muscles also fail to respond to the faradic current, but show an increased irritability toward the galvanic. These changes may persist for some time after the muscles begin to respond to voluntary impulses.

5. The appearance of a tumor at the seat of injury. In some cases neuromata develop at the point where the nerve has been either contused or severed. A spindle-shaped enlargement can often be felt at the point where the nerve has been injured or cut, after a variable period, usually two to three months. In some cases, as in amputation stumps, it may be exquisitely tender to the touch.

Injuries of the nerves occur as the result either of pressure or of laceration of the nerve. The former may (*a*) immediately follow a single trauma, like a blow or a kick or the application of a constrictor; (*b*) it may follow the pressure of crutches (crutch paralysis); (*c*) the nerve may become compressed between the fragments of a fracture or by

a callus (Fig. 268). Lacerations of nerves follow (*a*) gunshot, stab, or any variety of wound made by cutting or tearing violence; (*b*) penetration by a fragment of bone in fractures; (*c*) crushing of the nerve without an external wound.

INJURIES OF THE INDIVIDUAL NERVES.

The **circumflex nerve** is most frequently injured in connection with fracture of the surgical neck of the humerus. It may also be injured in dislocations of the shoulder as well as in severe sprains, without fracture. The principal symptom is paralysis of the deltoid resulting in inability to raise the arm from the chest and in such marked atrophy that the normal convex outline of the shoulder is lost.

The **musculospiral nerve** is more often injured than any other in the body. In the axilla it may be compressed by the head in dislocations of the humerus or by the pressure of a crutch. At the middle of the shaft (Fig. 268) it may be compressed by too tight an application of a constrictor, or more often by being caught in a callus in fractures at this level. It may be torn by blows over this place without any wound of the skin. Its continuation, the radial nerve, is often severed in gunshot wounds of the forearm or in incised wounds just above the wrist.

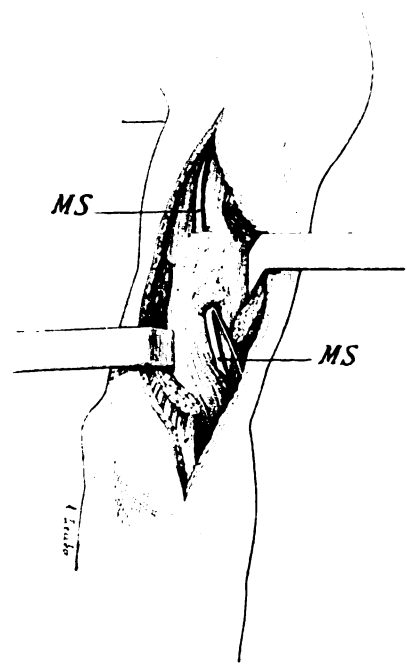

FIG. 268.—MUSCULOSPIRAL NERVE COMPRESSED BY A CALLUS RESULTING FROM A FRACTURE IN MIDDLE OF SHAFT OF HUMERUS (Lejars).

MS, Musculospiral nerve above and below point of compression by callus.

The motor symptoms vary somewhat according to the level of the injury: (*a*) If in the axilla, the elbow, wrist, and fingers cannot be extended. (*b*) If at the middle of the humerus, the elbow can be extended but there is inability to supinate the forearm and to flex it, when

half-way between supination and pronation (supinator longus action). There is, in addition, the loss of movements of extension of the fingers and wrist. (*c*) If below the humerus, the elbow can be extended

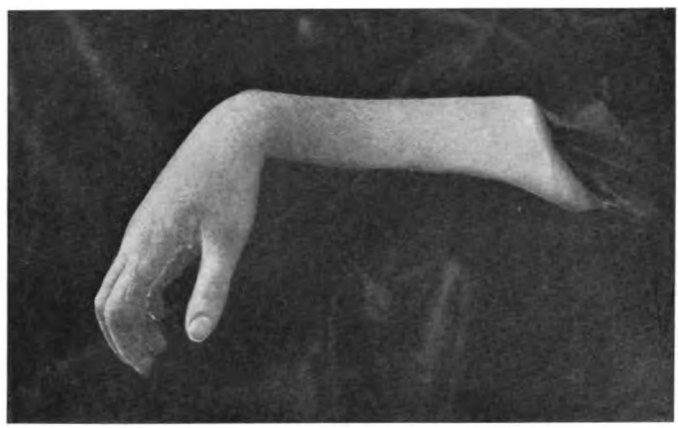

FIG. 269.—WRIST-DROP.

Due to pressure paralysis of the musculospiral nerve, following too tight an application of an Esmarch constrictor.

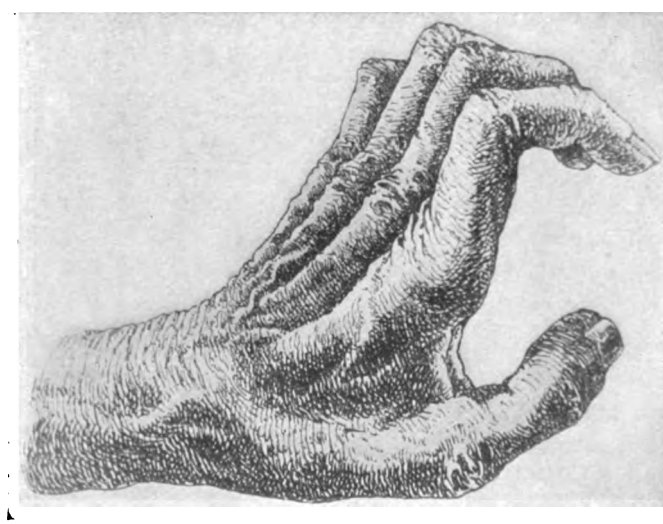

FIG. 270.—CLAW-HAND (MAIN EN GRIFFE) FOLLOWING ULNAR PARALYSIS (Leube).

and forearm supinated, but the inability to extend the wrist and fingers is more prominent (Fig. 269), causing the deformity known as wrist-drop.

The sensory symptoms are often so slight as to escape notice at

first, because the median and ulnar nerves establish a collateral supply. When anesthesia is present it is most marked over the back of the thumb and index-finger.

The **ulnar nerve** is injured either in gunshot or stab wounds of the forearm or in incised wounds just above the wrist. The motor symptoms are inability to flex the first and to extend the second and third phalanges of the fingers, resulting in a claw-like deformity (Fig. 270). The thumb cannot be adducted nor can the wrist be drawn toward the ulnar side. As a rule, there is anesthesia only over the little finger.

The **median nerve** is most often injured in the same manner as the ulnar. The motor symptoms are inability to flex the fingers except the ring and little fingers. The first phalanges of the fingers cannot be flexed on account of paralysis of the interossei muscles. The thumb cannot be flexed or abducted. The area of anesthesia is usually very small and most marked over the volar surfaces of the thumb, index, and middle fingers.

FIG. 271.—DUCHENNE PARALYSIS.

Due to tearing of the fifth and sixth cervical nerves during birth, close to their point of emergence from the spinal cord. (See text.) The position of the hand is typical.

The **brachial plexus** may be injured (*a*) through tearing of one of the nerve-roots close to its emergence from the spinal cord. These are known as birth paralyses. The most frequent type is that known as the Duchenne (Fig. 271). (*b*) In the axilla, as the result of dislocations or gunshot wounds. (*c*) In fractures and other injuries of the upper arm or forearm regions, several of the nerves of the plexus may be involved simultaneously. Of chief interest is the first named mode of injury, viz., traction on the arm during birth. It may result in a subluxation of the humerus simulating a true dislocation. There is

inability to raise the arm and to supinate the forearm, the latter being held pronated with a drop-wrist deformity.

The sciatic nerve and its branches are oftenest injured in the lower extremity. The main trunk may be severed by gunshot or stab wounds of the thigh. It is rarely caught by a callus or compressed by fragments at the time of injury, in supracondyloid fractures of the femur. Injuries of the main sciatic trunk are quite rare. They result in the absence of ability to use any of the muscles below the knee as well as inability to flex the knee-joint. There is anesthesia over a narrow strip from the gluteal fold to the calf of the leg, which then spreads so as to embrace all of the leg and foot except an area along the inner side supplied by the internal saphenous.

The **external popliteal** or **peroneal nerve** has been caught in a callus in fractures of the upper end of the fibula. Injury of this branch results in inability to raise the outer edge of the foot (paralysis of peronei), to extend the toes, or to flex the ankle. There is an area of anesthesia over the outer half of the front of the leg and dorsum of the foot.

GENERAL CONSIDERATIONS OF INJURIES OF THE BONES.

Injuries of the bones and joints of the extremities are so often associated that they will be considered together. Before taking up the diagnosis of injuries of the individual bones and joints, a short review of their more general characteristics will be of value.

These are, as a rule, of two varieties: (*a*) contusions; (*b*) fractures.

Contusions of the Bones.—These are the result of direct violence and affect the periosteum. For this reason the condition is often spoken of as a traumatic periostitis. The periosteum becomes greatly thickened and very tender. The diagnosis can readily be made by palpation in the more superficial bones like the tibia, where it most frequently occurs. At times the swelling in the periosteum becomes quite localized and fluctuates as the result of the liquefaction of a hematoma. In some places, like the neck of the femur, a contusion of the bone may be followed by softening and bending of the bone. (See Coxa Vara Traumatica.) The periosteum remains thickened for some time and then gradually resumes its normal size.

Fractures.—These are divided according to various criteria: (*a*) Into *incomplete and complete*, according to whether or not the line of fractures passes partly or entirely through the bone. (*b*) Into those which occur in a normal bone or in one changed in its structure as the result of disease (*pathologic fractures*). (*c*) Into those in which there

is no communication between the wound in the skin and the seat of fracture, called *simple or closed fractures*, and those in which there is such a communication, called *compound or open fractures*. A third class in this division are the fractures which are associated with injury of nerves, blood-vessels, etc., and called *complicated fractures*.

A fourth class also belongs to this group, viz., the *gunshot fractures*.

Incomplete fractures are subdivided as follows: (1) Fissured. (2) Greenstick or infraction (Fig. 272). (3) Depressions. (4) Separation of a splinter or apophysis.

Complete fractures are subdivided according to the direction of the line of fracture into:

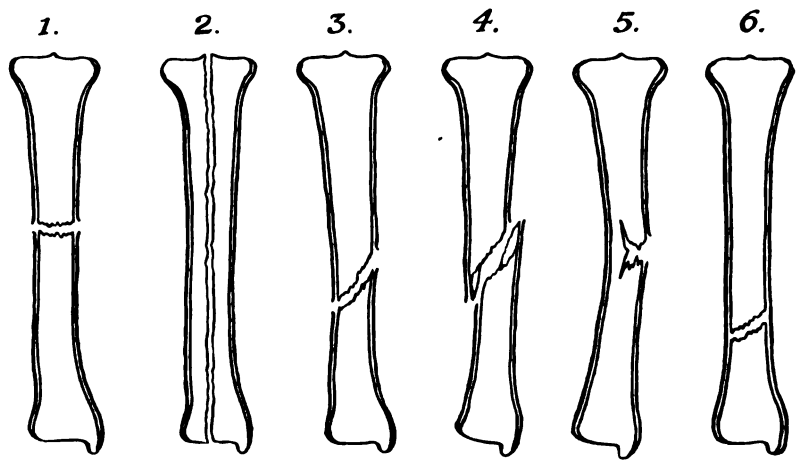

FIG. 272.—VARIOUS FORMS OF LINES OF FRACTURE.
1, Complete transverse; 2, longitudinal; 3, oblique; 4, spiral; 5, incomplete or greenstick; 6, subperiosteal.

1. *Transverse.* These are rare in the shaft of the long bones and are usually found in the lower end of the radius, in the femur, and in the short bones.

2. *Longitudinal.* Only two cases have been reported of this form of fracture line.

3. *Oblique.* This is the most frequent form in the shaft, but occurs less often in the epiphysis. If in the latter portion of the bone, it is either confined to it alone or extends from it, into the shaft.

4. *Spiral.* This was formerly considered a rare form of fracture. With the more systematic use of the *x*-ray as a portion of the routine of diagnosis, they are found to occur far more frequently than was thought to be the case. They are usually the result of a rotating or

twisting force and occur oftenest in the femur, then in the tibia, humerus, and fibula. There is a great tendency in this variety to penetrate the skin.

Number of Fragments.—In the majority of fractures there are only two fragments. In many, however, the bone is broken in such a manner that there are three or more fragments. If each of the latter are large, the fracture is called a multiple one; but if they are quite small, as after a crushing force, the fracture is termed a comminuted one (Fig. 340). The lines of fracture may resemble a letter Y or T, and this variety is especially apt to occur at the epiphyseal ends of certain bones, like the humerus.

Displacement of Fragments.—This either occurs at the time of the

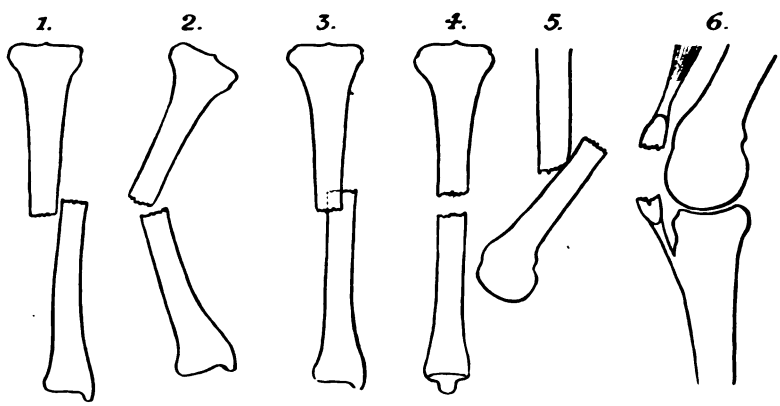

FIG. 273.—VARIOUS FORMS OF DISPLACEMENT OF FRAGMENTS IN FRACTURES
1, Lateral; 2, angular; 3, overriding; 4, axio-rotation; 5, overlapping and angular combined; 6, great separation of fragments.

accident or as a result of the weight of the limb or the action of muscles at a later period. The various forms are: (*a*) Dislocatio ad axin or angular deformity. This seldom occurs alone, but usually in conjunction with one or all of the other varieties. (*b*) Dislocatio ad latus or lateral or side-to-side displacement (Fig. 273). This rarely occurs in a pure form except in transverse fracture. (*c*) Dislocatio ad longitudinem or overlapping or overriding of fragments. This form is one of the most frequent results of oblique fractures. (*d*) Dislocatio ad axin or rotary deformity. In this variety the surfaces of the bone (Fig. 273) which are normally in apposition have rotated upon each other.

Seat of Fracture.—A fracture may (*a*) involve the diaphysis or shaft of a long bone, or (*b*) the epiphysis, or (*c*) occur through the epiphyseal cartilage (epiphyseal separation), or (*d*) it may occur through

a special anatomic point, either a constriction (neck of femur), a depression (olecranon fossa), or an elevation of the bone (trochanter, tuberosities).

Subperiosteal Fractures.—A special variety of fracture has been recently described by Hennig[1] and others and called subperiosteal. In these the diagnosis can only be made at the time of the injury by the use of the *x*-ray, the latter mode of examination often revealing a fracture passing through the entire shaft but not causing any injury of the periosteum (Fig. 274). It is important to recognize these on account of the resultant static deformities, such as flat-foot, knock-knee, coxa vara or valga, etc.

Pathologic or Spontaneous Fractures.—The more correct term for those fractures, which occur either after slight or practically no trauma in bones which are not normal in structure, is *pathologic fracture.* One of the best classifications is that given by Grunert.[2]

I. *Fractures Associated with Local Lesions of Bone.*
   A. Tumors.
      1. Primary and metastatic sarcoma.
      2. Metastatic carcinoma.
      3. Metastatic thyroid tumors.
      4. Solid enchondroma and benign bone cysts.
      5. Echinococcus cysts.
   B. Inflammatory processes.
      1. Infectious osteomyelitis (pyogenic).
      2. Tuberculosis of bone.
      3. Syphilis.
      4. Aneurysms.

II. *Fractures Associated with General Diseases.*
   A. Neuropathies.
      1. Tabes dorsalis.
      2. Syringomyelia.
      3. Mental diseases.
   B. Senile changes.
   C. Exhausting chronic diseases.
   D. Atrophy due to non-use.
   E. Scurvy.
   F. Rickets and Osteomalacia.

III. *Idiopathic Friability of Bone* (osteoporosis, fragilitas ossium).

It is of importance to note that in many cases, especially in those of primary sarcoma, tabes, syringomyelia, etc., the fracture may be the first symptom. In general, it is well to remember that a *fracture occur-*

[1] "Deutsche Zeitschrift für Chirurgie," Bd. lxxv. [2] Ibid. Bd. lxxvi.

ring after the use of a minimum amount of force should be investigated as to the possibility of its being of a pathologic variety. Union may rarely occur in the ordinary manner after these fractures.

The Healing of Fractures.—Union by callus formation occurs a little more rapidly in children than in adults. The average length of time required for firm union is as follows: (*a*) For the ribs—three weeks; (*b*) for the forearm, humerus, clavicle, bones of leg—four to five weeks; (*c*) for the femur—six to eight weeks.

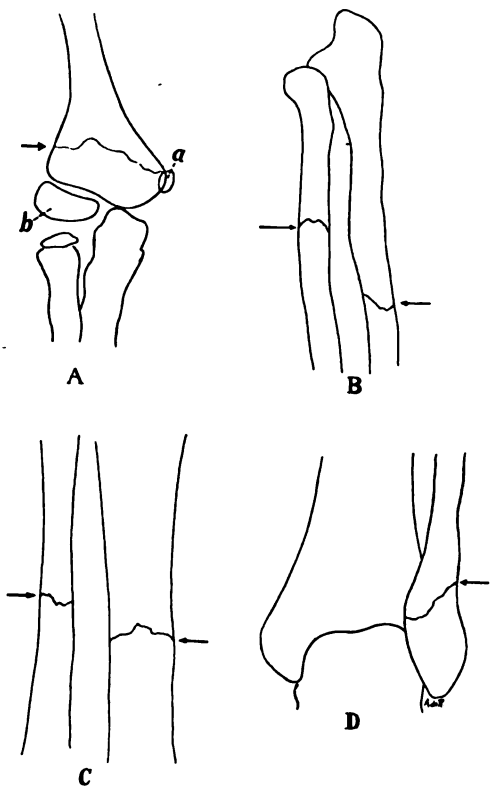

FIG. 274.—SUBPERIOSTEAL FRACTURES (Lauenstein).

A, Of the lower end of the humerus; *a*, internal condyle epiphysis; *b*, external condyle epiphysis. The arrow in all of the figures points to the seat of the fracture. B, Subperiosteal fractures of the ulna and radius; C, of the tibia and fibula at middle of shaft; D, of the external malleolus.

Simple fractures and compound fractures without infection, heal more rapidly than do any other forms. Union in infected compound fractures is often greatly delayed, as is also the case with fractures involving the larger joints (intraarticular).

In children and in some adults the amount of callus formation is excessive. In superficial bones like the clavicle such an exuberant callus may simulate a displacement of fragment. The callus even in such gradually decreases in size after a short period.

Complications of Fractures.—The following are the chief complications which occur during the clinical course of a fracture:

1. *Formation of bullæ in the skin*, especially in fractures of the leg.

2. *Thrombosis and Embolism.*—Not infrequently, a thrombosis of the deep veins of the lower extremity occurs in fractures of the bones of the leg, as well as in those of the patella and femur. A marked swelling of the entire limb occurs, which is far greater than that ordinarily accompanying such a fracture. It is often observed for the first

time when a cast or other retentive apparatus has been removed and the patient allowed to get about. Quite rarely an embolus is detached and causes marked dyspnea, rapid pulse, and often results in death (Fig. 479).

3. *Fat Embolism.*—Small amounts of fat are washed off into the circulation with every fracture. Quite rarely the fat emboli lodge in the brain, lungs, and kidneys, and give rise to serious symptoms, and, in some cases, death occurs.

In the lungs, the fat infarcts are followed by edema and patches of pneumonia. The symptoms of fat embolism are usually mistaken for those of shock, but begin a little later. In some cases pulmonary symptoms, such as rapid breathing, dyspnea, and coarse râles predominate.

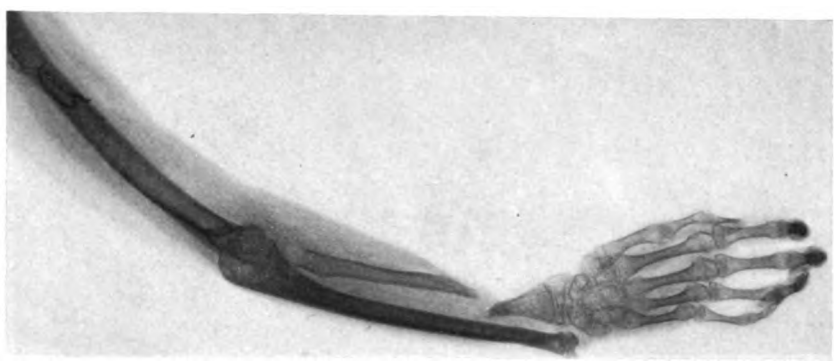

FIG. 275.—X-RAY OF PSEUDARTHROSIS OF ULNA FOLLOWING CRUSHING INJURY OF THE ENTIRE UPPER EXTREMITY.

Taken two years after the injury. Notice the well-marked lower epiphyses of the radius and ulna, and the silver wire *in situ* in the middle of the shaft of the humerus

In other cases cerebral symptoms, such as coma, twitchings, slow stertorous breathing, etc., are more marked.

4. *Injury to Blood-vessels.*—These have been described on page 429.

5. *Injury to Nerves.*—These may occur either at the time of the injury, as a result of compression or laceration of the nerve, or at a later period, through inclusion of the nerve in a callus. The recognition of these has been described on page 433.

6. *Septic Complications.*—These are more likely to occur in connection with compound fractures or as a complication of the gangrene following injury of the vessels of the limb.

The various forms of infection are the same as those which complicate other injuries of the extremities, and are described on page 529.

7. *Osteomyelitis.*—This only occurs in infected compound fractures and will be described later (page 578).

8. *Delirium Tremens and Traumatic Delirium.*—Hallucinations of vision, muscular twitchings, restlessness, and a muttering delirium accompanied by rapid heart's action, are frequent and often fatal complications of fractures in alcoholics. The same group of symptoms may occur in individuals not addicted to drink, and the condition is then called

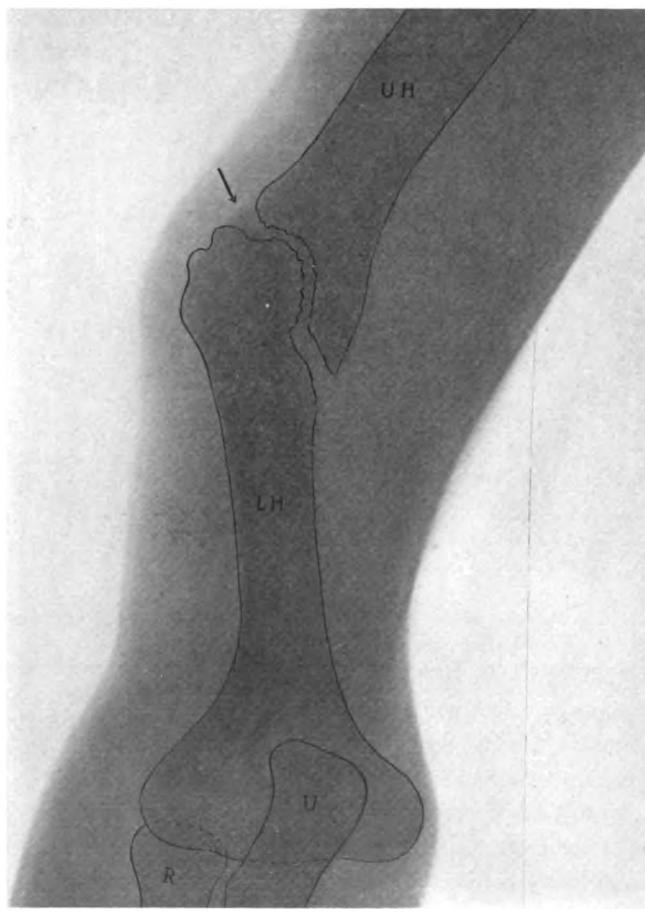

FIG. 276.—X-RAY OF PSEUDARTHROSIS OF MIDDLE OF SHAFT OF HUMERUS (G. G. Cottam).

simple or traumatic delirium. The latter is more apt to occur in elderly persons after injuries.

9. *Pulmonary Edema and Pneumonia.*—Pneumonia appears either as an early complication in a lobar form, or late as a hypostatic pneumonia. Both are more apt to occur in elderly people, and especially in alcoholics. The lobar or early type runs a rapid and severe course with

high fever and delirium. In the late or hypostatic form, the symptoms appear gradually a few weeks after the injury, with a lower range of temperature, stupor, and rapid pulse.

10. *Delayed Callus Formation (Delayed Union, Fibrous Union, or Pseudarthrosis).*—It is often difficult, if not impossible, to determine the causes of this complication.

The following are the most frequent conditions: (*a*) The union is delayed. Union does not occur within the ordinary period, but eight to twelve weeks after the fracture. (*b*) The callus does not go on to ossification but remains soft. (*c*) The fragments are held together by fibrous tissue. This can be recognized by persistence of mobility at



FIG. 277.—VIEW OF NORMAL ELBOW-JOINT OF A BOY TEN YEARS OF AGE.
R, Shaft of radius; U, shaft of ulna; H, shaft of humerus; 1, upper epiphysis of radius (capitellum); 2, epiphysis which forms the tip of the olecranon process; 3, lower epiphysis of humerus.

the point of fracture and the fact that an *x*-ray fails to show a shadow, indicating ossification of the callus (Fig. 275). (*d*) A false joint is formed at the point of fracture. The fragments are bound together by fibrous bands. A cavity is formed in which the rounded ends of the bones rub on each other (Fig. 276). (*e*) There is no attempt at union at all, the ends of the bone becoming atrophied. It is of importance to recognize the causes of non-union or delayed union. These may be divided into local and general.

(1) *Local.*—(*a*) Imperfect immobilization of fragments. This is one of the most frequent causes.

(*b*) Great separation of fragments.

(*c*) Interposition of bone, muscle, or tendon between the fragments.

(*d*) Poor blood-supply.

(2) *General.*—(*a*) Neuropathic causes, *e. g.*, tabes, syringomyelia, paralysis.

(*b*) Constitutional causes, *e. g.*, acute infectious diseases, rickets, scurvy, gout, rheumatism, chronic nephritis, diabetes, alcoholism.

11. *Faulty or Vicious Union. Union with Deformity, or Mal-union.*—This condition may be recognized: (*a*) By inspection and measurement of the limb and its comparison with the opposite one. (*b*) By palpation at the point of fracture. (*c*) By *x*-ray examination.

The most frequent causes are: lateral displacement with overriding, marked angular displacement, or rotation deformity.

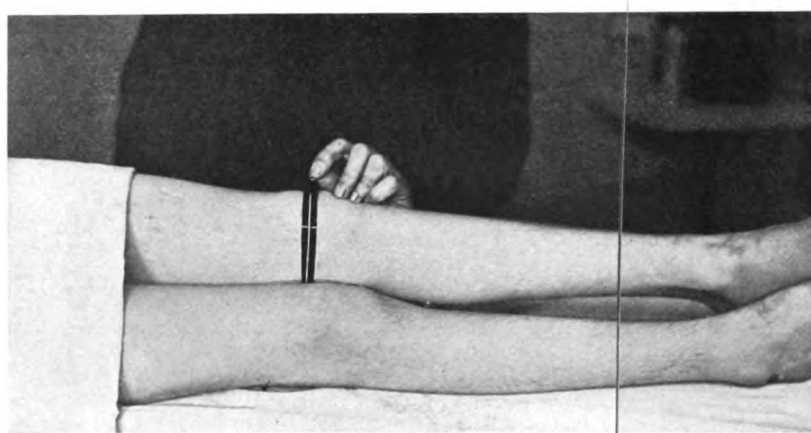

FIG. 278.—METHOD OF MEASURING THE CIRCUMFERENCE OF THE KNEE-JOINT.

In order to determine any increase in size, due to the presence of fluids, tumors, etc. (See text.) The method of measurement is the same as was described under Fig. 259.

The Diagnosis of Fractures in General.—The diagnosis of a fracture of one of the bones of the extremities does not differ from that of the bones previously considered in the chapters on the head and thorax.

The following routine should be followed in the examination of a case:

1. History of how the accident occurred.

2. Objective signs, such as deformity, abnormal mobility and crepitus, ecchymoses.

3. Subjective symptoms, such as pain, loss of function of the limb.

4. Examination with the *x*-ray.

1. *History.*—This should include the history of any previous accidents which may have caused shortening or other deformity of the limb. An exact account of how the accident occurred, will enable one to judge

however, one will find persons walking about on a fractured leg or using a broken arm.

4. *X-ray Examination.*—This method has become one of the most valuable aids in the diagnosis of injuries of both bones and joints. It serves the double purpose of confirming the diagnosis of fracture and of giving much information as to its exact nature. The *x*-ray should not be employed, however, to the exclusion of the other objective methods. It has the great advantage, especially in the case of fractures in deep-seated bones and in those close to joints, of enabling a diagnosis to be made at an earlier hour and with less manipulation than any of the other methods.

Every one should perfect himself in the examination of normal limbs by the ordinary methods of inspection, palpation, and mensuration. The examination of a fractured limb for deformity, abnormal mobility,

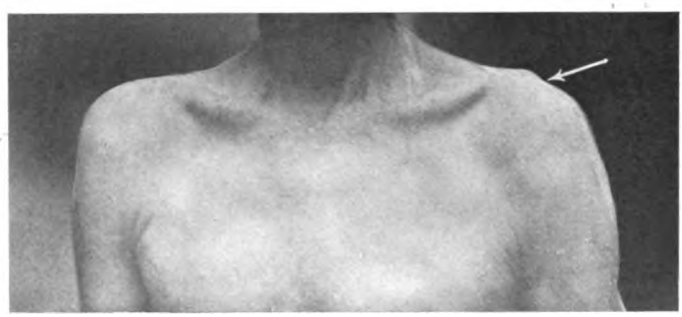

FIG. 281.—DISLOCATION UPWARD OF THE ACROMIAL END OF THE CLAVICLE.
The arrow points to the depression lying between the bony prominence, caused by the separation of the acromia end of the clavicle from the acromion process of the scapula.

and crepitus will then become a routine procedure, and the *x*-ray will occupy its true position of confirming and amplifying a diagnosis previously made by the other methods. It is essential to have a knowledge not only of the bony landmarks, etc., of the normal limbs, but of the skiagraphic appearance of the various bones and joints at all ages.

The normal epiphyseal cartilage looks to the novice like a fracture line (Fig. 277), so that one of the most valuable contributions to skiagraphy during recent years has been the study of the joints from infancy to the time ossification has been completed.[1]

It must be remembered that the amount of deformity as shown by the *x*-ray is often exaggerated and appears far greater than seems to be the case by external examination.

[1] "Fortschritte auf dem Gebiete der Roentgen strahlen."

For information in regard to the necessary time of exposure, the angle at which the picture should be taken, and other technical points one should consult the special treatises on this subject.

GENERAL CONSIDERATIONS UPON INJURIES OF THE JOINTS.

An injury to a joint, whether the force be applied in a direct or an indirect manner, will result in one of the following conditions: (*a*) A

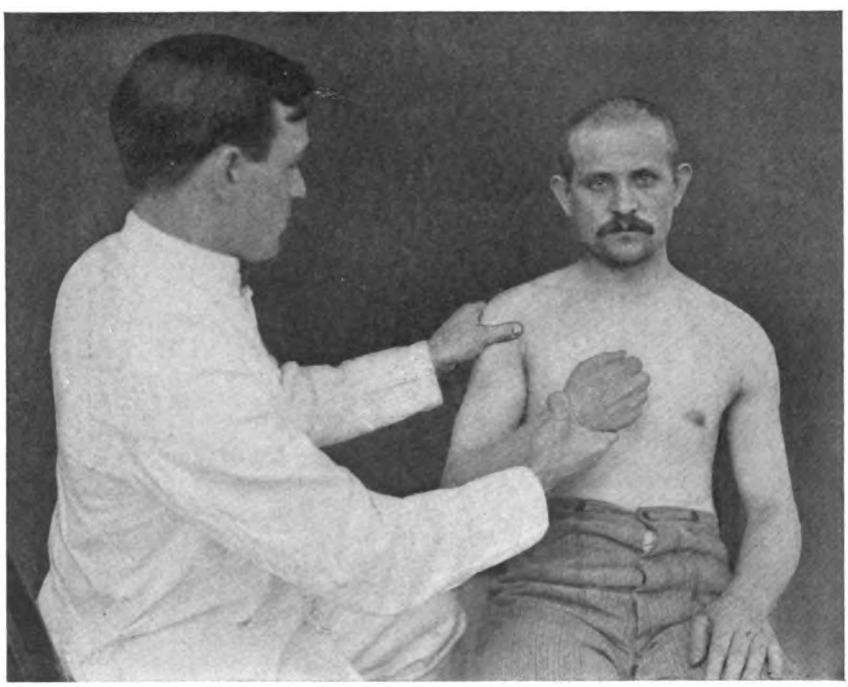

FIG. 282.—METHOD OF EXAMINATION TO BE EMPLOYED IN MAKING A DIFFERENTIAL DIAGNOSIS BETWEEN DISLOCATION OF THE SHOULDER-JOINT AND FRACTURE OF THE ANATOMICAL OR SURGICAL NECK OF THE HUMERUS.

This illustration shows the manner of examining the head of the humerus in order to determine whether it has its normal range of rotation, thus aiding in ascertaining whether the head of the humerus lies in the glenoid cavity. The method consists in grasping the forearm of the patient close to the wrist, with one hand, while the head of the humerus is held between the thumb in front and the remaining fingers behind, *i. e.*, along the anterior and posterior borders respectively of the deltoid muscle.

traumatic arthritis; (*b*) a penetrating wound of the joint; (*c*) a dislocation.

Traumatic Arthritis.—The term sprain was formerly applied to all forms of non-penetrating joint injury, except dislocations. With advancing knowledge of both the pathologic and clinical aspects of these injuries it seems proper to speak of a traumatic arthritis. This term

includes injuries to all of the structures of a joint, viz., synovial membrane, capsule, intraarticular and extraarticular ligaments, cartilages, etc. In joints the immediate or remote consequences of injury may be:

(*a*) A serous or hemorrhagic effusion.

(*b*) Stretching or rupture of the capsule.

(*c*) Stretching or rupture of one or more ligaments.

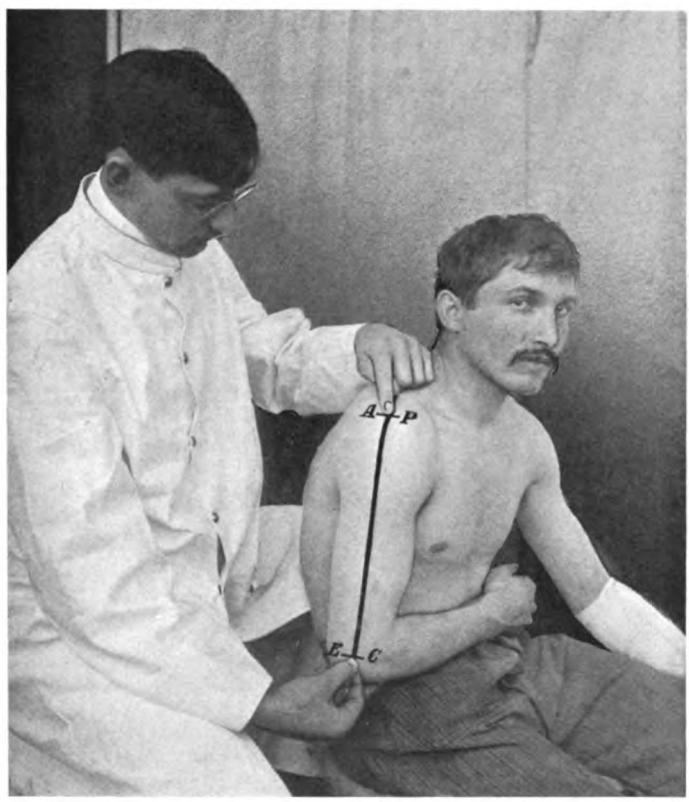

FIG. 283.—METHOD OF DETERMINING THE DISTANCE BETWEEN THE ACROMION PROCESS (*A–P*) AND THE EXTERNAL CONDYLE OF THE HUMERUS (*E–C*), BY MEANS OF A STEEL TAPE-MEASURE.

This method is often used in order to compare the humerus of one side to that of the other, and also for the purpose of determining the distance between these two points in the diagnosis of dislocations of the head of the humerus or fractures of the surgical neck.

(*d*) Complete or incomplete dislocation or tear of the intraarticular cartilages.

(*e*) Formation of free joint bodies.

(*f*) Recurrent effusion into a joint, often called intermittent hydrops.

The diagnosis of these various conditions can be made either (*a*) shortly after the injury or (*b*) at a later period.

The Diagnosis of Fractures in General.—The diagnosis of a fracture of one of the bones of the extremities does not differ from that of the bones previously considered in the chapters on the head and thorax.

The following routine should be followed in the examination of a case:

1. History of how the accident occurred.
2. Objective signs, such as deformity, abnormal mobility and crepitus, ecchymoses.
3. Subjective symptoms, such as pain, loss of function of the limb.
4. Examination with the *x*-ray.

1. *History.*—This should include the history of any previous accidents which may have caused shortening or some deformity of the limb. An exact account of how the accident occurred will enable us to judge

of the degree of [illegible]
such as to produ[illegible]
in some cases [illegible]
broke, followed [illegible]
2. *Objective* [illegible]
more be absent [illegible]
ment, and palpat[illegible]
often a [illegible]
opposite limb [illegible]

[illegible] in the examination of normal [illegible]
[illegible] palpation, and mensuration [illegible]
[illegible] deformity, abnormal mo[illegible]

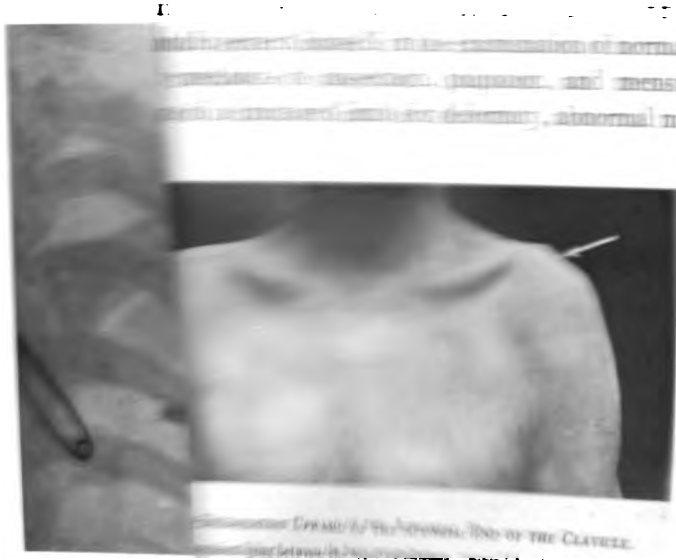

[illegible] Upward of the Sternal End of the Clavicle.

[illegible] by the separation [illegible]

Fig. 270 [illegible]

The black arrow points [illegible] fragment is displaced behin[illegible] acromion process is due to the [illegible]

bone at a point wh[illegible]
signs of fracture [illegible]
well as in the [illegible]
sign are dis[illegible]
This sign [illegible]
grating [illegible]
It resem[illegible]
and [illegible]
or [illegible]
si[illegible]

(*a*) *Diagnosis Shortly after Injury.*—In the majority of joints, a traumatic arthritis can be recognized by the diffuse pain and swelling which sets in soon after the injury. The presence of an effusion can be recognized in the more superficial joints, by the obliteration of the normal depressions, by fluctuation, obtained as elsewhere, by bimanual manipulation, and in the knee, by the ballottement of the patella (Fig. 438). The measurement of the circumference of the joint (Fig. 278) should be compared with that of the opposite side. For both diagnostic and ther-

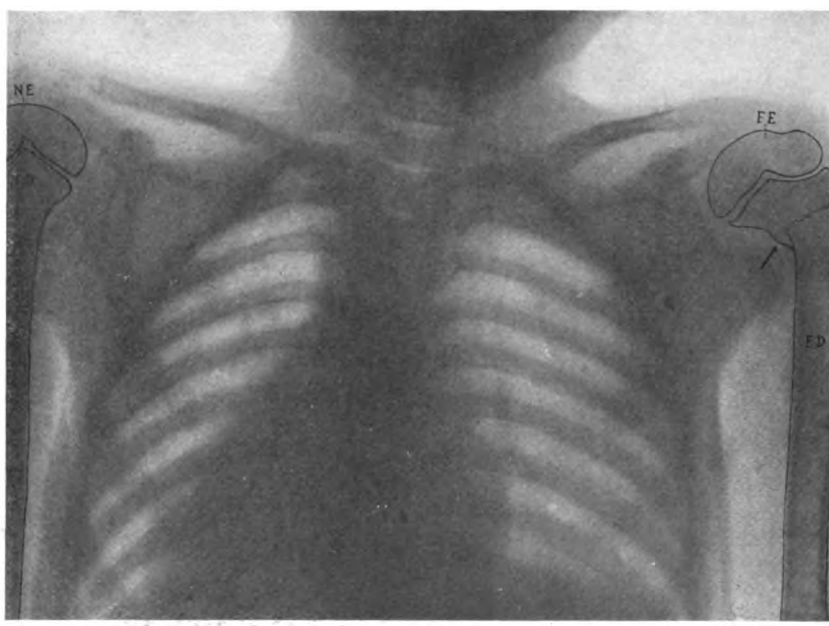

FIG. 284.—X-RAY OF FRACTURE OF SURGICAL NECK OF HUMERUS IN A BOY TEN YEARS OF AGE.

The arrow points to the line of fracture. The lower fragment, FD, has been pulled upward and outward through the action of the deltoid muscle, so that it forms, as is frequently the case, an angle with the upper end of the bone; FE, upper epiphysis of humerus on injured side. The clear line just below it, and separating it from the shaft or diaphysis, is due to the fact that the epiphyseal cartilage does not cast a shadow. NE, Epiphysis on normal side; ND, diaphysis or shaft on normal side.

apeutic purposes it is often advisable to aspirate the fluid under all possible aseptic precautions.

In deeper joints, like the hip and shoulder, the presence of an effusion is difficult to detect. In such cases one can judge by the position in which the limb is held; in the shoulder this is adduction; in the hip, flexion, slight abduction, and outward rotation.

In the majority of cases, in addition to the effusion, there is severe pain which may be localized at first at the point of insertion of a ligament.

Pathologically such cases are accompanied by stretching of ligaments and of the capsule. These are the cases ordinarily spoken of as *sprains*. The more hemorrhagic the character of the exudate, the greater the probability of tears of the capsule or ligaments, or of a fracture extending into the joint.

In large joints like the knee a diagnosis of a tear of one of the lateral ligaments may be made at an early period by obtaining abnormal lateral mobility (Fig. 334).

At a later period, when the effusion has disappeared, one must bear

FIG. 285.

Frequent mode of displacements of fractures of the surgical neck or of the humerus, or of separation of the upper epiphysis in children. *L*, Lower fragment (shaft), displaced inward and forward. Compare with Fig. 286.

FIG. 286.

Side view of a case of a fracture of the surgical neck of the humerus showing lower fragment displaced upward and forward in boy of ten. Compare with Fig. 285.

in mind the possibility of the other sequelæ of a traumatic arthritis. These sequelæ of a traumatic arthritis are:

(*a*) *Rupture of ligaments.* There is either abnormal mobility or one can palpate a distinct gap, as in the case of a torn ligamentum patellæ. In slight tears there is often persistent pain referred to the point of insertion.

(*b*) *Subluxation of cartilages.* This only occurs in the knee-joint as a result of forced rotation, involving the internal meniscus or semilunar cartilage, far more often than the outer. Complete dislocation has

never been observed. The diagnosis is seldom made at the time of the injury, because there is such a marked effusion that palpation is impossible, and the case is treated as a sprain. At a later period there is a history of sudden attacks of pain in the knee and inability to move it, the joint being often fixed in a position of slight flexion. The patient may fall to the ground on account of the severe pain in the knee, but usually he is able to remain erect, but cannot support himself on this knee.

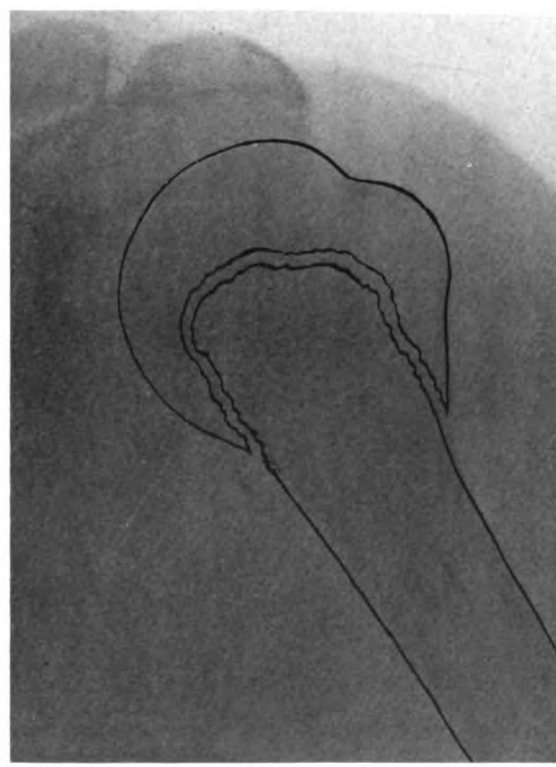

FIG. 287.—X-RAY OF IMPACTED FRACTURE OF SURGICAL NECK OF THE HUMERUS IN A MAN OF THIRTY-FIVE. The outlines of the line of fracture were traced in ink upon the *x*-ray. The shaft of the bone has become impacted into the head.

The patient often experiences a sensation as though something moved in the joint or snapped back with a distinct click. Some patients observe a prominence on the inner or outer sides of the joints.

If the attacks recur frequently they are milder than if far apart. In the latter there is usually more or less effusion present.

The patients can often reduce the luxation by traction on the leg and by rotation.

Vollbrecht [1] has described two groups of cases. In the first the original injury is followed, after a long confinement to bed, by the typical attacks, which are almost continuous.

In the second group there is an apparent recovery from the first accident after a tedious convalescence. After a second or third trauma the typical clinical picture sets in. One of the most characteristic objective signs is the interference with movements. Both flexion and extension are actively and passively interfered with. Another confirmatory sign, if found, is the palpation of a movable body in the gap between the femur and tibia. There is also great tenderness over the dislocated meniscus.

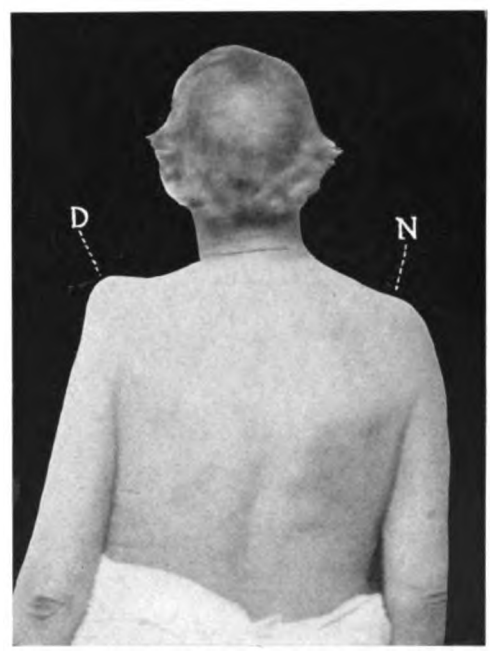

FIG. 288.—POSTERIOR VIEW OF SUBCORACOID DISLOCATION OF SHOULDER-JOINT.

Same case as shown in Fig. 289. N, Normal shoulder; D, dislocated shoulder.

(*c*) *Free bodies in the joints.* These have been variously termed floating cartilage, loose cartilage, joint mice, etc. They may result from the application of a direct (fall, blow, crush) or of indirect force (sudden tension of muscles or ligaments, torsion). They may occur even after very slight injury. They occur oftenest in the knee-joint, but may also follow injury to the shoulder, elbow, and wrist.

The most characteristic symptom is the so-called "locking" of the joint, due to the fact that the foreign body becomes wedged between the articular surfaces. There is severe pain and the joint is suddenly checked in its range of motion, so that flexion and extension cannot be executed. Such attacks may be accompanied by considerable effusion. Occasionally the free body can be felt and held between the fingers. After some manipulation the floating cartilage becomes free and the joint can be used again.

The typical symptoms may not appear until some time (months to

[1] Bruns: "Beiträge zur klinischen Chirurgie," Bd. xxi.

years) after the injury or they may become noticeable immediately after the initial symptoms have passed away.

GENERAL CONSIDERATIONS UPON DISLOCATIONS.

Dislocations are either (*a*) traumatic, (*b*) pathologic, or (*c*) congenital in origin. They may, as in the case of fractures, be either simple or compound, according to whether or not there is a communication between a wound in the skin and the seat of injury.

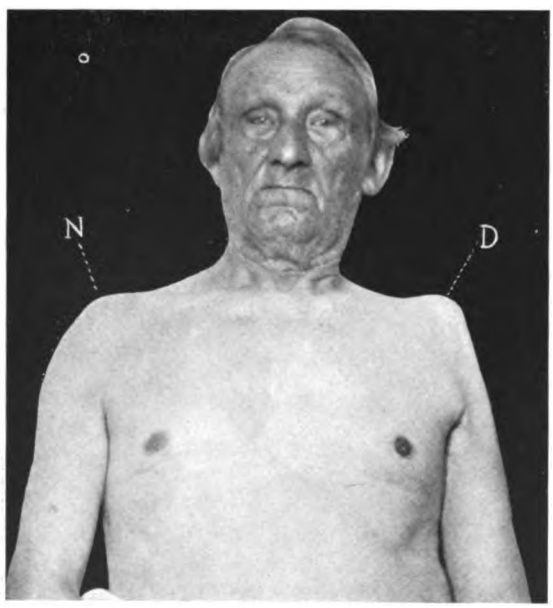

FIG. 289.—ANTERIOR VIEW OF DISLOCATION OF SHOULDER-JOINT.

Same case as shown in Fig. 288. N, Normal shoulder. Note the absence of prominence of the acromion process, and the presence of the normal convexity of the shoulder. D, Dislocated shoulder. Note the prominence of the acromion process, and the flattening of the shoulder due to absence of the head of the humerus.

If a dislocation tend to recur from time to time after having been reduced, it is termed a *recurrent or habitual dislocation.*

If the dislocation has remained unreduced for a long period it is called an *inveterate or ancient or unreduced dislocation.*

The *pathologic dislocations* are the result either of (*a*) an excessive distention of the capsule, (*b*) a malformation as the result of disease of the articular ends of the bones composing the joints. In both cases, following a slight trauma or independent of one, the dislocation occurs. These spontaneous or pathologic dislocations are described in the section on diseases of the joints.

A dislocation may be complicated by injury of the soft parts or by a fracture involving the articular bone ends. Compound dislocations are much more apt to be complicated by injuries of vessels and nerves than the simple are.

The recognition of an *injury to one of the blood-vessels of the limb*

is difficult. Such a lesion, as a rule, occurs oftenest in dislocations of the shoulder and knee. The signs are:

The pulsations of the artery below the point of impingement cannot be felt, the limb is cold, and pressure with the finger shows no variation in color when the finger is raised, as in the case of a normal limb. Gangrene may occur immediately, *i. e.*, within a few days or only gradually. If the artery has been torn a large pulsating swelling rapidly forms accompanied by signs of shock and internal hemorrhage.

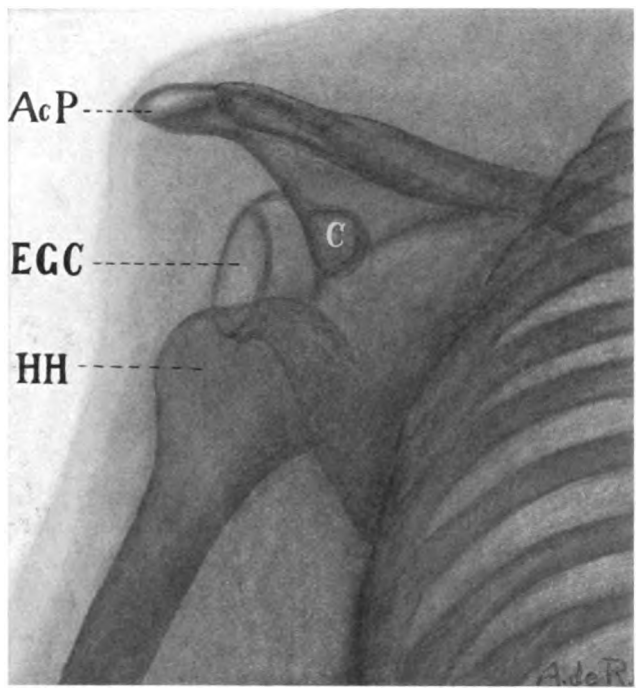

FIG. 290.—X-RAY OF SUBCORACOID DISLOCATION OF THE SHOULDER-JOINT.

C, Coracoid process, below which lies the head of the humerus (HH); EGC, empty glenoid cavity; AcP, acromion process of scapula. Note the flattening of the shoulder below the acromion process due to the absence of the head of the humerus.

Injury of nerves as a result of dislocation is more frequent than is injury of the vessels. Rupture of a nerve is quite rare, while a contusion occurs not uncommonly.

The diagnosis of nerve injury can be readily made from the presence of the disturbances of sensation and motion characteristic of such injury. In the upper extremity paralysis of the musculospiral nerve is far more frequent than is that of all the other nerves. In the lower extremity the sciatic and anterior crural are occasionally involved.

Other complications of dislocations are: (*a*) injuries of the skin and other soft parts in compound dislocations; (*b*) the occurrence of atrophy of the muscles proximal and distal to the joint, as well as the formation of adhesions within the joint; (*c*) fractures involving the articular ends of the bones which enter into the formation of the joint.

Diagnosis of Dislocations in General.—As in fractures, a diag-

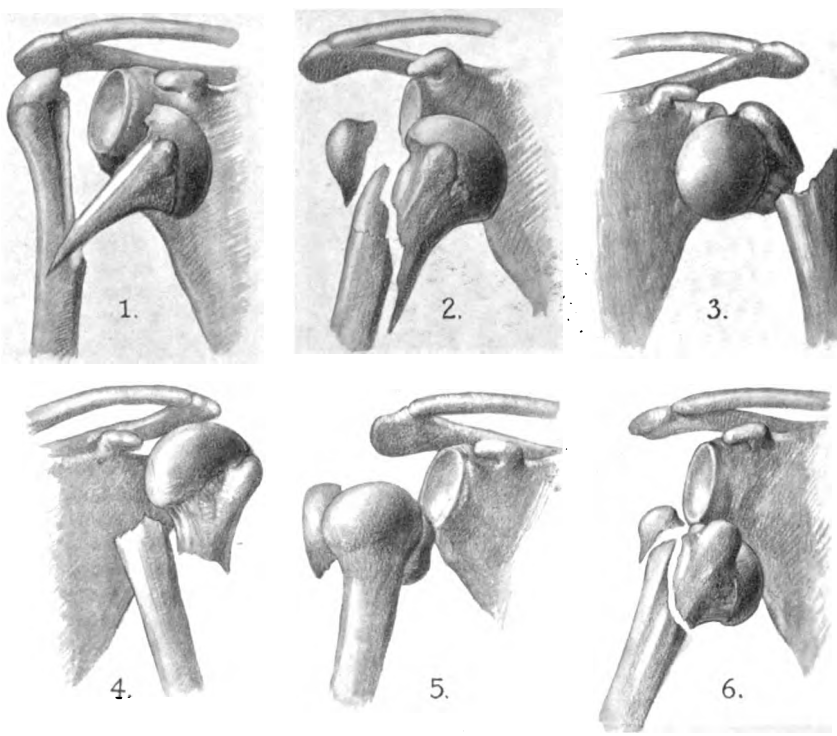

FIG. 291.—VARIOUS FORMS OF FRACTURES OF THE UPPER END OF THE HUMERUS ASSOCIATED WITH DISLOCATION OF THE HEAD OF HUMERUS (Robert Jones).

1, Split fracture of shaft of humerus with subcoracoid dislocation of head; 2, oblique fracture of upper end of humerus with subcoracoid dislocation and separation of greater tuberosity; 3, fracture of surgical neck of humerus, with dislocation of head; 4, fracture of surgical neck of humerus with displacement upward of head, and inward of shaft; 5, subglenoid dislocation of humerus, with separation of greater tuberosity to outer side, and lesser to inner side; 6, subglenoid dislocation of humerus, with fracture of anatomic neck and separation of greater tuberosity. This illustration was made from skiagraphs.

nosis can be made from certain objective and subjective signs taken in conjunction with an accurate history of the manner in which the accident occurred.

The examination should be made by (*a*) inspecting the limb to ascertain the nature of the deformity; (*b*) palpating the parts to learn the relation of the displaced articular ends to each other; (*c*) measuring the

limb with the aid of certain fixed anatomic points (Fig. 283); (*d*) an *x*-ray examination if necessary to confirm the diagnosis of dislocation and to ascertain whether there is a complication in the shape of a fracture.

The *objective signs of a dislocation* are:

1. *Deformity.*—The position in which the limb is held is often so characteristic that a simple inspection will indicate the condition to the experienced eye. In stout individuals such a change in the axis of a

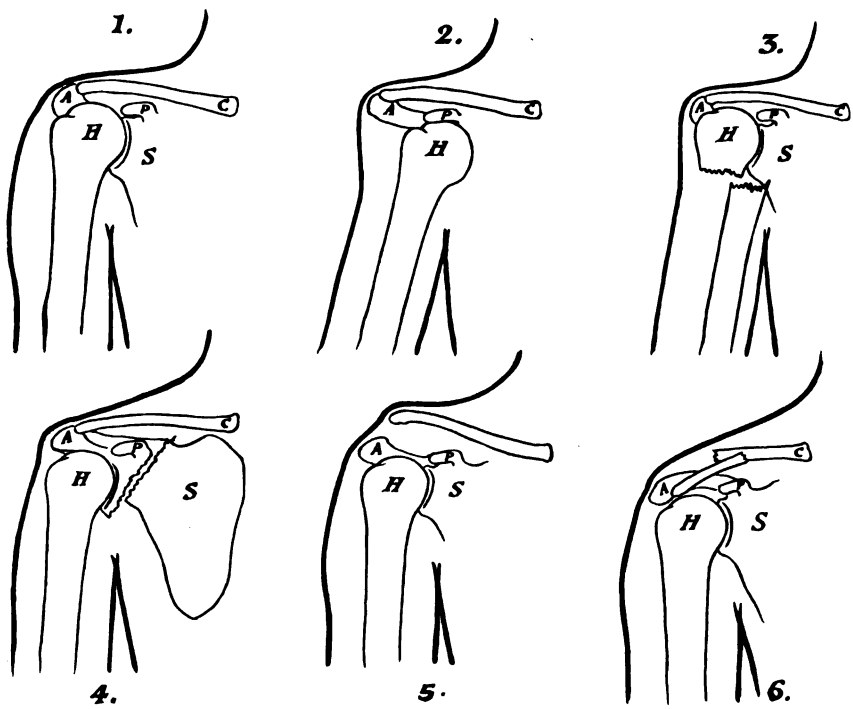

FIG. 292.—LESIONS TO BE CONSIDERED IN DIFFERENTIAL DIAGNOSIS OF SHOULDER INJURIES.

A, Acromion process of scapula; *P*, coracoid process of scapula; S, body of scapula; *C*, clavicle; *H*, humerus; 1, normal shoulder-joint, showing convexity due to presence of head of humerus in glenoid cavity, and to deltoid muscle; 2, subcoracoid dislocation of the humerus; 3, fracture of surgical neck of humerus, displacement of lower fragment inward. Note the flattening of the normal convexity of the shoulder in both 2 and 3. 4, Fracture of neck of scapula, permitting humerus to drop; 5, upward dislocation of acromial end of clavicle; 6, fracture of clavicle, with typical displacement of fragments.

limb or of its position is much more apt to be overlooked than in thinner individuals.

In general, the deformity may be said to be due (*a*) to a change in the direction or axis (Fig. 288) of the dislocated bone or bones; (*b*) to the abnormal position as determined by palpation (unless too much swelling exists) of the dislocated articular ends; (*c*) to the presence of an empty joint socket.

DIFFERENTIAL DIAGNOSIS OF INJURIES OF SHOULDER (FIG. 292).

	ABNORMAL PROMINENCES.	CONVEXITY OF SHOULDER.	POSITION OF HEAD.	AXIS AND LENGTH OF ARM.	CREPITUS, ABNORMAL MOBILITY, ETC.
1. Sprain.....	None.	Unchanged.	Rotates in joint.	Unchanged.	Absent.
2. Dislocation outer end of clavicle.....	Prominence above acromion.	Unchanged.	Rotates in joint.	Unchanged.	Outer end of clavicle shows abnormal mobility above acromion.
3. Fracture acromion process.....	None unless marked displacement.	Acromion lower, otherwise unchanged.	Rotates in joint.	Unchanged.	Crepitus and abnormal mobility at outer end of acromion.
4. Fracture of spine of scapula (rare).....	Acromion very prominent.	Depression beneath acromion.	Head felt in axilla, but rotates in joint and can be raised.	Axis unchanged, but arm apparently longer.	Distinct crepitus and abnormal mobility.
5. Fracture upper end of humerus (surgical neck or epiphysis)...	Prominence of upper end of shaft below coracoid or acromion.	Shoulder somewhat flatter according to degrees of displacement.	Head in glenoid cavity, does not rotate with shaft.	Axis changed, more internal, arm shorter.	Unless impacted, get distinct crepitus and abnormal mobility in adults. Less marked in children.
6. Dislocation of humerus.....	Acromion prominent.	Depression or flattening beneath acromion.	Head felt below coracoid process or in axilla.	Axis changed, length increased.	Head fixed, adduction impossible. Only movable if tuberosities broken.

2. *Disturbance of Function of the Limb.*—The range of movement of a dislocated joint is usually limited. If any movements of the end of one of the bones forming the articulation are felt, they are at a point away from the normal joint.

3. *Change in Length of the Limb.*—In many of the hip and shoulder dislocations (Figs. 289, 329) there is a shortening of the distance between the generally accepted fixed bony points on the dislocated side. An absence of any difference in length usually means only a partial dislocation (subluxation).

4. *X-ray Examination.*—This is not employed as often as in the case of fractures, owing to the fact that the deformity and other objective signs usually enable a diagnosis to be made.

It should, however, be used wherever there is any difficulty in reduction to determine whether a fracture coexists.

When the patient is stout or the swelling appears early and is very marked, a skiagraph is of the greatest possible aid.

FIG. 293.—METHOD OF EXAMINATION OF FRACTURES OF THE SURGICAL NECK OF THE HUMERUS.

The left hand grasps the arm close to the point of fracture in the case of the right arm, and vice versâ in the case of the left arm, while the forearm of the patient is allowed to rest upon the outstretched palm of the examiner. By carrying the forearm and lower fragment alternately away from and toward the body the false point of motion and crepitus can readily be elicited.

SPECIAL FRACTURES AND DISLOCATIONS.

Shoulder Region.—In the examination of a patient to ascertain the nature of an injury to the shoulder region, the following conditions must be thought of and eliminated by exclusion in the order named:

1. Fractures of the clavicle (most often in middle third).
2. Dislocations of the clavicle at the sternal or acromial ends (latter most common).
3. Fractures of the scapula (most often in acromion process).
4. Fractures of the upper end of humerus (usually at surgical neck).
5. Dislocation of the shoulder-joint (subcoracoid most frequent).

The principal diagnostic features of these injuries follow:

1. **Fractures of the Clavicle.**—About one-half of these occur in the middle third of the bone, and a third of the remainder at the junction of the outer and middle thirds of the bone. Incomplete fractures of the greenstick variety are quite common in children, and not infrequently escape recognition until a callus has begun to form. Fractures of the middle third, when complete and associated with displacement of fragments (Fig. 279), are easily diagnosed. On passing the finger along the anterior or upper surfaces, the projection of the overlapping fragments, or the formation by them of an angle directed backward, can be readily felt. The other signs of fracture, crepitus and a false point of motion, can be demonstrated, if necessary, by alternately raising and lowering the arm when grasped at the elbow-joint (Fig. 280). At times it is necessary to draw the shoulder back in order to obtain crepitus.

FIG. 294.—METHOD OF EXAMINATION OF A FRACTURE OF THE UPPER OR MIDDLE THIRD OF THE SHAFT OF HUMERUS.

The right hand in the case of an examination of the left humerus is placed over the seat of fracture, the elbow is permitted to rest upon the opposite hand, the arm being moved alternately toward and away from the body in order to determine abnormal mobility and crepitus.

The diagnosis of fractures which are complete but not associated with displacement, as well as of greenstick (incomplete) fractures, is not as easy. In such cases one is guided by the history of the mode of injury (fall upon the shoulder or outstretched hand) and the results of palpation. The latter shows a great tenderness at the point of fracture and there is pain on raising the arm voluntarily or, as shown in Fig. 280, it is referred to this spot. In many cases a slight elevation of the surface of the bone is present at the point of greatest tenderness.

Multiple and comminuted fractures of the clavicle are quite rare, and can be recognized by feeling the separate fragments and by the use of the *x*-ray (Fig. 279).

Fractures near the sternal or clavicular ends of the clavicle are often associated with considerable displacement of fragments (Fig. 279) and may simulate a dislocation of the clavicle. In the case of a fracture there is distinct crepitus, and the point at which abnormal mobility exists is situ-

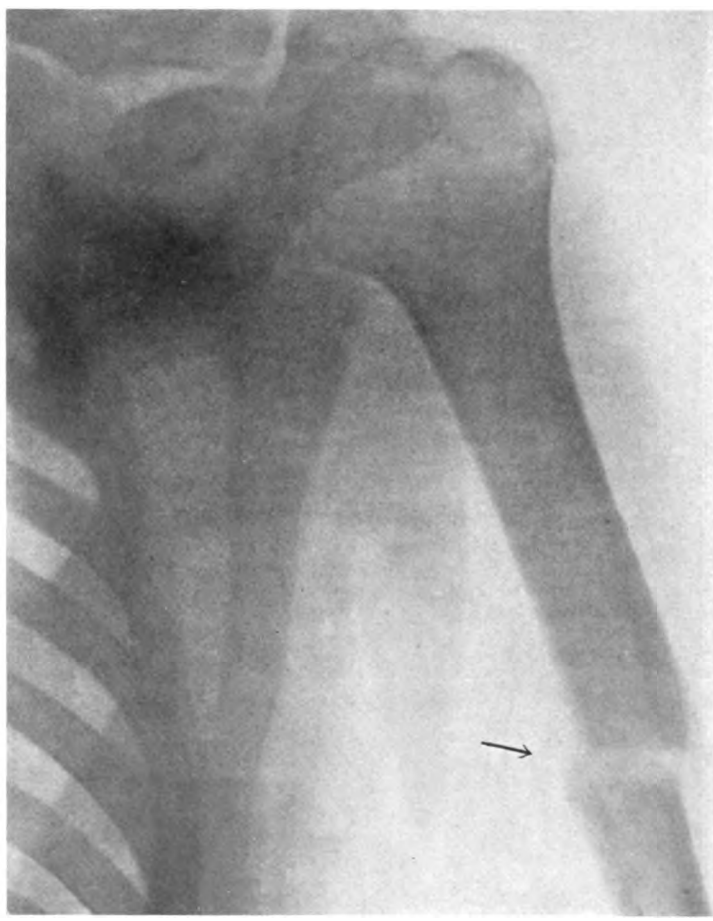

FIG. 295.—X-RAY OF PSEUDARTHROSIS OF FRACTURE, MIDDLE OF SHAFT OF HUMERUS, THE EXTERIOR PICTURE OF WHICH IS SHOWN IN FIG. 293.

This *x*-ray was taken five months after the injury; the *x*-ray shows practically no callus formation (fibrous union).

ated close to the sternoclavicular and acromioclavicular joints respectively. The joints themselves are found to be intact by placing a finger over them while the arm is alternately raised and lowered. A familiarity with the anatomic relations, as gained by palpation on normal subjects during life, is of invaluable aid in the diagnosis of injuries of the bones and joints.

In cases of doubt, especially if the injury is at the acromioclavicular joint, a skiagraph should be taken. In the greenstick fractures of children the callus is usually excessive in size for the first eight to twelve weeks and then gradually disappears.

2. Dislocations of the Clavicle.—*Dislocations of the sternal end* are much rarer than are those of the acromial end. Dislocation at the sternoclavicular joint occurs in three forms: (*a*) a forward, which is the most common; (*b*) a backward, and (*c*) an upward. In each of these the diagnosis should be readily made unless great swelling exists. The unat-



FIG. 296.—ANKYLOSIS OF SHOULDER-JOINT (PARTIAL), FOLLOWING FRACTURE OF THE UPPER THIRD OF THE HUMERUS.

The left arm is shown so that it can be compared with the right or injured arm. The amount of abduction of the left or uninjured arm was normal. On the right or injured side the arm could be abducted only to the distance of about forty-five degrees from the body. The illustration also shows a well-marked flexion contracture due to non-use of the elbow-joint.

tached end of the clavicle is felt either in front, behind, or above its normal position. In addition, there is localized pain, and in the backward variety there may be signs of pressure upon the trachea or upon the vessels at the lower part of the neck.

Dislocation at the acromioclavicular joint occurs (*a*) upward (supraacromial); (*b*) downward and backward (subacromial), and (*c*) downward and forward under the coracoid process (subcoracoid). Of these, the second and third are so rare that one need but consider the first variety clinically. This may exist in either an incomplete or a complete form. In the former the clavicle can be felt to be raised slightly

above the level of the acromion and can be forced back in place by pressure. Upon removing the finger the bone springs back again. In the complete variety there is quite a gap to be felt between the outer end of the clavicle and the acromion process (Fig. 281). By pressure upon the clavicle the latter can be brought toward the acromion, but can only be held there with difficulty. The amount of functional disturbance and local pain varies greatly, being very marked in some cases.

3. **Fractures of the Scapula.**—Fractures of this bone may occur either through the body, inferior and superior angles, spine, acromion,

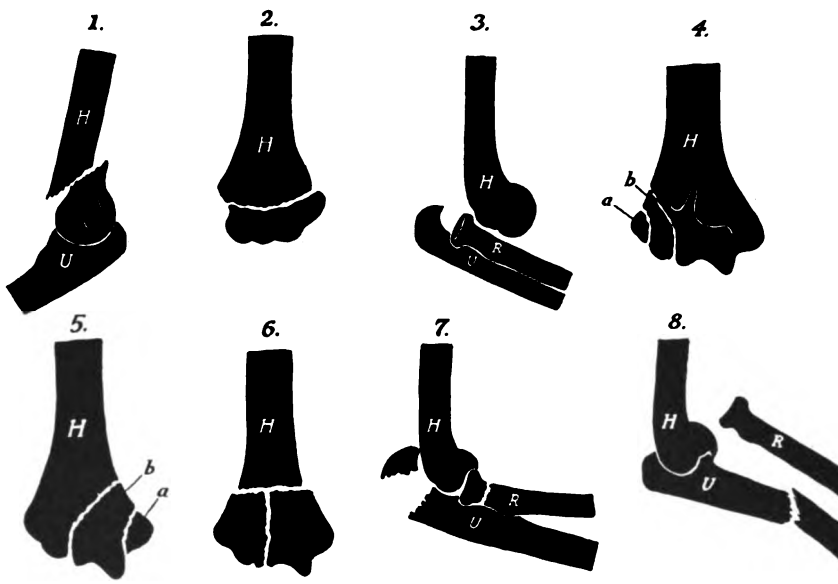

FIG. 297.—MOST FREQUENT FORMS OF INJURY OF THE BONES COMPRISING THE ELBOW-JOINT.

H, Humerus; *R*, radius; *U*, ulna. 1, Supracondyloid fracture of humerus; 2, epiphyseal separation of the lower end of humerus; 3, backward dislocation of both bones of forearm; 4, fracture of internal epicondyle (*a*) and of internal condyle itself (*b*); 5, fracture of external epicondyle (*a*) and of external condyle (*b*); 6, T-shaped fracture of lower end of humerus; 7 fracture of olecranon and of neck of radius; 8, fracture at junction of upper and middle shafts of ulna, combined with forward dislocation of head of radius.

coracoid, surgical neck, and glenoid cavity. Of these, all except fractures of the body, acromion, and spine are so rare as to be of little importance clinically. *Fractures of the body* may be suspected from the history of a blow or other direct violence over the scapular region, followed by pain localized over the body of the scapula and increased by any movement of the arm. The outline of the bone can be felt to be irregular, and by grasping the lower angle one can obtain crepitus and abnormal mobility. In many cases this is either difficult or impossible, on account of the pain and swelling, so that reliance must be placed upon feeling an irregularity and the presence of severe pain on pressure and movement.

Fractures of the acromion process, like those of the body of the bone, are very difficult to recognize by palpation. The use of the *x*-ray has been of great aid in the diagnosis of these fractures. On passing the finger backward from the tip of the process one can at times feel a depression corresponding to the displacement of the fragments. Crepitus and a point of abnormal mobility are obtained by alternately raising and lowering the arm, which is grasped at the elbow (Fig. 293), while the finger is placed over the acromion process. There is usually inability to raise the arm.

FIG. 298.—TYPICAL SWELLING OF ELBOW-JOINT IN A CHILD OF FIVE, FOLLOWING A FALL UPON THE ARM, ILLUSTRATING THE DIFFICULTIES OF DIAGNOSIS. (See text.)

The most frequent locations of these fractures are either at the base or tip of the acromion process. Fractures of the surgical neck of the scapula are very rare. They simulate dislocations of the shoulder on account of the dropping of the humerus (Fig. 292) with marked concavity below the acromion process. When the arm is raised the latter deformity disappears, the manipulation being accompanied by crepitus. An *x*-ray will readily clear up the diagnosis.

4. Fractures of the Upper End of the Humerus.—Before attempting the diagnosis of an injured shoulder one should accustom one's self, either by previous training or examination of the normal shoulder, to palpate the most important points in the applied or clinical anatomy of the normal shoulder. These are: (*a*) palpation of the acromion process and its relation to the clavicle; (*b*) determination of the fact that the head of the humerus rotates in the glenoid cavity (Fig. 282); (*c*) palpation of the normal convexity of the shoulder due to the deltoid muscle and the head of the humerus; (*d*) measurement from the tip of the acromion process to the external condyle of the humerus (Fig. 283); (*e*) extent of normal movements of the shoulder-joint (abduction, adduction, exten-

sion in a forward and backward direction); (*f*) study of an *x*-ray of a normal child's and adult's shoulder-joint.

The possible injuries at the upper end of the humerus which must be taken into consideration are: (1) Fracture of the anatomic neck alone or with fracture through the tuberosities; (2) epiphyseal separation; (3) fracture of the surgical neck; (4) impacted fracture of the surgical

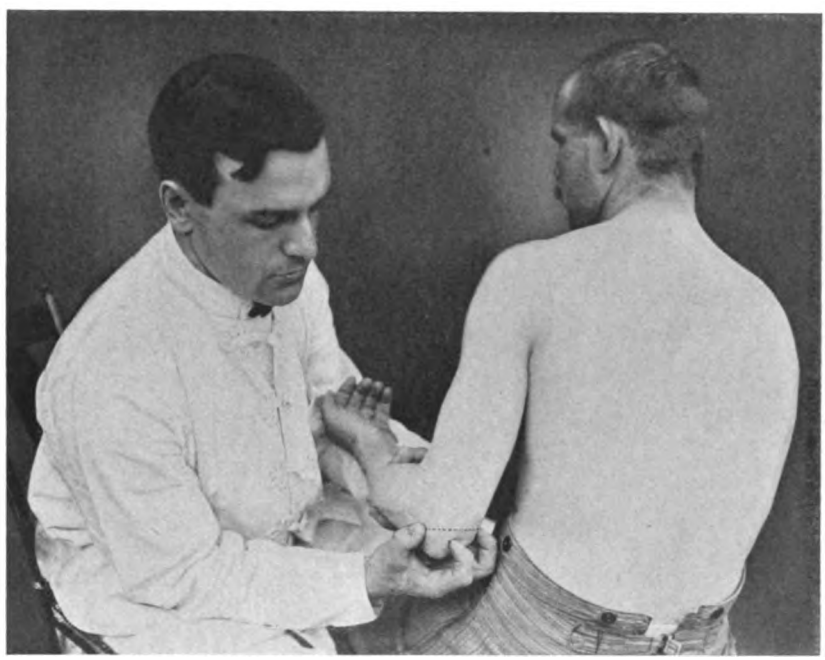

FIG. 209.—METHOD OF DETERMINING THE RELATION OF THE THREE BONY POINTS AT THE BACK OF THE ELBOW IN EXAMINATIONS FOR FRACTURES OR DISLOCATIONS OF THE BONES WHICH FORM THE ELBOW-JOINT.

In the case of an examination of the left elbow, as shown here, the patient's left forearm is allowed to rest upon the left forearm of the examiner, while the latter's right hand supports the elbow in such a manner that the thumb rests upon the external condyle, the middle finger upon the internal condyle, and the index-finger upon the tip of the olecranon. The relation of these three points is shown in the illustration when the elbow is flexed, that is, the tip of the olecranon lies a little below the dotted line joining the two condyles. When the arm is extended the tip of the olecranon lies either in this line or above it.

neck; (5) fracture of the upper end of the humerus, combined with dislocation of the head.

Fracture of the anatomic neck is almost always associated with fracture of the tuberosities and cannot be distinguished clinically from fractures of the surgical neck except by an *x*-ray examination. Isolated fractures of the tuberosities are also rare. Those of the greater tuberosity usually accompany a dislocation of the shoulder. When it occurs independently of such an injury the diagnosis may be made if one can

palpate a loose fragment corresponding to the greater tuberosity and can cause pain by pressure and upon rotating the arm outward.

Lorenz [1] reported a case of fracture of the lesser tuberosity which followed forced outward rotation of the arm. Sixteen months after the injury when first examined by Lorenz internal rotation was impossible, and on palpation a sharp edge of bone was evident at the location of the lesser tuberosity.

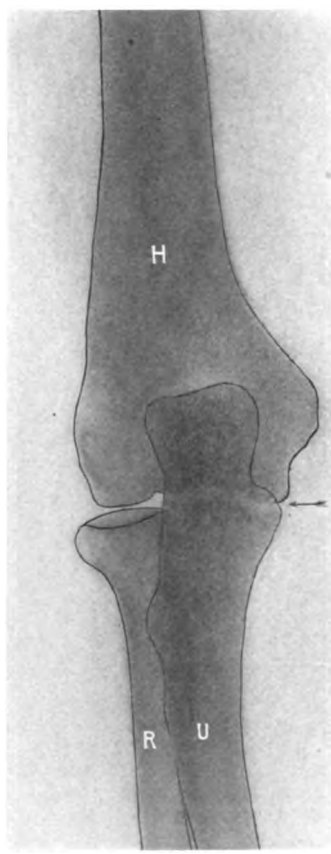

FIG. 300.—POSTERIOR VIEW OF NORMAL ADULT ELBOW-JOINT (*x*-ray).

H, Humerus; R, radius; U, ulna. The arrow points to the clear space seen in such views, which corresponds to the olecranon fossa, and is not to be interpreted as a fracture.

Epiphyseal separation at the upper end of the humerus occurs most frequently between the ages of nine and sixteen. The diagnosis in cases without displacement is very difficult and can be made only by the presence of pain on pressure, or pain and soft crepitus upon rotation of the humerus, localized at the level of the epiphyseal cartilage. In some of these cases displacement is likely to take place after a few days if the arm is not immobilized.

In cases with either primary or the above referred to secondary displacement, the diagnosis can be made by palpation, if the swelling is not too great, or by an *x*-ray examination.

On palpation one feels the normal convexity of the shoulder, due to the fact that the head is still in the glenoid cavity, thus serving to distinguish the injury from a dislocation. The upper end of the diaphysis or shaft is to be felt over the coracoid process an inch or more below the acromion. This point rotates with the remainder of the shaft and can be rendered more prominent by raising the shoulder. The displacement is usually forward and inward (Fig. 285). Upon manipulation

[1] "Deutsche Zeitschrift für Chirurgie," Bd. lviii, S. 523.

For ordinary diagnostic purposes one need consider only the subcoracoid and subglenoid. The patients incline the head toward the injured side and complain of pain in the shoulder and along the entire arm. *The objective signs of a subcoracoid dislocation* are:

(*a*) The normal convexity is lost and one can see a distinct flattening or even a depression below the acromion process (Fig. 288) when looked at while standing in front of or behind the patient.

(*b*) There is a prominence below the outer end of the clavicle at the coracoid process.

(*c*) The arm is abducted, the elbow often being three to four inches from the chest.

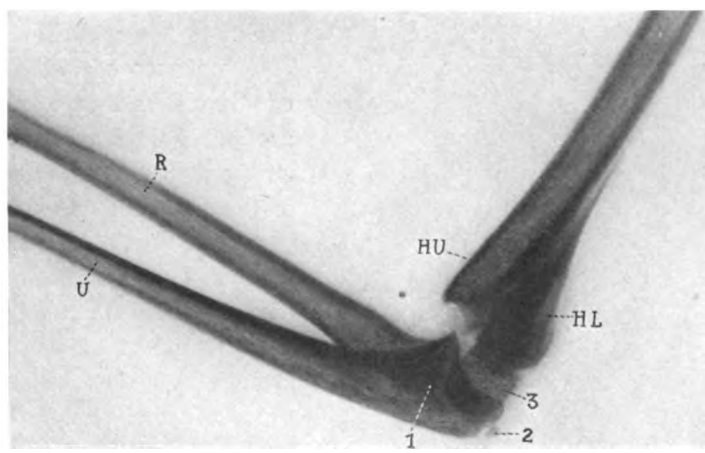

FIG. 303.—DEFORMITY FOLLOWING SUPRACONDYLOID FRACTURE OF THE HUMERUS.

The illustration shows how the lower fragment, HL, is displaced backward and upward, and the upper fragment downward and forward, HU, causing it to become prominent at the bend of the elbow. (See text.) R, Radius; U, ulna. 1, Upper epiphysis of radius; 2. epiphysis corresponding to olecranon process; 3, lower epiphysis of humerus.

(*d*) The axis of the humerus is changed so that instead of being nearly parallel with that of the opposite side, an imaginary line drawn through the dislocated humerus meets that of the corresponding bone of the opposite arm a little beyond the head (Fig. 289).

(*e*) There is a lengthening of the arm as measured from the acromion to the external condyle (Fig. 283).

(*f*) On palpation one feels the depression below the acromion and the empty glenoid cavity is felt by pushing the fingers in deeply.

(*g*) The head can be felt beneath the coracoid process.

(*h*) The arm is more or less fixed, permitting of but slight, if any, abduction or rotation.

The *symptoms of a subglenoid dislocation* are that the head can be felt through the axilla, lying beneath the glenoid cavity and the abduction of the arm is more marked. In *the subclavicular form*, the head is to be felt at the point where the pectoralis major and deltoid meet and the arm is greatly adducted. In the *subacromial and subspinous or backward forms*, in addition to the flattening of the shoulder and the empty glenoid cavity, one can see and feel the head of the humerus beneath the prominent acromion process or even further back.

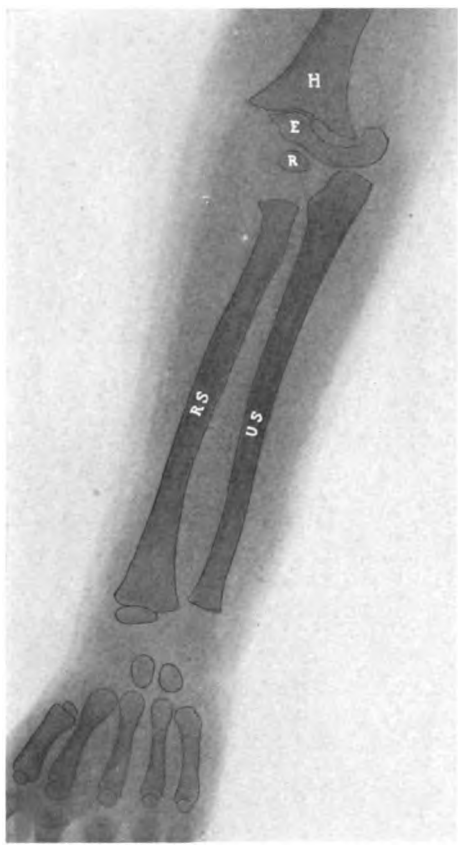

FIG. 304.—X-RAY OF FRACTURE THROUGH THE LOWER EPIPHYSIS OF THE HUMERUS IN A CHILD OF THREE.

The outlines of the bones have been strengthened by tracing them in black. RS, Shaft of radius; R, upper epiphysis (capitellum) of radius; US, shaft of ulna; E, lower epiphysis of humerus displaced inward; H, shaft of humerus.

Fractures of the Shaft of the Humerus.—In this are included all fractures occurring between the insertion of the deltoid above and the upper portion of the supracondyloid ridges below. The diagnosis can be made in the majority of cases by manipulation of the arm (Fig. 294), especially if there is some degree of dislocation. The ordinary signs of fracture, such as crepitus, abnormal mobility, loss of function, localized pain, are all quite marked. If there is considerable displacement of fragments, the lower portion of the arm may form an angle with the upper and the ends of the fragments are visible and easily felt.

The greatest interest in connection with fractures of the shaft of the humerus is in connection with injuries of the musculospiral nerve or laceration of the brachial artery. The diagnosis of these complications has been previously discussed (page 434). Delayed union is very frequent in this form of fracture and can be recognized by the

persistence of abnormal mobility and the absence of ossification (Fig. 295), as shown in a skiagraph.

Injuries in the Vicinity of the Elbow-joint.—In the examination of a person suffering from an injury of the elbow-joint the following possible lesions must be thought of and one excluded after the other by a systematic examination, combined, if required, with the use of the *x*-ray.

1. *Fractures of lower end of humerus.*

(*a*) Supracondyloid fracture (more or less transverse of shaft above condyles).

(*b*) T or Y fractures.

(*c*) Epiphyseal separation.

(*d*) Fractures of external or internal condyles and epicondyles.

2. *Lesions of the radius and ulna:*

(*a*) Dislocation backward of radius and ulna.

(*b*) Fracture of upper third of ulna with or without dislocation forward of radius.

(*c*) Dislocation forward of upper end of radius.

(*d*) Fracture of olecranon process of ulna.

(*e*) Fracture of neck or head of radius.

(*f*) Subluxation of head of radius.

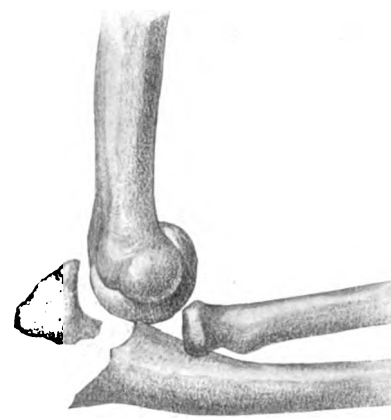

FIG. 305.—FROM A DRAWING OF AN *x*-RAY OF A FRACTURE OF THE OLECRANON PROCESS.

3. *Simple sprains of the elbow.*

In the majority of cases swelling occurs so rapidly after elbow injuries that palpation is difficult. In children especially the administration of an anesthetic is advisable in order to make a diagnosis.

Familiarity with the surface anatomy of the elbow region will be of great aid in an examination for possible injury. The more important normal landmarks are: (*a*) The two condyles of the humerus and the tip of the olecranon process form an equilateral triangle when the arm is flexed to a right angle. When the arm is extended they lie in a straight line (Fig. 299). (*b*) The head of the radius can be felt to rotate below the external condyle of the humerus (Fig. 301). (*c*) An angle is formed by the radius and ulna with the humerus when the

hand and forearm are held in a supinated position, which is known as the *carrying angle.*

If the two condyles of the humerus lie in their normal relation to the olecranon process as determined by palpation, this will exclude a dislocation of both bones of the forearm, a fracture of either condyle or a fracture of the olecranon process.

If the head of the radius can be felt to rotate in its normal position (Fig. 301), this will exclude a fracture of the neck or head of the radius and a dislocation of the radius.

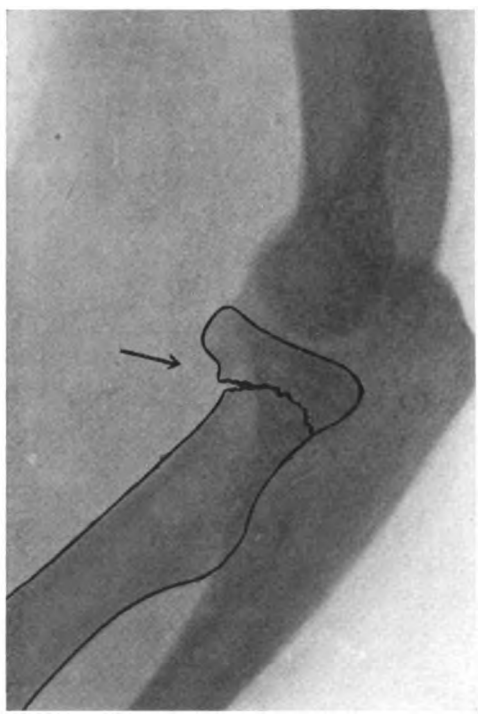

FIG. 306.—X-RAY OF FRACTURE OF THE NECK OF THE RADIUS IN A VERY MUSCULAR INDIVIDUAL.

The arrow points to the point of separation of the capitellum and shaft.

The chief diagnostic points of the various injuries in the vicinity of the elbow-joint are as follows:

I. (*a*) *Supracondyloid Fracture of the Humerus.*—1. Deformity may be present or not according to the degree of displacement. If the displacement is marked, there is a prominence at the back of the elbow in those fractures which follow a fall upon the elbow. These are called extension fractures (Fig. 303) and resemble a dislocation backward of the radius and ulna, but palpation shows the relations of the olecranon to the condyles to be normal (Fig. 299). The lower end of the upper fragment is often prominent and easily felt a little above the bend of the elbow. The deformity can usually be readily corrected by downward traction.

2. Abnormal mobility and crepitus are easily elicited by grasping the forearm and lower end of the humerus and moving it firmly forward and backward while the shaft of the humerus is steadied with the other hand or by an assistant (Fig. 302).

I. (*b*) *Intercondyloid or T or Y Fractures of Lower End of Humerus.*—

In this form of injury an *x*-ray is often necessary in order to make an exact diagnosis. These are often compound, so that a direct inspection is possible. The signs are the same as for supracondyloid fracture, but the relation of the condyles will be changed according to the degree of displacement. In some cases the condyles are so widely separated that the olecranon passes between them. Unless the swelling is too great, the condyles can be moved independently of each other and of the shaft. In some cases the median nerve has been contused by being stretched across the displaced fragments.

I. (*c*) *Epiphyseal Separation.*—The signs are those of supracondyloid fracture, and it occurs in children below the age of ten. It may involve the entire epiphysis only at a very early age (Fig. 304), resulting in lateral or antero-posterior displacement, as in the typical supracondyloid form in older children and adults. The crepitus is usually muffled or indistinct.

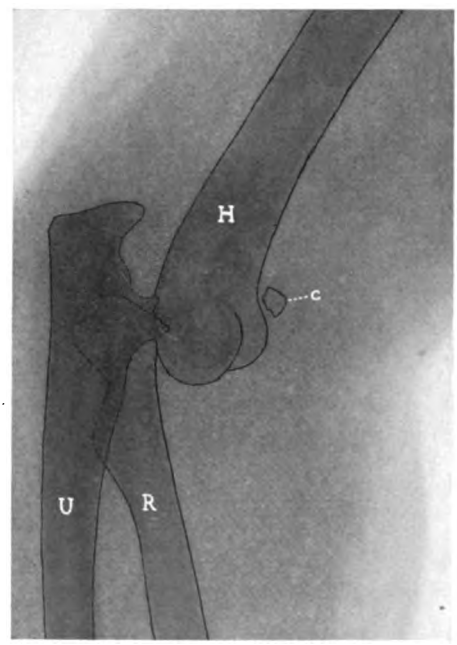

FIG. 307.—SKIAGRAPH OF CASE OF DISLOCATION BACKWARD OF BOTH BONES OF FOREARM.

U, Ulna; R, radius; c, broken-off coronoid process of ulna; H, shaft of humerus. Note in the shadow the obliteration of the normal depression above the coronoid process. (See text.)

A fracture through the epiphysis can be distinguished from a dislocation of the elbow by the fact that the bony points on the lower fragment of the humerus still retain their normal relation to the olecranon. It differs from the supracondyloid fracture of older children and adults in showing a prominence, due to displacement forward of the upper fragment. This prominence is found at a lower level than in the supracondyloid variety.

One should, in general, never make a diagnosis from an *x*-ray of an elbow-joint injury in children without referring frequently to *x*-ray pictures of the normal joint at various ages. The presence of a clear area caused by a normal cartilage may often lead one to think it a fracture line.

I. (*d*) *Fractures of the Internal Epicondyle or Internal Condyle.*—Fractures of the internal epicondyle are common in children on account of the fact that union with the shaft does not occur before the eighteenth year. The fragment, if large, can be grasped between the fingers of the examiner and moved, and soft crepitus elicited.

In fractures of the internal condyle, the latter can be moved to and fro independently of the shaft, by grasping it between the thumb and index-finger. This abnormal mobility is accompanied by crepitus. One

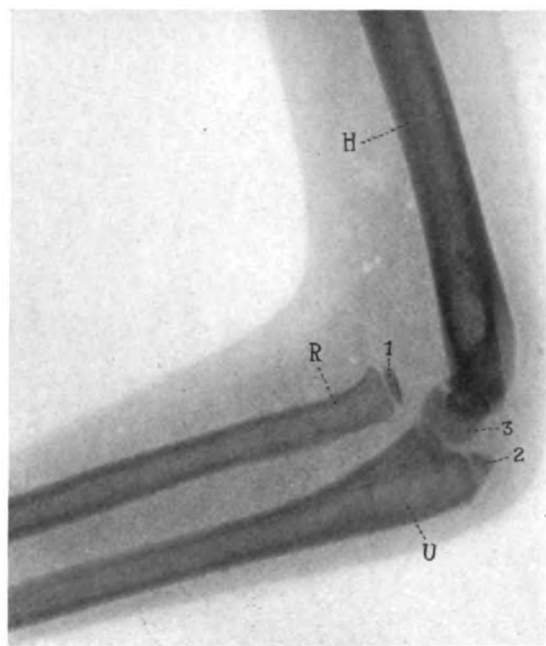

FIG. 308.—FORWARD DISLOCATION OF RADIUS, IN A BOY OF TEN.

Compare with the normal elbow of same patient shown in Fig. 277. R, Shaft of radius; U, shaft of ulna; H, shaft of humerus. 1, Upper epiphysis of radius (capitellum); 2, upper epiphysis of ulna, which forms the olecranon process; 3, lower epiphysis of humerus.

of the most characteristic signs, if any displacement of the fragment has occurred, is the fact that when the relation of the three bony points is looked for, the internal condyle is found above the level of the external condyle (Fig. 299).

There is lateral mobility of the elbow-joint present.

I. (*e*) *Fractures of the External Epicondyle and External Condyle.*—The former are rare and so difficult to recognize that for practical purposes it is only necessary to consider the fractures of the external condyle itself. The latter occur more frequently than those of the

internal condyle, especially in young persons. The fragment broken off includes the epicondyle, outer portion of the trochlea, and capitellum (Fig. 297). It may be tilted or even rotated so that the broken surface looks upward or outward. The external condyle is found displaced upward when the three bony points at the back of the elbow are palpated. The fragment can usually be grasped between the fingers and moved independently of the shaft, accompanied by crepitus. In some cases a deformity is visible.

II. (*a*) *Fractures of the Upper End of the Ulna and Radius.*—Fractures of the olecranon process of the ulna can be readily recognized if there is a considerable separation of the fragment from the main portion of the bone. This condition is seldom present in sufficient degree to be relied upon for diagnosis. If it exists a gap or depression can be felt between the fragment and the shaft, and the former possesses independent mobility.

If no separation exists one should search for mobility of the end of the olecranon by moving it laterally and also holding it between the fingers while an assistant alternately flexes and extends the forearm. Voluntary extension of the elbow-joint is usually absent and is a characteristic sign. If the swelling is great the presence of an olecranon fracture should be suspected from the inability to extend the arm voluntarily and also from the localized pain.

If possible, an *x*-ray should be taken at the earliest moment in these cases. Fractures of the coronoid process of the ulna are rare and usually associated with backward dislocation of the ulna and radius. It renders the reduction of the latter easier, but there is greater tendency to recurrence. It probably occurs more often than is generally thought, and must be searched for by *x*-ray examination in all severe injuries of the elbow-joint. Dislocation of the fragment and resultant excessive callus formation may greatly interfere with the function of the joint.

Fractures of the Head and Neck of the Radius.—The recognition of this fracture is usually difficult. In the case shown in Fig. 306 the lesion was suspected from the presence of great pain over the head of the radius when it was grasped between the fingers, while the forearm was alternately pronated and supinated (Fig. 301). In some cases the head will be found not to move when the shaft is rotated, and there may be crepitus. At the present time the use of the *x*-ray has been found of the greatest service in the diagnosis of such fractures.

Dislocations of the Bones of the Forearm.—Dislocation of both radius and ulna backward (Fig. 307) or of the radius alone forward occurs

far more frequently than any other varieties of dislocation. The former injury is at times complicated by fracture of the olecranon, of the coronoid process, of the head, shaft, and lower end of the radius, or of the internal condyle of the humerus.

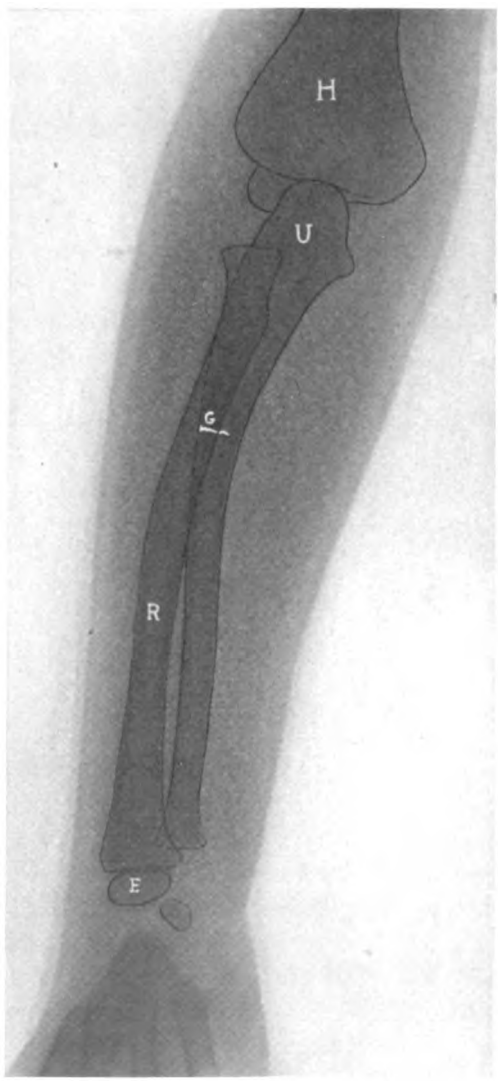

FIG. 309.—X-RAY OF CASE OF GREENSTICK FRACTURE OF THE ULNA, SHOWING THE CHARACTERISTIC BENDING OF THE BONES OF THE FOREARM.

The outlines of the bones have been strengthened by tracing them in black, and the light space in the ulna, shown at G, represents the incomplete line of fracture on the convex side of the ulna. The skiagraph was taken so that the back of the forearm is shown. R, radius; U, ulna; E, lower epiphysis of radius; H, humerus.

Dislocations of both bones of the forearm backward are recognized by careful attention to the results of palpation of the three bony points at the back of the elbow. The tip of the olecranon will be found either on a line with or above the level of the two condyles of the humerus. The olecranon also lies in a plane which is considerably further behind the humerus than in the normal arm. The head of the radius can be felt, and often seen, lying behind the external condyle of the humerus. The lower end of the shaft of the latter bone can be felt as a projection at the front of the elbow-joint. The arm is held in a semiflexed position and there is great limitation of movements in the elbow-joint. *Dislocation of the radius alone* is usually of the forward variety. It may at times be complicated by fracture of the upper third of the shaft of the ulna. Both active and passive

movements of the elbow are painful and limited, especially flexion. Upon examining the elbow in the systematic manner referred to, the head of the radius is not found in its normal position. Instead of the head, one finds a depression on deep palpation; the head itself is felt in front of the lower end of the humerus on the radial side of the bend of the elbow.

In older cases when the swelling has disappeared, the head of the radius may project considerably above the level of the surrounding tissues. In the cases associated with fracture of the ulna the latter can be recognized by palpation of the deformity when the finger is passed along the back of the ulna, and also by the presence of abnormal mobility.

Subluxation of the radius, or "pulled elbow," occurs in a young child after lifting it by the forearm or pulling upon the hand. There is no palpable or visible displacement of the radius. The child will not use the arm and it either hangs by its side or is supported by the other one. There is pain on pressure over the head of the radius and the child resists any rotary movements of the forearm, especially supination. In the majority of cases a separation can be felt between the lower end of the humerus and the head of the radius. After forced supination a slight click is heard and the child uses the arm freely again.

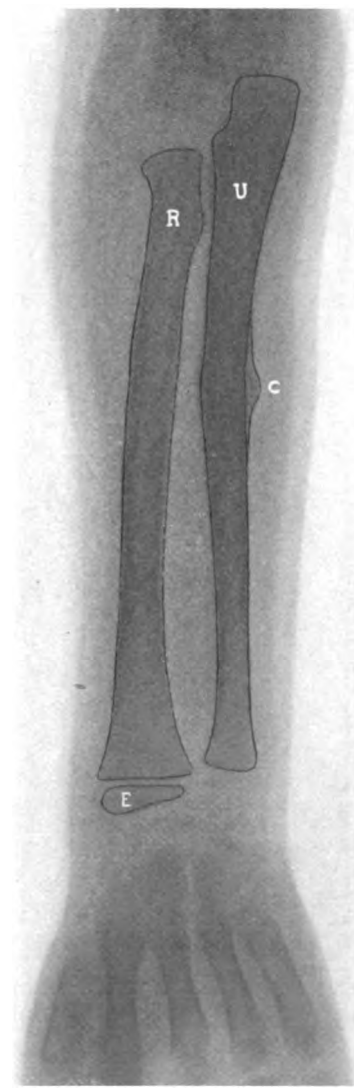

FIG. 310.—GREENSTICK FRACTURE OF THE ULNA SHOWN IN FIG. 309, AFTER REDUCTION.

R, Shaft of radius; E, lower epiphysis of radius; U, shaft of ulna; C, callus at point of greenstick fracture, showing the relatively large size of these in such cases.

Fractures of the Shafts of the Ulna or Radius.—Fractures of both

bones of the forearm may occur simultaneously or either one alone may be broken. In children the *greenstick or incomplete* form (Fig. 308) is by far the most frequent and is often overlooked. As in the case of the complete form in adults, it usually occurs in the middle third. It may involve one or both bones. If after a fall upon the forearm or outstretched hand a child complains of pain or does not use the arm, a search for an incomplete fracture should be made. The radius and ulna can be palpated in children throughout almost their entire length, so that a bowing or angle is readily detected. The other signs are localized pain and tenderness. An *x*-ray examination should be made in every suspected case. One bone may be completely broken and the other only incompletely. Complete fractures of either or both

FIG. 311.—CHARACTERISTIC SWELLING OF WRIST-JOINT AND DEFORMITY IN RECENT COLLES' FRACTURE.

Note the fullness on the flexor surface of wrist, due to displacement downward of the upper fragment of the radius, and the more distal prominence on the dorsal surface of the wrist, due to displacement upward of the lower fragment of the radius. Note also the swelling and obliteration of the normal depressions corresponding to the wrist-joint.

bones of the forearm are not difficult to recognize unless the individual is very muscular or very fat. When the arm is grasped in the manner shown in Fig. 317, abnormal mobility and crepitus can be readily detected. At times the diagnosis may be made from the deformity alone, which is either visible or can be felt by palpating the bones.

Injuries in the Vicinity of the Wrist-joint.—The following conditions must be thought of in this region:

(*a*) Fractures of the lower end of the radius. Colles' fracture.
(*b*) Fracture of the styloid process of the ulna.
(*c*) Fracture of both radius and ulna near the wrist.
(*d*) Fractures and dislocations of the carpal bones.
(*e*) Dislocations of the wrist-joint.
(*f*) Carpo-metacarpal dislocations.

As in the case of injuries of the shoulder-joint and elbow-joint, familiarity with normal conditions is of the greatest aid in making a diagnosis. The injured wrist should always be compared with the opposite sound one. One should first observe the presence of deformity,

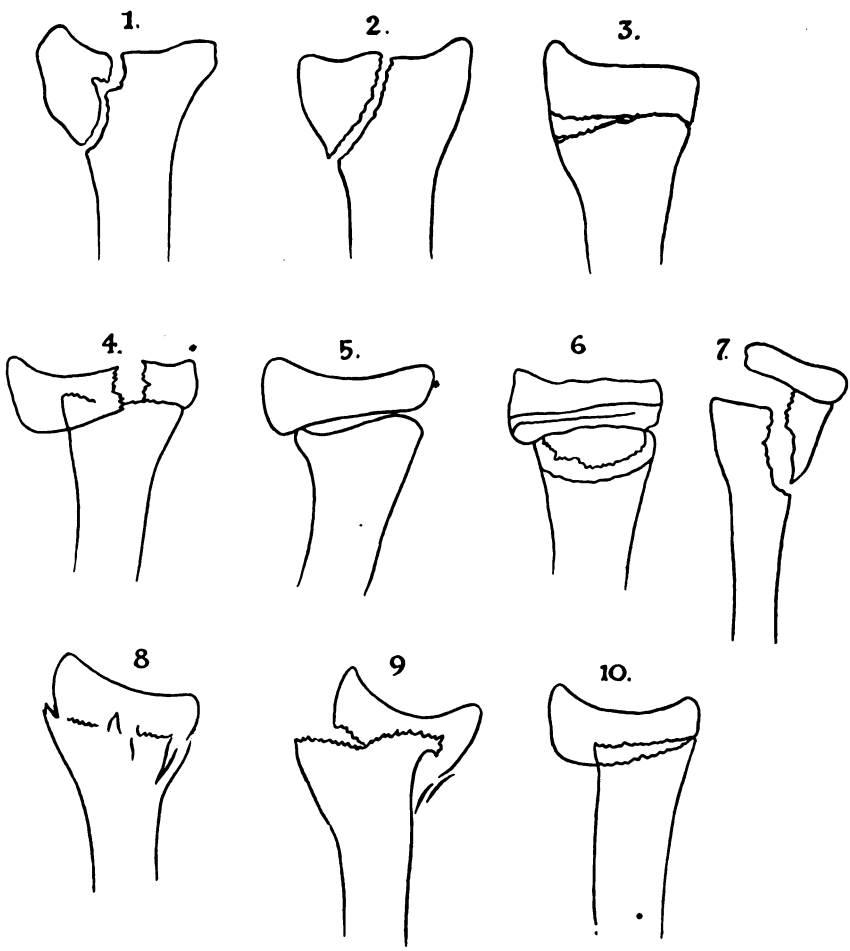

FIG 312.—OUTLINES OF *x*-RAY PICTURES OF VARIOUS FORMS OF FRACTURE OF THE LOWER END OF THE RADIUS.

1, Through base of styloid process; 2, through inner angle of lower end of radius; 3, transverse fracture without displacement; 4, comminution of distal fragments; 5, separation of epiphysis; 6 and 7, separation of epiphysis with chips of diaphysis; 8, impaction of lower into upper fragments; 9, typical Colles' (lateral view); 10, reverse Colles'.

which is often quite marked (Fig. 311). The injured hand is then grasped by the hand of the examiner while upward and downward movements are imparted to the lower end of the radius and ulna to determine abnormal mobility and crepitus. A second and very use-

ful method is to grasp the lower end of the forearm with the two hands of the examiner as shown in Fig. 317. In many of the injuries, especially of the carpal bones, an *x*-ray picture will be found to be indispensable.

(*a*) *Fractures of the Lower End of the Radius. Colles' Fracture.*— Our knowledge of this most common form of fracture has been greatly increased through the use of the *x*-rays. The various forms of fracture are shown in Fig. 312. Many of these are associated with no deformity and show the necessity of routine skiagraphic examinations, not only for the purpose of diagnosis, but for that of treatment as well. The classes which cause sufficient deformity to be recognized without the use of the *x*-ray are the comminuted and the impacted forms and those spoken of as typical Colles' fractures. In the latter, the line of fracture is more or less transverse and there is accompanying displacement of the lower fragment either to the radial side or posteriorly or both. In epiphyseal separation there is usually less deformity than in the typical form. The most marked symptoms of a Colles' fracture are the prominence over the back of the wrist and the change in outline of the ulnar side of the wrist (Fig. 313). The former is due to the upward displacement of the lower fragment and the latter to the displacement of the lower fragment with the hand toward the radial side of the forearm. Crepitus and abnormal mobility can often be obtained by grasping the wrist in one of the ways described above.

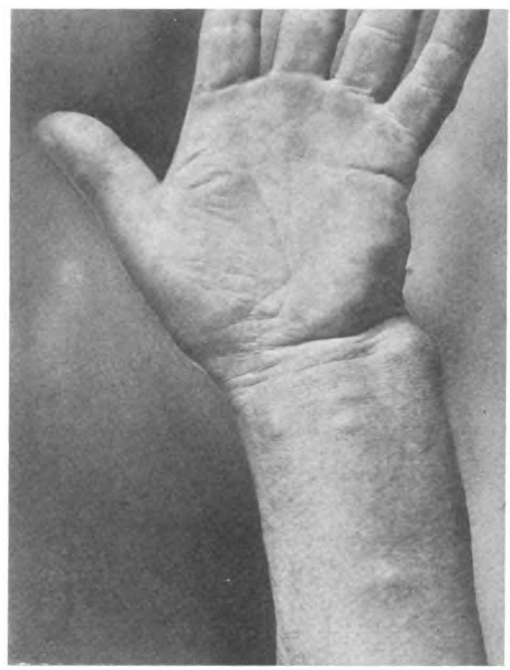

FIG. 313.—DEFORMITY FOLLOWING FRACTURE AT THE LOWER END OF THE RADIUS.

This is the exterior of the same case as is shown in *x*-ray of Fig. 315. Note the displacement of the hand and lower end of the radius toward the radial side of the arm, causing the styloid process of the ulna to become abnormally prominent.

If great swelling exists or there is little displacement, and also in

children, such an injury must be suspected if there is inability to use the wrist and well-localized pain referred on pressure to the lower end of the radius.

(*b*) and (*c*) Fractures of the styloid process of the ulna alone and of both bones near the wrist are quite uncommon. The former can be recognized by the abnormal mobility of the styloid process. In fractures of both bones the diagnosis is made from the presence of abnormal mobility, and crepitus at the lower ends of both bones.

(*d*) *Fractures and Dislocations of the Carpal Bones.*—The recognition of these injuries is of great importance, since many cases of sprains or contusions of the wrist are in reality fractures or dislocations of the carpal bones. The large majority of these are either simple fractures of the scaphoid or anterior dislocations of the semilunar bone. The two injuries are frequently combined, and in such cases (Codman and

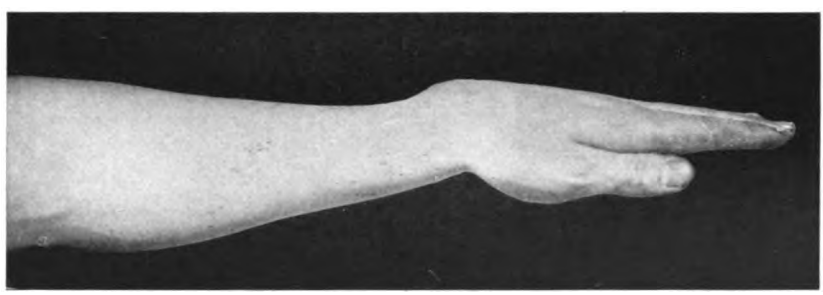

FIG. 314.—VIEW FROM RADIAL SIDE OF A TYPICAL SILVER-FORK DEFORMITY FOLLOWING COLLES FRACTURE. (See text.)

Chase[1]) the proximal fragment of the scaphoid is usually dislocated forward with the semilunar bone. Simple fracture of the scaphoid gives a definite clinical picture, and may be recognized, even without the *x*-ray, by the association of the following symptoms: viz., (*a*) The history of a fall on the extended hand; (*b*) localized swelling in the radial half of the wrist-joint; (*c*) acute tenderness in the "anatomic snuff-box" when the hand is adducted; (*d*) limitation of extension by muscular spasm, the overcoming of which causes unbearable pain.

Anterior dislocation of the semilunar bone should be recognized clinically, even without the *x*-ray, by the association of the following symptoms: viz., (*a*) The history of an injury of considerable violence to the extended or twisted wrist; (*b*) a silver-fork deformity, the posterior prominence of which corresponds with the head of the os magnum,

[1] "Annals of Surgery," May, 1905.

and between which and the lower end of the radius is found a groove representing the position formerly occupied by the now anteriorly dislocated semilunar; (*c*) a tumor under the flexor tendons of the wrist just anterior to the lower end of the radius; (*d*) a shortened appearance of the palm as compared with the other hand; (*e*) stiffness of the parti-

FIG. 315.—X-RAY OF A COLLES' FRACTURE, WITH MARKED DISPLACEMENT OF THE LOWER FRAGMENT TOWARD THE RADIAL SIDE OF THE ARM.

This is the same case shown in Fig. 313. Note how the radius has been shortened by the displacement of the lower fragment, so that the styloid process of the ulna projects quite prominently to the inner side of the wrist.

ally flexed fingers, motion of which, either active or passive, is painful; (*f*) the persistence of the normal relation of the styloid processes of the ulna and radius and the existence of shortening of the distance from the radial styloid to the base of the first metacarpal.

(*e*) and (*f*) *Dislocations of the Wrist and Carpo-metacarpal Disloca-*

tions.—Dislocation of the wrist is usually compound, but is uncommon. It may occur in a backward or forward direction. The former resembles a Colles' fracture, but differs from it by the fact that the prominence on the front of the wrist extends further down, even to the thumb, and ends more abruptly in dislocation than in fracture. The dorsal prominence is also more sharply outlined at its upper border in a fracture. In the forward variety there is a marked depression on the back of the

FIG. 316.—METHOD OF EXAMINATION FOR FRACTURES OF THE LOWER END OF THE RADIUS.

In the examination of the left forearm the wrist is grasped by the left hand of the examiner close to the point of fracture, while the right arm grasps the bone just above the suspected point of fracture. In the examination of the right arm this order should be reversed.

wrist, at the upper border of which is seen the sharp outline of the lower ends of the radius and ulna. There is a rounded prominence on the front of the wrist formed by the displaced carpus. The hand appears to be shortened at the expense of the wrist.

Dislocation backward of the metacarpal bone of the thumb is the most frequent and is oftenest incomplete. The posterior edge of the base of the metacarpal bone can be seen and felt in the depression known on the back of the thumb between the two long extensors. In the complete form this dorsal prominence is more marked. Dislocations of the other metacarpal bones alone or of all five simultaneously are

quite rare, and the reader is referred to the special text-books on fractures for their recognition.

Injuries of the Metacarpal Bones and Phalanges.—Fractures of the metacarpal bones and phalanges are far more common than was thought to be the case before the use of the *x*-ray. Many are not diagnosed, owing to the absence of displacement, unless a skiagraph is taken of every severe sprain or contusion of the hand. The deformity in metacarpal fracture is usually quite slight, except in those close to the metacarpo-phalangeal joint. In the latter class there is

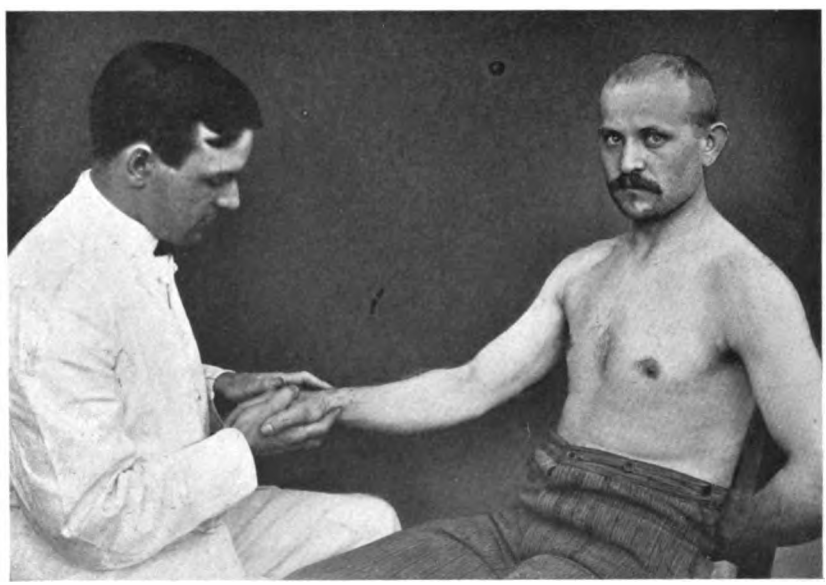

FIG. 317.—ONE OF THE METHODS OF EXAMINATION FOR FRACTURE OF THE LOWER END OF THE RADIUS.

In the case of the right radius, the patient's hand is grasped by the right hand of the examiner as though shaking hands. The index-finger of the examiner's right hand is placed below the lower end of the radius, while the fingers of the examiner's other hand are placed on the dorsal side of the same bone By a rocking or to-and-fro motion a false point of motion can be readily detected.

often a distinct depression, best seen when the joint is flexed, resembling a dislocation at this joint. At times the displacement of fragments in the shaft can readily be palpated. The deformity is often obscured by the great amount of swelling. Abnormal mobility and crepitus can be elicited by alternately flexing and extending the fingers, while the suspected bone is grasped between the index-fingers and thumbs of both hands of the examiner, the latter being placed on the dorsum and volar surfaces of the hand.

Fractures of the phalanges are usually due to crushing forces.

The proximal phalanx is most frequently involved. The diagnosis can be readily made by inspection of the wound in compound fractures. In the simple variety crepitus and abnormal mobility are easily elicited by grasping the phalanx with the fingers of the examiner and moving it to and fro. In those close to a joint the diagnosis is more difficult,

FIG. 318.—X-RAY OF A NORMAL HAND AND WRIST-JOINT.

The radius and ulna have been outlined in white; the carpal bones in black. U, Ulna; R, radius; P, pisiform; CF, cuneiform; SL, semilunar; SP, scaphoid; TM, trapezium; T, trapezoid; OM, os magnum; U, unciform.

and often necessitates the use of the *x*-ray, especially in children, in whom epiphyseal separation (Fig. 319) is not infrequent.

Dislocations of the proximal phalanx of the thumb are the most frequent of all, in the hand. The backward form is the most common one. The proximal end of the phalanx is to be seen and felt on the

back of the thumb, lying upon the metacarpal bone, the thumb being adducted. The head of the metacarpal bone can be seen and felt projecting on the front of the thumb. In forward dislocations the deformity is the opposite of the above.

Dislocations at the metacarpo-phalangeal joints occur most frequently in the thumb and index-finger and in a backward direction. There is a prominence on the back of the hand, due to the base of the phalanx, and one in the palm, due to the head of the displaced metacarpal bone. The finger may be extended or slightly flexed. The forward form is less frequent and the deformity is the reverse of that of the backward variety.

FIG. 319.—FRACTURE OF METACARPAL BONE OF LITTLE FINGER.

Dislocations of the middle and distal phalanges usually occur in a backward direction and are not difficult to recognize from the deformity. They are frequently compound.

Fractures of the Pelvis.—Fractures of the pelvis may be divided into:

1. *Those which involve the pelvic girdle as a whole:*

(*a*) Separation of the symphysis pubis.

(*b*) Fracture of the horizontal and ascending rami of the pubes.

(*c*) Vertical (single or double) fractures of the lateral portions, *e. g.*, the ilium passing through the acetabulum.

2. *Those which involve individual bones:*

(*a*) Fractures of the expanded upper portion of the ilium.

(*b*) Fractures of the rim of the acetabulum.

(*c*) Fractures of the ischium, sacrum and coccyx.

Of the above, the commonest are those in which the rami of the pubis or ischium or the alæ of the ilium are broken. The remaining ones are very rare. Fractures of the rim of the acetabulum resemble dislocation

of the hip so closely that they will be considered under the injuries of the hip. For diagnostic purposes fractures of the pelvis are best divided into (*a*) *those complicated by visceral injury*, and (*b*) *those not accompanied by such a lesion.* The possibility of a fracture of the pelvis with or without visceral complications must always be thought of in examining a patient who has been subjected to a crushing force, such as being run over, caught between buffers, etc. The diagnosis of fractures of the crest of the ilium and of those involving the ala or expanded upper portion of the ilium is, as a rule, not difficult. Crepitus is seldom present and but little force should be

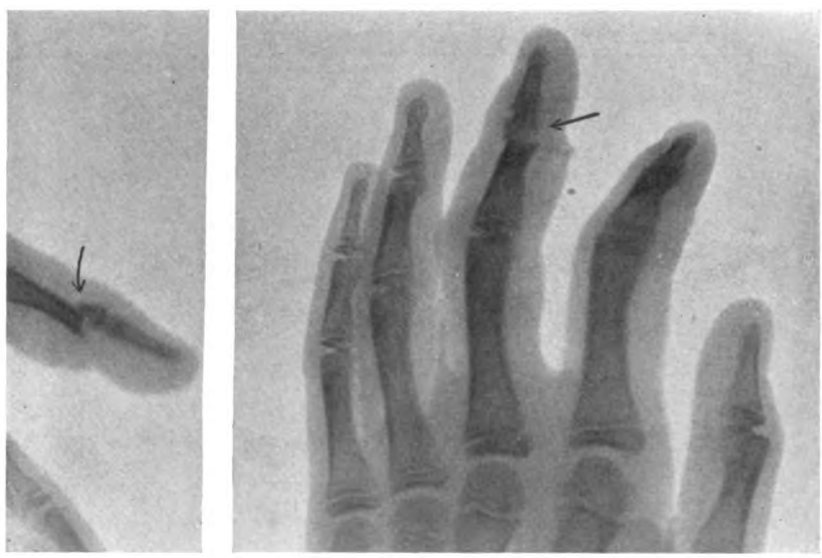

FIG. 320.—ANTERO-POSTERIOR AND LATERAL *x*-RAY VIEW OF FRACTURE OF THE SHAFT OF THE SECOND PHALANX OF THE MIDDLE FINGER, IN A GIRL OF EIGHT.

Exterior picture of this is shown in Fig. 321.

employed in efforts to elicit it. *Chief reliance must be placed upon localized pain and abnormal mobility.* These are best elicited by a systematic examination of the entire crest of the ilium, placing a hand on each side of the pelvis, while pressure is gently exerted upon the underlying bone. In many cases it is possible by this manipulation to detect either displaced fragments or abnormal mobility. The latter sign is more apt to be present than the former. Repeated examinations will often show the pain to be accurately localized to the seat of fracture. In fractures of other portions of the pelvis it is inadvisable to attempt to make a diagnosis by manipulation. Usually there

is but little displacement, so that the diagnosis must be made from the accompanying visceral injuries. A rectal examination and an *x*-ray should never be omitted in doubtful cases, as they often enable an exact diagnosis to be made.

The complications of fractures of the pelvis are, in the order of their frequency: (1) Rupture of the urethra; (2) rupture of the bladder; (3) rupture of one of the other abdominal viscera (kidney, spleen, liver, bowel, etc.); (4) rupture of the external iliac artery or vein.

A diagnosis of such visceral injuries is only of value for treatment by operation if made during the first twelve to twenty-four hours after

FIG. 321.—COMPOUND FRACTURE OF PHALANGES.
This is the exterior view of the case of which the *x*-ray is shown in Fig. 320. (See text.)

injury, and if the patients are unable to urinate or blood escapes from the urethra they should be most thoroughly examined with these lesions in mind.

The principal diagnostic points of these are as follows:

1. *Rupture of the Urethra.*—(*a*) Retention of urine. If the patient is able to urinate, the act is only accomplished with great difficulty and pain, the urine is scanty and accompanied by considerable amounts of clotted and liquid, bright-colored blood. (*b*) Pain over the perineum and end of the penis. (*c*) Swelling and evidences of subcutaneous hemorrhage of the perineum, scrotum, and penis. (*d*) Blood escapes from the urethra, and when the catheter is inserted bloody urine in small quantity is withdrawn.

2. *Rupture of the Bladder.*—In extraperitoneal rupture, an area of dullness appears (Fig. 323) above the pubes and there is a feeling of fullness around the bladder when a rectal examination is made. There is retention of urine or an incontinence of retention exists. Small amounts of bloody urine constantly escape from the external meatus. If a catheter is inserted into the bladder, a small quantity of bloody urine is obtained. If, as in one case of the author's, a fracture of the pelvis is complicated both by an extraperitoneal rupture of the blad-

FIG. 322.—TYPICAL LOCATIONS OF LINES OF FRACTURE IN FRACTURES OF THE PELVIS.

Note the line of fracture passing through the horizontal ramus of the pubis, and a second at the junction of the descending ramus of the pubis and ascending ramus of the ischium. The posterior fracture lines pass through the ilium in a Y manner, terminating in the greater sciatic notch.

der and a rupture of the urethra, a diagnosis of the presence of both conditions is seldom possible. In the majority of cases the bladder injury which accompanies fractures of the pelvis is in the form of an extraperitoneal rupture. Those in which the tear is in that portion of the viscus covered by peritoneum are much less frequent. The diagnosis of such intraperitoneal ruptures of the bladder has already been referred to. The symptoms are those of a septic peritonitis, but are slower and more insidious in their appearance than in the case of

a ruptured intestine, etc. Injuries of the other abdominal viscera must always be thought of in connection with fractures of the pelvis. Their symptoms and diagnosis do not differ from those previously given.

The Diagnosis of Injuries of the Hip.—The possibility of the following lesions must be borne in mind in adults:

1. Fracture of the neck of the femur.
2. Dislocation of the hip.
3. Fracture of the head of the femur or rim of the acetabulum.
4. Fracture of and through the trochanter.
5. Contusion of the hip.

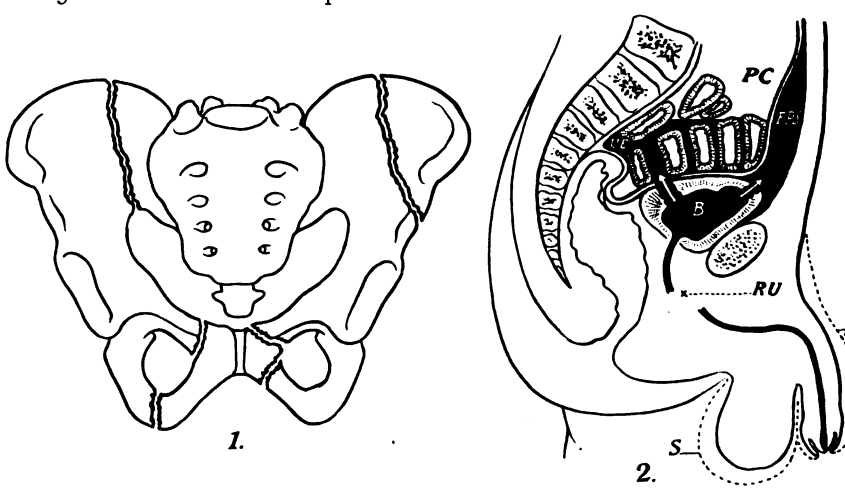

FIG. 323.—VARIETIES OF FRACTURES OF THE PELVIS AND MOST FREQUENT COMPLICATIONS.

1, Shows the most frequent lines of fracture of the pelvis (see text); 2, shows the three most frequent complications of fractures of the pelvis. *RU*, Rupture of urethra associated with extravasation of urine into the scrotum (*S*) and penis (*p*); *B*, bladder. The arrow upon the anterior wall indicates an extraperitoneal rupture of the bladder with extravasation of urine into the extraperitoneal cellular tissue around the bladder and between the peritoneum and anterior abdominal wall (*EPS*). The arrow situated upon the posterior wall and the fundus of the bladder indicates the escape of urine through an intraperitoneal tear into the free peritoneal cavity. The black area (*UE*) indicates the urine escaping between the coils of intestine into the general peritoneal cavity (*PC*).

In children and young adults the possibility of an epiphyseal separation or traumatic coxa vara must also be thought of. The examination when conducted in a systematic manner will enable a diagnosis to be made in the majority of cases without the use of an *x*-ray. The latter should, however, be employed whenever possible. Satisfactory skiagraphs of the hip, especially in adults, are very difficult to obtain unless the operator has had considerable experience and is provided with an excellent tube.

The chief points to be determined are: (*a*) The attitude of the

limb; (*b*) the amount of shortening as determined by a measurement of the limb in the manner indicated in Fig. 324, viz., from the lower border of the inner malleolus (when the limb is adducted) through the middle of the patella to the anterior superior spine of the ilium; (*c*) the relation of the upper border of the trochanter to the Roser-Nélaton line (Fig. 325); (*d*) gentle manipulation of the limb to deter-

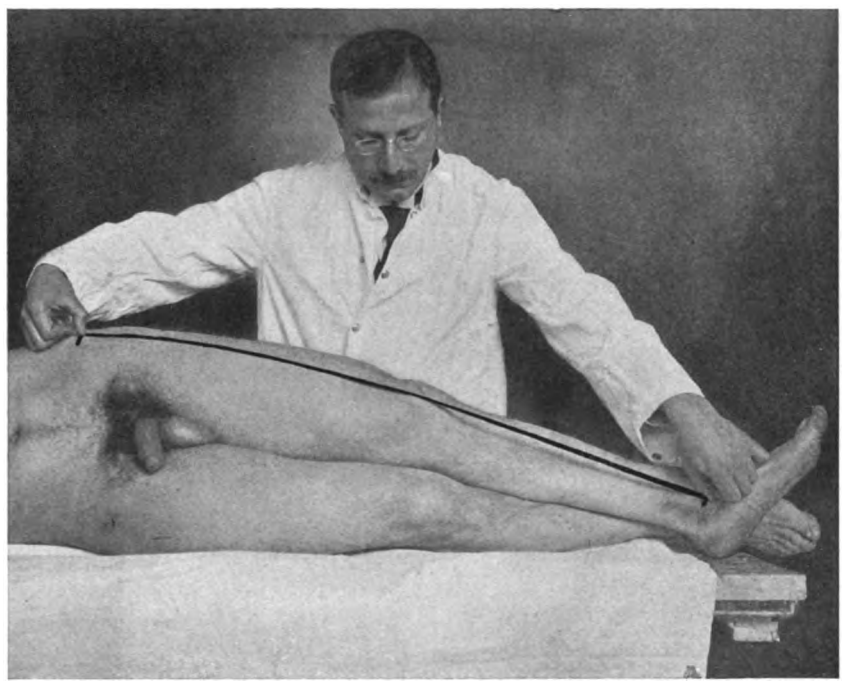

FIG. 324.—MEASUREMENT OF LENGTH OF LIMB TO BE EMPLOYED IN CASES OF DISLOCATION OF THE HEAD OF THE FEMUR OR FRACTURE OF ITS NECK.

One end of the steel tape-measure is laid upon the anterior superior spine of the ilium, which has been previously outlined with ink or a blue pencil, while the other hand holds the tape-measure immediately below the inner malleolus. The tape passes through the middle of the patella. Both limbs should be placed flat upon the table at an equal distance from the median line, *i. e.*, adducted.

mine the presence or absence of crepitus, abnormal mobility, or fixation, etc.

In doubtful cases it is advisable to administer an anesthetic, owing to the fact that the muscular rigidity disappears; otherwise it might render a diagnosis very difficult or impossible.

The principal diagnostic features of the above named lesions of the hip are:

1. *Fractures of the Neck of the Femur.*—These may take place either at the point of junction of the neck or at the base of the neck

where it joins the shaft. It is of little importance, from the standpoint of either diagnosis or treatment, to determine whether the fracture is situated within or without the capsule, *i. e.*, intracapsular or extracapsular.

It is of far more value to ascertain whether the fracture is impacted or not. Loss of function of the limb is, as a rule, quite marked. The patient is unable to walk upon the limb or to move it without experiencing great pain in the hip, and then only to a very limited extent. There is often pain on pressure over the trochanter or neck of the bone. The position is quite characteristic (Fig. 326). The limb is usually

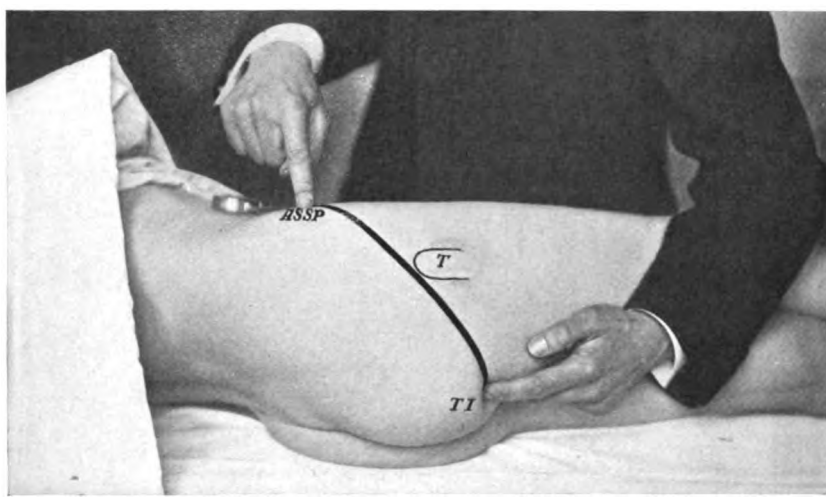

FIG. 325.—METHOD OF DETERMINING THE RELATION OF THE TROCHANTER TO THE ROSER-NÉLATON LINE.

The patient is laid upon the side of the body opposite to the one to be examined, the steel tape is stretched from the anterior superior spine of the ilium, *ASSP*, to the tuberosity of the ischium. These two points are fixed by the index-fingers of the two hands, preferably those of an assistant, while the examiner marks the lower level of the tape as it crosses the upper border of the trochanter. Under normal conditions the tape should pass exactly along the upper border of the trochanter.

everted so that the outer border of the foot rests upon the bed. Quite rarely the limb is inverted, this being more marked after a few days. Measurement of the limb must always be carried out with both limbs in the same position, if possible brought as near as may be to the median line of the body with the toes pointing upward. The two standard modes of measurement are: (*a*) From the lower border of the inner malleolus to the anterior superior spine of the ilium (Fig. 324). (*b*) Bryant's method. A line is dropped from the anterior superior spine to the table or bed in a perpendicular manner. The distance from the upper border of the trochanter to this line (Fig. 325) is less

on the side of the injury than upon the opposite side. Both of these measurements should always be made upon the bare skin, the various points having been previously marked.

In fracture of the neck of the femur the above measurements will show a shortening which varies from a small fraction of an inch to two or three inches. It may be present at its maximum, just after the acci-

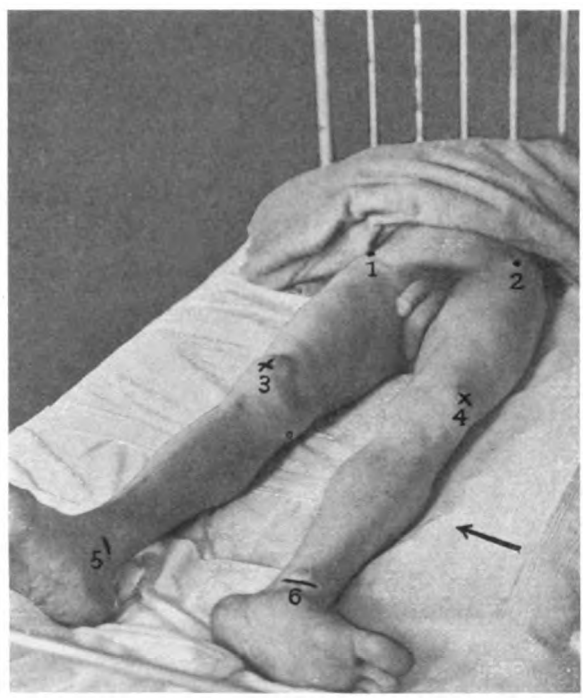

FIG. 326.—EVERSION OF LOWER EXTREMITY IN A CASE OF RECENT FRACTURE OF THE NECK OF THE FEMUR.

The arrow points to the markedly everted limb. 1 and 2, Anterior superior spines of the ilium; 3 and 4, placed on center of patellæ; note how the patella on the fractured side points outward; 5 and 6, marks placed on lower border of internal malleoli. The measurement of the limb for shortening should be made as shown in Fig. 324, from 2 to 6 on the fractured side, and 1 to 5 on the normal side, passing through the middle of the patellæ. The characteristic shortening of the limb can be observed by comparing the points 5 and 6, taking into consideration at the same time the elevation of the pelvis on the side of the injury.

dent, or absent at first and appear gradually or suddenly after a few hours to days. It must not be forgotten that a normal difference of ½ to 1 inch may exist in the length of the limbs. Crepitus is present in unimpacted but is absent in impacted fractures.

Only the most gentle manipulation is permissible to elicit crepitus, since rough handling may readily do great damage in breaking up an impaction.

Palpation of the neck of the femur in the manner shown in Fig. 328, while an assistant rotates the limb very gently, will often enable one to detect abnormal mobility, thickening or tenderness about the neck of the bone. The history of the case will show that the majority of patients fell upon the region of the greater trochanter, rarely upon the more distant portions of the limb. Fracture of the neck of the femur in young people is considered separately.

2. *Dislocation of the Hip.*—This may occur chiefly in a forward or backward direction. Of the posterior or backward variety there are two forms: (*a*) the iliac, the head resting upon the dorsum of the

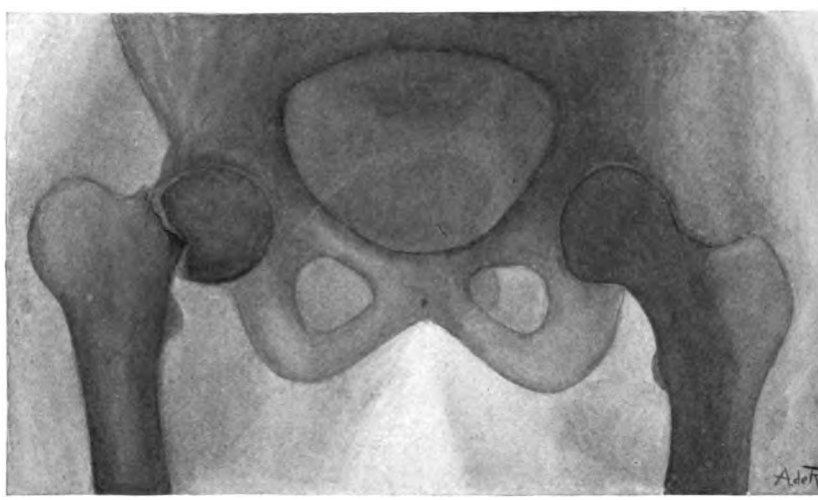

FIG. 327.—X-RAY OF A FRACTURE OF THE NECK OF THE FEMUR, AT THE JUNCTION OF THE HEAD AND NECK WITH UPWARD DISPLACEMENT OF THE SHAFT OF THE FEMUR.

On the opposite side note the outlines of the normal femur and hip-joint. This *x*-ray was kindly loaned to the author by Dr. Le Moyne Wills.

ilium, and (*b*) the ischiadic, the head being located in the sciatic notch. Of the anterior or forward variety there are also two forms: (*a*) the obturator or thyroid, the head lying over the obturator foramen, and (*b*) the pubic, the head resting upon the pubic ramus.

The majority of hip dislocations are dorsal (55 per cent.), the next most frequent are the sciatic (20 to 25 per cent.), then the obturator (15 per cent.), and the pubic (5 per cent.).

The signs of the two forms of backward dislocation are practically the same, those of the dorsal being more marked than is the case with the sciatic variety. The position of the limb is one of moderate adduction and flexion, marked inversion, and more or less shortening, the

toes of the injured limb resting upon the sound foot (Fig. 329). Measurement of the limb shows that the trochanter lies above the Roser-Nélaton line. It is almost impossible to bring the two limbs into a sufficiently symmetrical position to enable an accurate measurement of their length to be made, but this is rarely necessary to make a diagnosis.

The head of the bone can be indistinctly felt through the gluteal muscles, especially when attempts are made to rotate the limb.

In forward or anterior dislocations of the hip the limb is slightly

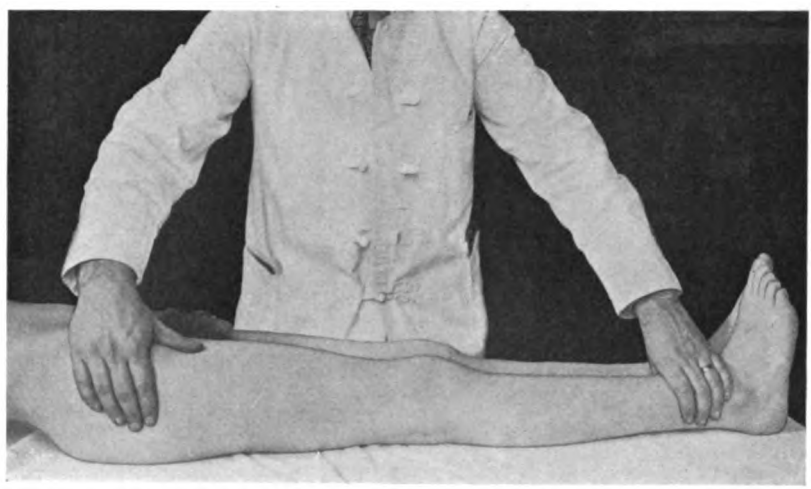

FIG. 328.—METHOD OF EXAMINATION OF THE LOWER EXTREMITY FOR ABNORMAL MOTION AT NECK OF FEMUR.

For photographic purposes it was necessary to have the examiner stand upon the left side of the patient. In practice in examining the right lower extremity the left hand should grasp the trochanter, the fingers placed upon the back of the latter, and the thumb upon its anterior surface. The right hand should be placed across the front of the ankle-joint. In examining the left limb, the order should be reversed, the right hand being placed over the trochanter, and the left over the ankle.

flexed, abducted, and rotated outward. There is apparent lengthening of the limb, but careful measurement will show that this is not real.

In the obturator form, the head of the bone can be indistinctly felt toward the obturator foramen. In the pubic form the limb is considerably more abducted and everted than in the thyroid variety. The head of the femur can also be more distinctly felt in the groin.

3. *Fracture of the Head of the Femur or Rim of the Acetabulum.*—The former is so rare and has so few characteristic signs that it may be left out of consideration in the differentiation of injuries of the hip.

Fractures of the acetabulum are also infrequent. In the majority of such cases the posterior rim of the acetabulum is broken off and the

accompanying dislocation is backward. Fracture of the rim of the acetabulum may occur as a complication of backward dislocations of the hip, from which it can only be distinguished, without the use of the *x*-ray, by the fact that the dislocation can be reduced without difficulty, possibly with crepitus, but tends to recur.

It can be distinguished from fracture of the neck of the femur by the straightness and lack of eversion of the limb, and from *backward dislocation* of the hip, by the position of the limb, viz., adduction, inward rotation, and slight flexion.

FIG. 329.—DISLOCATION OF HIP, DORSUM ILII VARIETY (Macdonald).

4. *Fracture of or through the great trochanter.* Both of these are very rare. In the former the diagnosis can only be made without a skiagraph by the independent mobility of the trochanter. In the fracture through the great trochanter, the *pertrochanteric fracture of Kocher*, the differentiation from ordinary fractures of the neck is impossible unless a prominent angle is distinctly visible anteriorly, which is formed by the two fragments. The eversion and shortening of the limb are the same as in fracture of the neck.

5. *Contusion of the Hip.*—If the case has been systematically examined as to the history of the accident, the posture and loss of function of the limb, the shortening and fixation, the diagnosis from a simple contusion ought not to present any difficulties. Contusion of the hip may occur at any age. It usually follows a fall upon the trochanter, and there are often evidences of a contusion of the soft parts around it. The limb is straight, the head of the bone cannot be felt in an abnormal place, there is no shortening, and the trochanter lies in the Roser-Nélaton line and rotates in the normal manner. There may be localized pain and some limitation of motion. If there is any doubt the administration of an anesthetic is of great aid. The same may be said for the *x*-ray.

Injuries of the Hip in Children.—Acquired traumatic dislocations of the hip are infrequent in early life, and until recent years it was thought that fractures of the neck of the femur were equally rare.

Coxa Vara Traumatica.—This name was first given by Sprengel [1] in 1898 to a condition following injuries of the neck of the femur in children and young adults. According to Sprengel and others, the resultant deformity, which consists of a bending downward and backward of the neck, is due to an epiphyseal separation which may be complete or incomplete.

Whitman [2] is of the opinion that the injury is a true fracture of the neck and only rarely a separation of the neck from the head at

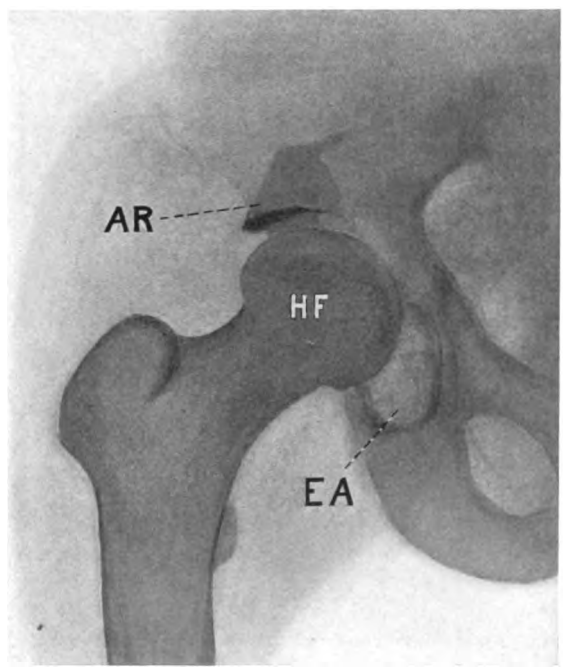

FIG. 330.—X-RAY OF FRACTURE OF RIM OF ACETABULUM.

AR, Fragment of rim of acetabulum, which has been displaced upward and backward; HF, head of femur which has been allowed to be displaced through the absence of the acetabular rim, thus causing a backward and upward dislocation of the hip-joint.

their junction (Fig. 445). In the majority of cases the lesion is undoubtedly one of epiphyseal separation. In both epiphyseal separations and fractures of the neck the condition may follow even a slight trauma and result in the deformity known as coxa vara (page 648).

In children fracture of the neck can be distinguished clinically and with the *x*-ray from epiphyseal separation, according to Whitman, as follows:

In fracture of the neck there is more shortening, less outward rota-

[1] "Archiv für klinische Chirurgie," Bd. lvii. [2] "Medical Record," March 10, 1904.

tion, and the trochanter is more prominent. Motion at the hip-joint is practically free, except in abduction, which is particularly restricted when the limb is flexed.

In epiphyseal separation the shortening is less, the outward rotation greater. Frequently there is a swelling to be felt over Scarpa's triangle over the position of the head. The trochanter is not as prominent, but motions at the hip-joint are always more restricted, due to

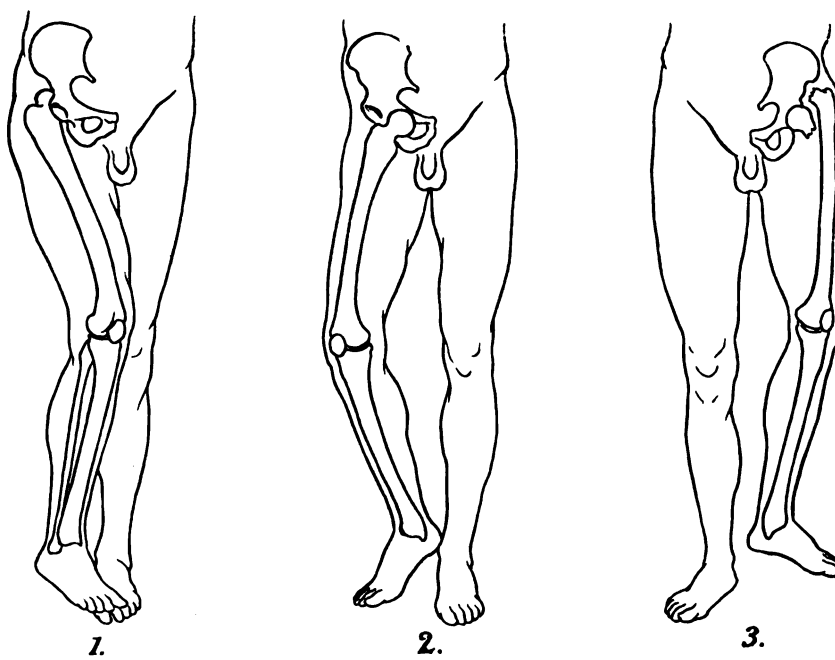

FIG. 331.—MOST FREQUENT CONDITIONS TO BE CONSIDERED IN DIFFERENTIAL DIAGNOSIS OF INJURIES OF THE HIP-JOINT.

1, Backward and upward dislocation of the head of femur; 2, forward dislocation of head of femur; 3, fracture of neck of femur.

dislocation of the head and to the reflex muscle spasm resulting from the traumatic synovitis.

The cases are often seen months to years after the accident, when the resultant coxa vara is the most prominent sign. At such a period it is impossible to differentiate a coxa vara traumaticum from a true coxa vara.

Fractures of the Femur.—The diagnosis of these fractures usually presents no difficulties. Their recognition is easier when the fracture is a complete one and the periosteum has been torn. In such patients the usual signs of fractures, viz., abnormal mobility, deformity, crepitus, loss of function, and pain are quite marked.

If the fracture is incomplete or the periosteum has not been torn, as not infrequently occurs in children, especially in those suffering from scurvy or rachitis, the diagnosis is far more difficult. This is due to the fact that there is but little deformity and the diagnosis depends chiefly upon the elicitation of crepitus and abnormal mobility combined with localized pain and loss of function.

Fractures of the shaft are divided into those (*a*) of the upper, (*b*) of the middle, and (*c*) of the lower third. In fractures of the upper third the line of fracture is most oblique, the upper fragment being displaced upward and forward and the lower one upward and inward (Fig. 334), resulting in a greater degree of shortening than is present in fracture of the other two-thirds.

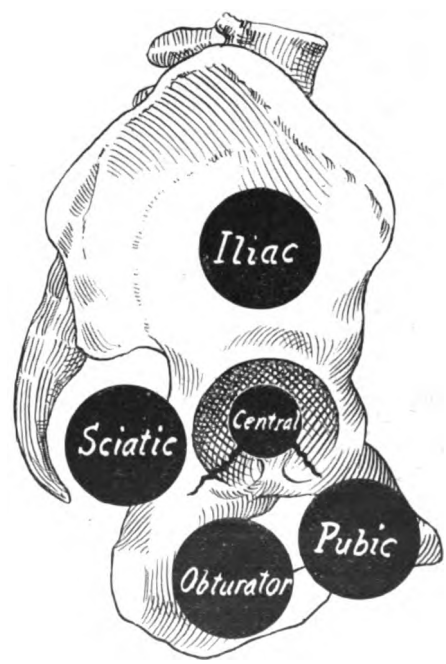

FIG. 332.—LOCATION OF HEAD IN VARIOUS FORMS OF DISLOCATION OF HIP.

In fractures of the middle third the line of fracture is either oblique or spiral in direction. Even in healthy children the periosteum often remains untorn in fractures at this level. Both fragments are usually displaced outward, forming an angle, or there is considerable overlapping of the fragments.

In fractures of the lower third the line of fracture is oftener transverse and the upper fragment overrides the lower, there being but little tendency to outward displacement.

The diagnosis of fractures of the shaft depends to a great extent upon the recognition of the deformity and shortening which result from the displacement of fragments. This is often so marked and visible as to require but little manipulation.

The degree of shortening can be determined by measurement of the limbs from the anterior superior spine of the ilium to the lower border of the inner malleolus, and comparison with that of the opposite limb. Both limbs should form the same angle with the pelvis when the measurements are made and should be brought as close to the median line of the body as possible.

Abnormal mobility and crepitus are most marked in fractures of the upper and middle thirds, especially if complete, and can be best elicited by grasping the limb in the manner shown in Fig. 334.

The projecting ends of the upper and lower fragments can often be felt beneath the skin in simple fractures or projecting through it in compound fractures. In fractures of the lower third the diagnosis is more difficult, on account of the accompanying effusion into the knee-joint and the

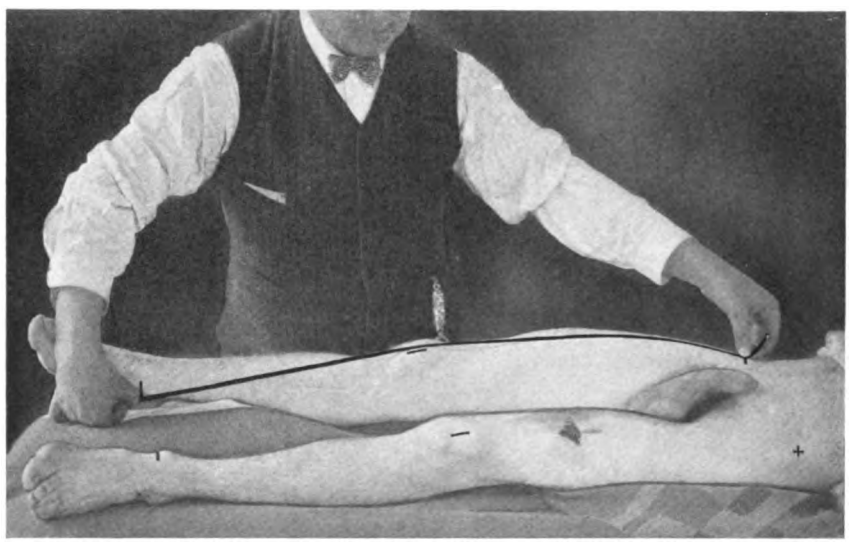

FIG. 333.—METHOD OF MEASURING THE LENGTH OF THE TWO LIMBS IN A CASE OF FRACTURE OF THE SHAFT OR OF THE NECK OF THE FEMUR.

While the patient is lying upon his back, three points should be marked on each limb, as shown in the illustration, namely, the anterior superior spine of the ilium, the middle of the patella, and the lower border of the inner malleolus. There may be apparent shortening due to the elevation of the pelvis, as shown in the illustration. The method of measurement consists in placing one end of a steel tape-measure on the anterior superior spine, and the other across the line drawn just below the inner malleolus. The tape-measure should pass exactly through the line drawn in a vertical manner through the middle of the patella. In the illustration this latter line has been purposely shown a little to the inner side of the tape-measure. The outward rotation of the limb in fractures of the shaft of the femur is well shown in this patient.

slighter degree of displacement of fragments. There is usually, however, marked loss of function, swelling, and some degree of deformity.

In every case in which the diagnosis of fracture of the lower third of the femur (supracondyloid) has been made an examination of the limb distal to the knee should be made. This should include (*a*) the palpation of the superficial arteries, like the dorsalis pedis and posterior tibial, for loss of pulsation as the result of injury of the popliteal artery, and (*b*) the changes in color of the limb, swelling, etc., which might result from compression and thrombosis of the popliteal vein (Fig. 266).

Fractures of the Lower End of the Femur.—These greatly resemble those of the lower end of the humerus. They are: (*a*) Intercondyloid; (*b*) fractures of either condyle; and (*c*) separation of the lower epiphysis.

In the intercondyloid variety the line of fracture is either T- or Y-shaped, is very apt to be compound and associated with injury of the popliteal vessels. The diagnosis is made from the independent mobility of the two condyles on each other, when they are moved backward and forward, and by the pain, when they are pressed together. Effusion into the knee-joint is constant and often obscures the recognition of the fracture. Separation of either condyle is not accompanied by any shortening. It

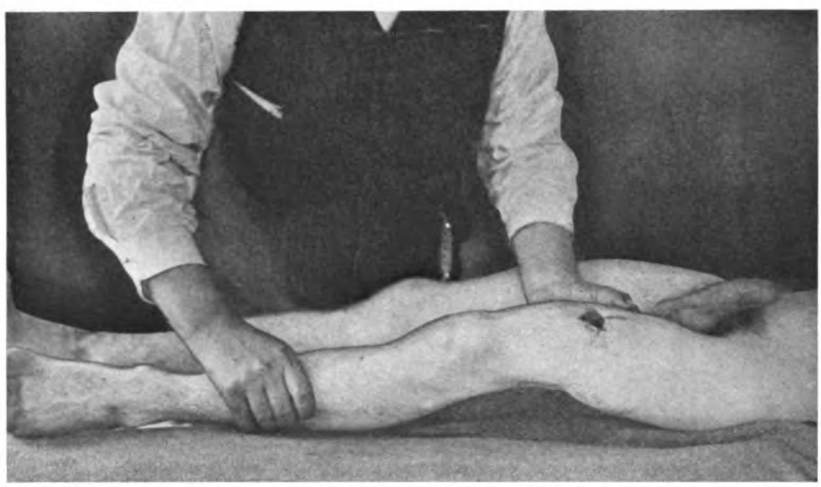

FIG. 334.—METHOD OF EXAMINATION FOR FRACTURE OF SHAFT OF FEMUR.

The injured thigh is laid upon the outstretched hand of the examiner, with palm upward, while the opposite hand grasps the middle of the leg. While the hand which is supporting the point of fracture fixes the thigh to some extent, the opposite hand by a motion to and away from the median line of the body enables one to determine the false point of motion. In this illustration the forward bowing of the limb due to slipping of the fragments past each other is well shown, causing considerable shortening of the limb.

is quite rare and is usually overlooked because there is but little displacement. Separation of the lower epiphysis of the femur is next in order of frequency to epiphyseal separation of the upper end of the humerus. The epiphysis is usually displaced forward and the shaft pulled backward by the gastrocnemius muscle. The latter displacement may in some cases endanger the popliteal vessels, as in supracondyloid fracture (Fig. 266).

The diagnosis can be made from (*a*) the presence of abnormal mobility in a young person, just above the knee-joint; (*b*) the palpation of the two fragments, the lower in front of the upper, and (*c*) the elicitation

of a soft cartilaginous crepitus. One should never neglect to search for absence of pulsation of the superficial arteries below the point of fracture and note any changes in the color of the limb.

Injuries in the Vicinity of the Knee-joint.—These include:

1. Fractures and epiphyseal separation at the lower end of the femur.
2. (*a*) Fractures or (*b*) dislocation of the patella.
3. Dislocations of the knee (upper end of the tibia).
4. Fractures of the upper end of the (*a*) tibia and (*b*) fibula.
5. Sprain or other injuries of the knee-joint proper and of its ligaments.

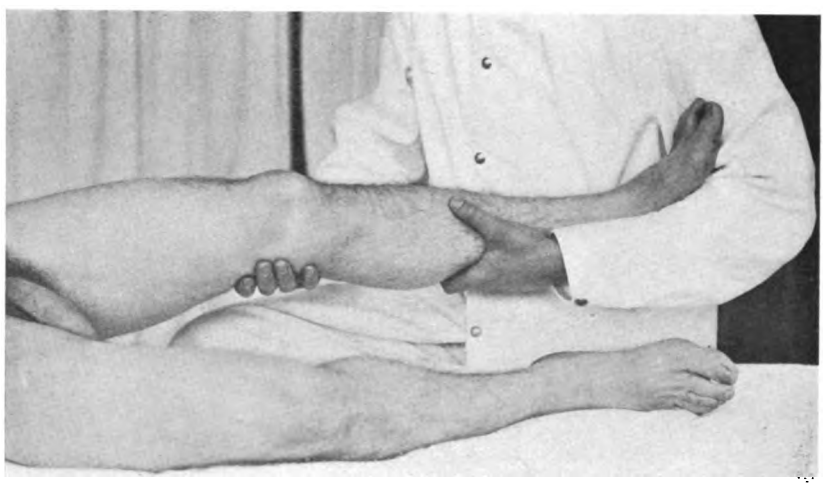

FIG. 335.—METHOD OF DETERMINING ABNORMAL LATERAL MOBILITY OF KNEE-JOINT, DUE TO TEARING OR STRETCHING OF THE LATERAL LIGAMENTS.

The patient while lying down is grasped so that the knee rests upon the palm of the examiner's right hand, if the left limb is to be examined, and vice versa in the case of the right limb, while the opposite hand grasps the leg at about its middle, the object being to fix the knee more or less with the hand beneath it, while the other hand by to-and-fro motions determines any increase in lateral mobility.

In every case of injury in the vicinity of the knee one must exclude all of the above named injuries through systematic examination as follows:

(*a*) Inspection. This will often show at once the presence of a deformity, changes in color of the limb due to vessel injury, or the swelling of the knee-joint proper with obliteration of its normal depressions (Fig. 336) on either side of the patella.

(*b*) Palpation and manipulation. This will show: (1) the presence of fluid in the knee-joint by ballotement of the patella (Fig. 335) and measurement of the circumference; (2) palpation of the surface of and position of the patella will show the presence or absence of a fracture or dislocation of this bone; (3) manipulation of the knee as shown in Fig. 335 will reveal

the presence of abnormal mobility due to laceration of the lateral ligaments; (4) palpation and manipulation of the lower end of the femur and upper end of the bones of the leg will reveal the presence or absence of abnormal relation to each other, as in dislocation of the knee, or of abnormal mobility, deformity, or crepitus, as in fractures or epiphyseal separation.

The methods of examination for ruptured ligamentum patellæ and for injuries of the semilunar cartilages have been previously given.

The principal diagnostic points of the above named injuries are as follows:

1. *Fractures and Epiphyseal Separation of the Lower End of the Femur.*—(See page 503.)

2. (*a*) *Fractures of the Patella.*—There is usually great swelling of the knee, most marked about six to eight hours after the accident. Unless this effusion into the knee is too extensive, it is possible to feel a hiatus or gap in the patella and to move the two fragments independently of each other, by grasping them between the thumb and index-fingers. Crepitus can often be elicited by this manipulation. If the fragments are close together, both of these signs are less marked. The patient is unable to extend the limb, and there is usually great pain in the knee, especially when the fragments are pressed together or the limb is flexed.

FIG. 336.—CASE: FRACTURE OF THE PATELLÆ. Moderate separation of the fragments of each knee-joint. Useful legs (Scudder).

2. (*b*) *Dislocations of the Patella.*—These are quite rare, forming about one per cent. of all forms of dislocation. Dislocation may occur outward, inward, or edgewise (vertical). Of these, the outward variety is the most frequent. The knee appears flatter and broader than usual and the intercondyloid notch is quite prominent. The patella can be felt on the outer side of the condyle, and at its upper and lower ends respectively the quadriceps tendon and ligamentum patellæ can be felt as tense bands. The inward and vertical forms are rare and their recognition is similar to that of the outward form.

3. *Dislocations of the Knee.*—These are as rare as those of the patella. This form of dislocation is very rare in children. Dislocations of the knee are divided, according to the direction in which the tibia is displaced, into forward, backward, outward, and inward varieties, and there is a fifth form, or dislocation by rotation. The lateral (outward and inward) varieties are usually associated with more or less rotation. *Dislocation forward* is the most frequent of all and can be readily recognized. The tibia lies in a plane in front of that of the thigh. The outline of the tibia can be seen and felt lying in front of the lower end of the femur, the latter being prominent in the popliteal space. The limb may be fixed or movable in any direction. There may be evidences of injury of the popliteal artery and of the internal popliteal nerve; the former can be recognized by the loss of pulsation and the latter by the loss of sensation (pages 430 and 434).

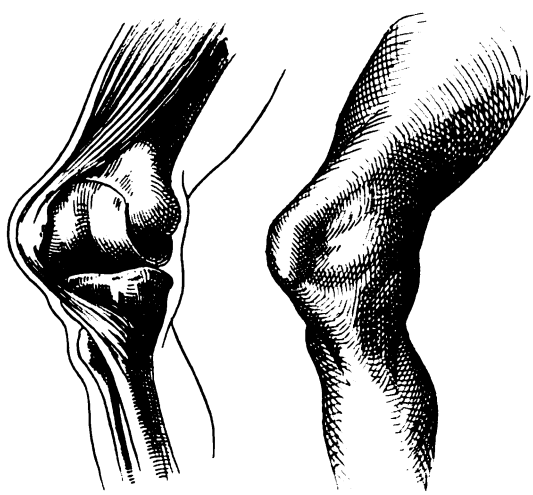

FIG. 337.—OUTWARD DISLOCATION OF THE PATELLA (Hoffa).

In the backward variety the above signs are reversed. The head of the tibia lies behind the condyles of the femur and can be felt in the popliteal space. There is a marked depression below the condyles of the femur in front of the knee. Injury of the popliteal vessels is even more frequent than in the forward variety.

Lateral dislocations are quite rare and their recognition is not difficult, the outer part of the head of the tibia projecting on the outer side of the joint in the outward and in the opposite manner in the inward variety.

4. *Fractures of the Upper End of the Tibia and Fibula.*—Fractures of the upper end of the tibia usually extend into the knee-joint. The most frequent form is that in which the line of fracture is oblique and results in the separation of either the internal or external condyle from the remainder of the bone (Fig. 338). In addition to the oblique fractures of the condyles, transverse and longitudinal fractures occur, but are comparatively infrequent. A form of compression fracture has also

been described by Wagner of Königshütte, in which there is a fracture of either condyle and more or less marked crushing of the head of the tibia after a fall upon the foot.

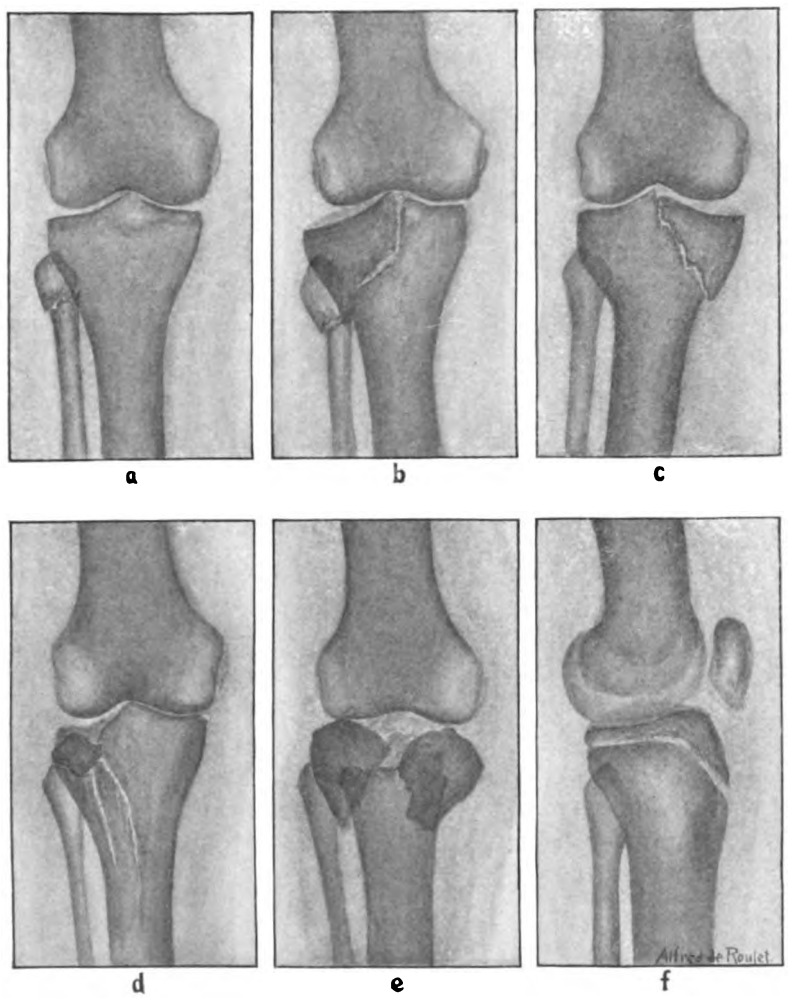

FIG. 338.—VARIOUS FORMS OF FRACTURES OF THE UPPER END OF THE TIBIA AND FIBULA NEAR THE KNEE-JOINT.

A, Fracture of the upper end of the fibula alone. B, Fracture passing through the outer tuberosity of the knee-joint, accompanied by fracture of the upper end of the fibula close to its head. C, Fracture passing through the inner tuberosity of the tibia, with displacement of the leg outward, resulting in a genu valgum position. D, Multiple crushing fracture of the outer tuberosity of the tibia. E, Multiple crushing fracture of the upper end of the tibia, extending into knee-joint. The lower fragment composed of the shaft is forced upward between the two upper fragments, composed of the tuberosities. F, Side view of separation of upper epiphysis of tibia and the beak-shaped process of same.

The diagnosis of a fracture of the upper end of the tibia is often impossible without the aid of an anesthetic and the *x*-ray. In almost

every case the accompanying effusion into the knee-joint is so marked after a few hours as to render an examination very difficult.

In fractures involving one of the condyles abnormal mobility of the knee either in an inward or outward direction will be found when the knee is manipulated in the manner shown in Fig. 335. There is great pain on pressure over the fractured condyle. If the internal con-

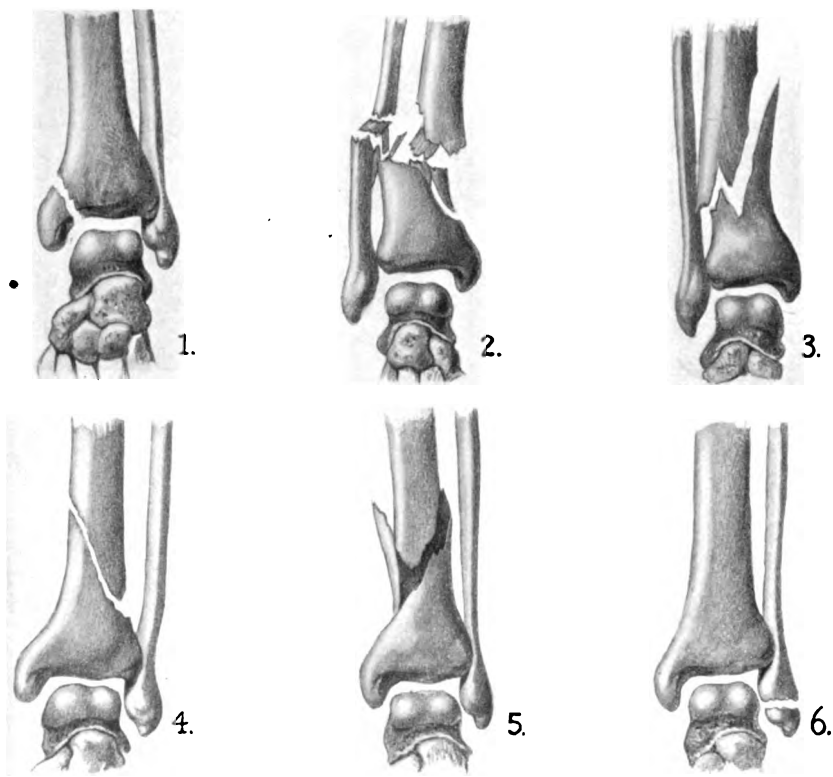

FIG. 339.—VARIOUS FORMS OF FRACTURES IN LOWER THIRD OF LEG.

Wash drawings made from skiagraphs. 1, Fracture of internal malleolus; 2, comminuted fracture of tibia and fibula at junction of lower and middle third; 3, oblique fracture of tibia with displacement of upper fragments outward; 4, oblique fracture of tibia without displacement; 5, spiral fracture of lower third of tibia; 6, fracture of external malleolus.

dyle is involved, there is abnormal mobility at the knee in an inward direction or the limb is found in a genu varum position. If the external condyle is broken, abnormal mobility in an outward direction is to be found and the limb is held in a genu valgum position. Unless the swelling of the knee-joint is too great, one can palpate the displaced condyle and in some cases elicit distinct crepitus.

If both condyles have been broken and the shaft has been displaced upward between them, there is widening of the knee-joint.

Separation of the upper epiphysis of the tibia, of which twenty-six cases have been reported, is, like that of the lower epiphysis of the femur, a serious and often fatal injury.

The swelling of the knee-joint is usually considerable. Mobility of the epiphysis, most noticeable in a lateral direction, is, as in other epiphyseal separations, the most trustworthy sign, according to Poland. Crepitus of a soft muffled character can be detected in many of the simpler cases in which mobility of the epiphysis is present. Dislocation of the knee is scarcely known in children and the free movement of the joint in cases of separation suffices to exclude this form of injury. When there is little or no displacement or mobility, the injury may be mistaken for a sprain of the knee. Osgood has recently called attention to a peculiar partial separation of the tongue-shaped portion of the upper tibial epiphysis in young athletes. Clinically acute pain is felt in the knee, referred to below the patella. It is accompanied by slight swelling of the joint and there is considerable weakness on exertion.

FIG. 340.—COMPOUND (GUNSHOT) COMMINUTED FRACTURE OF THE LOWER THIRD OF THE TIBIA AND FIBULA.

The line passing across the upper portion of the plate is due to a defect. The black particles of the bullet fragments are well shown lying over the front of the tibia.

Avulsion of the tubercle of the tibia occurs in the young. The diagnosis can be made by the recognition of independent mobility of the tubercle, inability to use the limb, and swelling of the knee-joint.

In some cases there is only local pain and tenderness and the diagnosis cannot be made without the aid of a skiagraph.

Fractures of the upper end of the fibula occur either through muscular

action of the biceps or more commonly through forcible adduction of the leg. The injury may be recognized by the presence of pain just below the head of the fibula, accompanied by the presence of a small, hard mass, movable from side to side, which is raised by extension, but sinks after flexion of the knee-joint. There is also abnormal lateral mobility

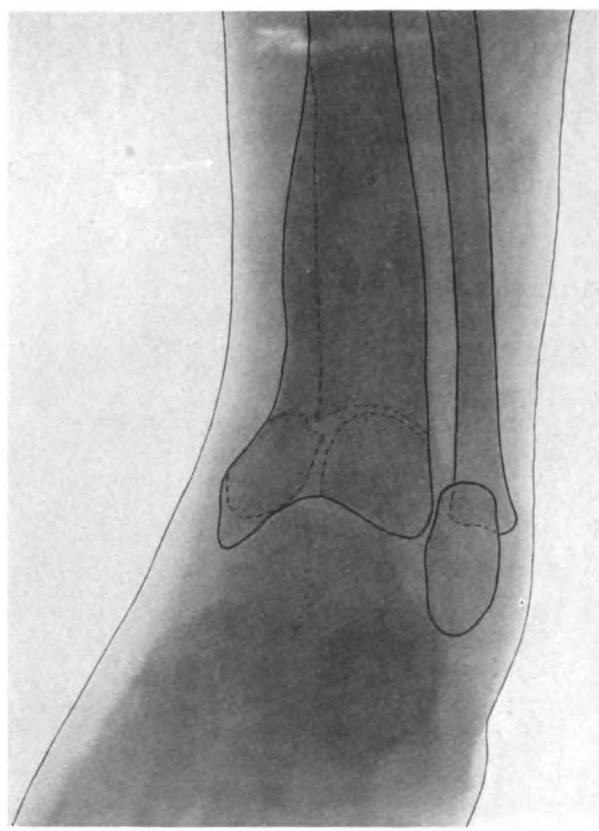

FIG. 341.—X-RAY OF CASE OF FRACTURE OF BOTH BONES OF THE LEG, THE EXTERIOR PICTURES OF WHICH ARE SHOWN IN FIGS. 343 AND 344.

Note the voluminous callus formation in the tibia, and the displacement inward of both lower fragments and of the foot.

of the knee-joint. Not infrequently the injury is followed by paralysis of the muscles (peronei) supplied by the peroneal nerve, causing inability to raise the outer border of the foot.

Fractures of the Shaft of the Tibia.—These occur more frequently after direct injuries (when the limb is run over, or a heavy body falls on it) than after indirect injuries (such as a sudden abduction or adduc-

tion of foot). Both bones of the leg are usually broken after indirect violence, complete fractures are far more frequent in adults than in children.

The line of fracture is most often oblique (Fig. 339), although spiral fractures have been found in about one-seventh of all of the cases. This is important to diagnose by the use of the *x*-ray, owing to the fact that

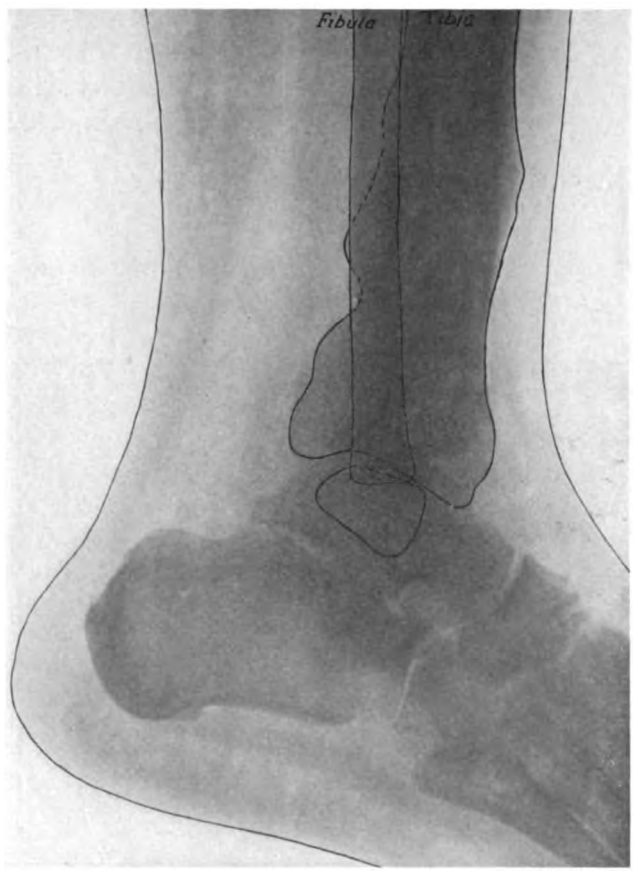

FIG. 342.—X-RAY OF SAME CASE AS SHOWN IN FIGS. 341 AND 343, OF FRACTURE OF BOTH BONES OF THE LEG JUST ABOVE THE ANKLE-JOINT.

The illustration shows the characteristic backward displacement of the foot and lower fragments.

in the spiral form the fracture is much more difficult to reduce completely.

In the oblique form, the line of fracture runs from below and anteriorly backward and upward, so that the upper fragment is often displaced forward to such an extent as to lie directly beneath the skin.

Comminuted fractures, especially of the lower end of the tibia and

fibula, are not uncommon. The *diagnosis of a fracture of the shaft of one or both bones of the leg* is, as a rule, not difficult.

In many cases the deformity at the point of fracture and the outward rotation of the foot will permit a diagnosis to be made from inspection alone. In some cases of compound fracture the ends of the fragments project through the skin. By gently grasping the limb while the assistant supports the knee or ankle, abnormal mobility and crepitus can be readily elicited.

FIG. 343.—ANTERIOR VIEW OF DEFORMITY FOLLOWING POTT'S FRACTURE.

Note the change in the axis of the right or injured limb from the middle of the leg downward. This deformity was due to the displacement inward of the lower fragments of the tibia and fibula respectively.

Shortening of the limb can be estimated by measurement from the upper border of the inner tuberosity of the tibia to the tip of the inner malleolus. The finger should also be passed along the tibia and fibula wherever they lie beneath the skin in order to detect any irregularity. In a few cases where the broken ends are dentated and displaced but little, one must be content, in the absence of a skiagraph, with making a diagnosis from the presence of localized pain and swelling followed by loss of function.

When both bones are broken the abnormal mobility is usually much greater than is the case if the tibia alone is fractured. *Isolated fractures of the upper and middle thirds of the shaft of the fibula* are relatively rare. The diagnosis of such fractures depends upon the localized pain and the elicitation of crepitus and abnormal mobility on pressure.

It is of the greatest importance to combine the use of the *x*-ray with the above outlined external examination. It reveals many cases of in-

complete or subperiosteal fractures where none were suspected. It also yields much information as to the degree of displacement and the direction of the line of fracture, whether spiral, oblique, or transverse.

Separation of the lower epiphysis of the tibia is more frequent than is that of the upper. Deformity is the most marked sign, the foot and the epiphysis being displaced backward. The internal malleolus preserves its normal relations with the foot, but not with the

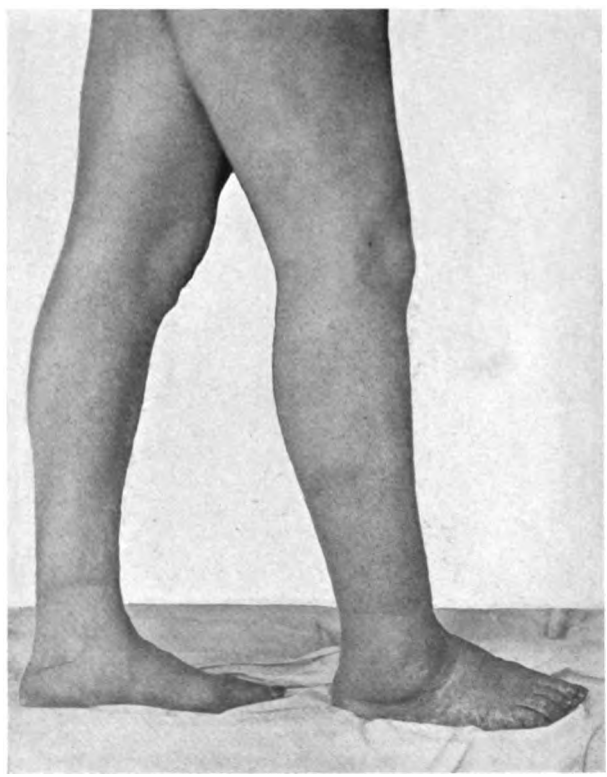

FIG. 344.—VIEW FROM OUTER SIDE OF DEFORMITY FOLLOWING POTT'S FRACTURE.
Note the prominence of the external malleolus, due to the displacement outward of both upper fragments, that is, of the tibia and fibula.

rest of the leg or the external malleolus. In gunshot fractures (Fig. 340) of the leg, the comminution of the tibia is usually much more extensive than is thought from external examination.

Injuries in the Vicinity of the Ankle-joint.—In the examination of a patient who shows evidences of injury in the vicinity of the ankle-joint, such as swelling, deformity, loss of function, etc., the following conditions must be thought of and excluded, in the order given:

1. Fractures of the lower ends of the tibia and fibula (Pott's fracture).
2. Dislocations at or near the ankle.
3. Fractures of the tarsal bones.
4. Rupture of the tendo Achillis. (See page 426.)
5. Sprains of the ankle.[1] (See page 450.)

1. Fractures of the Lower End of the Tibia and Fibula.—These are all given the name of Pott's fracture. They may be the result either

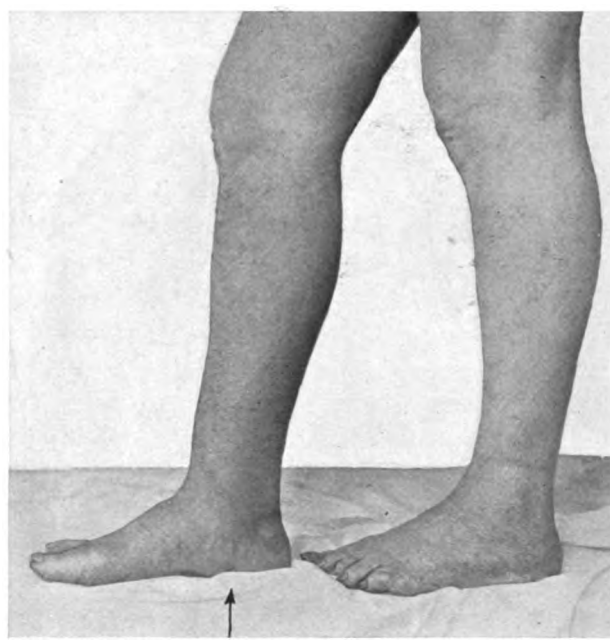

FIG. 345.—VIEW OF A DEFORMITY FOLLOWING POTT'S FRACTURE FROM THE INNER SIDE.

Note the bowing forward at the lower third of the anterior aspect of the leg. The arrow points to a frequent complication of fractures of the lower third of the tibia and fibula, namely, traumatic flat-foot. This is the same case as is shown in Fig. 344.

(*a*) of forcible abduction or eversion of the foot, or (*b*) of inversion or adduction. If the sole or main movement is eversion the internal malleolus is broken, and if the force continues to act it also causes the external malleolus to be broken. In the second variety, *i. e.*, fracture by inversion, the first effect of the force is to break the fibula (external malleolus). If the movement continues, the internal malleolus or a greater portion of the tibia is broken off.

[1] Sprains of the ankle are not infrequently accompanied by fractures of the lower end of the tibia and fibula which can only be recognized if an *x*-ray be taken.

There is usually no difficulty in making a diagnosis. The ankle-joint is greatly swollen, the depression normally present, in front of and behind the malleoli, being obliterated. The foot is displaced outward and the internal malleolus is prominent. This deformity will often persist and become a cause of disability after healing of the fracture (Fig. 343). There is also backward displacement of the foot (Fig. 344).

These displacements may be so marked as to resemble a true dislo-

FIG. 346.—FRACTURE OF BOTH BONES OF THE LEG WITH MARKED BACKWARD DISPLACEMENT.

cation of the ankle at first glance. Abnormal lateral and antero-posterior mobility may be ascertained by grasping the sole of the foot (Fig. 349) with one hand and moving it inward or outward or backward and forward while the other hand steadies the leg. There is great tenderness between the tibia and fibula at the front of the ankle and over the points of fracture in the malleoli.

If the fibula alone is broken, abnormal mobility and crepitus may be

elicited by pressing its tip inward with the index-finger of one hand (Fig. 348) while a finger of the other hand is placed at the seat of fracture.

In some cases of Pott's fracture the foot will move inward instead of outward. The degree of backward displacement can be measured by the difference in the distance from the front of the ankle to the cleft between the first and second toes as measured on the sound and on the injured foot. There is not always complete loss of function. In fractures of the external malleolus alone the patient may walk quite well.

FIG. 347.—FRONT VIEW OF A RECENT POTT'S FRACTURE, WITH SLIGHT DISPLACEMENT OF FRAGMENTS.

Note the swelling of the lower third of the left leg, and the obliteration of the normal depressions over the front of the ankle-joint, and above and below the malleoli, on the left or injured limb.

2. Dislocations at or Near the Ankle.—These injuries are very rare, constituting, according to the statistics of Krönlein, only about 0.5 per cent. of all forms of dislocations. The displacement may be complete or incomplete, the latter occurring more frequently. Dislocations at the ankle are often associated with fractures of one or both bones of the leg, especially of the malleoli.

Dislocations at the Ankle-joint (Tibiotarsal Dislocations).—They are best divided (*a*) into those which occur in a sagittal direction, *i. e.*, forward or backward, and (*b*) into those which take place laterally, *i. e.*, outward or inward.

(*a*) *Dislocations in a Sagittal Direction.*—In the forward variety (Fig. 351) the whole foot appears to be lengthened. The prominence due to the heel has disappeared. The upper articular surface of the astragalus can be felt, and the malleoli are nearer to the heel. It can be differentiated from a fracture of both bones of the leg above the malleoli by the fact that in a forward dislocation the malleoli are further

back than normal, while in a supramalleolar fracture they have moved forward with the foot.

In the backward variety, the findings are opposite to those of the forward. The front portion of the foot is shortened (Fig. 351) while the heel is more prominent than normal. The lower end of the tibia protrudes over the dorsum of the foot and the sharp edge of its articular surface is to be felt distinctly. The extensor tendons and the tendo Achillis are tense and prominent. It may be distinguished from a supramalleolar fracture by the fact that the malleoli in the latter have moved backward with the foot, while in a dislocation backward they are prominent at some distance forward from the heel.

FIG. 348.—ONE OF THE METHODS OF EXAMINATION IN ORDER TO DETERMINE A FRACTURE OF THE EXTERNAL MALLEOLUS.

The method consists in making pressure upon the tip of the malleolus, as shown in the illustration, with the two fingers of one hand, while the other hand is placed at the suspected point of fracture. The hand placed over the tip presses it in and allows it to spring back, thus establishing a kind of lever action, which permits the other fingers to detect readily a false point of motion.

(*b*) *Dislocations in a Lateral Direction.*—The inward variety is very rare, only twenty-seven cases having been reported. It is not infrequently compound or associated with fractures of the tarsal bones or of the bones of the leg. The convex upper articular surface is prominent (Fig. 351) just below the outer malleolus.

In the outward variety the most frequent form is that in which the foot is markedly abducted, much more so than in an ordinary Pott's fracture. The inner border of the foot points upward while the outer border rests upon the ground or table. The upper articular surface of the astragalus is to be felt just below the internal malleolus. A few cases have been reported. The abduction is so extreme that the toes

point directly outward (Fig. 351), the foot forming an angle of 90 degrees with the leg. To this subvariety the term rotation-outward dislocation of the ankle has been given.

As is true of all varieties of injuries about the ankle or of the foot, the *x*-ray has been of the greatest aid in making an early diagnosis of the nature of the injury.

Subastragaloid Dislocations.—These occur in the astragalo-calcaneal joint (Fig. 352). There are two chief forms: viz., (*a*) the true subastragaloid, in which the astragalus remains in articulation with the tibia and fibula but is displaced from its articulation with the calcaneus. In the other form (*b*) the astragalus is completely separated from its re-

FIG. 349.— METHOD OF EXAMINATION FOR FRACTURE OF THE TIBIA OR OF BOTH BONES OF THE LEG CLOSE TO THE ANKLE-JOINT.

The foot is grasped by the left hand of the examiner when fracture of the left leg is suspected, while the right hand grasps the region just above the malleoli, so as to steady the limb during the time that the foot is being turned toward or away from the median line of the body, in order to determine false point of motion and crepitus.

lations to the bones of the leg and calcaneus. This latter is called "total dislocation of the astragalus." The true subastragaloid dislocation may occur in one of four directions, viz., inward, outward, forward, and backward.

The most frequent of these (thirteen out of twenty cases reported) is the outward variety. They follow forced abduction of the foot, especially a fall upon the heel, while the foot is excessively abducted, or a blow upon the outer side of the leg, while the foot is fixed. The position of the foot is that of a well-marked case of flat-foot. The internal malleolus is nearer to the sole of the foot. In front of this malleolus, the head of the astragalus forms a prominence and the scaphoid is to be distinctly felt

upon the sole of the foot. The injury is not infrequently compound, so that the astragalus presents in the wound.

An important point in the diagnosis of subastragaloid dislocation is the absence of any prominence due to the projection of the body of the astragalus in front, behind, or on either side of the malleoli, as is the case in the tibio-tarsal dislocations described above. Another fact is the abnormal position of the calcaneus and scaphoid with relation to the mal-

FIG. 350.—LATERAL VIEW OF AMOUNT OF FIXATION OF ANKLE-JOINT FOLLOWING MANY INJURIES IN CLOSE PROXIMITY TO THE SAME.

The lower one of the two limbs shows the degree of extension of the foot on the uninjured side. On the side of the fracture it can be readily seen that the amount of extension is practically lost, and that the foot is fixed at a right angle to the long axis of the leg.

leoli and astragalus. The swelling is usually so great that a diagnosis is very difficult without the use of the *x*-ray.

Total dislocation of the astragalus is much more frequent than that of the tibio-tarsal or astragalo-calcaneal joint. The most frequent form is the outward. In this variety the foot is rotated markedly inward, *i. e.*, adducted and inverted, or club-foot position. The external malleolus is very prominent, and below it one can feel the dislocated astragalus.

3. Fractures of the Tarsal Bones.—After a fall from a height the tissues around the ankle-joint are often so enormously swollen that an exact diagnosis by palpation is very difficult. If by a systematic exam-

ination one has excluded all of the varieties of injuries just described, one must not omit a careful search, aided by the *x*-ray, for fractures of the astragalus and calcaneus. These have been frequently overlooked, and not until ankylosis has occurred was the suspicion aroused that the case might have been more than a severe sprain. Fractures of the tarsal bones, especially of the astragalus and calcaneus, are not infrequently associated with one of the other injuries around the ankle, viz., fractures or dislocations of the tibia and fibula.

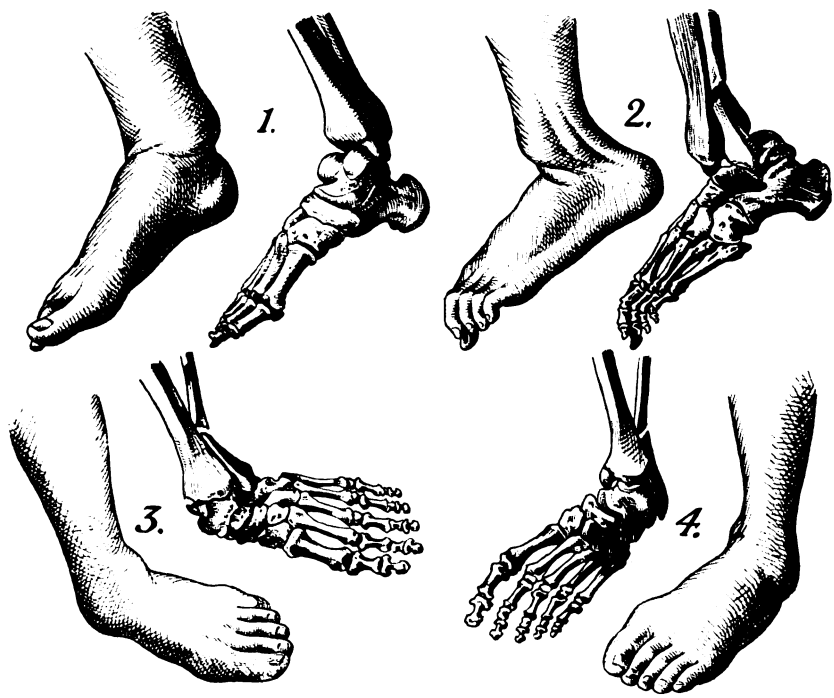

FIG. 351.—VARIOUS FORMS OF DISLOCATIONS OF THE ANKLE-JOINT (Hoffa).

1, Forward dislocation of the foot; 2, backward dislocation of the foot, associated with fracture of the fibula; 3, outward dislocation of the foot, associated with fracture of the tibia and fibula; 4, inward dislocation of the foot, associated with fracture of the tibia and fibula. (See text.)

The diagnosis of fractures of the astragalus can be most satisfactorily made if every injury about the ankle is systematically examined with the *x*-ray. If there is no displacement of fragments, a diagnosis is almost impossible at the time of injury, the case being usually diagnosed as a severe sprain. There is, however, more pain on pressure and upon flexing the foot, than is the case in a sprain, and not infrequently crepitus can be elicited. If there is displacement of fragments the diagnosis is a little less difficult, since one can at times feel the displaced fragments. In

fractures of the neck of the astragalus, the foot is extended and supinated, while in those of the head or body, it is flattened or even in a pes valgus position, the malleoli is lower than normal, especially when the body is greatly comminuted (Fig. 355).

Fractures of the Os Calcis.—These are divided (*a*) into compression fractures of the body; (*b*) tearing fractures of the tuberosity; the latter is most apt to occur, as in the patient whose *x*-ray is shown in Fig.

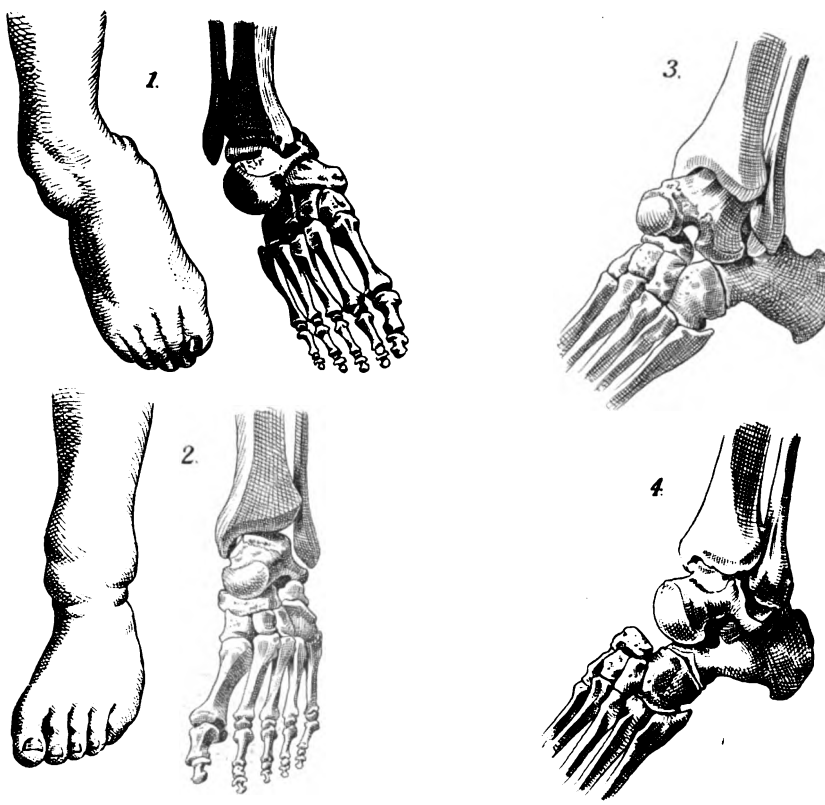

FIG. 352.—VARIOUS FORMS OF SUBASTRAGALOID DISLOCATION OF THE FOOT (Hoffa).
1, Outward; 2, inward; 3, backward; 4, forward.

354, by falling forward while the heel is fixed, and is often associated with a tearing off of the attachment of the tendo Achillis to the os calcis. The diagnosis in the second variety is easier than in the crushing or compression fractures of the body of the bone. The detached fragment can often be felt just beneath the skin above the heel.

In both varieties the depressions below the malleoli are noticeably obliterated, there is marked swelling of the entire ankle (Fig. 357) and

enlargement of the heel. The malleoli lie closer to the sole of the foot. There is marked tenderness on pressure of the calcaneus and severe pain on walking. Passive adduction and abduction of the foot are especially interfered with and painful.

In both tearing and compression fractures the use of the *x*-ray is invaluable. One should, however, always compare this skiagraph with one taken of the normal ankle of the patient.

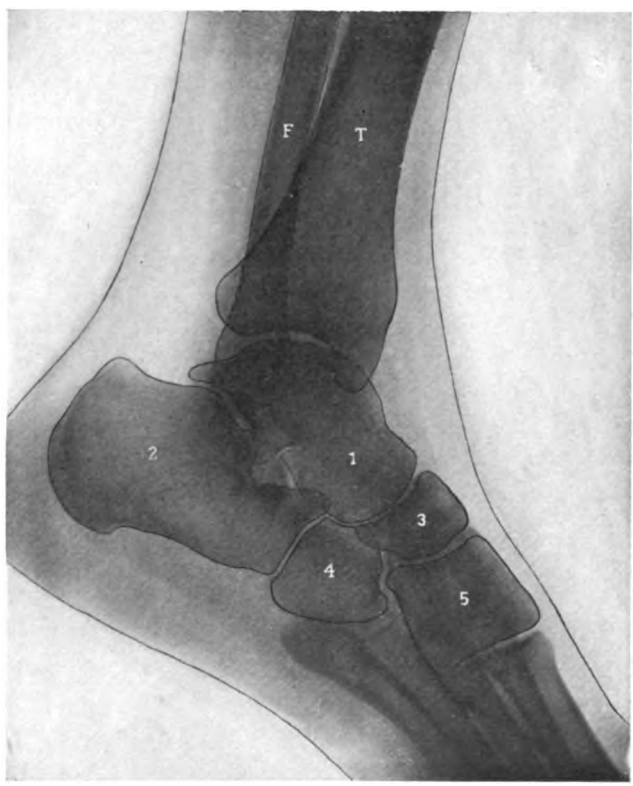

FIG. 353.—X-RAY OF NORMAL FOOT AND ANKLE-JOINT VIEWED FROM THE OUTER SIDE.
F, Fibula; T, tibia; 1, astragalus; 2, os calcis; 3, scaphoid; 4, cuboid; 5, external cuneiform.

Fractures of the Remaining Tarsal Bones of the Metatarsals and of the Phalanges of the Toes.—These occur from heavy weights falling upon the dorsum of the foot or from being run over. Fractures of the metatarsal bones may also result from jumping or from long marches, such as soldiers make.

In the case of the metatarsal bones the diagnosis is made from the presence of severe, well localized pain, swelling, and not infrequently crepitus and deformity. Standing upon the foot causes great pain. A

traumatic flat-foot may follow this form of fracture or large calluses develop on the sole of the foot over the seat of fracture. Fractures of the phalanges of the toes are usually the result of a crushing force and are often compound. The diagnosis is readily made by inspection and

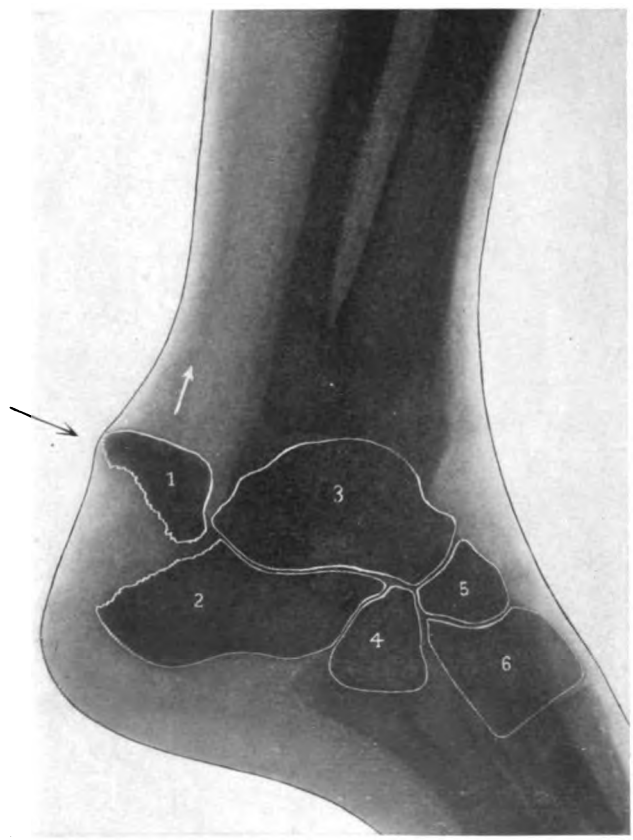

FIG. 354.—FRACTURE OF OS CALCIS (*x*-RAY) BY MUSCULAR VIOLENCE.

The white arrow indicates the direction of traction of the gastrocnemius and soleus muscles. The black arrow points to the characteristic elevation of the skin caused by the displacement upward of the fragment in such cases. 1, Fragment of os calcis; 2, main portion of bone; 3, astragalus; 4, 5, and 6, tarsal bones (cuboid, scaphoid, and cuneiform, respectively).

from the presence of a false point of motion and crepitus on manipulation.

Dislocations of the Metatarsal Bones.—These may be either complete or incomplete at Lisfranc's joint. They occur most often in an upward direction and may follow such injuries as being run over, the fall of a heavy weight upon the foot, or forcible flexion of the foot. The dorsum of the foot is more convex than normal while the sole of the foot

is flattened. One can see and feel the displaced upper ends of the metatarsals on the dorsum of the foot. The foot is shortened and the toes point inward. Dislocations of the individual metatarsal bones are much rarer. The middle ones are displaced upward and the first and fifth inward and outward respectively.

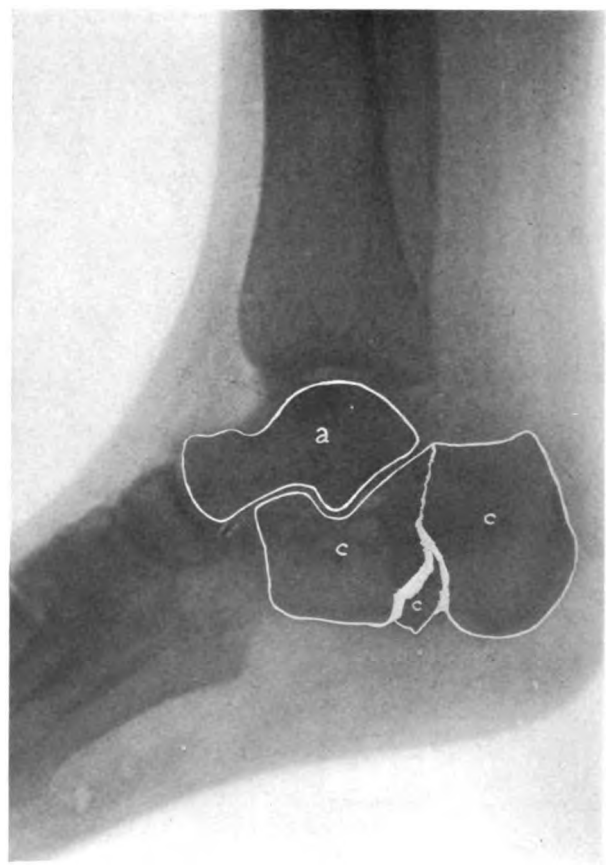

FIG. 355.—COMPRESSION FRACTURE OF OS CALCIS. FOLLOWING FALL UPON THE FEET FROM A HEIGHT OF FORTY FEET.

a, Astragalus; c, c, c, fragments of os calcis.

Dislocations of the Toes.—These occur most often in the great toe after forcible dorsal flexion. The dislocation may be complete or incomplete. In the former case the proximal end of the first phalanx is prominent on the dorsum of the foot, and on the sole of the foot the head of the metatarsal bone projects.

COMPLICATIONS OF INJURIES.

SHOCK AND HEMORRHAGE.

It is of the greatest importance to be able to recognize the presence of one or both of these complications clinically in order that the case may be intelligently treated.

The symptoms of hemorrhage into closed cavities, like the cranium, pleural, pericardial, and peritoneal cavities, have already been referred

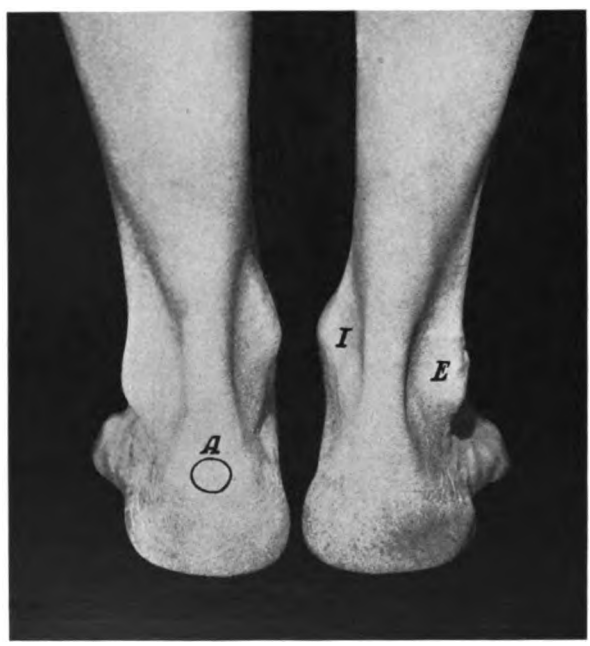

FIG. 356.—VIEW OF ANKLES FROM BEHIND.

The illustration shows the normal depressions to either side of the tendo Achillis, and between the lower border of the malleoli and the os calcis. These depressions are all partially or entirely obliterated in sprains or in fractures of the tarsal bones. (See text.) *I*, Inner malleolus; E, outer malleolus; *A*, location of bursa between the point of insertion of tendo Achillis and os calcis, referred to as a painful spot in inflammations of the bursa (achillodynia).

to. They do not differ in their constitutional signs from those following an injury of the extremities. In the latter, however, the symptoms of shock and hemorrhage often coexist, especially after severe crushing injuries, so that a differentiation is almost impossible.

The *most characteristic signs of hemorrhage* are the following:

1. Marked pallor of the skin and of the visible mucous membranes, such as the lips, gums, tongue, and conjunctivæ. The latter is best seen when the lower eyelid is everted.

2. The pulse is soft and rapid. It lacks its normal tone and the tension becomes less and less as the hemorrhage increases. If the primary loss has been very great the peripheral pulse may from the first be scarcely palpable and the heart-beats are very feeble.

3. The pupils are widely dilated and there is no response to light.

4. The mental condition varies. If the primary loss of blood has been moderate or even excessive, but there has been no further hemorrhage, the patient is apathetic, responds very slowly to external stimuli or to questions, or may even be in a deep stupor. If the hemorrhage continues this condition becomes one of deep coma, followed by convulsions and death. In some cases each fresh hemorrhage is accompanied by attacks of syncope or fainting from which the patient slowly recovers, but remains in a feeble condition.

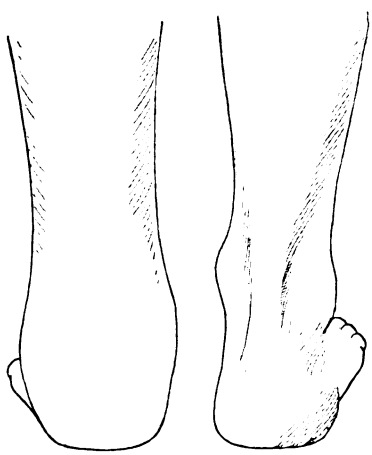

FIG. 357.

Outlines of normal ankle shown on the right, and of characteristic obliteration of depressions on either side of the tendo Achillis which occurs in severe sprains of the ankle-joint, with or without fracture of either bone of the leg, or fractures of the tarsal bone.

5. Dyspnea is a very marked symptom, especially if the loss of blood is a progressive one. This is often accompanied by great restlessness (even though the sensorium is benumbed) and by constant thirst.

6. There is usually a marked fall in blood-pressure.

The *most characteristic signs of shock* are:

1. The skin is cold, pale, and may be covered with perspiration. The temperature is subnormal. There is pallor of the skin and visible mucous membranes, but this is less marked than in cases of hemorrhage. The pallor is often accompanied by more or less cyanosis.

2. The pulse is very weak, rapid, and often irregular or intermittent.

3. The pupils are widely dilated.

4. The mental hebetude is even more marked than in hemorrhage, and it is difficult to arouse the patient. They are very apathetic and muscular relaxation is extreme. Less often there is slight delirium and great restlessness.

From the above it will be seen that the more important symptoms of shock and hemorrhage bear a great resemblance to each other. In many cases, especially of extensive wounds or crushing injuries of the

extremities, they coexist. In such cases the persistence of mental torpor, rapid weak pulse, shallow breathing—even though the source of the hemorrhage has been checked and the loss partially compensated for by transfusions, etc.—should lead one to suspect the coexistence of shock.

There are apparently two classes of cases of shock—(*a*) the erethis-

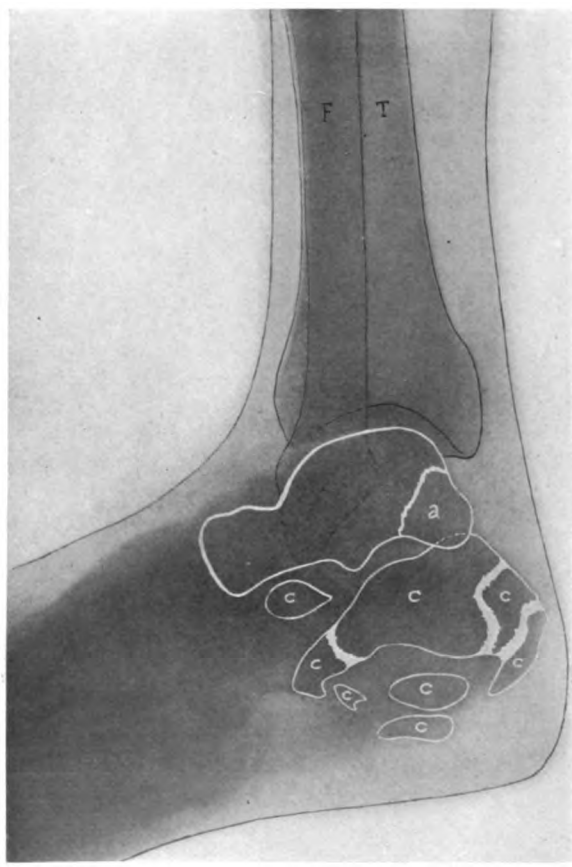

FIG. 358.—COMPRESSION FRACTURES OF THE ASTRAGALUS AND OS CALCIS, FOLLOWING A FALL OF EIGHTY FEET.

Outline of fibula; T tibia; a, posterior fragment of fractured astragalus. The various letters *c* represent the comminuted fragments of the fractured os calcis.

tic, and (*b*) the ordinary or torpid form. In the former the restlessness, pallor, etc., can scarcely be distinguished from that of hemorrhage. In the torpid or apathetic form, the mental condition is one of more marked stupor, and the muscular relaxation and weakness are more pronounced symptoms.

In some cases the symptoms of shock pass over into those of septic

infection. The pulse-tension is then increased, delirium becomes a more marked symptom, and the pulse-rate rises rapidly. The marked increase in temperature as taken per rectum and the presence of leukocytosis serve to distinguish it from shock. Fat embolism has already been referred to (page 443) as a complication of fractures, and may simulate the symptoms of shock or be obscured, at first, by those of the latter condition.

Cyanosis is a more constant symptom of fat embolism than of shock. The respiration is also stertorous and rapid, while it is shallow and slower

FIG. 359.—METHOD OF EXAMINATION FOR FRACTURE OF THE METATARSAL BONE.
The foot is grasped between the fingers of the two hands in order to determine the false point of motion and crepitus.

in shock. The diagnosis of fat embolism can be confirmed by finding free fat in the urine.

The pulmonary symptoms are usually more marked in fat embolism than in shock. They are either great dyspnea and asphyxia or those of pulmonary edema with expectoration of frothy, blood-stained mucus. In some cases cerebral symptoms predominate.

TRAUMATIC DELIRIUM AND DELIRIUM TREMENS.

In addition to the delirium often accompanying head injuries, a distinct form exists which follows both injuries and operations in those not

admitted to be alcoholics, and has been termed *traumatic delirium*. It is especially frequent after injuries of the extremities in the young and in the aged, and after extensive burns at all ages. If it exists more than a few hours after an injury, other causes should be sought for, such as great loss of blood, septic infection, suppression of urine, acetonemia, iodoform absorption, or senile atrophy of the brain in the aged. If these can be excluded, the case must be considered as one of true nervous traumatic delirium. The latter is of a low, muttering character without fever. Its etiology is not quite clear.

The recognition of delirium tremens is not difficult. It most often follows fractures. The condition rarely begins suddenly and then only after a severe loss of blood. Most frequently the onset is gradual in chronic alcoholics. The patients are at first restless, even very talkative, rarely depressed. They complain of not being able to sleep, and soon begin to show marked tremors and become delirious. There is now complete insomnia, constant low, muttering delirium, or loud outcries. Efforts are made to get out of bed, accompanied by cries and marked tremor. Hallucinations and illusions are constant, and there is incessant muscular activity accompanied by an increase in the pulse-rate, cyanosis, etc., until death ensues, unless the treatment has succeeded in controlling the disease. If high fever is present one must suspect the coexistence of septic infection or of a pneumonia, which may end by crisis.

INFECTIVE COMPLICATIONS OF WOUNDS.

The various tissues of the extremities are subject to the same varieties of infection as have been referred to in the head, neck, thorax, and abdomen. The chief differences are: (*a*) the extremities are more frequently the seat of injuries than are other portions of the body; (*b*) the anatomic conditions are such that the spread of infection is greatly favored. This is especially true of infection in the upper extremity.

Infections of the extremities have two modes of origin: (*a*) from without inward, as occurs after operations or injuries, or (*b*) the limb is the seat of a local process which results from some systematic infection. The second mode of origin is far less frequent than the first-named.

It is important to remember from a diagnostic standpoint that the clinical course of an infection varies greatly.

1. It may remain local throughout its course.

2. It may become general, as, for example, hydrophobia, glanders, anthrax, emphysematous cellulitis, malignant edema, and the more virulent forms of streptococcus and staphylococcus, or bacillus pyocyaneus

infections. In this second group the organisms may give rise to a very characteristic clinical picture, or the general infection or absorption of toxins (as the case may be) present the features of a sapremia, septicemia, or septicopyemia.

A comparatively insignificant local focus may give rise to the most grave forms of general infection, so that a thorough knowledge of the chief diagnostic features of both local and general infections is essential.

Local Infections in the Upper and Lower Extremities.—The organisms most frequently concerned in these are (*a*) the staphylococci and streptococci. Among the other rarer bacterial agents are (*b*) the bacillus pyocyaneus, streptococcus erysipelatis, bacillus of malignant edema, bacillus aërogenes capsulatus, pneumococcus, colon bacillus, gonococcus, influenza bacillus, bacillus of anthrax, and typhoid bacillus.

Of the second class just enumerated, infections with the organisms of erysipelas, malignant edema, and the bacillus aërogenes capsulatus result in such typical clinical pictures that they will be described separately. The diagnosis of whether an infection is due to the other organisms mentioned in this second group can only be made if (*a*) a primary focus exists elsewhere and (*b*) the organisms are found in the pus either by microscopic examination or by bacteriologic tests. In the case of infection with the bacillus pyocyaneus, it may be recognized by the bluish or bluish-green color of the pus and a peculiar sour odor.

Staphylococcus and streptococcus infections are greatly influenced by anatomic conditions and by their own special characteristics. In regard to the latter it may be said that, in a general way, staphylococcus infection is usually more circumscribed, does not spread as rapidly, and produces a thicker pus than is the case with the streptococcus pyogenes. The latter is, as a rule, far more virulent, extends along the surface (especially by way of the lymphatics) much more rapidly, and produces, if in pure culture, a thin turbid serum, which to the uninitiated is not recognizable as pus.

A staphylococcus infection in the extremities is much more apt to spread along tendon-sheaths and intermuscular septa than is, as a rule, the case with the streptococcus. In the upper extremity infection may occur either through a wound or through a hair-follicle. The wound may be an extensive one, or even microscopic in size.

A reference to Fig. 360 will show the chief anatomic points and modes of transmission of infection from the fingers to the forearm, etc.

The clinical forms are: (*a*) In the epidermis; (*b*) in the subcutaneous connective tissue; (*c*) along the tendon-sheaths; (*d*) around the

matrix and beneath the nail, and (*e*) between the muscles of the hand, forearm, and arm.

(*a*) *Epidermal Infection.*—This can be recognized clinically by the presence of blisters or bullæ which contain pus. If the entire epidermal covering is removed, the deeply injected upper layers of the rete malpighii are exposed.

(*b*) *Injection of the Cutaneous and Subcutaneous Tissues (Cellulitis of Finger or Hand).*—This not infrequently follows an insignificant punctured wound whose possibility of causing infection may have entirely escaped the patient's memory.

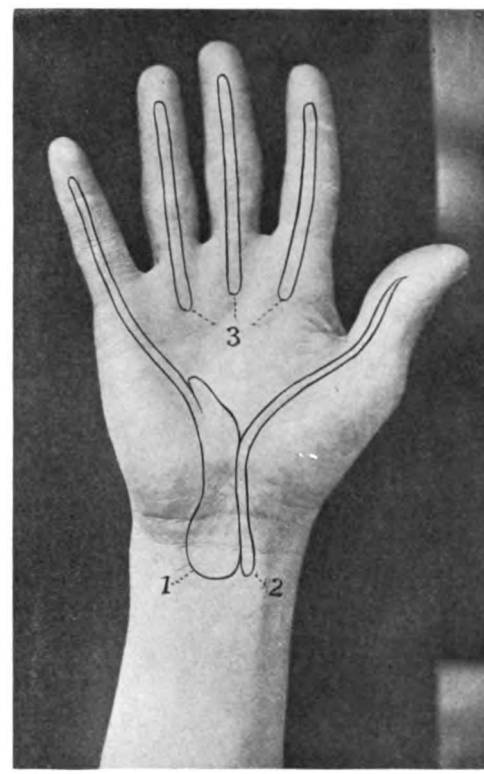

FIG. 360.—RELATIONS OF FLEXOR TENDON-SHEATHS TO HAND AND FOREARM.

1 Flexor tendon-sheath of little finger extending through annular ligament to lower third of forearm; 2, flexor tendon-sheath of thumb extending to lower third of forearm. 1 and 2 often communicate. 3, Flexor tendon-sheaths of index-, middle, and ring-fingers, terminating at middle of palm of hand, and beginning again just distal to the wrist-joint.

On account of the anatomic fact that the connective-tissue fibers on the flexor surface of the fingers run at right angles to the bone the infection is more frequently carried directly to the periosteum or the tendon-sheath than is the case on the dorsum. On the latter surface it is more likely to spread along the lymphatics in an upward direction, or remain localized in the form of a furuncle in the subcutaneous tissue. The possibility of such insignificant foci on the dorsum of the fingers or hand being the starting-point of a lymphangitis or cubital or axillary lymphadenitis must be constantly borne in mind. The case may be seen at a time when the primary focus has healed and the most prominent symptom is a suppurative cubital or axillary lymphadenitis.

If the pus is present in the subcutaneous tissue the skin of the finger, hand, or forearm is indurated, very tender to the touch, feels hot, red-

dened, and there is a constant throbbing pain. If complicated by a lymphangitis a red streak can be seen spreading over the hand and forearm to the cubital or axillary lymph-nodes.

If the infection has extended through the periosteum of the phalanges a so-called *felon* results. This can be recognized before incision by the intensity of the pain, which is far greater than in the other forms. If the felon or, as it can be more correctly termed, suppurative periostitis of a phalanx has been incised or the pus has been spontaneously evacuated a sinus lined with exuberant purulent granulations remains, which may persist for months until the sequestrum has been removed or discharged spontaneously.

If the infection is in the palm of the hand, the swelling of the dorsum is often so great that it would appear as though the infection were on this side.

(*c*) *Along the Tendon-sheaths.*—Infection, as a rule, only spreads along the flexor sheaths, on account of the anatomic fact that the latter extend almost to the end of the fingers on the palmar surface, while on the dorsum the extensor sheaths terminate at the middle of the back of the hand.

In virulent cases the infection may spread in twenty-four hours from the finger-tip to the forearm. This condition can be recognized from the fact that the entire finger is swollen on its flexor surface and the interphalangeal folds are effaced. The palm of the hand along the course of the tendon is tender and swollen and examination of the wrist will reveal an area of redness and tenderness extending to the beginning of the forearm. Such an involvement of the tendon-sheaths also causes marked swelling of the dorsum of the hand and a rise in the patient's temperature.

(*d*) *Ungual and Subungual Injection.*—The first effect of an infection is to cause pain referred to the matrix of the nail. Considerable pus may accumulate beneath the nail, so that pressure upon the nail at its matrix will show a ballottement similar to that of a patella floating on fluid in the knee. If the matrix is completely detached, it can often be separated from its bed by pushing back the fold of skin at its base. Not infrequently a sinus or ulcer will form, as is the case of a felon covered with exuberant granulations, which will persist for weeks or even months until the dead nail is removed (Fig. 361). The author has seen a number of such cases in which a diagnosis of chancre, etc., had been wrongly made.

(*e*) *Between the Muscles and Tendons of the Forearm and Arm.*—This has been correctly termed an intermuscular phlegmon. It may be due to transmission of infection from the hand or be the result of an infected wound or other focus of suppuration.

Not infrequently an infection of the subcutaneous connective tissue

FIG. 361.—ULCER OF TOE, WHICH WAS THE EXTERNAL OPENING OF A SINUS LEADING TO A DEAD NAIL, THE RESULT OF A PARONYCHIA OF A SUPPURATIVE ARTHRITIS OF THE DISTAL INTERPHALANGEAL JOINT.

coexists. Unless attention is paid to the fact that free incision of the more superficial infection produces no change in the symptoms of septic intoxication (fever, rapid pulse, etc.) the deeper phlegmon is often overlooked until too late. The latter causes considerable swelling and tenderness of the forearm and arm proper. This is most marked around the wrist- and elbow-joints.

Pain is not very marked, the most prominent symptoms being the swelling, tenderness, and persistence of fever. If there is much accompanying involvement of the cutaneous and subcutaneous tissues, the skin is of a deep red color, indurated, and the tenderness on pressure is more marked. It is often necessary to distinguish this condition (inter-

FIG. 362.—PHLEGMON OF ARM CAUSING ENORMOUS SWELLING, MOST MARKED IN CLOSE PROXIMITY TO THE ELBOW-JOINT, DUE TO THE LODGMENT OF A SEPTIC EMBOLUS, SECONDARY TO A GANGRENE OF THE LUNG.

muscular phlegmon) from erysipelas, and the same may be true in the case of extensive diffuse phlegmons in the lower extremity. In the case of erysipelas the infiltration of the skin is firmer, has a glazed appearance, and the red color is of a darker hue and is less diffuse than in phlegmon. Another point of difference is that in erysipelas the line of demarcation between infected and non-infected skin is quite sharp. The edge is often raised above the level of the surrounding skin and is irregular. In a phlegmon the edge passes imperceptibly into that of the surrounding skin and is not elevated or irregular.

Infections of the interphalangeal and metacarpo-phalangeal joints do not differ from those of joints elsewhere and will be considered in the diagnosis of purulent arthritis in general.

Infective Processes in the Lower Extremities.—Infection with the ordinary pyogenic organism is far less frequent than in the upper extremities. They may originate (*a*) from an ingrown toe-nail or an abrasion of the foot with lymphangitis extending to the inguinal lymph-nodes as a red streak; (*b*) as a complication of compound fractures; (*c*) from an inflamed varicose vein or an infected ulcer of the leg; (*d*) secondary to an osteomyelitis, usually of the tibia or femur. Of the above atria of infection, the first-named group is the most frequent. The arrangement of the tendon-sheaths of the flexor and extensor muscles of the foot and toes is such that infection rarely travels upward through these channels. Infection in the lower extremities is much more apt to be transmitted along the lymphatics and in the loose-meshed subcutaneous connective tissue than is the case in the arm. In children and young adults, the rapidity with which infection spreads is much greater than in later life.

Attention has already been called to the fact that suppuration of the cubital and axillary lymph-nodes may not occur until two to three weeks after the primary focus was noticed. The same is true of the lower extremities, especially in children. A case may present itself for diagnosis with inflamed lymph-nodes in the subinguinal region (Scarpa's triangle) in which an infected abrasion or an ingrown toe-nail was either not observed or had already healed.

Another diagnostic point not to be forgotten in connection with infection in the lower extremities is the fact that the pus may extend into the deep lymph-nodes lying within the pelvis (deep iliac group) from the external (superficial inguinal) set and cause long-continued fever and other septic phenomena before they are recognized by finding a tender mass upon deep palpation of the iliac fossæ. Infection of the prepatellar bursa and of the knee-joint occurs far more frequently as a complication of suppuration in the lower than is the case with similar bursæ and joints of the upper extremities. The diagnosis of these conditions is considered on page 566.

The diagnosis of subungual and periungual suppuration and infection of the interphalangeal and metatarso-phalangeal joints does not differ from that of the same conditions in the upper extremities. They show, in general, less of a tendency to spread. Ingrown toe-nail, which is a form of subungual infection, is readily recognized from the local pain, redness, and the exuberant granulations along the side of the nail. A dead nail, as in the fingers, may cause a long-continued ulceration of the neighboring tissue (Fig. 361).

Emphysematous Cellulitis and Malignant Edema.—These are

rare, but yet frequent enough forms of infection of bullet wounds, compound fractures, abrasions, etc., to demand attention. In the majority of text-books no distinction is made between emphysematous cellulitis produced by the bacillus aërogenes capsulatus, and the rapidly spreading gangrenous form of infection due to the bacillus of malignant edema. They both lead to gangrenous processes in an arm or leg following one of the above classes of wounds, accompanied by a hemorrhagic exudate and the development of gas in the tissues. The conditions may be recognized (*a*) by the rapidly spreading discoloration, swollen condition of the limb, and early gangrene; (*b*) by the crepitation on pressure when the limb is palpated; (*c*) from the foul-smelling hemorrhagic serum which exudes from the wound, and (*d*) from the early onset of marked septic symptoms, such as high temperature, rapid pulse, delirium, and marked leukocytosis. Death may take place within a few days unless amputation be performed. The diagnosis of which organism is concerned should be made as early as possible by making cover-slip preparations of the bloody serum, and cultures on anaërobic media. If death ensues from the immediate virulence of the infection, the case may pursue a more protracted typhoid-like course.

Erysipelas.—This form of infection, like those due to the ordinary pyogenic organisms, may be a complication of operations, of ulcerative processes, of compound fractures, or any form of injury of the extremities. It occurs less frequently here than on the face.

Erysipelas most often begins with a chill and a reddening of the edges of the wound, accompanied by a rise of temperature. Within a few hours the skin around the wound assumes its characteristic appearance, from a careful inspection of which the diagnosis can usually be made. The edges of the area of redness usually show a sharp demarcation from the normal skin. The edge is raised above the surrounding level and often shows irregular prolongations, giving it a jagged appearance. Red streaks can frequently be seen running toward the regional lymph-nodes from the area of infection. They are due to an involvement of the lymph-vessels (lymphangitis). In many cases the erysipelatous redness spreads from day to day, growing pale where the limb was first involved.

In healthy individuals the color of the area is of a deep reddish hue. In those with a tendency to venous congestion it has a bluish tint, while in anemic or cachectic persons it is of a light red shade. Over this area numerous vesicles or even bullæ are found. The swelling of the skin is usually marked, so that the infected area feels tense, glistens, and does not pit on pressure. The following may be mentioned as infrequent local complications in the severer cases: abscesses in the subcutaneous tissue,

infection of tendon-sheaths, intermuscular spaces, and joints, as well as gangrene of the skin. The latter is most apt to occur in the finger-tips.

The general symptoms of erysipelas are: (*a*) The presence of more or less fever of a continuous type. The rise of temperature is less often of a distinctly remittent type and is accompanied by repeated chills. (*b*) A rise of pulse-rate accompanies the fever. (*c*) Delirium is often present, especially in elderly persons and in those cases characterized by marked septic symptoms and high fever.

Among the complications, whose possible appearance must be constantly borne in mind during the course of the disease, are pneumonia, ulcerative endocarditis, septicemia, and less frequently pleuritis, meningitis, and nephritis.

The differentiation of erysipelas from a phlegmon is not difficult, as a rule. In erysipelas the skin is often covered with blebs, the redness is of a bright, glistening character, and the border is more or less jagged or irregular and sharply marked off from the healthy skin. In a streptococcus phlegmon, from which the differentiation must usually be made, the induration is more board-like, and the redness is of a darker hue. In addition, the skin does not glisten, seldom has blebs, and the area of redness shows no sharp line of demarcation.

Erysipeloid.—This is a form of wound infection which often occurs in cooks, butchers, and others who handle game, fish, and oysters. It is usually found on the fingers as a dark red swelling with quite a sharp border. It gradually extends from the finger upon which it happens to begin to the remaining fingers and to the hand, as in a true erysipelas. The disease lasts about three weeks and ceases spontaneously. There is but little general disturbance. Locally the patients complain of tingling and itching.

The diagnosis is usually easy from (*a*) its location on the fingers or hand; (*b*) the occupation of the patient; (*c*) the absence of fever; (*d*) the bluish redness of the eruption and its slow spreading with only a minimal amount of infiltration of the skin.

From erysipelas it can be differentiated by the absence of fever, its slow spreading, and the fact that it lacks the bright redness, tension, and glistening appearance of an erysipelatous area.

Sapremia, Septicemia, and Pyemia.—Infection of a wound either sustained through injury or subsequent to an operation; by any of the organisms just referred to, may be followed by one of three groups of symptoms. They may also follow any of the acute forms of bone infection.

Sapremia means a local infection with the development of toxins. This condition is present if fever develops after the infliction of a wound,

accompanied by other general symptoms, such as malaise, rapid pulse, restlessness, headache, and prostration. Locally one finds all of the evidences of infection described on page 531. The gravity of the initial symptoms varies according to the amount of toxins absorbed. Instead of high fever, etc., one may find rapid collapse, coma, and death, or the condition passes imperceptibly into one of septicemia or of septicopyemia. If the sapremia is of a moderate type, and due to imperfect drainage of a wound, it is often characterized by a regular evening rise of temperature and a considerable degree of leukocytosis.

The most important differential point between sapremia (septic toxemia) and septicemia (bacteriemia) is that when thorough treatment of the focus of infection has been instituted the symptoms of fever, etc., disappear in sapremia, but show no improvement in septicemia.

In sapremia the signs of local infection predominate, while in septicemia it is the general symptoms of poisoning which attract attention.

Septicemia.—In this form of infective complication of wounds there is a constant formation of toxins in the blood itself, due to the bacteriemia which exists. The eradication of the primary focus does not cause a termination of the symptoms as in sapremia. Such a step has but little influence upon the course of either septicemia or the next form to be described, septicopyemia. The chief diagnostic features of a progressive septicemia from local infection are the following:

1. *Fever.*—Usually this is of a continuous type. The occurrence of chills is not characteristic of septicemia, although it occurs at times.

2. *Pulse.*—This is at first full, somewhat increased, and shows tension. As the infection progresses, it is soft, lacks tension, becoming weaker and more rapid. The rapidity of the pulse is in general a good criterion of the severity of the infection, being 140 to 160 in the graver cases.

3. *Mental Disturbances.*—Headache and mental dullness are quite common, but not infrequently unusual clearness and activity of the mind continue throughout the greater part of the illness. If mental stupor exists, it is often accompanied by delirium, and may develop into deep coma.

4. *Alimentary Canal.*—The tongue is dry and covered with dirty brown crusts. The breath is offensive and often has a peculiar sweetish odor. There is complete anorexia, accompanied either by constipation or by diarrhea (septic enteritis).

5. *Kidneys.*—The urine is scanty, high-colored, and contains much albumin and many hyaline and granular casts.

6. *Blood.*—There is usually a moderate degree of leukocytosis (15,000 to 20,000). The organisms concerned in the process may be demon-

strated in pure culture by aspirating blood from one of the arm veins and inoculating the blood-serum, agar, and other media.

7. *Appearance of Wound.*—The wound secretions are often malodorous, thinner, and smaller in quantity. The arm or leg may show local evidences of an extensive progressing phlegmon of the most septic type.

In the most virulent forms of streptococcus malignant edema or bacillus aërogenes capsulatus infection the local signs are often the most prominent feature of the clinical picture.

Septicopyemia or Pyemia.—This condition is understood to be general infection resulting from the entrance into the circulation of septic thrombi containing the ordinary pus cocci. These infected thrombi when

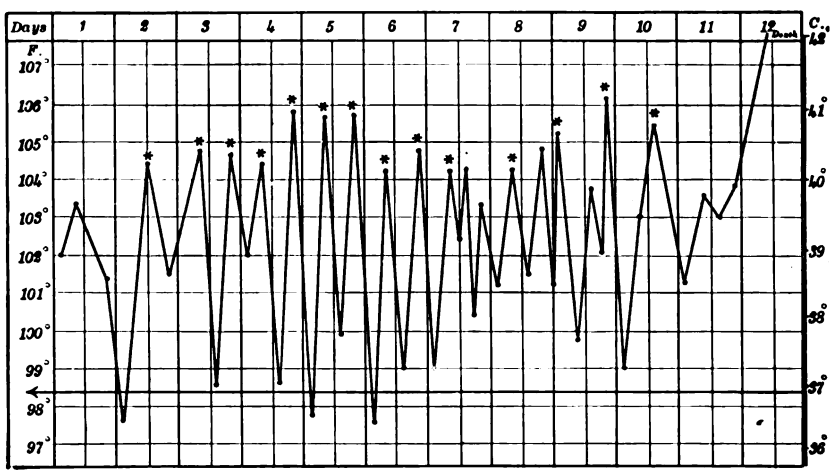

FIG. 363.—TEMPERATURE-CHART IN A CASE OF PYEMIA WITH MUSCULAR LOCALIZATIONS.

* indicates a chill. The fall of temperature was frequently due to the use of the cold pack ("International Text-book of Surgery").

carried to distant points form independent centers of suppuration. In the extremities such a pyemia or, to use a better term, septicopyemia may arise (*a*) from an infected wound of the skin or deeper structures, (*b*) from an osteomyelitis, (*c*) from a septic thrombophlebitis, *e. g.*, of a varicose vein.

The chief features of the disease as compared with septicemia are the occurrence of chills, and of an irregular, more remittent type of temperature. Accompanying these general symptoms are the local ones due to the deposit of the infected thrombi in the lungs, endocardium, liver, spleen, kidneys, skin, and bones. These symptoms may appear at any period in the course of a wound. The disease may pursue a very acute, a subacute, or a chronic course, the latter lasting for years.

The chief diagnostic features of septicopyemia are the following:

1. *Fever.*—The onset is usually with a chill, followed by a rise of temperature to 103° to 105° F. and a profuse sweat.

This triad, viz., chill, fever, and sweat, is repeated at intervals, either daily or every other day. In the intervals there may be a slight rise of temperature. In some cases chills either do not accompany every rise of temperature or are entirely absent. If the latter is the case, there is persistence of the remittent type of fever. The rise of temperature may occur at any time of day and even two or three times in twenty-four hours. It is this irregularity which serves, with the absence of plasmodia in the blood, to distinguish it from malaria.

2. *Pulse.*—If the pyemia occurs in a previously healthy individual the pulse is full and strong and rises to 120 during the fever, but may sink to normal in the interval. In the majority of cases the pulse remains high throughout the disease.

3. *Mental Condition.*—In the most acute cases a typhoid-like stupor exists, but in the subacute and chronic forms, the mind is much clearer than in septicemia. The patients are often fully conscious, anxious, and irritable. As they grow weaker, stupor and delirium set in and terminate in coma.

4. *Alimentary Canal.*—The most prominent symptoms are anorexia, nausea, vomiting, and rapid emaciation. Jaundice is a very characteristic sign of pyemia and may be accompanied by marked anemia. Diarrhea is only present in the later stages.

5. *Kidneys.*—Traces of albumin and casts are found in the urine. In general the signs of the renal disturbance are less marked than in septicemia.

6. *Evidences of Metastases.*—These are very important to recognize. They have been referred to on page 538. Pulmonary metastases reveal themselves clinically by the presence of dyspnea, cough, and blood-tinged sputum. If many abscesses exist, the physical signs of a lobular pneumonia are found, or evidences of a pleurisy. Embolic abscesses in the spleen cause localized pain and enlargement of the organ. Metastases in the liver produce, if small, local peritoneal friction sounds and tenderness. If larger, they cause increased dullness and swelling. Metastases in the skin, parotid, thyroid, testis, bones, and joints are easily recognized. A metastatic brain abscess is very rare and can only be diagnosed if it causes focal symptoms.

7. *Appearance of Wound.*—The secretion is diminished, the granulations appear pale, or flabby and necrotic.

8. *Blood.*—In pyemia there is marked leukocytosis, while in malaria and typhoid there are normal relations or leukopenia.

In the differential diagnosis of pyemia and septicemia from other affections one must remember the following:

Acute suppurative osteomyelitis.

Acute septicopyemia from gonorrhea.

Typhoid fever.

Ulcerative endocarditis.

Malaria.

Acute lymphatic leukemia.

Acute Hodgkin's disease.

Pyelitis, pyelonephritis, and perinephritic abscess.

Septic pharyngitis.

The profound anemia and the intermittent fever sometimes seen in rapidly growing carcinoma.

Tetanus.—This complication of accidental wounds occurs far less frequently at the present time than in the preantiseptic era. It most commonly follows wounds of the hands and feet, especially those in which the wound of entrance in the skin is comparatively small and closes at an early period, thus permitting the anaërobic tetanus germ to multiply in a closed cavity.

The possibility of symptoms of tetanus developing must always be borne in mind in punctured or blank cartridge wounds, in crushing injuries of the extremities, and in compound fracture, whenever there is any likelihood of street, garden, or stable dirt having been carried into the wound.

Tetanus may appear clinically in several forms, viz.: (*a*) *A very acute form*, in which the symptoms appear during the first eight days and the patients die within twenty-four to forty-eight hours after onset of the tetanus symptoms. This class embraces about 33 per cent. of the cases. (*b*) *The typical form*, in which the first symptom appears between the eighth and fifteenth days after reception of the injury. About 45 per cent. of the cases belong in this group. (*c*) *The subacute or chronic form*, in which the first sign (lockjaw) appears in the third or fourth week after the injury. This form embraces the remaining 22 per cent. of the cases.

In spite of the variation in the time of onset and intensity of the individual symptoms in these three groups there are certain constant signs from which a positive diagnosis can be made. They are:

1. A tonic spasm of the muscles of mastication, known as *trismus*, so that the patient is unable to open the mouth, a symptom so prominent that the disease is called by the laity lockjaw. This symptom is gradual in its

development. The patient is at first able to open and close the mouth, but not fully. This lack of control of the voluntary muscles, due to their spasmodic contraction, spreads to the muscles of the back of the neck, so that the neck cannot be flexed. The rigidity soon extends to the back and abdominal muscles. These become very hard from the tetanic contraction, almost board-like. The trunk becomes overextended through the spasm of the back muscles, so that the patient's weight rests upon the head and heels, a position called opisthotonos. When the spasm affects the muscles of the tongue, pharynx, larynx, and those of respiration, the speech becomes indistinct, there is marked dyspnea, and asphyxia may occur from spasm of the glottis.

2. The second symptom of tetanus, viz., increased reflex irritability and convulsions of a tonic and clonic character, appears soon after the trismus in those cases in which death does not occur, as in acute tetanus, in twenty-four to forty-eight hours after onset of the first symptom. These spasms vary in duration, and affect all of the rigidly contracted muscles. Every irritation, such as a draft or touching the patient, excites a convulsion.

3. The temperature is high, as a rule, but there may be little or no elevation. There is a special class of cases, called *head or cephalic tetanus*, which follow wounds of the head, especially those around the eye or of the cranial nerves. The most prominent symptoms of this form are the appearance of spasms of the muscles of deglutition, and a paralysis of the facial muscles on the side of the injury, in addition to trismus or lockjaw. To this form of tetanus the name of *tetanus hydrophobicus* still clings, on account of its resemblance to true hydrophobia.

Differential Diagnosis of Tetanus.—(*a*) In strychnin poisoning the rigidity does not persist in the intervals between convulsions, and the jaw muscles are not the first ones affected, as is almost invariably the case in tetanus. The muscles of mastication may not be involved at all in strychnin poisoning. (*b*) In tetany the hands are held in a peculiar position, the wrists being flexed and the fingers extended at the interphalangeal, but flexed at the metacarpo-phalangeal joints. The tonic spasms occur at regular intervals, involve the extremities chiefly, and there are no general convulsions. Tapping upon the facial muscles or pressure upon the bend of the elbow or at the back of the knee will often cause the spasm to appear. (*c*) In so-called symptomatic lockjaw or trismus, there is inability to open the mouth, due to reflex contraction of the masseter muscles. There is no history of a wound, no general rigidity, or spasms, or rise of temperature. An examination of the mouth will soon enable a correct diagnosis to be made. This reflex trismus is

often due to a stomatitis, either due to neglect of cleanliness, to the use of mercury, or to the irritation due to the eruption of a wisdom-tooth.

Hydrophobia.—This disease occurs rarely as a complication of wounds of the face and extremities, but its early recognition is important. The proportion of persons in whom the disease develops is greater after bites from wolves (40 per cent.) than from dogs (5 to 15 per cent.). The average period of incubation is four to six weeks, rarely less (thirteen to eighteen days). A period of three to six, or even from six to twelve months is rare. As in the case of tetanus there are no changes in the wound which indicate a possible development of the disease. The wound appears red and swollen, and if it has healed may reopen and secrete a thin turbid pus. Whenever possible after a person has been bitten, the animal should not be killed, but kept under observation for the purpose of noting the development of the symptoms of the disease.

In man the diagnosis is usually not made until the appearance of great irritability, accompanied by a spasm of the muscles of the larynx and those of deglutition. When the patient is given some water to drink, the spasmodic painful contractions of these muscles cause it to be expelled, so that the very sight of water becomes repulsive.

The diagnosis can be made from: (*a*) The history of the bite of an animal, even though it occurred weeks to months prior to the onset of the symptoms. (*b*) A period of mental depression, followed by one of great mental irritability and anxiety. (*c*) The onset of the typical spasm of the muscles of deglutition whenever water is seen or an attempt made to swallow it. The patient can still swallow solids at first, but not liquids. (*d*) There is increased reflex excitability, not only of the sense of sight for water, but also of other special senses, like those of smell, taste, etc., and of the sexual organs. Exhaustion from insomnia, with rapid increase in the pulse and respiration, gradually appears and is followed by death. The only condition which needs to be mentioned in the differential diagnosis is that of the so-called *cephalic or tetanus hydrophobicus* described on page 540, especially when it follows a dog bite. In this, there is the history of a wound of the head or involving one of the cranial nerves, accompanied by paralysis of the facial muscles and trismus. In both this condition and true hydrophobia there is spasm of the muscles of deglutition, so that in some cases the diagnosis depends on the trismus in tetanus. In rare cases the spasms of the muscles of swallowing may be absent and yet the case be one of true hydrophobia.

Symptoms of difficulty in swallowing may appear in hysterical persons some weeks after being bitten by a dog. The clinical picture may at first resemble that of the genuine disease, but careful observation and

a search for other stigmata of hysteria will soon clear up the diagnosis.

Anthrax.—This complication of wounds has been referred to on page 530. It may follow wounds of the face, hands, or arms. In addition to this *external or cutaneous*, there are two other rarer clinical forms, the *alimentary* and *pulmonary*. These latter are fully described in the text-books on internal medicine. The *cutaneous form* appears either as a pustule or as a rapidly spreading edema. The period of incubation varies from two to fourteen days, and upon inquiry one can usually obtain the history of a wound received while handling wool, sheepskins, infected meat, or manure.

In man the diagnosis of anthrax can usually be made from the rapid change in the appearance of the wound. The site of inoculation begins to swell and itch as it does after an insect-bite. A blister appears at the apex of the papule and the area of induration around the wound of inoculation rapidly increases in extent, is of a bluish-red color, and becomes covered with vesicles. At the center of the area of infiltration a black, gangrenous slough appears, and this rapidly increases in size. The infection soon extends into the adjacent lymph-vessels and regional lymph-nodes. Lymph-vessel involvement causes red streaks of lymphangitis to appear, and lymph-node infection is followed by pain and swelling of the regional nodes.

Accompanying these local changes there is high fever, severe headache, delirium, rapid weak pulse, and other septic symptoms, such as diarrhea. Death may occur quite early. The process may remain a local one, and instead of a central slough with a rapidly spreading area of induration, covered with vesicles, one may simply find (*a*) a few vesicles with moderate inflammatory induration, or (*b*) a small gangrenous center, or (*c*) a peculiar edema, the so-called *anthrax edema*. In the latter the swelling spreads very rapidly, especially where the connective-tissue fibers are loosely arranged under the skin. The edematous area is of a dark bluish color, and may be followed by extensive gangrene.

The diagnosis can usually be made in all of the above forms by the rapidity of the induration and sloughing, the occupation of the patient, and finding the bacilli either in cover-slip preparation or by culture tests.

Glanders.—This disease may appear in such an atypical manner and so unexpectedly that a short description of its principal diagnostic features is necessary.

If the disease is inoculated through a cutaneous wound in man, the wound soon ulcerates, and there is early swelling and tenderness of the adjacent lymph-nodes. The local ulceration spreads and greatly

resembles a soft chancre. Soon after this, red papules (farcy buds) appear in various parts of the body, and soon form abscesses with resultant ulcers in the skin or deeper tissues. Accompanying these signs of a pyemia there is a thin mucopurulent discharge from the nose. Symptoms of septicopyemia appear in the majority of cases, followed by death. Less often the clinical picture is that of articular rheumatism or typhoid fever. In the chronic form the same symptoms, viz., widely scattered areas of induration and abscess formation, appear, accompanied by milder septic symptoms. The diagnosis can only be made by considering the occupation of the patient and finding the characteristic glanders bacillus in the nasal discharge or in the pus.

SURGICAL DISEASES OF THE EXTREMITIES.

AFFECTIONS OF THE SKIN AND SUBCUTANEOUS TISSUES.

Ulcers.—Ulcers are more frequently found on the lower than the upper extremities. In the diagnosis of what the cause and nature of an ulcer might be, the following must be considered:

(*a*) A careful previous history should be taken to ascertain the circumstances attending the first appearance of the ulcer, whether it followed trauma or pressure, or whether it appeared spontaneously. The duration of the ulcer and its lack of tendency to heal, or its steady growth in size, are data of considerable value. The history will also throw light on any constitutional disease, such as syphilis, tuberculosis, diabetes, or spinal-cord affections.

(*b*) The examination of the edges of the ulcer as to the degree of induration; and whether these edges are steep or undermined.

(*c*) The form of the ulcer, whether irregular, serpiginous, or reniform.

(*d*) The floor of the ulcer, as to the degree of sloughing, and the nature of the granulations covering it.

(*e*) The examination of the limb for varicose veins, for eczema, for evidences of arteriosclerosis, for syphilitic periostitis, etc.

The chief varieties of ulceration which occur on the skin of the extremities, and their clinical characteristics are:

1. *Traumatic Ulcers.*—These occur in persons with a lowered degree of resistance, or in limbs in which considerable venous stasis exists. In such individuals a wound may heal so slowly that epidermization is retarded, the edges become indurated and the granulation tissue flabby. In such persons the diagnosis is not difficult if there is a distinct history of an injury with loss of skin, or after a burn or freezing of the parts. The ulcers present no characteristic appearances, and in the absence

of a history, a diagnosis as to the cause is impossible. In some cases the ulceration may spread and encircle the limb. In these a condition of elephantiasis often accompanies the ulcer, forming a vicious circle in thus increasing the venous congestion which prevents the healing of the ulcer.

2. *Varicose Ulcers.*—These are usually situated on the front of the lower third of the leg, but may be located over the malleoli. They are irregular in form, the edges are rarely sharply cut, *i. e.*, steep, and the floor may present a condition varying from a dirty sloughing appearance to a healthy, red, granulating surface.

FIG. 364.—VARICOSE ULCER OF LEG. (See text.)

The skin around the edges is usually of a bluish-red color, and indurated. It may show evidences of extensive brownish pigmentation and chronic eczema.

The diagnosis can be made from the presence of accompanying varicose veins, in the area of distribution of either the internal or external saphenous veins, or of both. Various complications may call for recognition, such as acute inflammation of the skin around the ulcer, thrombosis of the varicose veins (see page 563) leading to it, or an erysipelas starting from the edge of the ulcer. Carcinomatous changes may also occur, and can be recognized by the rapid spread of the ulcerated area, the marked induration and elevation of its edges, and the enlargement of the regional lymph-nodes (Fig. 132).

In some cases varicose ulcers, like the more chronic variety of traumatic ulcer, may completely encircle the limb, and be associated with elephantiasis of the entire leg from the knee to the foot.

3. *Syphilitic Ulcers.*—If the characteristics of these are borne in mind, there is usually no difficulty in their diagnosis. Their outline is, as a rule, more regular than is the case with varicose ulcers. They are

either round or serpiginous or kidney-shaped. Their edges are usually so sharp and steep that they look as though they had been punched out with a die. The floor is covered with sloughing fetid granulation tissue and the ulceration usually extends quite deeply into the tissues.

The absence of a history of trauma and of varicose veins will often enable a differentiation from these two varieties of ulcerations to be made. There are many cases, however, in which the syphilitic ulcer appeared after an injury or is accompanied by varicose veins. In such cases the diagnosis can only be made if (*a*) there is a clear history of syphilis; (*b*) the outline and edges are as just described, and (*c*) the ulcer shows marked improvement after the use of the iodids. The latter test is, unfortunately, not an absolutely infallible one, since many varicose and other slowly healing ulcers are greatly improved through the stimulating influence of this drug.

FIG. 365.—PERFORATING ULCER OF THE FOOT IN A TABETIC SUBJECT (Matas).

4. *Trophic Ulcers.*—These are the result of some disease of the peripheral or central nervous system. They usually occur on the sole of the foot (especially in tabetic patients), over the head of the first metatarsal bone. Rarely they are found upon the hand. They present a round, punched-out appearance, and involve the deeper structures of the foot, including the bones. In every such case an examination of the central nervous system should be made for evidence of disease of the spinal cord, such as tabes or syringomyelia. The condition has also been called mal perforans pedis. It may be simulated by an ulceration due to necrosis of skin over an infected bursa in the same location developing beneath a callus, with suppuration and ulceration of the overlying skin.

5. *Blastomycotic Ulcers.*—These may occur either on the upper or

lower extremities, but more often on the latter (Fig. 366). Their presence must be suspected if (*a*) all of the forms of ulcer just

FIG. 366.—BLASTOMYCOTIC ULCERATIONS ON DORSAL SURFACE OF LOWER THIRD OF LEG.
Note the peculiar warty or papillomatous elevations characteristic of this variety of ulcer, and the raised edges, showing multiple areas of softening or miliary abscesses in which the organisms are most frequently found.

described have been excluded, and (*b*) from the appearance, viz., a peculiar warty or papillomatous surface, especially around the edges; (*c*) from the history of contact with horse manure, etc., and (*d*) from finding the characteristic yeast organisms (Fig. 367) in the secretion or in the miliary abscesses of the edge.

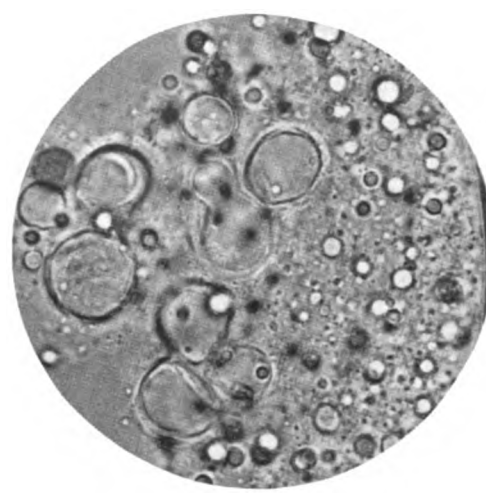

FIG. 367.—MICROPHOTOGRAPH SHOWING BLASTOMYCOTIC ORGANISMS IN SPUTUM FROM PATIENT SHOWN IN FIG. 366 (× 1200.)

6. *Tuberculous Ulcers.*—These are quite rare on the skin of the extremities except when associated with a similar affection of the deeper structures. They can be recognized by the characteristic thin bluish edges, by the undermined condition of the latter, by the caseous degeneration of many of the granulations covering its surface, and the presence of enlarged regional lymph-nodes.

In some cases of infection with virus from cattle, etc., the process may begin as an ulcer on the fingers and spread along the lymph-vessels to the groin or axilla, causing multiple ulcerations with undermined, thin, bluish edges and cheesy surface (Fig. 368).

In some forms of cutaneous tuberculosis the ulceration is not marked, but instead of it one finds a condition similar to that mentioned in the blastomycotic ulcers, viz., papillomatous excrescences. The latter, however, are higher and more apt to be undermined in tuberculosis. This is the form commonly known as the verrucous or warty variety of cutaneous tuberculosis.

7. *Decubitus Ulcers.*—These may be recognized from their appearance at places which are subjected to pressure, such as the heel, the

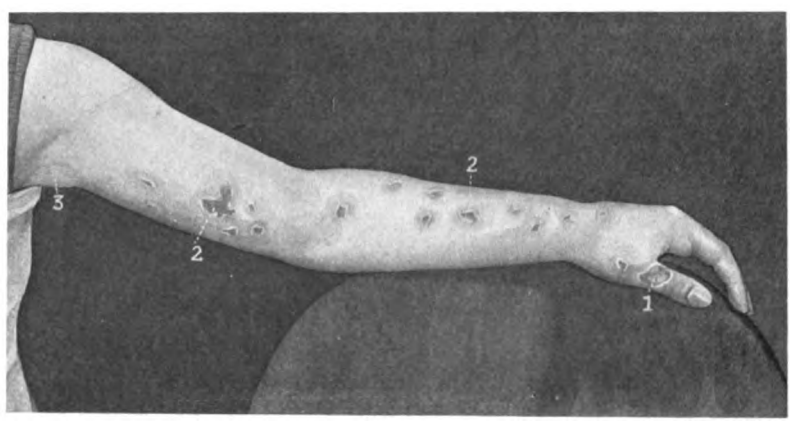

FIG. 368.—TUBERCULOSIS OF THE SKIN OF THE LEFT UPPER EXTREMITY.

1, Indicates primary focus or atrium of infection from a tuberculous steer; 2, both of the figures 2 are placed upon several of the many secondary tuberculous foci along the course of the lymph-vessels; 3, tuberculous axillary glands.

extensor surfaces of the toes, the malleoli, amputation stumps, great trochanter, and tuberosity of the ischium. The cause should always be searched for, viz., a tight or ill-fitting shoe, disease of the spinal cord or peripheral nerves, or cachexia, due to various constitutional causes, such as diabetes, arteriosclerosis, anemia, etc.

Gangrene.—Gangrene occurs far more frequently in the lower than in the upper extremities. In the diagnosis of gangrene one must consider not only the clinical phenomena, but also the etiology of the process. The mode of onset of gangrene varies somewhat, according to the cause. In the forms known as senile and pre-senile gangrene, the actual necrosis is preceded by more or less severe pain for a considerable period before any discoloration, etc., of the limb takes place. In the gangrene due to

FIG. 370.—SENILE GANGRENE.
Note sharp line of demarcation.

Raynaud's disease the process is also preceded for a long time by a bluish tinge of the fingers or toes, which may or may not be followed by actual gangrene.

Gangrene may involve one or more toes or fingers, or an entire limb. It may at other times appear simply as single or multiple patches. In the majority of forms of gangrene the direct cause is a cutting-off of the blood-supply. The result is the same, whether the anemia be due to an obstruction to the flow of arterial blood or some infective or other process which prevents the return of the venous blood of the limb. In a relatively small proportion of cases the gangrene is due to infection with the organisms described on pages 534 and 535, viz., the bacillus of malignant edema or bacillus aërogenes capsulatus of Welch.

If the dead tissue remains dry, we speak of a *dry gangrene or mum-*

FIG. 369.—BED-SORES IN A CASE OF FRACTURE OF THE SPINE ("International Text-Book of Surgery").

mification. If it becomes moist, the process is termed *moist gangrene* or sphacelus. In both forms putrefaction may occur, so that there is a marked fetid odor with toxemia from absorption of septic products. Clinically, it is useless to retain the terms dry and moist gangrene, since one may pass into the other and the same cause may at one time produce one form and at another time the other variety, the difference in this mode of action being more one of infection with putrefactive organisms.

The diagnosis of the presence of gangrene itself usually presents no difficulties. The part may become, either gradually or suddenly, cold and bluish. Pressure with the finger over the discolored area shows a very slow return of color. This bluish discoloration is gradually replaced by a black or green hue. These changes in color may be limited

to the area originally involved, or the process gradually spreads. In every form, except those due to infection of wounds with gangrene-producing organisms (malignant edema and bacillus aërogenes capsulatus), a line of demarcation forms, separating the dead from the living tissues. Accompanying the above local changes one finds in some of the forms, especially in those due to obstruction or injury of the artery of the limb, an absence of pulsation at the points where it is normally to be felt.

FIG. 372.—SOLES OF FEET IN RAYNAUD'S DISEASE.
The bluish-black discoloration of beginning gangrene is more marked upon the right than upon the left foot.

The constitutional disturbances vary greatly. In some they are very marked, while in others they are slight.

They are usually due to septic intoxication or to septicemia, and have been fully described on pages 537 and 538.

After a diagnosis of the existence of gangrene has been made, the next question is to determine its cause. By a process of exclusion one must rule out one after the other of the following forms, viz.: (*a*) Senile and pre-senile; (*b*) diabetic; (*c*) injury to arteries and veins; (*d*) freezing; (*e*) embolic; (*f*) following one of the infectious diseases; (*g*) symmetrical or Raynaud's disease; (*h*) so-called idiopathic multiple; (*i*) ergotism; (*j*) carbolic acid.

FIG. 373.—SIDE VIEW OF FEET OF PATIENT SUFFERING FROM RAYNAUD'S DISEASE.
The bluish-black discoloration is far more advanced upon the right than upon the left foot.

The principal diagnostic points of these different forms are as follows:

FIG. 371.—GANGRENE OF THE TOES AS THE RESULT OF ADVANCED RAYNAUD'S DISEASE.

Note the cyanotic hue of the distal portion of the dorsum of the foot and of the remaining toes. The gangrene is far advanced on the fourth toe and just beginning on the third.

(*a*) *Senile Gangrene.*—This may occur after a slight injury, and is often preceded by severe pains in the limb, or a feeling of numbness. In other cases there are no premonitory signs, and the first warning is the appearance of a gangrenous spot on one toe or on the dorsum. Senile gangrene is invariably a disease of the lower extremities, and seldom extends higher than the middle of the leg. The absence of pulsation in the dorsalis pedis, posterior tibial, popliteal, and femoral arteries is a prominent symptom. It may involve one or both limbs (Fig. 370).

Pre-senile Gangrene.—This occurs in middle-aged or even young persons. All writers agree that the cause is an arteriosclerosis with occlusion of the vessel, as in the true senile form. The predisposing causes are tobacco, alcohol, syphilis, trauma, and diabetes. The gangrene is often preceded by a group of symptoms termed *intermittent claudication*, first described by Charcot, in 1859. The patients complain of stiffness and pain in the calf of the leg on walking, so that they limp. The foot and leg show extreme pallor on walking. In some cases an ulcer may appear on the toes, which gradually increases in size, and is very painful. There is no pulsation in the arteries at an early stage.

FIG. 374.—ENORMOUS ELEPHANTIASIS OF BOTH LOWER EXTREMITIES.

(*b*) *Diabetic Gangrene.*—There are two distinct forms, the inflammatory and non-inflammatory, as is the case in senile gangrene. In the inflammatory there is considerable edema, tenderness, and febrile reaction, with gradual spreading of the gangrene. In the non-inflammatory form the process is slower and there is a mummification. Both varieties of diabetic gangrene are due, not to the diabetes itself, but, in the majority of cases, to the coexisting arteriosclerosis. The

diagnosis, therefore, of this form can only be made by examining the urine for the presence of sugar.

(*c*) *Gangrene from Injury to the Arteries or Veins of a Limb.*—Attention has been called to this form of gangrene on page 430. The diagnosis of this form can be made if the changes in the color of a limb, accompanied by absence of pulsation in its palpable arteries, follow within a few hours to several days after an injury. It is especially frequent after supracondyloid fractures of the femur, or separation of the lower epiphysis, and also after severe crushing injuries of the upper or lower extremities.

FIG. 375.—GENERAL KELOIDAL DISEASE IN A NEGRO, WITH MOLLUSCUM FIBROSUM (Matas).

(*d*) *Gangrene from Frost-bites.*—This cause can be readily recognized from the history, although the possibility of this variety occurring in a person suffering from arteriosclerosis or diabetes must not be forgotten.

(*e*) *Embolic Gangrene.*—This form is due to the blocking of the lumen of one of the larger arteries, such as the brachial, femoral, or popliteal. It occurs in elderly persons as the result of an endocarditis. The gangrene of the limb occurs far more rapidly than in the senile form, and can only be distinguished from it by the sudden onset and the presence of evidences of valvular disease.

(*f*) *Gangrene in the Course of the Infectious Diseases.*—It is most often due to an infective process in the artery with or without accompanying venous thrombosis. It occurs in typhoid, typhus, puerperal infection, measles, scarlatina, pneumonia, malaria, and acute articular

rheumatism. Of all of these, those complicating typhoid constitute the majority (forty-four of sixty-eight cases, collected by Barraud[1]). The clinical signs are the same as those of other forms of gangrene. The diagnosis can be made from the gangrene, absence of pulsation, and the history of the preceding disease.

(*g*) *Gangrene due to Raynaud's Disease.*—This form can be recognized from the history of a bluish discoloration of the fingers or toes, or both, accompanied by severe pain existing, in some cases, for years before the onset of the gangrene. The latter is characterized by its symmetrical distribution (Fig. 371), and the bluish or asphyctic hue is often very marked in the adjacent skin or toes. The disease may not be confined to the extremities, but involve symmetrical areas on the trunk.

FIG. 376.—ANTERIOR VIEW OF SAME PATIENT SHOWN IN FIG. 377.

Note the many pedunculated fibromata.

FIG. 377.—POSTERIOR VIEW OF MARKED CASE OF MULTIPLE FIBROMA MOLLUSCUM.

Of the other forms of gangrene, the diagnosis of those due to carbolic acid or ergotism can only be made from the history of the use of these drugs. That due to ergotism is very rare, and the form resulting from the application of even weak solutions of carbolic acid is infrequent, since the latter is seldom used as a wet dressing at the present time.

The diagnosis of idiopathic multiple gangrene should only be made

[1] "Deutsche Zeitschrift f. Chirurgie," vol. lxxiv.

if all of the above-named causes have been carefully excluded. Many case of gangrene without any obvious cause have been reported in young or middle-aged persons.

Surgical Diseases of the Skin.

Elephantiasis.—This chronic diffuse hypertrophy of the skin has already been referred to as a complication of extensive ulcers of the leg, especially those of the traumatic variety. It causes enormous enlargement of the foot and leg, or of the entire limb. At times both lower extremities are involved (Fig. 374).

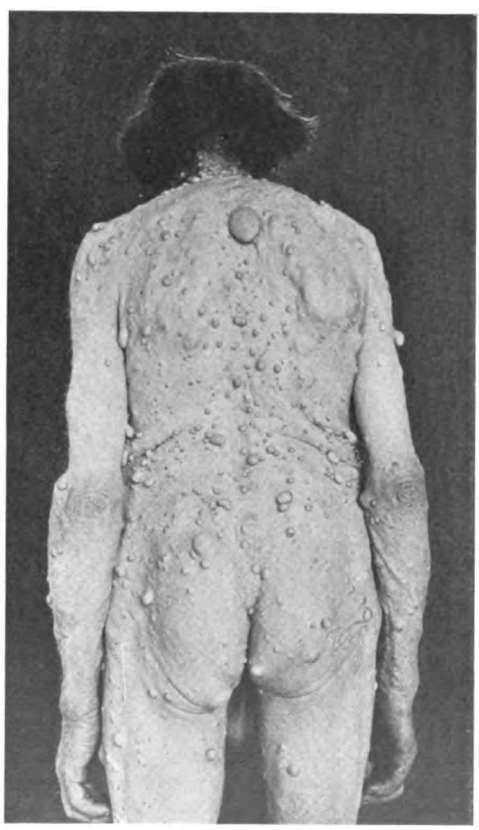

Fig. 378.—Posterior View of a Case of Diffuse Multiple Cutaneous Fibromata. (See text.)

The limb is enormously swollen, is very firm, of a grayish color, and covered, especially around the ankle and upon the foot, by innumerable pigmented papillary excrescences. In places deep furrows are seen interrupting the swelling. It is a disease due to pathologic changes in the lymph-vessels of the skin, consisting of great thickening of their walls and cystic dilatation of the vessels themselves.

It is of interest, from a diagnostic point of view, to search for the cause. In some cases seen in tropical climates it is due to the filaria sanguinis hominis, which obstructs the lymph-vessels. In our own northern climate the disease may be due (*a*) to interference with return circulation through ulcers which almost encircle the limb; (*b*) to chronic inflammatory processes, such as eczema.

In persons suffering from this condition there are attacks of acute

inflammation of the area from time to time, similar to those already referred to in lymphangiomata (see page 134). The limb becomes reddened, very tender, and feels hot. The swelling is increased, and these symptoms are accompanied by a rise in temperature. Such attacks last from a few days to weeks, and then the symptoms disappear.

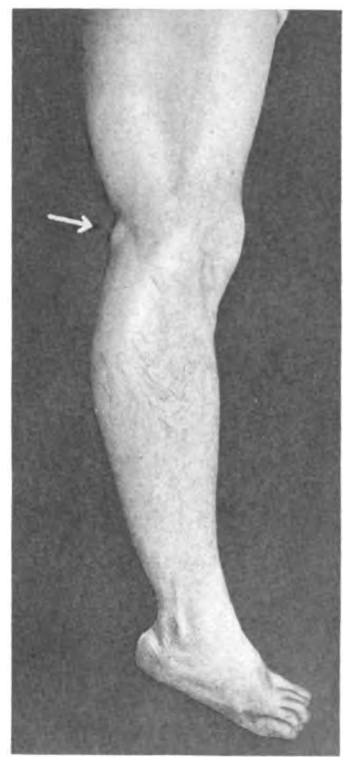

FIG. 379.—SEBACEOUS CYST IN POPLITEAL SPACE, RESEMBLING SEMI-MEMBRANOSUS BURSA.

Keloid.—This is a peculiar tumor-like formation of the skin, which either develops in the scar of some wound or arises spontaneously. In the former case it is most apt to occur in those having a history of tuberculosis, as well as in the negro race. They may be limited to a scar, or may grow quite diffusely. The spontaneous form is rare, and does not appear on the extremities. Its favorite locations are over the sternum and front of the shoulders (Fig. 374). In both the traumatic and spontaneous varieties the appearance and slow growth are the same.

It feels firmer than the surrounding skin, above whose level it rises slightly. It is of a dull reddish color, and extends over the entire length of the scar, even involving the cicatrices following the suture openings in the skin.

Tumors of the Skin and Subcutaneous Tissue.—The diagnosis of tumors of the skin does not differ from that of similar conditions elsewhere.

The various forms of tumors which occur in the skin of the extremities are:

BENIGN.

1. Hemangioma (capillary and venous).
2. Lymphangioma.
3. Fibroma (soft and hard).
4. Lipoma.
5. Benign epithelial wart (papilloma).
6. Moles (congenital and acquired).
7. Sebaceous and dermoid cysts.
8. Adenoma of sebaceous or sweat glands.

MALIGNANT.

1. Sarcoma:
   - (*a*) Spindle- and round-celled.
   - (*b*) Hemangiosarcoma.
   - (*c*) Lymphangiosarcoma.
   - (*d*) Mycosis fungoides.
2. Carcinoma:
   - (*a*) Malignant warts.
   - (*b*) Rodent ulcers.
   - (*c*) Epithelioma proper.
   - (*d*) Adenocarcinoma arising in the sweat and sebaceous glands.

In attempting to make a diagnosis, the following points must be considered: (*a*) The question of whether the tumor has grown slowly or rapidly; (*b*) the period when first noticed, whether at birth, before middle age, or after the latter period; (*c*) the clinical appearances; (*d*) evidences of metastases, and, lastly, (*e*) the results of the microscopic examination.

Of the above tumors, the majority of those in the benign group require no special description here.

Hemangioma and *lymphangioma* are most often found in children, and may involve an entire limb, especially the upper. The soft fibroma is usually a part of a generalized condition (see Fig. 376). The hard variety must be distinguished from keloids. It is smooth and hard, and may become pedunculated, and appears independently of scars.

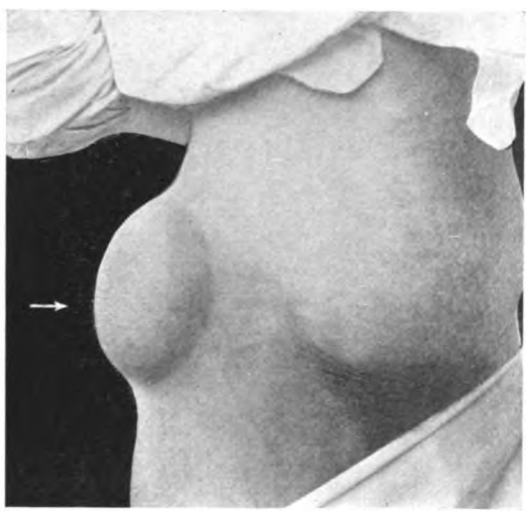

Fig. 380.—Cavernous Hemangioma of Outer Aspect of Right Gluteal Region.

Adenoma of the sweat and sebaceous glands is found chiefly in the axilla as a hard, round nodule, lying just beneath the skin.

Sebaceous and *dermoid cysts* are quite rare in the extremities, but the former may be encountered in unexpected locations (see Fig. 379). They lie just beneath the skin, which is freely movable over them unless they have become adherent to it.

In addition to the ordinary *papillary wart* found especially often on the hands and feet, a fibropapillary hypertrophy may occur, which at first may resemble an epithelioma, but is softer and slower in growth. The appearance of *moles* does not differ from that of the same growths elsewhere. They may show a tendency to become malignant by ulceration, especially in later life, and more often in those having a smooth than a warty surface.

Malignant Tumors.—Of these, the spindle- and round-celled *sarcomata* rarely arise from the connective tissue of old scars. More frequently

they have their origin in the fasciæ between the skin and muscles. They grow very rapidly, as a rule, especially the round-celled variety, and lift up the overlying skin.

The *hemangiosarcomata* belong to the peritheliomata, and represent a malignant change in a previously existing hemangioma. Often the case is seen when a history of such a preceding angioma cannot be obtained, and the diagnosis of its nature is impossible without microscopic examination.

The *lymphangiosarcomata* represent a malignant change either in a preëxisting lymphangioma or in a congenital mole.

The *malignant tumors of the epithelial type* are not difficult to diagnose. They all show an indurated base and adhesions to the underlying structures. The *ordinary type of epithelioma* most frequently develops in old ulcers, resulting from varicose veins, or in those due to former trauma or to burns. Such a malignant change can be recognized by the steady growth of the ulcer, and the marked induration of its base and edges (Fig. 383). An epithelioma may rarely occur as a primary tumor in the skin without previous ulceration (Figs. 132 and 133).

FIG. 381.—SARCOMA OF DORSUM OF FOOT.
The black area at its upper level was an area of ulceration covered with granulation tissue.

Rodent ulcers rarely develop in the skin of the extremities. They grow very slowly, and do not produce metastases in the regional lymph-nodes, as do the other forms of superficial carcinomata. *Adenocarcinomata of the sweat or sebaceous glands* are both very rare tumors in the extremities, and would be most likely to occur in the axilla or groin.

DISEASES OF THE ARTERIES.

The most frequent surgical diseases of the arteries are inflammations of the vessel wall (arteritis) and aneurysms.

An arteritis is always secondary to some infective focus elsewhere.

If a septic embolus lodges in an artery it causes a suppurative inflammation of the wall of the vessel and the formation of an abscess around the artery. In the case shown in Fig. 362 such an infection followed suddenly, after a gangrene of the lung, the embolus lodging in the brachial artery. A diagnosis can only be made from the existence of a septic focus elsewhere followed by the sudden appearance of evidences of infection around an artery of the extremities.

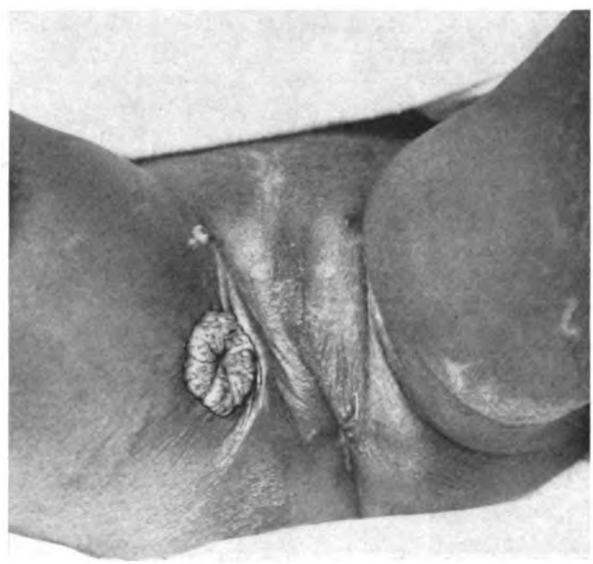

FIG. 382.—EPITHELIOMA OF INNER ASPECT OF RIGHT THIGH IN A WOMAN OF FIFTY-FIVE.

ANEURYSMS.

Cirsoid Aneurysms.—In connection with diseases of the scalp it was stated that the majority of cirsoid aneurysms occur in the frontal and temporal arteries. They have also been observed in the hands and fingers, being more common in women than in men in the proportion of ten female to six male in the sixteen cases collected by Wagner.[1] The diagnosis presents no difficulty. The tumor is soft, compressible, and pulsates, and one can feel distinctly the outline of the vessels composing it. On auscultation one hears a soft-blowing intermittent murmur. Its differentiation from an angioma of the venous type and from an arteriovenous aneurysm has been discussed on page 433.

[1] Beiträge zur klinischen Chirurgie, vol. xi, p. 49.

Non-traumatic Aneurysms of the Larger Vessels of the Extremities.—The fact that an aneurysm may follow a blow upon an artery or a penetrating wound with rupture of its coats has already been referred to. True aneurysms not infrequently occur in the larger arteries of the upper and lower extremities, whose origin is due to atheromatous degeneration of the vessel wall. In such patients the history of a preceding syphilis, of abuse of alcohol, of gout, or diabetes is usually to be obtained.

FIG. 383.—POPLITEAL ANEURYSM.

The arrow points to the prominence over the middle of the popliteal space due to the aneurysmal sac. Note the dilated and varicose condition of the superficial veins on the outer aspect of the same limb.

There is no longer any question that trauma plays a certain rôle in these cases, since they most often occur in men who are obliged to do hard work. Under these conditions degenerated arteries are more likely to rupture and form an aneurysm.

Of a total of five hundred and ninety-one aneurysms collected by Crisp, three hundred and eight were found in the arteries of the extremities. These involved the popliteal artery in one hundred and thirty-seven cases and the femoral in sixty-six, so that it may be said that aneurysms affect these two vessels more frequently than any of the others of the extremities. The axillary (sixteen cases) and brachial (one case) and the smaller vessels of the forearm and leg are rarely affected. The diagnosis of a non-traumatic aneurysm does not differ from that of the non-traumatic already given except in these two points: (*a*) There is usually no history of a single injury, although there may be that of repeated ones, and (*b*) the swelling itself is more apt to be circumscribed. The tumor is usually to be outlined distinctly; it is ovoid, round, or spindle-shaped. Its characteristic signs are: (*a*) A pulsation which is expansile in character and can be best felt by grasping the

tumor between the thumb and index-finger (see Fig. 386). This pulsation is synchronous with that of the pulse at the wrist or some other superficial artery. (*b*) A distinct blowing murmur is to be heard with the stethoscope which is also synchronous with the pulse. The tumor itself can be felt in the majority of cases to be directly connected with the artery involved and a peculiar thrill is felt with every pulsation. Pressure upon the vessel on the proximal side of the aneurysm causes both the pulsation and murmur to be diminished or even disappear.

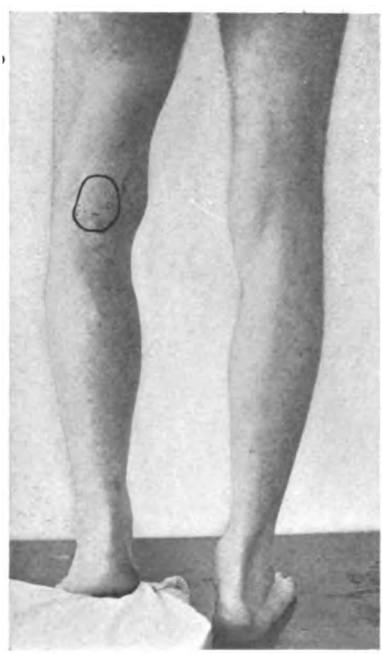

FIG. 384.—POSTERIOR VIEW OF A CASE OF NON-TRAUMATIC POPLITEAL ANEURYSM, SHOWING LOCATION (BLACK CIRCLE) OF PROMINENCE AT BACK OF KNEE.

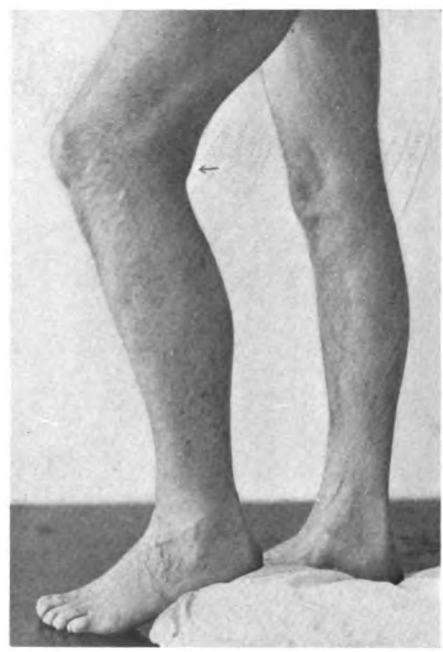

FIG. 385.—LATERAL VIEW OF NON-TRAUMATIC POPLITEAL ANEURYSM.

The black arrow points to the prominence at the back of the left knee. Same case shown in Fig. 384.

An aneurysm must be differentiated from pulsating neoplasms, especially osteosarcomata. The latter grow more rapidly and feel harder than an aneurysm, and the pulsation is more diffuse, and not expansile, but has a more lifting character.

Aneurysms of the femoral artery must be differentiated from a femoral hernia or a psoas abscess by the absence, in both of the latter, of expansile pulsation and a murmur and the fact that the tumor can usually be reduced. In the case of a psoas abscess the swelling shows more distinct fluctuation, and there are evidences of spinal disease.

If an aneurysm begins to show evidences of infection with involvement of the surrounding tissues the diagnosis becomes very difficult. There is high fever present, the swelling does not pulsate, and there are all the local evidences of a phlegmon. In a case occurring in the service of one of my colleagues an aneurysm of the femoral artery ruptured spontaneously and the patient succumbed to the hemorrhage, some hours after incision was made in the infected area, upon a diagnosis of a phlegmon. In case of doubt it is always best to observe the case a few days before making a diagnosis.

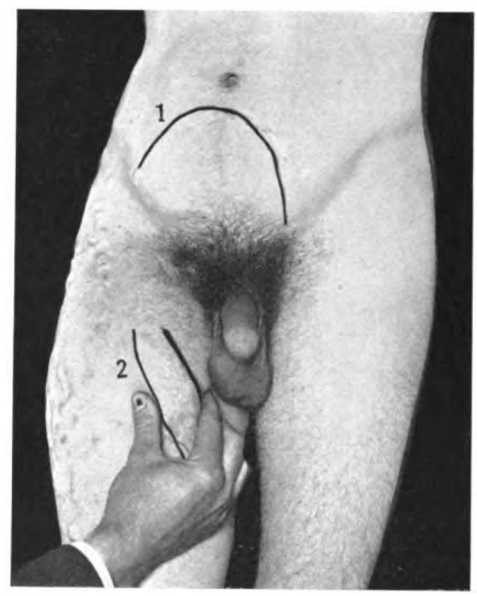

FIG. 386.—ANTERIOR VIEW OF EXTERNAL ILIAC (1) AND FEMORAL (2) ANEURYSMS, SHOWING METHOD OF PALPATION OF AN ANEURYSMAL SAC FOR EXPANSILE PULSATION.

DISEASES OF THE VEINS.

Phlebitis and Thrombosis.—Inflammation of a vein involves all of the coats of the vessels and often the tissues immediately surrounding it. The disease occurs in an acute and subacute form. The acute form can be recognized by the presence of marked redness of the skin over the vein, great tenderness on pressure, and swelling of the soft tissues around the vein. The outline of the vein itself can be felt as an extremely tender cord, especially if a superficial vein like the internal saphenous is involved. Accompanying these local phenomena there is high fever, prostration, and rapid pulse. If septic emboli become detached and float into the circulation, a pyemia results. Such virulent cases fortunately are rare. In the majority of cases of phlebitis the disease runs a subacute or chronic course. The chief diagnostic points are (*a*) the presence of pain and tenderness along the course of the vein; (*b*) edema of the limb below the point of thrombosis, if the thrombosis involves the deeper veins; (*c*) if the vein is a superficial one it can be felt as a tender firm cord. If the condition occurs as a complication of varicose veins, the latter become very tender and hard, the thrombi occupying every portion of the varicosities. The skin over them is red

and exceedingly sensitive to the touch. Such a subacute phlebitis is apt to follow (*a*) an infection of the soft parts of an extremity; (*b*) any one of the acute general infections, such as typhoid, pneumonia, rheumatism, or (*c*) occur in alcholism, or (*d*) as a phlegmasia alba dolens in puerperal infection.

Even though the inflammatory symptoms disappear, the edema of the extremity may persist for months to years.

FIG. 387.—VARICOSE VEINS ("International Text-Book of Surgery").

A not infrequent complication of a thrombophlebitis of the deeper veins of the lower extremity is the appearance of ulcers (page 545) which are very obstinate to treatment.

Thrombophlebitis may occur after operations and show no clinical signs except a slight local tenderness. Even the latter may be absent, and the first symptom may be the onset of symptoms of pulmonary embolism described as a post-operative complication on page 702.

Varicose Veins.—This condition is almost exclusively confined to the lower extremities, although it also occurs in the veins of the spermatic plexus as a varicocele. It affects chiefly the internal, less often the external, saphenous vein.

In the majority of cases, varicose veins cause no symptoms until complications appear. In a small percentage of cases attention is first called to their presence by the occurrence of pain referred along the line of the vein. If uncomplicated, the varicose veins can be felt as soft tortuous cords. The skin over them is stretched so that the bluish color of the vessel shows through. At times, the most prominent mass is found over the internal condyle of the femur. The individual dilatations may be so large as to simulate cystic tumors or other conditions. The tumor-like form is especially seen near the saphenous opening in Scarpa's triangle. The soft dilatation of a varicosity may resemble a femoral hernia (see page 415) or a psoas abscess. One of the best methods

of determining the extent of the varicosities is to compress the main trunk of the internal saphenous vein at the middle of the thigh. The *chief complications* of varicose veins are (1) ulceration; (2) subacute phlebitis, with the formation of thrombi and phleboliths; (3) hemorrhage from rupture of a varicosity; (4) chronic eczema and pigmentation of the limb, with the development of an elephantiasis. *Varicosities of*

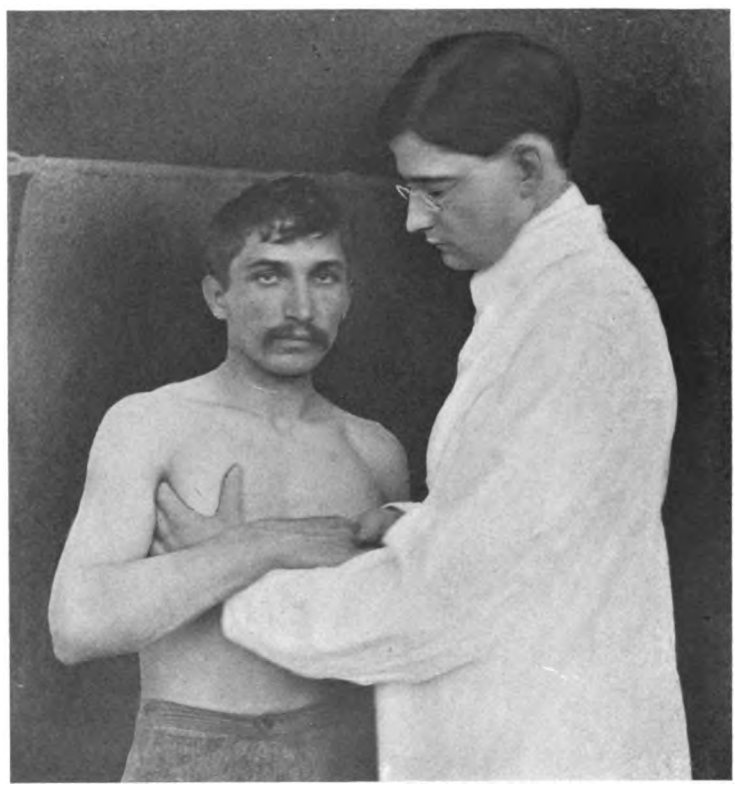

FIG. 388.—METHOD OF PALPATING THE AXILLARY LYMPH-NODES.

The same method may be used in both sexes. The patient's arm is laid upon the examining arm of the surgeon, after the fingers of the latter have been passed along the thoracic wall to the apex of the axilla. In this manner the axillary fascia is relaxed and the examining fingers can be inserted much higher than by any other method.

the deeper veins can be recognized (*a*) by the presence of edema around the ankle without other ascertainable cause; (*b*) the dilatation of the finer veins of the dorsum of the foot.

DISEASES OF THE LYMPH-VESSELS.

Acute lymphangitis has been referred to in connection with infection of the extremities. Its presence can be recognized by the occurrence of a

red streak in the skin, leading from the seat of infection to the axilla or groin, as the case may be. The inflamed lymph-vessel can also be palpated as a firm, tender cord, lying just beneath the skin. Abscesses may form in the course of the vessel opposite its valves.

Chronic lymphangitis occurs in the extremities chiefly in a tuberculous form (Fig. 368). The atrium of infection may be on the hand or

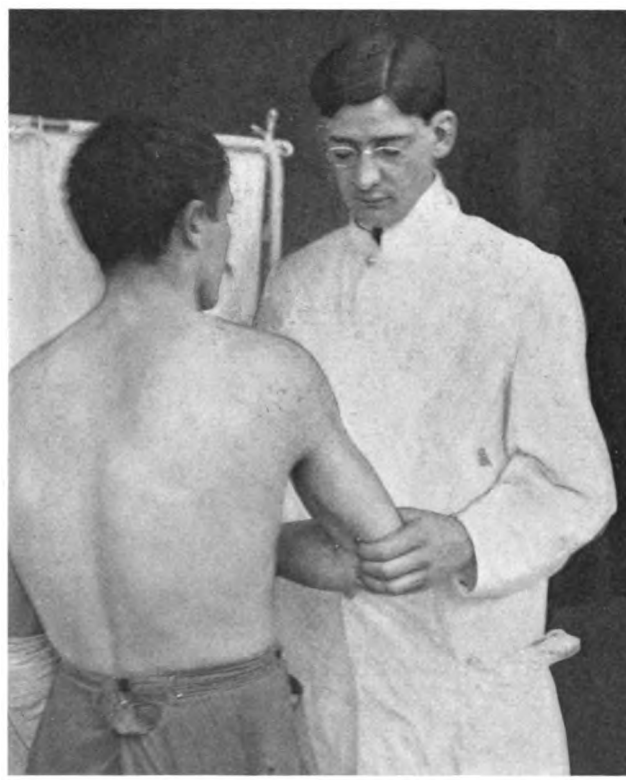

FIG. 389.—METHOD OF PALPATING THE CUBITAL LYMPH-NODES.

The examiner should stand in front of and to the right or left of the patient, according to the side to be examined, and grasp the elbow in such a manner that the tips of the fingers rest upon the humerus just above the internal condyle. The nodes are to be felt between the inner edge of the biceps and the space just above the internal condyle of the humerus.

foot. The lymph-vessel itself feels hard and nodular, and may break down opposite the valves into multiple foci of suppuration with the formation of typical tuberculous ulcers. Such an infection may come from bovine tuberculosis, as in the case shown in Fig. 368.

Lymph Cysts.—These are quite rare, arising as the result of the obstruction of a lymph-vessel through trauma and occurring most frequently in the thigh as large cystic tumors whose origin is usually not recognized

until operated upon. They present themselves as cystic tumors in the groin or thigh which must be differentiated from a hydrocele of the canal of Nuck, from lipoma, from blood-cysts, and from tuberculous abscesses.

DISEASES OF THE LYMPH-NODES.

This subject has been fully discussed in the chapter on the neck. The lymph-nodes of the extremities, which are most frequently involved, are the cubital, axillary, and inguinal. The diagnosis of an *acute inflammation* presents no difficulties. The nodes can be felt as round

FIG. 390.—METHOD OF PALPATING INGUINAL LYMPH-NODES.

The examining hand is placed flat upon the anterior aspect of the thigh, the finger-tips resting on Poupart's ligament, or rather the skin overlying it, and the nodes thus palpated by a rolling motion of the finger-tips.

tender tumors, which later become matted together and show evidences of suppuration, such as superficial redness and fluctuation. It is of great importance to remember that the primary focus of infection may have healed and perhaps have been forgotten, when the patient presents himself with all of the evidences of acute inflammation of the cubital, axillary, and inguinal nodes. This clinical fact is especially to be found in children. Suppuration of the inguinal nodes most frequently follows gonorrhea or soft chancroids.

Chronic Inflammation of the Lymph-nodes.—As was found to be the case in the neck, the percentage of tuberculous involvement is far greater than that from any other cause. Tuberculosis of the inguinal nodes is quite rare, while that of the axillary nodes is a frequent complication of the same affection of the neck.

When enlarged nodes are found in the axilla, the groin, or the cubital region, one must exclude one by one the following forms of enlargement of the lymph-nodes, by the diagnostic landmarks mentioned on pages 169 to 172: (*a*) Tuberculosis; (*b*) syphilis; (*c*) simple chronic hyperplasia as the result of long-continued irritation; (*d*) lymphosarcoma; (*e*) lymphatic leukemia; (*f*) Hodgkin's disease; (*g*) secondary carcinomatous enlargement. In connection with the last named it is important to call attention to the fact that quite malignant tumors of the breast cause early enlargement of the axillary nodes. Carcinoma of the prostate or of the lowermost portions of the rectum and vagina may cause enlargement of the inguinal nodes at an early date. If one find enlarged and hard inguinal nodes in an elderly person a search for such a primary cancer should always be made.

DISEASES OF THE BURSÆ.

In order to be able to make a diagnosis one must recall the location of the more important bursæ. These are (*a*) the subdeltoid, lying beneath the deltoid muscle; (*b*) the olecranon; (*c*) the metacarpo-phalangeal; (*d*) the ischial, over the tuberosity of the ischium; (*e*) the trochanteric, over the greater trochanter; (*f*) the prepatellar; (*g*) one between the tendo Achillis and the os calcis; (*h*) the ileopsoas bursa; (*i*) one over the head of the metatarsal bone of the great toe; (*j*) the semimembranous bursa (Fig. 265).

Acute bursitis as the result of trauma has already been referred to. A similar condition may follow infection of the neighboring or even distant parts. Such an acute inflammation has been repeatedly observed in gonorrhea, involving most frequently the achillean and prepatellar bursæ. Acute bursitis, whatever the cause may be, can be recognized when a tender swelling appears at a point corresponding to one of the above normal bursal locations. The skin over the inflamed bursa may be red and infiltrated. The direct relation of the subdeltoid and ileopsoas bursæ to the shoulder- and hip-joints respectively is of great surgical importance in acute inflammations of these bursæ, owing to the frequency of secondary joint involvement.

Chronic Bursitis.—In these there is a painless tumor, often as large

as a hen's egg, showing distinct fluctuation corresponding to the various normal positions of the bursæ. The majority of these tumors are the result of chronic irritation, with resultant catarrhal inflammation of the serous lining of the bursa and the production of a variable quantity of fluid. The latter often contains many small rice bodies. The diagnosis presents no difficulty unless suppuration has occurred and a sinus formed. The condition under these circumstances greatly resembles that of a sinus leading to an old focus of osteomyelitis. A chronic enlargement of the olecranon bursa has been given the name "miner's elbow," while that of the prepatellar bursa is called "housemaid's knee," although both often occur independently of these occupations.

Tuberculous and syphilitic bursitis occur less frequently than the ordinary catarrhal variety. A diagnosis of a tuberculous bursitis can only be made before operation, if a swelling which shows distinct crepitation (from the presence of many rice bodies) appears over one of the usual bursal locations. Syphilis causes a gummatous infiltration of the wall, giving rise to a thick indurated mass at the location of a bursa.

DISEASES OF THE TENDONS AND TENDON-SHEATHS.

Inflammatory Affections.

These almost invariably involve both the tendon itself and the tendon-sheath. The condition may be either primary or secondary. It may also be acute or chronic.

Acute Primary Tenovaginitis or Tenosynovitis.—(*a*) *Tenovaginitis Crepitans.*—This occurs only in the extensor sheaths of the thumb after excessive use or exposure to cold. It may be recognized by the occurrence of sharp pain upon extension of the thumb, accompanied by distinct crepitus. The latter is best felt when the fingers are placed along the course of the tendon as far as the middle third of the forearm, while the thumb is alternately extended and flexed. After a few days the pain and crepitus disappear, and the patient may have an oblong swelling extending from the back of the thumb, obliquely across the back of the lower third of the forearm. This swelling shows distinct evidences of fluctuation and is the result of accumulation of fluid within the sheath.

(*b*) An *acute primary serofibrinous tenosynovitis* occurs in the flexor sheaths of the fingers, and can be recognized from the location of the pain and the fullness over the normal depressions at the folds of the fingers. The latter are held rigid, and only the terminal phalanx can be flexed. This form is a not infrequent sequel of fractures or other conditions in which the fingers are kept immobilized.

(*c*) *Acute Primary Seropurulent Tenosynovitis.*—This also affects the flexor sheaths of the fingers. It shows the same local signs as the preceding form, but there is higher fever and more pain.

Acute Secondary Tenovaginitis or Tenosynovitis.—The acute secondary forms are due either to (*a*) infection from neighboring tissues extending through the sheath; (*b*) to gonorrheal metastasis, or (*c*) occur as a complication of syphilis during the period of the first skin eruption. Suppurative tenosynovitis, which is secondary to infection of the surrounding tissues, as in infected fingers, or occurs after penetrating wounds of the sheaths, has been previously referred to. The diagnosis of the acute gonorrheal and syphilitic varieties can be made as in the other forms by the occurrence of pain and swelling along the course of tendon-sheaths, accompanied by loss of function. In addition to these two signs there is usually more or less redness of the overlying skin.

All of the above-described forms, with the exception of the acute crepitating, affect the extensor and flexor sheaths of the hand and fingers, as well as those around the ankle (peronei, extensors, tibialis anticus and posticus). Involvement of the sheaths of the biceps brachii and of the flexors of the knee occurs less frequently. In the gonorrheal form the condition usually occurs when the urethritis has existed for some time.

Chronic Tenosynovitis.—(*a*) *Chronic Serous Tenosynovitis.*—This may be a sequela of the acute crepitating form, or it may follow excessive use of the hands or feet. In the case of the fingers, it occurs in painters, engravers, artists, etc. The diagnosis can be made from the swelling corresponding accurately either to the extensor (Figs. 391 and 392) or flexor sheaths. The sheath (*a*) may contain simply serum and the serous lining show but little change, or (*b*) it may contain many rice-like bodies (corpora oryzidæ) with marked papillomatous excrescences in the sheath wall.

(*b*) *Tuberculous Tenosynovitis.*—This form of chronic inflammation of the tendon-sheaths most frequently affects the flexors of the hand, less often the sheaths around the ankle. There are several clinical forms whose recognition is important. The first variety is one in which there is a well-marked oblong swelling, corresponding in outline to the tendon-sheaths, over which there is distinct fluctuation, and containing many rice bodies. These rice bodies can often be distinctly felt and pushed through constrictions in the sac. Perforation may occur with discharge of caseous material. In the second variety the tendon-sheath is greatly thickened, so that more or less solid tumors are formed

corresponding in outline to the sheaths. In both of these tuberculous forms the diagnosis is not difficult if there are evidences of tuberculosis

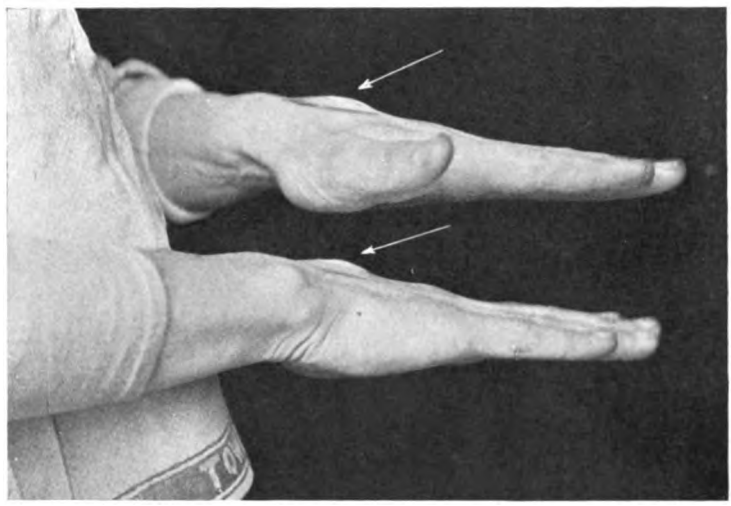

FIG. 391.—LATERAL VIEW OF CASE OF TENOSYNOVITIS OF EXTENSOR TENDON-SHEATHS ON DORSUM OF HAND.

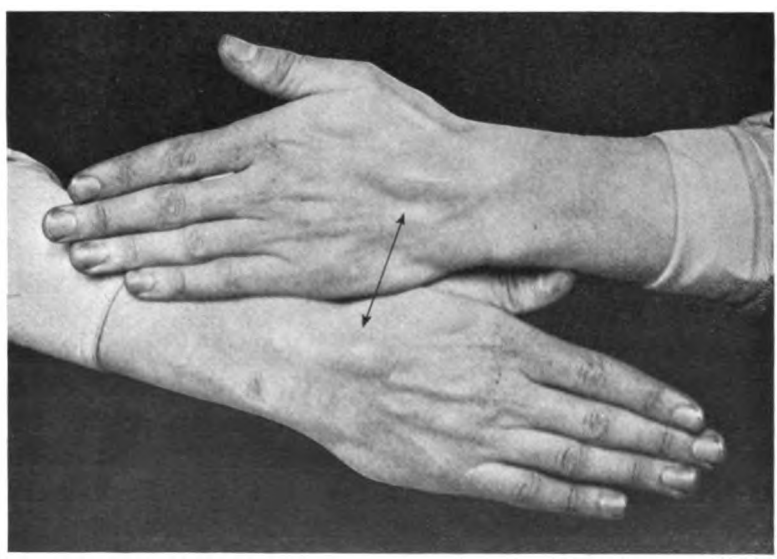

FIG. 392.—DIRECT VIEW OF SAME CASE AS SHOWN IN FIG. 391, SHOWING THE SWELLING IN THE MIDDLE OF THE DORSUM OF THE HAND DUE TO TENOSYNOVITIS OF THE EXTENSOR TENDON-SHEATHS OF THE FINGERS.

elsewhere. But if such a history is absent, suspicion should be aroused by the chronicity of the process and the clinical signs of one of these two forms.

(*c*) *Chronic Syphilitic Tenosynovitis.*—The acute form has been referred to above. Both the acute and chronic varieties are more frequently found in women and affect the extensors of the fingers and toes, the biceps, and peroneus sheaths. In the chronic form there may occur a simple exudation into the sheath, or a gummatous nodulated infiltration of the same. The diagnosis is very difficult unless there is a distinct history of syphilis and the condition clears up after the use of antisyphilitic treatment.

Tumors of Tendons and Tendon-sheaths.—Lipoma arborescens and sarcoma constitute practically the only forms of neoplasms. The former occurs in a symmetrical manner in the flexor sheaths of the hand, forming a soft semifluctuating tumor which can scarcely be distinguished from tuberculous inflammation. The most common forms of malignant tumors are the fibrosarcomata. They are observed both in young and old people. Their growth is slow and usually painless. They are hard and are situated on the flexor side.

FIG. 393.—GANGLION ON THE BACK OF THE WRIST ("International Text-Book of Surgery").

Ganglion.—It seems appropriate to refer here to a tumor which is usually found upon the dorsum of the wrist.

A second typical location is upon the flexor surface of the wrist or fingers. The tumors vary in size from a cherry to that of a walnut. If they lie deeply they are quite hard, but if they are superficial, they fluctuate. A diagnosis is not difficult on account of their consistency and location. They can best be seen when the wrist is fully extended or flexed, according to which side of the wrist they are located upon. Many communicate with the wrist-joint and are a form of hernia of the joint. According to Ledderhose and Ritschl, others are simply the result of a colloid degeneration of connective tissue.

DISEASES OF MUSCLES.

INFLAMMATORY AFFECTIONS.

1. **Acute Muscular Rheumatism** (*Acute Serous Myositis*).—This is only mentioned in a surgical book to call attention to the

fact that it may occur suddenly after muscular exertion and simulate a more serious condition. In addition to the severe pain, there is rigidity of the limb or joint which is moved by the affected muscle, as well as well-marked local tenderness. The affection yields rapidly to antirheumatic treatment.

2. **Acute Suppurative Myositis.**—This is almost invariably secondary to a neighboring focus of suppuration, but may occur quite rarely, as a primary form. In the latter there are manifest local disturbances, such as marked swelling and pain over the affected muscle, followed by edema and induration of the overlying skin with subsequent fluctuation.

3. **Simple Chronic or Fibrous Myositis** (*Sclerosing Myositis*).—This may follow (*a*) an attack of rheumatic myositis; (*b*) trichinosis; (*c*) thrombosis of the vessels of an extremity, or (*d*) the long-continued or too tight application of bandages, casts, etc.

In all of these there is overgrowth of the interstitial tissue with atrophy of muscle fibers. The muscle itself feels hard and atrophic. Contractures and loss of function usually result. After fractures, especially where the splints have been employed for a long period or the dressing was applied too tightly, this form is especially common. The condition is called *ischemic muscular contracture or paralysis*.

4. **Myositis Ossificans.**—This occurs most often in a localized form, but may rarely be quite generalized.

The formation of bone in the intermuscular tissue may occur as the result of either a single or frequently repeated trauma. The most frequent location is in the adductors of the thigh, as the so-called rider's bone, or in the deltoid and pectoralis major muscles. As a more general disease it occurs either without apparent cause or after an injury. The idiopathic form affects chiefly the muscles of the back and spine. This ossification may follow a complex of symptoms, such as high fever, swelling, and pain in the muscle. These recur from time to time, and after the attack has passed away, hard nodules are to be felt in the muscle. Every muscle in the body may be involved, with the exception of those of the face. Only forty cases of this generalized form have thus far been reported. The diagnosis is confirmed by the use of the *x*-ray.

5. **Tuberculous myositis** is usually secondary to bone or lymph-node foci in the vicinity or may occur after an injury, if there are foci elsewhere. Quite rarely multiple tuberculous abscesses are found in a muscle without any neighboring focus.

6. **Syphilitic Myositis.**—This occurs either (*a*) as an infiltrating

myositis which begins as a muscular rheumatism and causes the muscle to become rigid and nodular, or (*b*) as a gumma close to the tendon or in the belly of the muscle, affecting most often the sternocleidomastoid and the muscles of mastication. They form hard nodules which are usually painless. They may attain the size of an apple. At times they undergo softening and discharge, their contents leaving an ulcer with serpentine outline and steep edges. The diagnosis is not difficult if there is a distinct history of syphilis, either congenital or acquired. They must only be differentiated from echinococcus, since few other tumors occur in a muscle. The nodules disappear rapidly after the use of antisyphilitic treatment.

FIG. 394.—FASCIAL SARCOMA OF CALF OF LEG.
The arrow points to the prominence caused by the soft semifluctuant sarcoma.

TUMORS OF MUSCLES.

Primary tumors are rare. These are usually *hemangiomata, lymphangiomata,* or *sarcomata. Desmoids* occurring in the muscles of the abdominal wall were previously described (page 234). Angiomata are of slow formation, extending over a period of years. In rare cases they grow within a few months. They feel like a lipoma and are not always compressible. They occur most frequently in young persons.

Sarcoma may arise in muscle as a primary tumor. It causes rapid enlargement of the part, feels quite firm, and is painless (see Fig. 394).

Hydatid Cysts in Muscles.—These occur quite often in muscles

(about two per cent. of all cases). They can be differentiated from gummata by their more elastic consistency. The diagnosis of a hydatid cyst is seldom made before operation.

DISEASES OF THE FASCIÆ.

Dupuytren's Contraction.—In both young and old persons a contraction of the palmar fascia occurs, causing a flexion of one or more fingers. It usually affects the ring- and little fingers, but may involve the index- and middle fingers. In the palm of the hand, one can see and feel one or more firm bands to which the skin is adherent. The skin is also thrown into transverse folds and depressions. The flexion of the fingers may be very slight, or it may be so marked that the tip of the finger almost touches the palm of the hand (Fig. 260). The position of the hand has been likened to that in which it is held during benediction. The clinical picture is so typical that the diagnosis is easy. The only differentiation is from contraction of the fingers following opening of the tendon-sheath, as a result of injury (Fig. 260), or intentionally during the treatment of a suppurative tenosynovitis. Under these latter conditions one feels a single longitudinal band or cord, and the skin of the palm is only adherent to it. There is absence of the transverse folds and depressions, as well as of the nodules seen in a Dupuytren's contraction.

DISEASES OF THE NERVES.

Neuritis.—From a surgical standpoint great interest is attached to this condition of inflammation of a nerve-trunk. Its local causes are:

1. Pressure of a tumor or aneurysm upon the nerve, either close to its point of exit from the spinal canal or somewhere along its course.

2. The nerve may be involved by extension from a neighboring septic focus.

3. As a complication of nerve injury. Neuritis is much more apt to develop after an incomplete division of a nerve (by a knife, glass, or a bullet) than after a complete severing of its continuity.

4. As a complication of fractures or dislocations. In the former the nerve may be caught between the fragments or be pressed upon by the callus. In an unreduced dislocation the displaced head of the bone may compress the contiguous nerve-trunks.

5. Neuritis may follow temporary pressure upon or contusion of a nerve without any external signs of injury. The neuritis following too light an application of a constrictor is an example of this form.

Neuritis may present itself clinically in either an acute or a chronic form, or the latter may develop from the former. The diagnosis of the presence of a neuritis may be made from the following signs:

(*a*) Pain. This is of a boring character and continuous, not intermittent as in a neuralgia. The pain is felt along the course of the nerve and is increased by pressure upon the nerve or by movements of the limb.

(*b*) Sensory changes. At first all forms of paresthesia are complained of, viz., numbness, burning, coldness, etc. There is weakness or paresis of the muscles supplied by the affected nerve.

(*c*) Trophic changes. There is early wasting or atrophy of the muscles involved. The skin becomes glazed, the nails rough and curved, and the limb feels colder and looks bluish. Bullæ and ulcers may appear on the skin.

(*d*) Electrical changes. If the nerve has not been completely divided the reaction of degeneration is present three to four weeks after the injury. If the nerve has been totally destroyed by the injury or compression there is absence of all kinds of electrical responses.

(*e*) The muscle reflexes are lost and there are secondary contractures due to the action of the antagonistic muscles. If the nerve degeneration becomes complete there is complete anesthesia in the area of skin supplied by it and also total paralysis of the affected muscles. This condition is, however, infrequent, except after complete division of a nerve. The fact that the neighboring nerves may assume some of the cutaneous sensory distribution must not be forgotten.

A neuritis can be distingushed from a neuralgia by the facts that in the latter (*a*) the pain is intermittent and not continuous as in a neuritis. (*b*) There is an absence of pain along the nerve-trunk and of tenderness over the paretic muscles. (*c*) In neuralgia there is no paresis or paralysis of muscles, nor loss of muscle reflexes. (*d*) There are also non-trophic or sensory disturbances and no changes in the electrical responses.

Tumors of the Nerves.—Clinically, there are three forms of nerve tumors: (*a*) Traumatic neuromata; (*b*) neuroma dolorosa, or painful subcutaneous tubercle; (*c*) multiple neuromata.

Traumatic neuromata develop from the cut ends of a divided nerve. They form an extremely sensitive palpable nodule on the end of the nerve in an amputation stump, or wherever the nerve chances to have been severed.

Neuromata dolorosa, also called painful subcutaneous tubercles, are easily felt just beneath the skin, and cause pain and tingling in the area of cutaneous distribution of the nerve.

Multiple Neuromata.—These have also been termed plexiform neuromata and are often congenital. They seldom cause symptoms and are only to be diagnosed by the often visible, but more frequently palpable, series of nodules along the nerve-trunks. They are found clinically in three forms: (*a*) As bead-like enlargements at regular intervals along a single or several nerve-trunks; (*b*) only on a single nerve, when the symptoms of neuritis may be present and must be differentiated from those due to pressure from other causes; (*c*) invading nearly every nerve in the body.

DISEASES OF THE BONES.

For diagnostic purposes affections of the bones are best divided into the acute and the chronic. The majority of both of these clinical groups are due to infective microörganisms. A small percentage of the chronic forms are the result of disturbances in metabolism.

The following will be found to be a very useful classification:

I. *Acute Diseases of Bone.*

1. Those involving the periosteum chiefly.
   - (*a*) Acute traumatic periostitis.
   - (*b*) Acute infective periostitis—usually secondary to acute infective osteomyelitis, but the periosteum alone may be involved in some cases.
   - (*c*) Acute syphilitic periostitis. Painful nodes in early portion of secondary stage (see page 589).
   - (*d*) Chronic syphilitic or tubercular periostitis—usually secondary to same disease of medulla, but may be confined to the periosteum in late secondary or early tertiary syphilis (see page 589).
2. Those involving the medulla primarily.
   - (*a*) Acute infective or suppurative osteomyelitis.
   - (*b*) As a complication of compound fractures, of amputations, or of operations on bones.
   - (*c*) As a primary disease, *i. e.*, the ordinary type of acute infective or suppurative osteomyelitis. Most frequently due to the staphylococcus pyogenes aureus and albus, and, rarely to the streptococcus pyogenes, pneumococcus, and typhoid bacillus.

II. *Chronic diseases of bone, i. e.*, those which are primarily chronic.

1. Those due to infective agents.
   - (*a*) Due to the tubercle bacillus; most frequent seat is in epiphysis or in shaft close to epiphyseal cartilage in

long pipe bones. Frequent in shaft of metacarpals, metatarsals, phalanges, tarsal and carpal bones.

(*b*) Syphilitic periostitis and osteomyelitis.

2. Bone diseases due to retrograde disturbances of nutrition.

(*a*) Osteomalacia.

(*b*) Rachitis.

(*c*) Barlow's disease.

(*d*) Acromegaly.

(*e*) Osteoarthropathie pneumatique of Marie.

(*f*) Osteitis deformans of Paget.

(*g*) Phosphorus necrosis.

The majority of acute and chronic diseases of the bones occur during infancy and youth. This is especially true of acute infective osteomyelitis and of tuberculosis of bone. Lexer[1] has demonstrated this to be due to the fact that emboli composed of clumps of bacteria, originating from a primary focus in some other part of the body, are carried to the bone through the circulation. The long and short pipe bones of the extremities receive their arterial supply from three sources (see Fig. 395), viz.: (*a*) A diaphyseal group of vessels, which extend through the shaft in both directions almost to the epiphyseal line and end here as terminal arteries. These gradually become smaller with advancing age. (*b*) A metaphyseal group, which enter the shaft near the epiphyseal line and branch in the direction of the epiphysis, frequently perforate the epiphyseal cartilage, and end as terminal arteries in the epiphysis. These are the most important in relation to the localization of pyogenic or tuberculous infections in bone, since the majority of these are located close to the epiphyseal cartilage either on the diaphyseal or epiphyseal side. (*c*) The third or epiphyseal group of vessels enter the epiphysis from all sides and run toward the bone nucleus. Some, however, extend to the joint, while others pass in the direction of the epiphyseal cartilage.

In the diagnosis of the nature of any bone affection a knowledge of the above anatomic facts will be of great value. In the long bones of the extremities, *the focus of infection is almost invariably in or near the epiphyses*, because the terminals of all three groups of arteries are located here. In the short pipe bones, like the metacarpals, metatarsals, and phalanges, the diaphyseal vessels are large and the metaphyseal and epiphyseal, narrow. Hence, *affections of these bones most frequently involve the shaft*, as is seen in the case of a spina ventosa or tuberculous dactylitis (Fig. 399).

[1] Lexer: "Archiv für klinische Chirurgie," vols. lxxi and lxxiii.

Fränkel[1] has shown that organisms lodge in the medulla of the bones in all of the infectious diseases. They may cause no symptoms or remain latent for many years, and then suddenly be awakened into activity through some slight trauma. In general the following may be said of the two most frequent inflammatory diseases of bone:

1. Acute suppurative osteomyelitis most frequently affects the shaft of the long bones of the extremities. Less often does it start in the epiphysis as an epiphysitis (see page 579), and rarely it invades the neighboring joints at the beginning of the disease.

2. Tuberculosis of the bones of the extremities is most frequently found close to the epiphyseal cartilage in the shaft or in the epiphysis itself. In those bones like the upper end of the femur (hip-joint), where the epiphyseal cartilage lies within the joint capsule, it involves the joint primarily. In the other bones the joints are far more often involved than in acute suppurative osteomyelitis. In young persons such a primary tuberculosis of bone with a complicating secondary tuberculous arthritis is almost the rule, while in adults it is the exception, the joint disease being the primary focus.

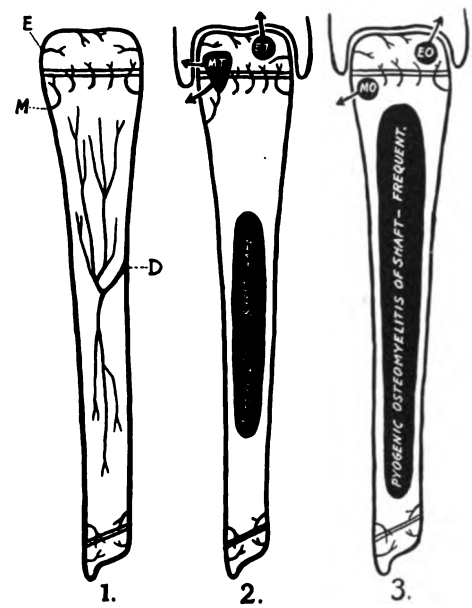

FIG. 395.—LOCALIZATION OF BONE DISEASE (modified from Lexer).

1, Normal bone. The three sets of arteries which every long pipe bone possseses are shown as E, epiphyseal; M, metaphyseal; and D, diaphyseal. 2, Localization of tuberculosis. Involvement of the shaft is quite rare (see text). MT, Focus near epiphyseal line as a result of plugging of metaphyseal vessel; ET, epiphyseal focus. 3, Localization of pyogenic osteomyelitis. Involvement of shaft in majority of cases. MO, Metaphyseal focus; EO, epiphyseal focus. The black arrows show the direction in which the pus may spread from the metaphyseal and epiphyseal foci into the adjacent joints or toward the skin.

I. ACUTE DISEASES OF BONE.

1. THOSE INVOLVING THE PERIOSTEUM CHIEFLY.

Acute Traumatic Periostitis.

This follows a blow or a fall upon the bone. It occurs most frequently in bones like the tibia and the lower end of the fibula, olecranon

[1] "Mittheilungen aus den Grenzgebieten der inneren Medizin und Chirurgie," vol. xii.

process, etc. If the bone lies superficially, as is the case in the three locations just named, a swelling can be distinctly felt upon passing the finger lightly over the bone. The swelling feels quite firm and is very sensitive to the touch. The patient usually complains of severe pain at this point.

The course of such a contusion of the periosteum varies. It may (*a*) undergo resolution, so that the indurated area gradually disappears; (*b*) it may become softer and show distinct fluctuation, and this mass becomes slowly absorbed, or (*c*) suppuration may occur even without any external wound being present. If this latter change occurs, the indurated area becomes softer and fluctuates. This latter change is accompanied by inflammatory symptoms. The periosteal area becomes extremely tender and painful, the skin over it is red and swollen, and, if the abscess is not opened, it will discharge spontaneously, pus and serum being evacuated. In some cases superficial necrosis of the underlying bone occurs, small sequestra being separated in five to six weeks.

Acute Infective Periostitis.

This is rarely a primary process, and if so is quite limited in extent. It occurs as a primary affection as the result of infection from neighboring tissues, *e. g.*, in the jaws by extension from a carious tooth, in the phalanges as a complication of infection of the fingers or toes. On the fingers such a suppurative periostitis, resulting in necrosis of the underlying bone, is called a "felon." The periosteum is not infrequently involved through extension of phlegmonous processes.

The diagnosis of such a suppurative periostitis cannot often be made until a sinus has formed, leading to necrotic bone. In the early stages there is severe pain and tenderness on pressure, well localized over the point of involvement. In superficial bones like the jaw or tibia there is a swelling of the periosteum which may fluctuate, and after discharging pus one can feel the exposed bone with a probe, and after one to two months sequestra separate and can be extracted.

2. THOSE INVOLVING THE MEDULLA PRIMARILY.

Acute Infective or Suppurative Osteomyelitis.

This occurs most often in young persons and may appear in a single bone or in several simultaneously. It is a disease which almost invariably begins in the shaft, and may involve the adjacent joints secondarily. It is very rare after complete ossification of the epiphysis.

When it occurs in adults, it is usually the result of the awakening into activity of a previously existing osteomyelitic focus. The tibia and femur are more often the seat of the disease than any other bones of the extremities. Next in order of involvement are the humerus, radius, fibula, ulna, and pelvis. The number of cases in the different years of early life gradually rises to the tenth year, and is highest at the seventeenth year. The greatest number of cases occur between ten and seventeen years. After seventeen years the number rapidly decreases, and after twenty years the number of cases is few (Trendel[1]).

The organism most frequently concerned is the staphylococcus pyogenes aureus. There are undoubtedly cases of acute osteomyelitis which are due to other organisms.

To this latter class belong those which are caused by (*a*) the streptococcus pyogenes; (*b*) the typhoid bacillus, and (*c*) the pneumococcus. It is almost impossible clinically to distinguish an osteomyelitis due to these three organisms from that caused by the staphylococcus pyogenes aureus. Lexer and Klemm have shown that there is but little difference, from either a clinical or pathologic standpoint. One may, however, find an infection atrium, such as an infected streptococcus wound, a pneumonia, an otitis media, a pharyngitis of some kind, an infected umbilicus, etc. There is also apt to be more edema of the soft parts, especially in the streptococcus variety. A widespread phlegmon of the shaft is rare in both of these forms, as well as in that due to the typhoid bacillus. The focus is usually quite localized and often subperiosteal.

The diagnosis of the ordinary form of acute suppurative osteomyelitis is, as a rule, not difficult. There are, however, three distinct clinical types:

1. It may begin suddenly with swelling over the affected bone, delirium, high fever, leukocytosis, rapid pulse, and other signs of a severe septic intoxication, death occurring in a few days.

2. It may appear as a so-called acute arthritis in infants from three weeks to two years of age. The onset is sudden, there is marked rise of temperature, rapid pulse, and other signs of septic intoxication. The joint is swollen and very painful. The local swelling may be followed by pus formation, which is often evacuated spontaneously. In the severer cases separation of the epiphysis occurs with disorganization of the joint. It has been clearly shown that these cases of *acute septic arthritis* in infants and young children are the result of a rupture into the joint of an osteomyelitic focus situated on the shaft side of the epiphyseal cartilage. The suppurative arthritis, which is the

[1] "Beiträge zur klinischen Chirurgie," vol. xli.

most prominent clinical symptom, is due (*a*) to the fact that (as in the hip) the epiphyseal cartilage lies within the joint, or (*b*) that the focus ruptures into the joint cavity, or (*c*) it burrows through the epiphysis and then invades the joint. To this form of the disease the name *epiphysitis* has been given in England.

3. The ordinary clinical form of acute suppurative or infective osteomyelitis may arise as (*a*) a complication of compound fractures, of amputations, or operations on bones, or (*b*) it may follow a slight trauma or exposure to cold or wet, or (*c*) develop in the course of an infectious disease like pneumonia, typhoid, scarlatina, variola, etc. The clinical history is as follows: The disease begins suddenly with severe pain and tenderness over the affected bone, usually of the shaft, or over several bones, if multiple foci exist. A chill often ushers in the disease, followed by high fever. The temperature curve resembles greatly that of a typhoid, being of a continuous type. The limb soon becomes swollen, tender, and indurated. The skin glistens, is red, and feels hot. There is rigidity of the adjacent joints. If no surgical relief is given one of two conditions results: (*a*) A septicemia develops with high fever of a continuous type, rapid pulse, dry-coated tongue, marked leukocytosis, delirium or stupor, sweats, and diarrhea.

FIG. 396.—ACUTE OSTEOMYELITIS OF THE TIBIA (Nichols).

(*b*) In less severe cases the pus perforates the cortical portion of the shaft and the periosteum, and appears beneath the skin as an abscess with distinct fluctuation. The patient may present himself with a sinus leading to necrotic bone in the shaft and give a history of such an acute onset as just described.

If the medulla has not been sufficiently drained, the septic symptoms may persist. The fever shows a distinct rise in the evening (hectic type) with morning remissions. The limb remains brawny and swollen, and considerable pus continues to be discharged from the wound

of operation or sinus. An *x*-ray picture will often be of great aid in the diagnosis of the presence of sequestra.

A chronic condition may result from an acute osteomyelitis and last for forty to fifty years. The sinus leading to the original focus may heal and then after years an acute exacerbation may supervene. The diagnosis in such cases can be made from the previous history, the presence of a scar over the shaft, and the local inflammatory signs.

In some cases an encapsulated abscess may exist for many years. It has been called a chronic bone abscess. The diagnosis in these cases can be made (*a*) from the frequently recurring pains; (*b*) the evening rise of temperature, and (*c*) from the presence of tenderness on pressure over the bone focus.

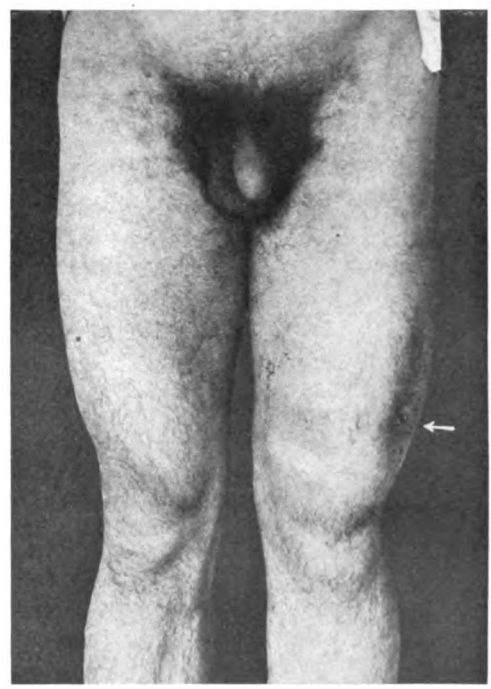

FIG. 307.—EXTERNAL APPEARANCE OF LEFT THIGH IN A CASE OF OSTEOMYELITIS OF THE FEMUR.

The arrow points to the swelling caused by the involucrum and thickening of the subcutaneous tissue.

Differential Diagnosis of Acute Osteomyelitis.—*Typhoid Fever.*—The first clinical type of acute osteomyelitis described above (see page 578) may at first sight resemble a case of typhoid. The fever is high and of a continuous type, and there is stupor and delirium in both. In acute osteomyelitis, however, there is a high degree of leukocytosis and absence of the Widal test, unless the patient has had a recent typhoid. In addition the local evidences of inflammation can usually be found by careful search.

Infectious Arthritis.—The second type of acute osteomyelitis, in which the focus lies in or near the epiphysis, may greatly resemble arthritis due to other causes. This is especially true of osteomyelitic foci at the upper and lower ends of the femur, and the upper end of the humerus. The symptoms are generally more severe both in infants and older children than in an arthritis due to other causes. The pain,

swelling about the joint, and fever are very marked. Abscess formation follows in the majority of the cases, and is preceded by a high degree of leukocytosis.

Epiphyseal separation is quite common in the cases of acute osteomyelitis close to a joint, and the diagnosis can often be made from the resultant deformity and the use of the *x*-ray.

In subacute cases it is impossible before operation to make a differentiation from tuberculosis of the joints.

Tuberculosis of Bone.—In the acuter types of suppurative osteomyelitis there should be no difficulty in making a differentiation from tuberculosis. The pain, leukocytosis, local swelling and tenderness, high fever, etc., are all characteristic of an acute osteomyelitis.

There are certain subacute cases of osteomyelitis which may resemble a tuberculosis. There are, however, even in these cases certain points of difference. *Tuberculosis affects the shaft close to the epiphysis, or the latter itself, while it is rare in the shaft of the long bones. Acute osteomyelitis is most frequently a disease of the medulla of the shaft and is rarely situated close to the epiphyses.* The history of pain, rise of temperature, and the local signs, such as tenderness on pressure, swelling, etc., are all more marked in an acute infective osteomyelitis. An *x*-ray will show greater thickening of the bone, due to involucrum formation in osteomyelitis. If a sinus exists, the granulation-tissue will often be of great aid in making a diagnosis, being caseous and flabby in tuberculosis, and if examined microscopically, will show giant-cells and tubercles.

II. Primarily Chronic Diseases of Bone.

1. Those due to infective agents.

Tuberculosis of Bone.—This may occur clinically in the following forms:

1. As single or multiple foci in the epiphyses of the long pipe bones, *e. g.*, femur, tibia, humerus, ulna, radius, fibula, and clavicle.

2. As a tuberculous osteomyelitis of the short pipe bones, *e. g.*, metatarsals, metacarpals, and phalanges of the toes and fingers.

3. In the spongy bones of the carpus and tarsus.

4. In the flat bones, *e. g.*, pelvis, scapula, ribs, sternum, and skull.

A tuberculous osteomyelitis of the shaft or a diaphysis of the long pipe bones is very rare. Nichols states that he has been unable to find it in one hundred and twenty cases studied by him, and Küttner was only able to discover six cases in a total of two thousand one hun-

dred and twenty-seven cases of tuberculosis of the bones and joints in von Bruns' clinic (0.28 per cent.).

The *diagnosis of tuberculosis of bone* varies according to its localization.

1. If situated in the epiphyseal ends of the long pipe bones, the symptoms of the secondary joint affection may predominate to such an extent that a primary bone focus is only to be suspected from the generally accepted fact that in the majority of cases tuberculous arthritis is secondary to a primary bone focus.

FIG. 398.—EXTERNAL APPEARANCE OF THIGH IN A CASE OF OSTEOSARCOMA OF THE LOWER END OF THE FEMUR SIMULATING TUBERCULOUS OSTEOMYELITIS.

In bones like the olecranon, upper and lower ends of the tibia, clavicle, lower end of the femur or radius, which are accessible to inspection and palpation, the presence of a tuberculous focus may be suspected from the following symptoms:

1. A localized tenderness and swelling (Fig. 398), accompanied by moderate pain upon pressure or movement of the limb. The pain is never acute, as in an infective osteomyelitis, and there is little if any rise of temperature. If caseation and perforation of the periosteum have occurred, the presence of fluctuation and the history of slight pain preceding the appearance of the swelling render the diagnosis of tuberculosis probable. This is especially true if such an abscess appears in a child or adult at the time of examination or at some prior period.

2. Tuberculous osteomyelitis occurs chiefly in the short pipe bones of the hands and foot, *e. g.*, metacarpals, metatarsals, and phalanges. It has been termed tuberculous dactylitis or spina ventosa. To some extent the ulna resembles these short pipe bones, in the fact that tuber-

culous localization, if it does not occur in the olecranon process, is most apt to take place in the shaft. The short pipe bones of the hand are far more frequently involved than those of the foot. The affected bone is expanded and becomes spindle-shaped. This thickening of the bone is so marked as to be distinctly palpable, and can be distinctly seen in a skiagraph. Such an enlargement of the bone seldom occurs in the epiphyseal form of tuberculosis, but if such is the case, it takes place at the lower end of the radius and upper ends of the tibia and ulna.

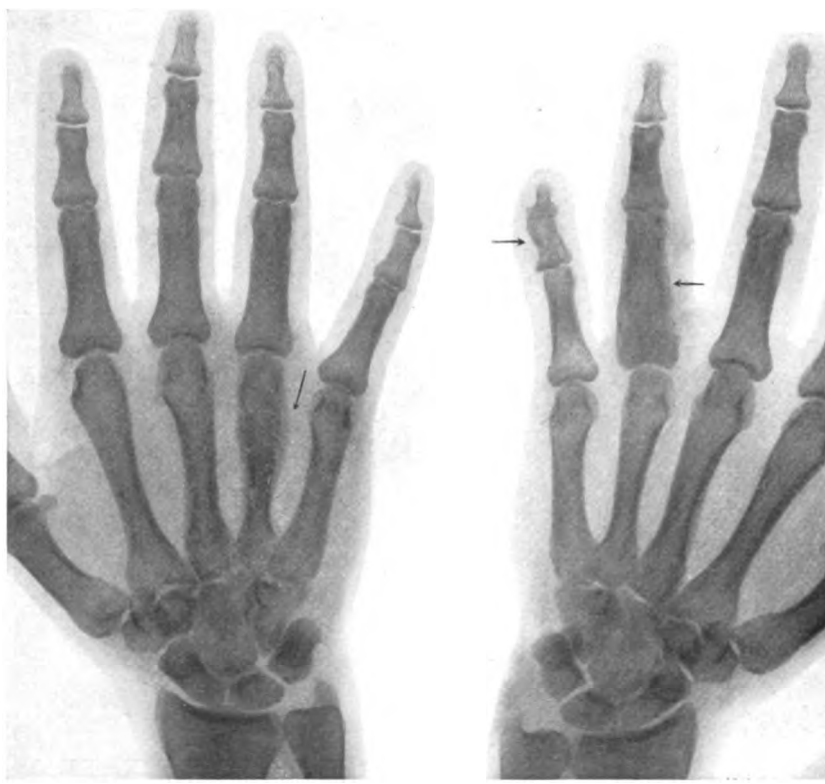

FIG. 399.—X-RAY OF A CASE OF TUBERCULOUS DACTYLITIS, OF LEFT METACARPAL BONE OF RING-FINGER, OF SECOND PHALANX OF RIGHT MIDDLE FINGER, AND FIRST PHALANX OF RIGHT RING-FINGER.

In addition to the enlargement of the bone, perforation of the overlying periosteum occurs at an early period with the formation of a sinus discharging thin yellow pus and lined by pale, flabby, often caseous, granulations. Such abscesses and sinus formations occur at an early stage in the case of tuberculosis of the metacarpals and metatarsals, but at a late stage in the phalanges, which latter may remain enlarged for a long time. *Syphilis* causes a similar enlargement of the short pipe bones,

but can be differentiated by the fact that it occurs chiefly in infancy, and there is no abscess formation. The history and a search for other evidences of syphilis will usually clear up any doubts. Should the latter, however, exist, the administration of antisyphilitic remedies should be instituted.

3. Tuberculosis of the spongy bones of the tarsus is more frequent than is that of the carpus. In lesions of these bones the articular symptoms predominate and will be referred to in the diagnosis of joint disease.

4. Tuberculosis of the flat bones of the extremities, *e. g.*, of the pelvis, may occur either along the crest of the ilium, the symphysis pubis, or in the acetabulum. The latter localization may be the starting-point of a hip-joint disease.

In the crest of the ilium and symphysis pubis, tuberculosis is very rare, and difficult to recognize until an abscess or a sinus which leads down to carious bone has formed.

Tuberculous periostitis as a primary affection occurs only in the ribs and has been described on page 203.

Syphilis of Bone.—Syphilis affects the bones both in the hereditary and acquired stages. The localization and pathologic changes are similar in both and will be described together. In hereditary syphilis there is, however, a greater tendency to secondary joint involvement, the clinical signs of which will be referred to in the section on joint diseases.

The following are the most frequent localizations of syphilis:

1. As a periostitis:
   (*a*) In the early portion of the secondary stage.
   (*b*) In the late secondary stage.
   (*c*) In the tertiary form.
   (*d*) In late hereditary syphilis.
2. As a gummatous osteomyelitis:
   (*a*) In the tertiary stage.
   (*b*) In the hereditary form.

In hereditary syphilis, bone symptoms appear (*a*) as an osteomyelitis of the epiphyses of the long pipe bones, causing pain, marked enlargement of the end of the bone, a swollen joint, and loss of function of the limb (*syphilitic pseudo-paralysis*).

(*b*) As an osteomyelitis of the short pipe bones (syphilitic dactylitis), which can be differentiated from a tuberculous condition by the absence of a tuberculous history and of a tendency to abscess formation and the rapid improvement under antisyphilitic treatment.

(*c*) As an osteomyelitis anywhere in the body with resultant necrosis and sinus formation.

(*d*) As an osteoperiostitis in that form of hereditary syphilis which appears about the age of puberty. The diagnosis of the latter two forms does not differ from similar conditions observed in the late

FIG. 400.—METHOD OF PALPATING THE PERIOSTEUM OF THE TIBIA.

The fingers are laid flat upon the limb, the tips resting upon the internal surface of the tibia or shin, and the hand then passed along the entire length of the tibia.

secondary or in the tertiary stages of acquired syphilis (see below).

Acquired Syphilis.—In the early weeks of the secondary stage one of the most marked symptoms, which appears just before the cutaneous eruption occurs, is the acute periostitis of the cranial bones (see page 70). In the late secondary or early tertiary periods this local-

ization is so characteristic that the diagnosis is usually not difficult. The disease most often involves the tibia, but may first show itself in the clavicle. The signs are (*a*) severe pain over the affected bone which is most marked at night, except in those who sleep during the day on account of their occupation, in which case they are most severe during the latter period. (*b*) Palpation of the bone reveals a distinct thickening of the periosteum and exquisite sensitiveness to the touch. This inflammatory form of syphilitic bone localization may be quite circumscribed (periosteal nodes) or diffuse. Even after the disease has subsided the affected bone may show upon palpation, alternating elevations and depressions, which may be of some aid in making a diagnosis of syphilis at some future period. These elevations are the result of ossification of the periosteal nodes.

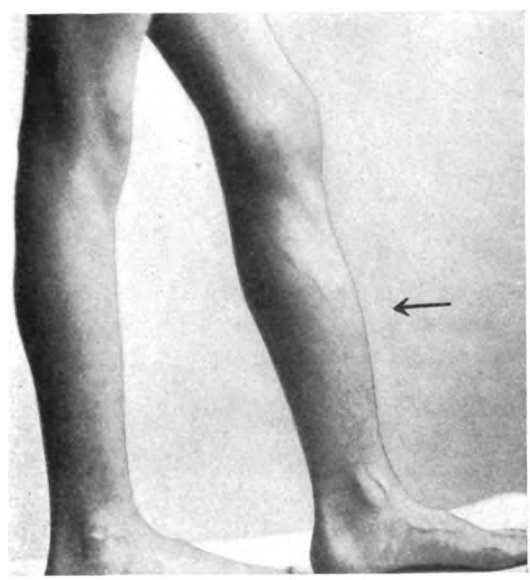

FIG. 401.—PERIOSTITIS SYPHILITICA IN A BOY OF SIXTEEN, SUFFERING FROM SYPHILIS HEREDITARIA TARDA.

This is the same case as shown in the *x*-ray of Fig. 402. The arrow points to the prominence along the entire internal aspect of the tibia.

Gummatous Periostitis and Osteomyelitis.—These occur in the tertiary stage in one of two forms: (*a*) As a superficial periosteal gumma; (*b*) as a circumscribed or diffuse gummatous infiltration of the medulla of the shaft.

The periosteal gumma, which varies from the size of a walnut to that of an apple, appears as a painful, superficial tumor, which may become soft and show evidences of fluctuation, or gradually disappear under treatment. At times they may break down and perforate the skin, or ulceration takes place with the formation of typical reniform, steep-edged ulcers.

A gummatous osteomyelitis causes a dull aching pain in the bone without palpable changes in the periosteum. There may be an accompanying marked enlargement of the shaft of the bone or extensive

necrosis may occur. In some cases, a spontaneous fracture may be the first sign of the presence of the disease.

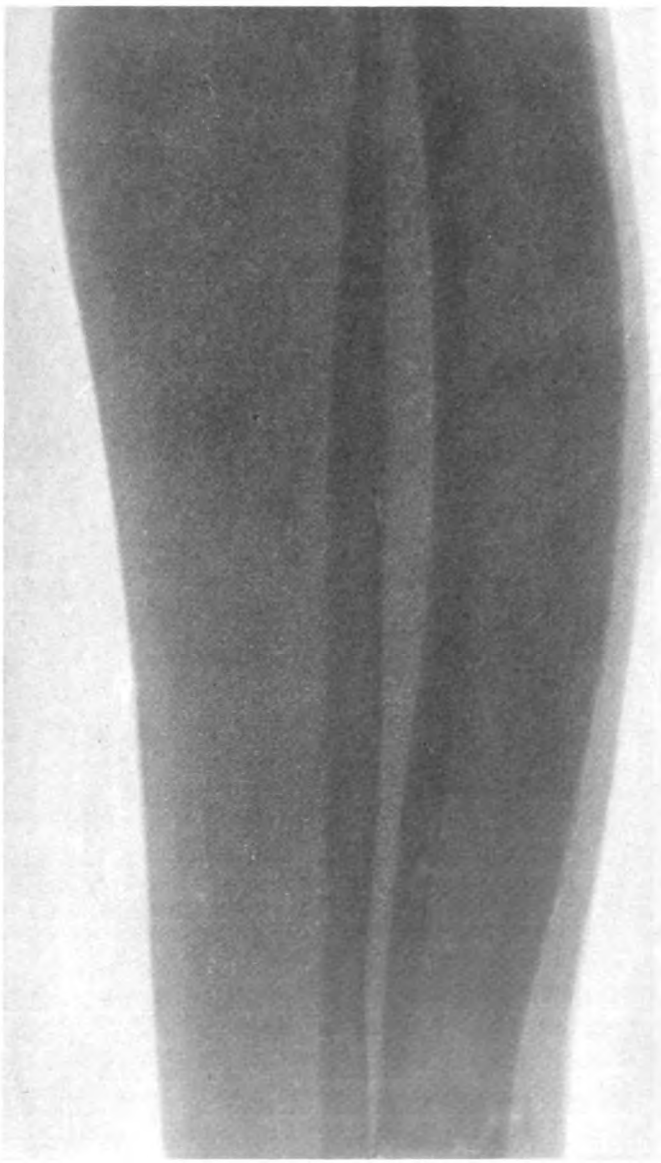

FIG. 402.—X-RAY OF CASE OF SYPHILITIC PERIOSTITIS OF TIBIA, EXTERIOR PICTURE OF WHICH IS SHOWN IN FIG. 400.

The diagnosis of the various forms of bone syphilis is usually not difficult, if there is a distinct history or there are evidences of the dis-

case elsewhere. In no other bone affection are the thickening, pain, and tenderness of the periosteum so marked. The nocturnal exacerbation of pain is also characteristic.

Tuberculous periostitis, as was stated, is very rare as a primary affection, and if present usually shows early signs of suppuration.

If the periosteum has increased in thickness rapidly, and the enlargement is quite marked and not very painful, the question of the possibility of a periosteal sarcoma arises. This is especially true if there is but little response to antisyphilitic treatment, and the history of a previous syphilis is not clear. In such cases an exploratory incision is often necessary.

The gummatous form of osteomyelitis, if it be accompanied by considerable osteosclerosis and enlargement of the bone, must at times be differentiated from an osteosarcoma, especially if situated at the epiphyseal ends of the long bones. A gumma in such a situation causes a unilateral, while a sarcoma causes a uniform, enlargement.

A gumma of the short pipe bones of the hand and foot (metacarpals, metatarsals, and phalanges) can be differentiated from a tuberculous osteomyelitis (spina ventosa) only by the greater tendency of the latter to suppurate and the fact that antisyphilitic treatment causes no improvement. The *x*-ray appearance of both processes would be similar (Fig. 399).

Osteomalacia.

This is a disease of bone in which absorption of lime salts occurs in healthy bone.

Bending of the softened bone leads to marked deformity, and the occurrence of spontaneous fracture is common. The majority of cases reported have been in women (91 per cent.), and of these it occurred during pregnancy in 70 per cent.

There is, however, a non-puerperal form, which is of constantly increasing interest to surgeons, since the spontaneous fractures occurring as the result of it may be easily diagnosed as being due to bone neoplasms. The most characteristic symptoms of the puerperal and non-puerperal forms are:

1. Rheumatoid pains in the spine and the extremities without swelling, but accompanied by marked muscular weakness.

2. In the non-puerperal form there is a history of malnutrition and of unhygienic surroundings.

3. Deformities. These may be (*a*) of the spine—there is a grad-

ually increasing curvature of the spine, which may be in a backward, forward, or lateral direction; (*b*) of the pelvis—the walk becomes waddling, like that of double congenital hip dislocation, the pelvic bones becoming misshapen; (*c*) of the chest—this assumes a barrel shape or the ribs sink in; (*d*) of the extremities—there is marked bending of the long bones.

4. Spontaneous fractures. These occur at an early period. They may be single or multiple, and *the possibility of an osteomalacia must always be borne in mind in cases of apparently spontaneous fracture.*

5. Owing to the absorption of the calcium salts, the *x*-ray will show a lighter shadow than normal bone does.

Differential Diagnosis.—The bone diseases from which osteomalacia must be differentiated are:

(*a*) *Osteosarcoma*, especially of the soft medullary type. This may, like osteomalacia, cause a spontaneous fracture as its first symptom. Usually, however, there is a history of deep-seated pain located in the shaft of one of the long bones, not diffuse, like that of osteomalacia, *i. e.*, felt in various parts of the body.

(*b*) *Osteitis Deformans.*—This occurs chiefly in elderly people, but may begin before forty. The accompanying rheumatic pains and the increasing curvature of the spine and lower extremities resemble those of osteomalacia, but there gradually develops an irregular nodular thickening of the various bones. In addition the *x*-ray will show that the normal deep bone shadow is not absent as in osteomalacia.

(*c*) *Rickets.*—This causes bending of the bones, but never marked as in osteomalacia, spontaneous fracture is infrequent, and rachitis occurs at a much earlier age than osteomalacia.

RACHITIS (RICKETS).

The diagnosis of this form of bone disease usually presents no difficulties. The most characteristic symptoms are:

1. **Deformities.**—These are most marked in the head, spine, thorax, and extremities.

(*a*) *Head.*—The head is larger than normal and of a square or box-shape, owing to the formation of bosses over the parietal and frontal eminences. The sutures and fontanelles remain open longer than normal. The occipital bone often shows abnormal softness or parchment-like cracking (craniotabes) on pressure. This rachitic condition is frequently accompanied by a variable degree of hydrocephalus.

(*b*) *Chest.*—Nodules are to be felt at the junction of the costal car-

tilages and ribs, which together form a series of bead-like enlargements to which the term *rachitic rosary* has been given. In addition to this beading, the chest is flattened from side to side and the sternum often very prominent (pigeon-breast).

(*c*) *Spine.*—The most characteristic deformity is a backward curvature (kyphosis), which is uniformly distributed over the entire spine.

(*d*) *Extremities.*—The deformities are more marked in the lower than in the upper extremity. The palpable epiphyses of the various bones are markedly enlarged. This is especially pronounced at the lower ends of the radius and ulna. The femur is bent forward and outward and there is frequently an accompanying coxa vara (see page 648). The other principal deformities are genu valgum and varum (see page 653). Spontaneous and greenstick fractures are not infrequently due to rickets. The **diagnosis** can usually be made from (*a*) the box-shaped skull; (*b*) beading of the ribs; (*c*) enlargement of the epiphyses at the wrist when accompanied by great restlessness; (*d*) nervous symptoms, such as convulsions, laryngismus stridulus; (*e*) marked muscular weakness; (*f*) delayed dentition and delayed closure of the fontanelles. There is never any breaking down of bone in rickets, or formation of sinuses. A diagnosis of rickets should never be made from a single symptom, since enlargement of the epiphyses may be due to hereditary syphilis. Again, deformities of the extremities, like coxa vara or genu valgum or varum, may be due to static or other causes. A curvature of the spine may be due to tuberculosis. The differentiation from scurvy is given below.

Chondrodystrophia Foetalis (Achondroplasia—Fetal Rickets).

This bone affection is essentially a disturbance of the normal process of ossification of the primary cartilage. The children are dwarf-like when born. The head is large, the ribs are beaded, the thorax flattened, and the long bones are bowed and shortened. The bones remain distorted and their growth is greatly retarded.

Scorbutus (Scurvy, Barlow's Disease).

This, like rickets, is a disease of childhood, although it may rarely occur in early youth or even in adult life as the result of errors of diet. About four-fifths of the cases occur between the sixth and fifteenth months (Holt). Most of the children have been in good health up to the time of the attack. The principal surgical interest in the disease is its tendency to involve the bones. A surgeon is often consulted on account of the fact that the children cry out with pain when lifted.

In the majority of cases this pain and tenderness are most marked in the lower extremities, especially about the knees and ankles.

This symptom alone should always lead one to suspect scurvy, since acute rheumatism is very rare in such young children. The accompanying symptoms—(*a*) swelling near or of the large joints; (*b*) spongy, swollen, often bleeding, gums; (*c*) tendency to subcutaneous hemorrhages and to melena, as well as (*d*) the history of improper diet (prolonged use of some proprietary food or sterilized or condensed milk)—will usually enable a diagnosis to be made. In anterior poliomyelitis there is no tenderness. In actue osteomyelitis there is fever, leukocytosis, as well as local redness and heat. The swelling of the limb may resemble a sarcoma, but an *x*-ray will soon exclude a neoplasm, because the normal outlines of the bone are preserved in scurvy.

Osteitis Deformans (Paget's Disease of Bone).

This is an affection which causes a softening and bending of some of the long pipe bones and of the spine, due to absorption of lime salts with secondary formation of fibrous tissue in its stead. It usually affects the tibia in elderly persons and soon involves the neighboring joints.

The disease attacks men more frequently than women. The average age of onset in twenty-one cases, according to Osgood and Locke, of Boston, was forty-three years. The skull is greatly enlarged, and there is neuralgia from pressure. The affection is often ushered in by a long period of rheumatic pains and headaches. The patient stands with legs bowed and spine bent gradually backward, the body is carried forward and bent at the hips. The occurrence of bow-legs late in life accompanied by enlarged skull and bending backward of the spine are the chief diagnostic features.

Osteoarthropathie Pneumatique.

This is a disease of bone which was first described by Marie. It occurs in persons suffering from chronic cardiac and pulmonary diseases, and consists of an enlargement (Fig. 403) of the end phalanges of the fingers and toes, resulting from a chronic periostitis.

Acromegaly.

This gives such a characteristic clinical picture that it seldom causes any difficulty in diagnosis. There is marked enlargement of the bones of the face (especially of the lower jaw) and of the hands and feet. It is often a symptom of tumors of the pituitary body, as was the case in the patient whose brain is shown in Fig. 37.

Tumors of Bone.

The clinical history of a patient with a tumor of one of the bones of the extremities is usually as follows: (*a*) He may present himself, for the first time, on account of a fracture which followed a very slight trauma; (*b*) he may complain of pain and tenderness over the affected bone for months to years before a palpable enlargement appears; or, lastly, (*c*) a patient who has a distinct tumor presents himself for examination and opinion.

In making a diagnosis, one must consider whether the enlargement to be felt is in reality a neoplasm of the bone or whether it is the result of some inflammatory process, and if one has excluded the latter,

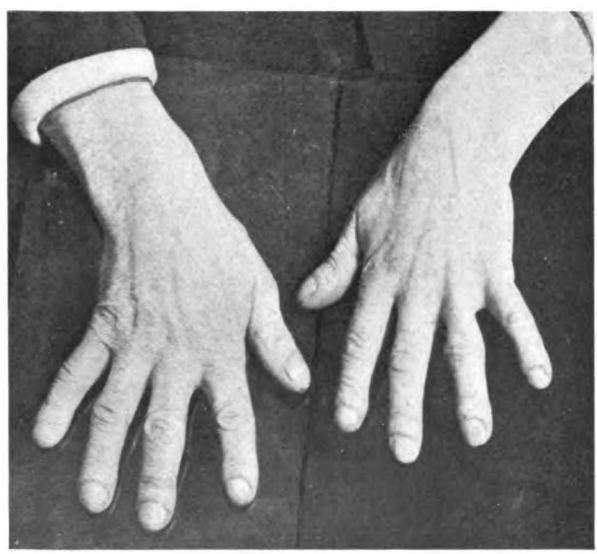

Fig. 403.—Osteoarthropathie Pneumatique of Marie of the Joints of the Fingers of Both Hands. (See text.)

the next problem is to determine the nature of the tumor, as to whether it be benign or malignant, etc.

If the patient is examined for the first time on account of an apparently spontaneous fracture, the various forms of pathologic fracture enumerated on page 441 must be excluded one by one.

If the spontaneous fracture is due to the rarefaction of the osseous tissue as the result of a neoplasm there will be the previous history, and the local findings to be enumerated below, as more or less characteristic of the different forms of bone neoplasms.

It is impossible to make a diagnosis of a bone neoplasm without

referring briefly to the chief varieties and then to consider their differentiation from other conditions:

Neoplasms of bones of the extremities.
- Benign.
  - True or simple bone cysts.
  - Osteomata and exostoses.
  - Enchondromata.
- Malignant.
  - Primary and secondary sarcomata.
  - Secondary carcinomata.

A group of tumors called *peritheliomata* is also found in bones which belong clinically to neither group, although they resemble the sarcomata histologically. These peritheliomata show no tendency to produce metastases, but are apt to recur locally after operation.

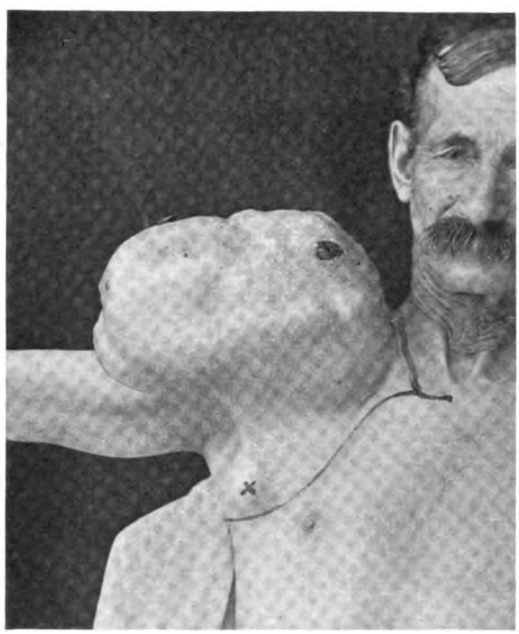

FIG. 404.—ENDOTHELIOMA OF SHOULDER, ANTERIOR VIEW (Dr. John A. Hartwell).

Benign Tumors.—*True or Simple Bone Cysts.*—As is the case with all bone tumors, patients may present themselves, for the first time, with a spontaneous fracture due to this form of tumor. If such be not the case, there is a history of pain over the epiphyseal ends of one of the long pipe bones (humerus, femur, and tibia), which has continued during months to years, followed by the gradual enlargement of the bone in the majority of cases. The bulging itself is seldom uniformly firm, but palpation reveals many soft compressible places. An *x*-ray will show, according to one writer (Carl Beck [1]), a characteristic light area, surrounded by the clear, narrow shadow of the expanded cortex. Others (Koch [2] and Helbing) do not believe much reliance can be placed upon the skiagraph in making a diagnosis.

[1] "Annals of Surgery," 1901, vol. xxxiv.

[2] "Archiv für klinische Chirurgie," Bd. lxviii, 1902.

The chief conditions from which it must be differentiated are a chronic bone abscess resulting from a former osteomyelitis, syphilis, tuberculosis, and osteosarcoma. In the last named (*a*) the growth is also very slow and gradual; (*b*) the surface is uniformly hard and does not show softer areas as in a simple bone cyst. In many cases only an exploratory incision will clear up the diagnosis. A cyst is filled with a thin yellowish serous fluid, while an osteosarcoma is solid throughout.

Chronic abscesses due to an old osteomyelitis are usually situated in the upper end of the tibia. They pursue a very protracted course and the pains occur periodically, especially after exertion. There is often some evening rise of temperature. Tuberculosis of bone seldom causes expansion of a long pipe bone, but it leads to abscesses and sinuses at an early date.

Central syphilitic gummata might give rise to deep-seated bone pain. They cause no enlargement of the bone, give a negative *x*-ray picture, and improve rapidly under antisyphilitic treatment. Up to the present time only twenty-two cases of simple bone cysts have been reported.

FIG. 405.—EXTERNAL VIEW OF DISSECTED SPECIMEN OF AN OSTEOSARCOMA OF THE UPPER END OF HUMERUS.
This is from the same case as is shown in Figs. 406 and 407.

Osteomata and Exostoses.—These terms are frequently used to represent the same tumor projecting from bone. The *exostoses* are congenital multiple tumors which are most frequently situated near the epiphyses and become ossified during puberty, at which time they are likely to cause symptoms. They are situated where the long bones grow most rapidly, viz., the lower end of the femur, upper ends of tibia and humerus. They grow very slowly, and are not accompanied by pain or tenderness. In some individuals these exostoses occur in multiple form, *i. e.*, at every epiphysis.

Exostoses may develop slowly, or in some cases rapidly, after trauma. If the growth has been rapid, a differentiation from an ossifying periosteal sarcoma is difficult. It can often only be made by an *x*-ray examination and an exploratory incision. In a periosteal sarcoma which is becoming an osteosarcoma, the bone shadow is seen arranged in spicules like rays, perpendicular to the shaft of the bone, while an osteoma or exostosis shows the architecture of normal bone, *i. e.*, cortex and medulla. An exostosis following trauma can also be distinguished from a periosteal osteosarcoma by the fact that its growth ceases after a time, while that of the malignant tumor is steady and progressive.

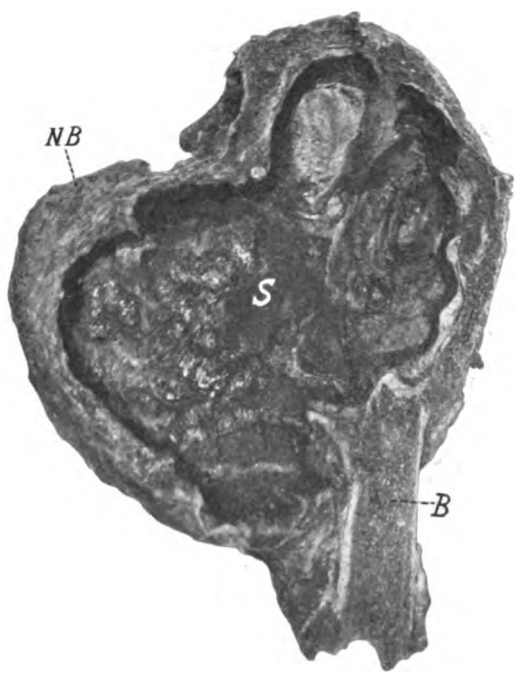

FIG. 406.—VIEW OF LONGITUDINAL SECTION OF AN OSTEOSARCOMA OF THE UPPER END OF THE HUMERUS.
NB, Ossifying periosteal layer; *S*, softer portion of tumor.

The exostoses which occur in chronic joint affections, like arthritis deformans, tabetic and syringomyelic joints, are readily diagnosed by the symptoms of the accompanying conditions.

Enchondromata.—These occur as nodulated elastic tumors, which have the consistency of cartilage. Quite rarely, they are soft, as the result of a myxomatous degeneration. They may occur as pure chondromata or as mixed tumors, *e. g.*, myxochondrosarcomata or osteochondrosarcomata. The two latter will be referred to under Sarcomata of Bone.

Pure enchondromata occur most frequently in the following bones,—scapula, pelvis, long and short pipe bones of the extremities, and phalanges of the fingers and toes. In the two latter situations they occur more frequently than in any other portion of the body. In the metacarpal bones they occur as central tumors, which gradually cause an expansion of the bone like a spina ventosa. On the fingers and toes enchondromata occur as multiple tumors and pursue a very benign

course, but in other bones may grow to enormous size. The diagnosis of enchondromata of bone is not difficult on account of their (*a*) slow growth; (*b*) consistency; (*c*) location as single or multiple tumors at the epiphysis; (*d*) the *x*-ray shows a light shadow; (*e*) absence of pain and tenderness.

Sarcoma of Bone.—This is the most frequent form of bone

FIG. 407.—X-RAY OF THE OSTEOSARCOMA OF UPPER END OF HUMERUS, SHOWN IN FIG. 406.

tumor. As secondary growths sarcomata of bone are a frequent result of metastasis of a primary sarcoma of the breast, testis, etc. They differ from the secondary carcinomata of bone in the clinical fact that the primary growths, in the latter case, are often insignificant when bone metastases occur, while in the case of sarcoma the bone metastases appear at an earlier period and the diagnosis of the primary growth has usually been made. Many cases of malignant bone

neoplasms may first present themselves for diagnosis on account of a fracture, which has either occurred spontaneously or after slight violence. Other cases may present themselves with the history of a tumor of the testis or other organs having been operated upon one to two years previously, followed by pain over the hip, limping, and shortening of the lower limb, as shown in Fig. 408. An *x*-ray in such cases shows a clear space opposite the head of the femur, due to bone absorption by the metastatic growth.

The diagnosis of secondary sarcomata differs from that of the primary forms only through the absence in the latter of a primary

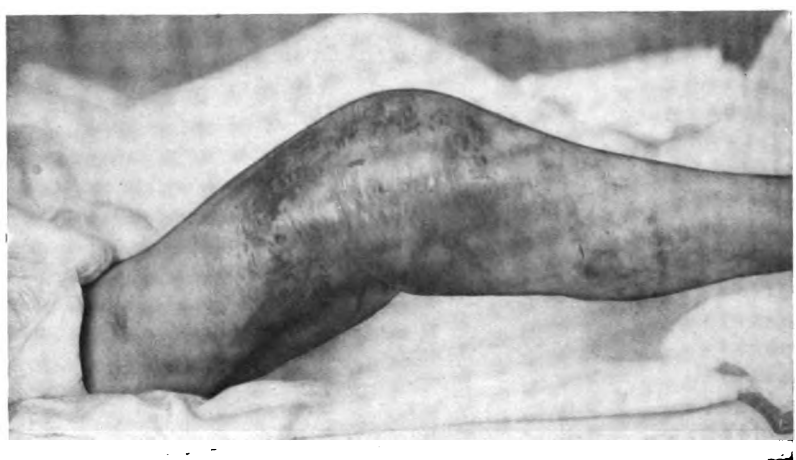

FIG. 408.—SARCOMA OF KNEE-JOINT.

Observe the flexion contracture, and the enormous enlargement of the lower end of the femur, in which the tumor was primary.

seat, and the fact that the secondary forms show a more rapid growth and less of a tendency to ossification.

Primary Forms of Sarcomata of Bone.—In the diagnosis of these an effort should be made to include, if possible, the exact variety of sarcoma, since, from a clinical point of view, they differ greatly in their malignancy.

They generally occur in two forms: One, the periosteal, and the other the myelogenous. Both forms have as seats of predilection the epiphyseal ends of the long pipe bones. The following table shows the percentage:

Upper epiphysis of tibia,	35 per cent.
Lower end of femur,	18 "
Upper end of humerus,	13 "
Ulna and radius,	4 "

The periosteal sarcomata are usually of the small round and spindle-celled type. They give rise to enormous tumors, which may at times undergo ossification, the lime salts being deposited in a needle-like manner radiating from the shaft. Giant-celled sarcomata of the periosteum are quite rare.

Myelogenous sarcomata may be of the round, spindle-, or giant-celled type. These tumors cause rapid expansion of the medulla, but at the same time new bone is formed from the overlying periosteum (see Fig. 405). This form is often associated as an osteochondrosarcoma or as a myxochondrosarcoma.

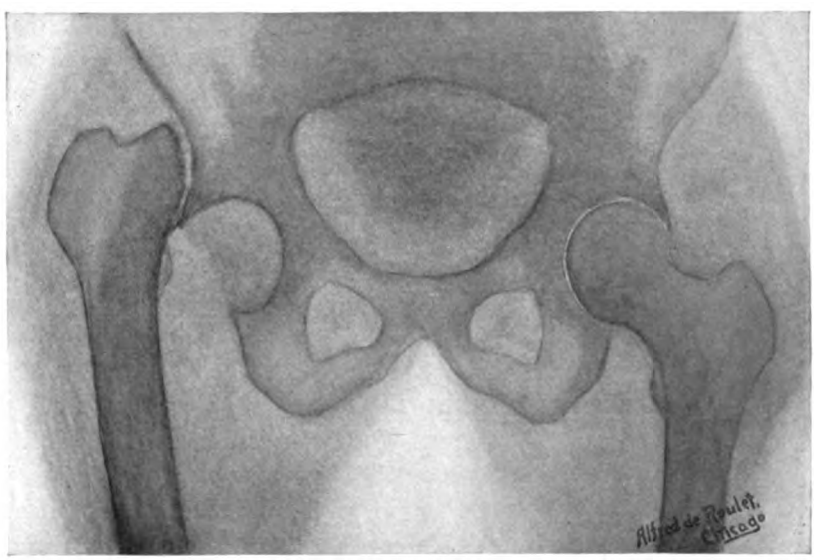

FIG. 409.—UPWARD DISLOCATION OF NECK AND SHAFT OF FEMUR, FOLLOWING ABSORPTION OF HEAD THE RESULT OF A METASTATIC SARCOMA, PRIMARY GROWTH IN TESTES (X-RAY COPY).

In general, it may be said that the softer a bone sarcoma is, the more rapid is its growth and the greater its malignancy.

The diagnosis of bone sarcomata may be made from the following data:

1. They occur at the epiphyseal ends of the most rapidly growing bones (femur, tibia, and humerus) of young adults. Only 5 per cent. occur beyond the age of forty.

2. In the periosteal form a palpable enlargement of the bone appears quite early, and is soft unless ossification has occurred.

3. In the medullary form the patient complains for some time of pain over the end of one of the above-mentioned long bones. After

a variable period a swelling appears at the seat of pain, and may be hard or soft, according to the amount of osseous tissue.

4. Trauma in young adults, followed by pain and tenderness which do not disappear within a month, should be watched as indicating the possibility of development of sarcoma.

5. A rise of temperature, and effusion into the adjacent joint is not uncommon, especially in the periosteal form.

6. The growth of bone sarcomata varies greatly. In the giant-celled and in the osteosarcomata it is very slow. In the other varieties it is more rapid and progressive than that of any other form of bone neoplasm.

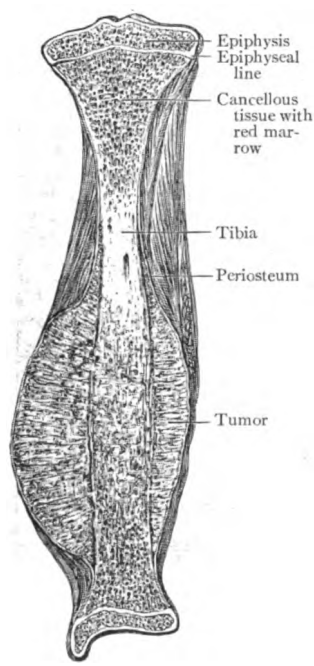

FIG. 410.—SECTIONAL VIEW OF OSSIFYING PERIOSTEAL SARCOMA OF THE TIBIA IN A GIRL (J. Bland-Sutton).

7. The *x*-ray is of value in distinguishing bone neoplasms from inflammatory processes or trophic changes. It may be said that the more cellular types, like the periosteal and the small rounded myelogenous sarcoma, generally show a translucency or faint shadow (Fig. 407) wherever the bone has been involved. The ossifying periosteal and myelogenous sarcomata give the most typical pictures. In the former (periosteal osteosarcoma) the fine spicules of bone are shown radiating from the periosteum. In the central or myelogenous osteosarcomata the *x*-ray shows a deep shadow with irregular margins throughout the extent of the growth, thus differing from the soft myelogenous forms which show a faint shadow.

8. Spontaneous fracture is a valuable sign in both the benign (osseous cysts) and malignant types of bone neoplasms. It may be the first symptom on account of which the patient consults the physician.

9. In some osteosarcomata with large vascular spaces pulsation is so marked as to simulate an aneurysm.

In the differential diagnosis of osteosarcomata one must consider (*a*) tuberculosis of bone, (*b*) chronic abscess resulting from a former acute osteomyelitis, (*c*) simple or benign osseous cysts, (*d*) other forms of malignant bone neoplasms, such as myelomata, peri- and endotheliomata, and secondary carcinomata.

The chief differential points of the first three were enumerated under simple bone cysts. The other forms of malignant neoplasms can only be differentiated from sarcoma by a consideration of the history of the case and the age of the patient. Carcinomata are always secondary to a primary growth in the thyroid, prostate, or breast, and occur at a late period of life.

Endo- and peritheliomata of bone occur after forty, as a rule, but do not differ clinically in other respects from the ordinary forms of sarcomata.

Myelomata cannot be differentiated from sarcomata clinically.

Other Forms of Malignant Bone Neoplasms.—In considering the diagnosis of the nature of a malignant bone neoplasm one must not omit the following forms:

1. *Carcinoma.*—This usually occurs as a metastasis of a primary carcinoma of the breast, prostate, or thyroid. It occurs most frequently in the femur, and the primary tumor may have been overlooked until a spontaneous fracture occurs.

2. *Myelomata* are composed of tissue which is similar to that of the red marrow of young bone. The tumor arises in the medulla of the bone, and on section looks like a freshly cut liver. It occurs oftenest in the tibia. Quite rarely the tumor is found in the lower end of the radius and ulna, upper end of the fibula and humerus, and lower end of the femur. The patients are young adults. The growth of the tumor and expansion of the bone take place very slowly, so that they behave more like the giant-celled central sarcomata.

Endo- and Peritheliomata of Bone.—About twenty-three cases[1] have been reported of this form of bone tumor, which can only be distinguished clinically from osteosarcoma by the fact that over seventy-three per cent. occur after the age of forty, while sarcoma is rare at that period of life.

DISEASES OF THE JOINTS IN GENERAL.

When the surgeon or physician is consulted by a patient suffering from some joint affection, the first question he asks himself is, *What is the nature of the condition?* In order to be able to systematically exclude one etiologic factor after the other, it is necessary to have some classification of joint diseases which shall serve as a working basis. In the light of our present knowledge the most satisfactory division is into two great clinical groups, the acute and chronic. It is necessary,

[1] Howard and Crile: "Annals of Surgery," Sept., 1905.

however, to state that there is often no hard and fast line between these two, since affections placed under one head will often present themselves clinically in such a form as to make it seem more appropriate to place them under the other. Until the etiology and pathology of chronic articular rheumatism and arthritis deformans is thoroughly investigated, no large grouping for these two affections will seem appropriate. They are undoubtedly of infectious origin, but the exact nature of the latter is as yet undetermined.

A classification which will be found most useful from a diagnostic point of view is that suggested by König.

The general term "arthritis" is used in preference to that of synovitis for some affections. Clinically the distinction cannot always be made between a case of synovitis and one of *arthritis*, since the same affection may at one time involve only the synovial membrane and, at another, all of the structures of the joint.

The classification is as follows:

ACUTE ARTHRITIS.

I. Primary acute arthritis.
   1. Acute traumatic.
   2. Acute articular rheumatism.
   3. Acute gout (described under gout).
II. Secondary acute arthritis.
   A. Metastatic arthritis.
      1. Through ordinary pus cocci, pyemic arthritis.
      2. Through other specific microörganisms.
         (*a*) Typhoidal arthritis.
         (*b*) Pneumococcus arthritis.
         (*c*) Influenzal arthritis.
         (*d*) Scarlatinal arthritis.
         (*e*) Gonorrheal arthritis.
         (*f*) Syphilitic arthritis (secondary stage).
   B. Secondary acute arthritis by extension.
      1. From an osteomyelitic focus (acute arthritis of infants).
      2. From the surrounding soft tissues (erysipelas, phlegmon, bursitis, tendo-vaginitis and lymphangitis).

CHRONIC ARTHRITIS.

I. Tuberculosis.
   1. Primary osteal.
   2. Primary synovial.
II. Chronic serous synovitis. (Chronic articular synovitis.)
III. Arthritis deformans.
IV. Chronic articular rheumatism.
V. Chronic and atypical gouty arthritis.
VI. Syphilitic arthritis.
VII. Neuropathic arthritis.
   (*a*) Tabes.
   (*b*) Syringomyelia.
VIII. Hemophiliac and scorbutic arthritis.
IX. Tumors of joints.
X. Hysterical joints.

In attempting to make a diagnosis of a joint affection, it is necessary to keep some such classification constantly in mind.

The examination should embrace the following:

1. An accurate history of the duration and mode of onset.
2. The general condition of the patient.
3. The examination of the affected joint or joints.

1. *History of the Case.*—If carefully taken this will yield much information as to (*a*) the mode of onset, whether sudden or gradual; (*b*) its relation to an injury either recent or at some remote period; (*c*) whether the affection accompanied some one of the systemic infections just mentioned; (*d*) whether it appeared after symptoms of a local infection had existed; (*e*) the family and personal history, as to hereditary or acquired diseases, habits, hemophilia, etc.

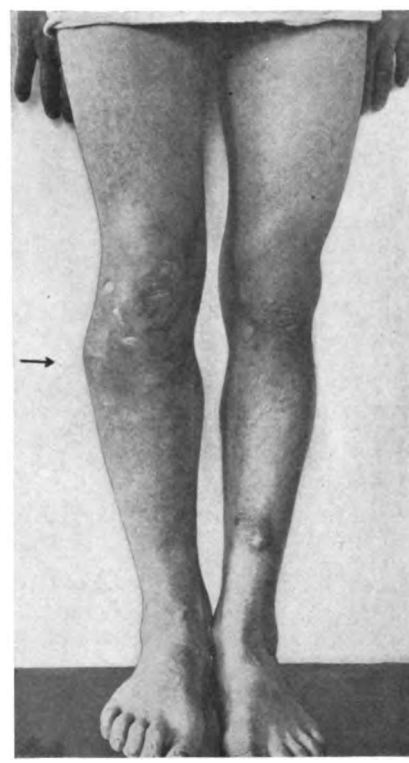

FIG. 411.—EXTERNAL VIEW OF PATIENT WITH PERIOSTEAL SARCOMA OF UPPER END OF FIBULA.
The arrow points to the greatly enlarged upper fibular region.

2. *The General Condition of the Patient.*—This embraces a thorough examination of the entire body, including temperature, pulse, condition of lungs, heart, and other viscera, and of the nervous system. Without such a general survey a case of tabetic joint, for example, may be easily overlooked. Again, the coexistence of tuberculous foci elsewhere will often throw great light on the nature of an obscure chronic joint affection. Evidence of cardiac or other serous membrane involvement is of great value in the diagnosis of rheumatic affections.

At times a therapeutic test is necessary, in order to clear up a diagnosis of rheumatism or syphilis.

3. *Examination of the Joint.*—(*a*) Inspection reveals the presence or absence of swelling, deformity, redness, edema of the overlying skin, etc., in the more superficial joints.

(*b*) Palpation shows the presence or absence of fluctuation, of localized or general tenderness, and of the degree of fixation of the joint.

(*c*) Exploratory puncture. This is a very valuable aid in ascertaining the character of the fluid, and must be performed with every possible regard for asepsis (see Fig. 412).

(*d*) X-ray. This gives much information in regard to the condition of the articular ends of the bones entering into the joint formation. In acute cases it is of little value; in chronic cases the changes are often slight or appear very late, especially in tuberculosis.

(*e*) Mensuration. The measurement of a joint and the comparison of the result obtained with that of the corresponding joints of the opposite limb is of great value in confirming other data.

The chief diagnostic features of the principal joint affections are as follows:

Acute Traumatic Arthritis.

This may follow (*a*) a blow over a joint or a fall upon a joint; (*b*) a distortion or twisting; (*c*) it may accompany a dislocation and, finally, (*d*) it occurs as the result of a fracture into the joint or in close proximity to it. The history is usually quite clear. The injury is followed by severe pain over the joint and by loss of function. Within a few hours there is noticeable swelling of the joint. It loses its normal contour, all of the depressions over it being effaced by the rapidly increasing swelling.

Exploratory puncture is rarely necessary for diagnostic purposes. If performed, however, the exudate will be found to be a clear, straw-colored fluid containing much albumin, more or less fibrin, and a few leukocytes.

As a rule, fever is not a diagnostic sign in an acute traumatic arthritis. There is, however, a rare possibility of a pyogenic infection of hematogenous origin, which will change the clinical picture. Under these latter circumstances the pain and swelling will be excessive. The presence of such increased local signs, accompanied by constantly increasing leukocytosis and fever, will speak for a joint infection.

Another fact is also of value from a diagnostic point of view. A joint trauma may be followed by an acute gonorrheal arthritis in a patient suffering from a subacute gonorrheal urethritis. Such a case is not readily recognized unless it be borne in mind that infection of a traumatic arthritis is very rare. If fever and other signs occur in such a joint, a search should be made for primary foci of pus infection, such as the urethra, etc.

Acute traumatic arthritis is also of interest on account of its sequelæ.

It usually disappears gradually, but may become chronic. The effusion either remains, or it disappears and then recurs from time to time. In the former case the disease is termed a *chronic serous synovitis* (see page 614). In the latter, *i. e.*, when it recurs, it is often given the special name *intermittent articular hydrops* (see page 614).

Among the other sequelæ of an acute traumatic arthritis or sprain of a joint, may be mentioned a subluxation of the articular cartilage, the formation of free or floating bodies,[1] and finally the development of tuberculous foci in the joint itself or in the epiphyseal ends of the long bones in close proximity to it.

Acute Articular Rheumatism.

This form of joint affection is usually polyarticular, but it may appear in one joint and follow a trauma. Under the latter conditions the clinical signs may be almost identical with that of a sprain.

The question can seldom be decided, without observing the rapid improvement following antirheumatic treatment (salicylates, etc.).

Local examination of a rheumatic joint of the monarticular type also shows greater tenderness over the affected joint, frequently accompanied by some degree of fever.

If polyarticular the diagnosis is not difficult in the more acute forms. The joints are greatly swollen, there being considerable edema of the periarticular tissues. There is also a variable degree of fever, usually from 101° to 104° F. The joint symptoms are frequently accompanied by sweats and evidences of involvement of the serous membranes, especially of the heart. The disease is also characterized by its tendency to wander from one joint to the other.

The greatest difficulty in both the monarticular and polyarticular forms is to differentiate them from the other varieties of multiple joint infection. The latter are, as a rule, secondary to foci elsewhere, whereas in an acute rheumatism such primary foci cannot be found. The most frequent source of difficulty is to differentiate multiple gonorrheal joint invasion from that of an acute rheumatic form.

Another form of arthritis which may simulate the acute rheumatic form is that resulting from an osteomyelitic focus of suppuration in the epiphyseal ends of the long bones, such as the femur or tibia. In the more superficial joints, like the knee or shoulder, the more severe local signs, such as pain, tenderness, etc., will enable one to differentiate this form of acute arthritis. In deeply situated joints, like

[1] For a description of the diagnosis of these complications see Injuries of Joints on page 453.

the hip, the diagnosis is more difficult. This form of acute septic arthritis occurs chiefly in children, and is accompanied by far more grave symptoms of infection than is the case in an acute articular rheumatism.

In infants such an acute osteomyelitis of the hip with secondary arthritis causes high fever, severe pain on movement of the limb, flexion, and early abscess formation. In older children there is also high fever, leukocytosis, delirium, much swelling, and marked local joint symptoms. The presence of these localizing signs, the invasion of a single joint, and the more severe constitutional symptoms enable a differential diagnosis from an acute rheumatism to be made. The differentiation of gout, acute arthritis deformans, and acute forms of tuberculous arthritis will be considered under the respective heads.

Secondary Acute Arthritis.

As was stated above, a primary purulent arthritis is very rare. Usually such an acute infectious joint disease is secondary to a more or less distinct primary focus. It is of the utmost importance to recognize this fact when called upon to make a diagnosis of an acute arthritis.

It is not always easy to state definitely the exact nature of the process.

1. The history should be carefully taken to ascertain (*a*) whether the joint affection followed one of the acute infectious diseases to be mentioned below; (*b*) whether it was preceded by an acute or a subacute gonorrheal process; (*c*) whether it followed a pyemia, and, finally, (*d*) whether it was preceded by evidences of infection in the bones forming the joint or in the soft tissues around it.

2. The examination of the exudate should be regarded as a more or less routine procedure in the diagnosis of this class of joint affections. This is conducted by aspirating (Fig. 412) some of the effusion and examining it cytologically, as well as staining it for microörganisms and inoculating culture-media from it.

The exudate may often be sterile, or the organisms can only be demonstrated after repeated examinations.

The acute arthritis of this group may be secondary to one of the following:

1. To a pyemia or septicopyemia—staphylococcus aureus and streptococcus pyogenes infection.

2. To one of the acute infectious diseases—typhoid, pneumonia, influenza, scarlatina, gonorrhea. With the exception of scarlatina, the specific organisms of the respective diseases can be found.

3. Secondary to an acute osteomyelitic focus or to infection in the soft parts. Ordinary pus cocci, unless the primary disease has been caused by other organisms, are usually found.

The clinical characteristics common to the majority of these cases of secondary acute infectious arthritis, are marked swelling, tenderness on palpation, pain on motion, loss of function, a variable degree of fever, leukocytosis, and more or less constitutional disturbances. The disease may affect a single joint or be polyarticular. The joints involved are seldom as exquisitely painful; there is also less tendency to a shifting about from one joint to another, and there is a higher degree of leukocytosis than in acute articular rheumatism.

FIG. 412.—METHOD OF PERFORMING EXPLORATORY PUNCTURE OF THE KNEE-JOINT.

The point of election is one situated to either side of the patella, preferably the outer, *e. g.*, point indicated in the illustration by the cross. The needle is inserted beneath the patella, which has been raised up by the fluid, and the piston gradually withdrawn.

Several of these forms of acute secondary arthritis require special mention.

Arthritis Secondary to Pus Foci Elsewhere (Pyemic).—This form occurs during the course of a general infection with the ordinary pyogenic organisms, viz., the staphylococcus aureus and the streptococcus pyogenes. When the joint affection is the direct result of a well-pronounced pyemia or septicopyemia it presents but little difficulty in diagnosis. The cases, however, in which the primary lesion was a furuncle or some other comparatively insignificant focus, such as a tonsillitis, otitis, etc., present far more difficulty. The exudate is always purulent, and contains the organisms which have caused the

primary disease. Usually the disease is monarticular, the joint being greatly swollen and very painful. The local disease is accompanied by high fever and other septic symptoms. The periarticular edema is very marked, and perforation of the capsule, followed by extensive necrosis of the joint cartilage, occurs at an early stage.

Typhoidal Arthritis.—This is an infrequent complication of typhoid fever. The infection is seldom due to the specific bacillus alone. In the majority of cases it is a mixed infection, *i. e.*, in association with the ordinary pus cocci and the colon bacillus. The joint complications occur usually during convalescence, or even months or years after the attack of fever. If it occur during convalescence the general symptoms are prolonged, and there is more or less fever. The local symptoms are not very severe, the pain, swelling, and tenderness not being marked.

The exudate may contain the typhoid bacillus alone. In the majority of cases the specific organism is mixed with staphylococci or colon bacilli. That which has been previously stated as true of all of the arthritides of secondary origin is true of this form, viz., that the joint exudate may be found sterile. The exudate can be either serous or purulent, and the disease may affect only one or several joints.

Pneumococcus Arthritis.—This form of arthritis may occur (*a*) as a direct complication of a pneumonia; (*b*) as a metastasis of a pneumococcus septicemia, or (*c*) as a purely local disease without any preceding pneumonia or any septic symptoms.

When the arthritis occurs as a complication of pneumonia it usually appears during the period of convalescence. The joint symptoms are quite marked. The pain varies in severity from a slight to a very severe one. Tenderness and swelling of the joint are very pronounced. Redness and widespread edema indicate an involvement of the periarticular tissues, and in some cases quoted by Herrick [1] an abscess was found in the structures about the articulation.

The lesion is usually monarticular, the knee-joint being most often involved. Exploratory aspiration of the joint effusion with bacteriologic examination of the fluid is the only means of recognizing the pneumococcic character of the disease. It must not be forgotten that an arthritis following a pneumonia, may be due to the ordinary pus cocci. The joint fluid may also be sterile at the time of the examination, so that repeated punctures should be made.

The constitutional symptoms show great variations (Herrick). In some cases the joint symptoms are insignificant as compared with those

[1] "American Journal of Medical Sciences," 1902.

involving the pleura, pericardium, meninges, or lung. In other cases the clinical picture is that of a severe septicemia, viz., high fever, dry tongue, rapid pulse, delirium, etc. In a third class of cases, the arthritis is apparently primary without pulmonary localization. This latter variety is the one which is often secondary to a pneumococcus osteomyelitis. The exudate is usually purulent.

Arthritis Following Other Infectious Diseases.—Pain, swelling, tenderness, and loss of function of a joint may appear during the course of a large number of other infectious diseases, *e. g.*, scarlatina, measles, diphtheria, dysentery, influenza, cerebrospinal meningitis, variola, and secondary syphilis. The diagnosis of the nature of the arthritis can only be made if there is a history of the primary disease. The arthritis may be monarticular or polyarticular. The exudate is usually serous, rarely sero-purulent.

Exploratory aspiration is rarely necessary in order to make a diagnosis.

Gonorrheal Arthritis.—This form of secondary arthritis presents such a varied clinical picture that its recognition often presents great difficulty.

Clinically and pathologically there are four forms:[1]

1. Hydrops. This is the mildest form. The arthritis is usually monarticular. The joint most often affected is the knee. If fever and general disturbances are present they are slight. There is but little pain, and the loss of function is chiefly due to the swelling. The effusion is of a serous character, clear, and often of a greenish tint.

2 and 3. Serofibrinous and purulent forms. The symptoms are more intense. There is moderately high fever and tenderness, and the pain on movement is quite severe. The capsule is greatly thickened and there is more paraarticular involvement than in the serous form, so that ankylosis is not an infrequent sequela.

4. The phlegmonous form. This is the most virulent, and is often polyarticular. The local symptoms are best seen in superficial joints, like the ankle, wrist, or knee.

This fourth, is the most characteristic form of gonorrheal arthritis and occurs in adults as a complication of a urethritis. In children it frequently follows a vaginitis, but it may occur in male babies (Holt) without other clinical evidence of gonococcus infection.

It may involve only a single joint, but more frequently is polyarticular, representing a gonococcus pyemia.

The disease may begin suddenly with severe pain, swelling,

[1] I have followed the classification of König, which appears the most satisfactory.

tenderness, redness, and edema of the affected joint or joints. The general symptoms in such cases are extreme. There is but little fluid in the joint, the swelling and pain being the most marked local signs. In a few cases intraarticular abscesses form at an early period.

In children [1] the general symptoms are of a pyemic character with marked prostration.

After such an acute onset, the course of the case becomes very chronic, resulting in complete destruction of the joint, *i. e.*, its ligaments become lax, the cartilages are destroyed, and ankylosis follows.

Gonorrheal arthritis may run a subacute or chronic course from the onset. The patients often complain of flying pains in the joints. There is no swelling, but loss of function and ankylosis frequently follow.

The majority of cases of gonorrheal arthritis appears during the latter weeks of the acute stage of the disease. The condition also appears in the subacute or chronic cases.

There is usually no difficulty in making a diagnosis, even without a bacteriologic examination. The first step is to examine the urethra for pus and the urine for clap shreds, and then stain for the gonococcus. The only form of acute arthritis which requires differentiation is articular rheumatism.

Both of these may begin as polyarticular lesions. Acute rheumatism is more apt to involve the smaller joints of the fingers or toes than is the gonorrheal form. In many cases the local signs are so similar in their severity as to make a differentiation impossible. The presence of a local gonorrheal infection should be sought for. If the gonococcus is found in the joint exudate, the diagnosis is confirmed. This latter is unfortunately a very difficult mode of diagnosis, and often results negatively.

Gonorrheal arthritis is more frequently monarticular than is the ordinary acute form; there is also an absence of cardiac or other serous complications in the gonorrheal form, and a greater tendency to early ankylosis.

In the more chronic forms of gonorrheal arthritis without much effusion and no tendency to ankylosis, the differentiation from chronic rheumatoid arthritis is very difficult. The most important point is to find the primary focus in the genito-urinary tract.

Secondary Acute Arthritis by Extension.—This form of acute arthritis occurs both in adults and children. The diagnosis presents no difficulty. Even in cases of this form of arthritis, following an acute osteomyelitis of the upper end of the femur or similar primary foci, the

[1] Holt: "Medical Record," March 11, 1905.

joint symptoms are so severe as to completely predominate the clinical picture.

The exudate is usually purulent, and contains the same organisms as those which have produced the primary focus.

Such secondary forms of arthritis may follow (*a*) infection of the bones forming the joint (acute pyogenic osteomyelitis); (*b*) phlegmon or erysipelas, or even lymphangitis around the joint; (*c*) a suppurative bursitis or tenosynovitis in the vicinity of the joint, where such structures normally communicate with the articulation; (*d*) penetrating wounds or operations upon the joints. Clinically the picture is that of a severe arthritis accompanied by marked constitutional disturbances. The primary cause can usually be ascertained.

Chronic Arthritis.

Although the division into acute and chronic arthritis seems an unsatisfactory one from a pathologic standpoint, it appears to correspond in the majority of cases to the more important clinical signs, such as mode of onset, local findings, etc. We shall see, however, that some of the forms of arthritis which are usually spoken of as chronic, *i. e.*, slow and progressive in their course, begin quite acutely. For example, there is a group of cases of arthritis deformans, which have an acute onset and course, becoming gradually chronic. Similar exceptions are found in some of the other groups, such as acute forms of tuberculous and gouty arthritis. These occur, however, rather infrequently, and with a little consideration of the chief diagnostic features of each individual case, they can generally be placed under one or the other heading.

Tuberculosis of Joints.—To this cause can be ascribed a large percentage of cases of chronic joint disease, and in the examination of such patients, especially in early life, this form of arthritis must always be thought of.

As in many other joint diseases a knowledge of the pathology is a most valuable adjunct in making a correct diagnosis. The disease may appear primarily (*a*) in the bone, called the primary osteal form, and then either invade the joint, or cause paraarticular abscesses without any involvement of the joint; or (*b*) its first manifestations are in the synovial membrane, called the primary synovial form, the bone being involved after erosion of the articular cartilage. In general, the primary synovial is more frequent than the primary osteal form. In the hip and elbow, the reverse is the case.

Clinically there are three forms, viz.:

(*a*) *A tuberculous hydrops.* A slow accumulation of serous exudate

takes place in the joint. Quite rarely, this form may pursue the acute course referred to above, the clinical picture greatly resembling that of an acute rheumatic arthritis. Accompanied by fever, pain, and swelling, several joints may be involved.

(*b*) *The fungus form.* In this, there is a gradually increasing enlargement of the joint with pain, contractures, and slight increase of evening temperature.

(*c*) *Empyema of a joint.* In this the joint also enlarges slowly, and contains a considerable amount of tuberculous pus.

The chief diagnostic features of tuberculosis of the joints are as follows:

1. *Pain.*—This varies greatly, often being quite severe, while at other times it is of a dull, aching character. The pain is usually referred by the patient to the joint involved, but it may be felt as in the case of a tuberculous hip-joint in the knee. The pain is often more marked at night, the exacerbations causing patients to cry out in their sleep.

2. *Tenderness.*—This is a valuable sign if found. It can, of course, only be elicited by pressure over the ends of the bones which form the more superficial joints, like the ankle, knee, fingers, wrist, elbow, and shoulder. When present it indicates an osteal focus. In deep joints, like the hip, it can be elicited by tapping upon the knee (Fig. 431).

3. *Swelling.*—This is an early sign in primary synovial tuberculosis. In the primary osteal variety it does not appear so early unless the disease progresses rapidly. The swelling is uniform (Fig. 438). All of the normal depressions disappear, and the muscles above and below the joint atrophy.

4. *Loss of Function and Rigidity.*—This is one of the earliest signs. The limitation of movement is marked in all directions, every movement being accompanied by pain. In a primary synovial lesion, the movements may at first be but little impaired and are painless. As soon, however, as the bone is involved, the limitations of motion and the pain become quite marked.

5. *Position of the Limb.*—This is often quite characteristic, and varies with the stage of the disease and the individual joint involved. This symptom will be referred to in connection with the special joints.

6. *Onset and Course.*—As a rule, joint tuberculosis begins insidiously, often weeks to months after a trauma. Its course varies according to the virulence of the disease and the treatment received. Deformities are a frequent sequela. The contents of the joint may penetrate the capsule in one or more places and form *paraarticular abscesses*, which gradually reach the surface of the limb and either form subcutaneous swellings, or

the pus is evacuated, sinuses forming with typical tuberculous bluish, undermined edges and lined by flabby, often caseous, granulations.

7. *Family and Personal History.*—It is of great importance in the diagnosis of joint tuberculosis to secure an accurate family history in order to ascertain if possible any hereditary tendency. In the same manner, information should be secured as to the occurrence of tuberculous lesions elsewhere, such as caseating lymph-nodes (Fig. 429), other osseous, cutaneous or pulmonary foci. A pleurisy with effusion is often of tuberculous origin.

8. *Temperature.*—As a rule, there is but little, if any, rise of temperature. If any exist it occurs toward evening. At times one encounters cases with considerable fever. These are usually the result of a mixed infection.

9. *X-ray.*—The *x*-ray is of considerable value in the diagnosis of tuberculous lesions, but unfortunately it only gives positive information at a rather advanced stage. This is due to the fact that skiagraphs of a tuberculous joint will only show absence of normal shadow, *i. e.*, a defective clear area in the plate, when the bone itself has been affected. Its use will be referred to again in the diagnosis of tuberculosis of the individual joints. In very doubtful cases, a skiagraph should be made, since it will often aid in differentiating advanced tuberculosis from arthritis deformans and chronic rheumatoid arthritis, although even here there is a chance for error.

10. *Tuberculin Test.*—The diagnostic value of tuberculin has been the subject of considerable discussion of recent years, and the general opinion is, that it is too unreliable a diagnostic agent to be depended upon. There are some[1] who believe it is of great aid in the diagnosis of tuberculous joints, but this opinion is not shared by the profession in general.

Differential Diagnosis.—Tuberculosis of a joint must be differentiated from a simple non-tuberculous joint effusion, from chronic gonorrheal and syphilitic arthritis, from chronic rheumatoid arthritis and arthritis deformans.

Chronic Serous Synovitis, i. e., a Non-tuberculous Joint Affection.—This usually begins acutely after an injury, and either persists, or disappears, to recur from time to time. It may, however, greatly resemble tuberculosis if it begins insidiously, causing a gradually increasing painless swelling of the joint. It is chiefly a disease of adults, so that it would rarely come into question in the diagnosis of joint disease in children. In adults it most often affects the knee. There is an absence of

[1] W. S. Baer and H. W. Kennard: "Johns Hopkins Hosp. Bull.," Jan., 1905.

bone tenderness, of limitation of motion, of pain, and of rigidity so frequently found in tuberculosis. The disease is not progressive; it tends to improve spontaneously. The hydrops often disappears and recurs. There is no formation of particular abscesses or sinuses.

Chronic Gonorrheal Arthritis.—In this form of arthritis, the history of its having begun acutely, and then becoming chronic, together with the finding of evidences of an old gonorrheal infection, are of great value. There is also a greater amount of paraarticular thickening, and more of a tendency to ankylosis at an earlier stage than is the case in tuberculosis.

Arthritis Deformans.—This disease must be considered from the fifteenth year on, especially in the elbow-joint. In this form of arthritis the ends of the bones are palpably enlarged, and the capsule feels harder and firmer than in tuberculosis. Arthritis deformans also runs a much slower course, and is seldom accompanied by pain. It is also more apt to affect multiple joints.

Chronic Serous Synovitis (Chronic Articular Hydrops).—This form of chronic arthritis is usually the sequela or outgrowth of an acute attack. The most frequent cause is an injury, *i. e.*, a simple sprain or distortion of the joint. It may, however, appear in a gradual manner without any apparent cause. In those cases in which it directly follows an injury, the diagnosis is not so difficult. There is a history of an injury followed by an acute swelling, which has either persisted or has disappeared, or has recurred from time to time. To the latter clinical variety the term *intermittent articular hydrops* has been given. It has also been called recurrent effusion.

Where the joint swelling has persisted after an injury, without intervals during which the exudate has disappeared, the case may greatly resemble a synovial tuberculosis. In the latter, however, there is a greater amount of thickening of the capsule, and often a clear history of tuberculosis in the family, or foci to be found elsewhere in the body. The course of a chronic serous synovitis is also more gradual, *i. e.*, it extends over a longer period. It is also characterized by an absence of fever, an almost painless course, only a slight crepitus, and an absence of pain on pressure.

In the second form of chronic serous synovitis, *i. e.*, where it appears gradually without apparent cause, the diagnosis is even more difficult. The joint may be filled with papillomatous growths or converted into a lipoma arborescens.

In the majority of cases the disease involves the knee-joint, then the elbow, ankle, and wrist. The joints are more movable than those of chronic articular rheumatism, and there is no change in the cartilages

and bones as in an arthritis deformans. There is a gradually increasing loss of function, and an accompanying accumulation of fluid.

Arthritis Deformans.—This form of chronic arthritis has been wrongly called rheumatic gout, chronic rheumatic arthritis, rheumatoid arthritis, osteo-arthritis, dry arthritis, and chronic articular rheumatism. We now know that it is a clinical entity characterized by a fibrous degenera-

FIG. 413.—ANTERIOR VIEW OF A CASE OF ARTHRITIS DEFORMANS IN A BOY OF TEN (SAME AS SHOWN IN FIG. 414).

Note the characteristic rigidity and deformities of the wrists, elbows, fingers, and knees.

FIG. 414.—LATERAL VIEW OF CASE OF ARTHRITIS DEFORMANS IN A BOY OF TEN.

Note the enlargement of the lower end of the femur and the characteristic deformities in the elbow- and wrist-joints and in the fingers. The spine could not be extended further than is shown in the illustration, as a result of the same process.

tion in the synovial membranes and periarticular structures, as well as by atrophic and hypertrophic changes in the bone. It is most common in old age. According to some, it is of infectious origin, while others believe it to be the result of changes in the central nervous system.

There are five clinical forms, according to Osler and MacRae:[1]

1. *Heberden's nodes.* Nodosities develop gradually at the sides of

[1] "Journal of the American Medical Assn.," Jan. 2, 1904.

the distal phalanges of the fingers about the thirtieth to the fortieth year. The larger joints are rarely involved, and the nodes seldom cause any symptoms.

2. *Polyarticular or general progressive form.* It may begin acutely with symptoms like an acute articular rheumatism. The chronic form is the more frequent, and the joints are involved symmetrically, usually those of the hands first, then the knees, hips, feet, and other articulations. There is a variable amount of pain. In some it is very severe, in others scarcely noticed. The pain is accompanied by more or less swelling of

FIG. 415.—DISLOCATION OF BOTH WRISTS DUE TO MARKED ARTHRITIS DEFORMANS.
The dislocation is more marked upon the right than upon the left side, and was of the forward variety. The characteristic deformity of the fingers is also present.

the joint. Creaking soon begins, followed by inability to move the joint owing to fibrous ankylosis. The muscles of the limb atrophy, and contractures of the joint set in (Fig. 411).

3. *The monarticular form* chiefly affects old people, and is seen particularly (Osler) in the hip, knee, spinal column, and shoulder-joint. In many the condition seems to directly follow an injury. The local signs and changes, viz., swelling, ankylosis, atrophy, and deformity, are the same as in the polyarticular form.

4. *Vertebral form.* The disease here causes a progressive ankylosis with resulting rigidity of the spine. It may be limited to one region or in-

volve the entire spine, causing inability to flex or extend it. Pressure on the nerve-roots may cause great pain, paresthesia, and muscular atrophy.

5. *In children and young individuals.* The onset may be acute with fever or even chills, or gradual with increasing limitation of motion and enlargement of the joints. In the hip of children and young adults it produces outward rotation, adduction, and flexion similar to coxa vara, under which heading it will be considered.

In children this form of chronic arthritis is often characterized by general enlargement of the lymph-nodes and spleen, to which complex of symptoms the name *Still's disease* has been given.

FIG. 416.—MARKED DEFORMITIES OF THE FINGERS AND WRISTS IN A GIRL OF SIXTEEN DUE TO ARTHRITIS DEFORMANS.

There is more involvement of the synovial membrane and soft parts of the joint in children, and less destruction of bone and cartilage than in adults. **The diagnosis of arthritis deformans** is in general not difficult in the advanced stages. In the earlier period, especially in the acute cases, the diagnosis is more difficult. The chief forms of arthritis from which it must be differentiated are the following:

From Acute Articular Rheumatism.—The pain and swelling are usually more marked than in arthritis deformans. The disease rarely disappears in a joint to reappear in another one, a phenomenon so characteristic of rheumatism. The spine and jaw are seldom involved in rheumatism. The enlargement of the lymph-glands speaks for arthritis deformans, as does the absence of cardiac involvement and the failure of the salicylates. There is also more rapid muscular atrophy, and the joint symptoms persist, even though the temperature falls in arthritis deformans.

From Gonorrheal Arthritis.—This may cause pain, swelling, stiffness,

and be polyarticular. It should always be excluded in every case (see page 609).

Chronic Articular Rheumatism.—This is characterized by the gradual onset of pain and swelling in the joints. The pain is very liable to exacerbations during changes in the weather. In some cases there is but little swelling or pain, the chief signs being stiffness and crepitation in the joints. The disease may be limited to a single joint, such as the shoulder, hip, or knee. There is never any erosion of cartilage or formation of new bone, as in arthritis deformans. The condition is often accompanied by valvular lesions.

Gouty Arthritis (Arthritis Urica, Podagra).—This form of joint disease may appear in (*a*) an acute, (*b*) a chronic, and (*c*) an atypical or irregular form. The chronic may be the outgrowth of the acute or appear gradually.

Acute Gout.—In this form there is a sudden onset of severe pain (usually at night) in the metatarso-phalangeal articulation of the great toe. The clinical picture is similar to that described as characteristic of other forms of acute arthritis, viz., severe pain, exquisite sensitiveness to pressure, redness of the overlying skin, fever, and swelling of the joint with obliteration of the normal depressions. The temperature may arise to 103° F.

The symptoms improve, only to recur from time to time. These acute attacks last about a week. Suppuration never occurs. After one or two attacks in one toe, the same joint of the other foot is apt to be affected; later it involves the ankle- or knee-joints.

The diagnosis usually presents no difficulties. The typical location of the acute joint swelling in a person who has been complaining of obscure pains all over the body, without gastro-intestinal disturbances, and has been a *bon vivant* or has led a sedentary life, should always lead to the suspicion of its being gouty in character. If the acute attack occurs primarily in other joints than those of the great toe, the diagnosis can only be made if *tophi* are found. These are collections of uric acid deposited in the external ear, the finger-joints, and later around the knee, elbow, etc. Another diagnostic point in favor of gout versus acute rheumatic arthritis is the fact that the output of uric acid is greatly diminished during the attack. Fever is more constant in acute rheumatism than in gout. If limited to the metatarso-phalangeal joint of the great toe it must be differentiated from a bursitis (see page 263).

Chronic Gouty Arthritis.—This is either an outgrowth of the attacks of acute gout or may be primarily chronic. The toes, and later the fingers, ankles, knees, and elbows, gradually increase in size and become deformed.

These enlargements are accompanied by deposits of uric acid around the affected joint capsule and in the ears. Ulceration of the skin over these tophi may occur. Accompanying these joint symptoms are often those of a chronic interstitial nephritis. These chronic cases can be differentiated from arthritis deformans and chronic rheumatism by the presence of tophi around the joints and in the ears, as well as by the constancy with which the acute attacks begin in the joints of the great toe.

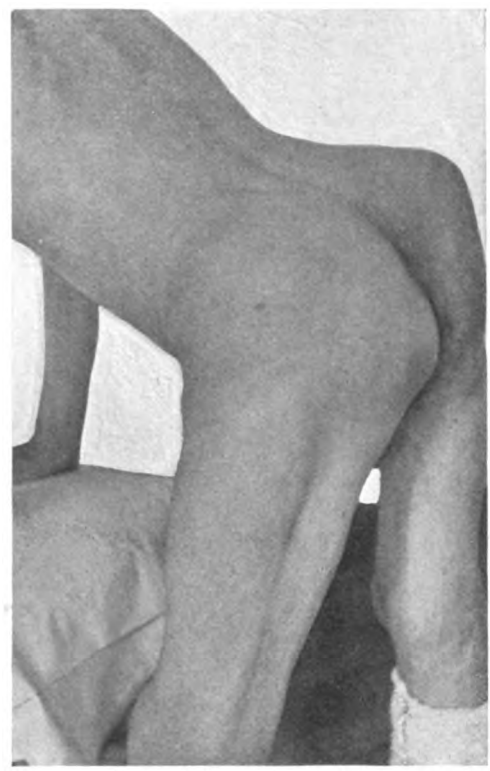

FIG. 417.—TABETIC HIP-JOINTS.
Note the enormous enlargement of the gluteal region, due to increased size of the articular ends of the bone.

Atypical or Irregular Form.—This is a group of cutaneous, gastro-intestinal, cardiovascular, nervous, and urinary symptoms, which often accompany more chronic forms of gouty arthritis, or may occur independently of it.

Syphilitic Arthritis. Acquired Syphilis.—(*a*) *Secondary Syphilitic Arthritis.*—Quite rarely an acute swelling, indicating an effusion into the larger joints, occurs during the secondary stage. It is characterized by pain and effusion in one or more of the larger joints. Usually the knee is the only joint involved. The diagnosis can be made from the fact that the arthritis appears almost simultaneously with the first cutaneous eruption, *i. e.*, about seven to eight weeks after the initial lesion. The joint swelling disappears rapidly after antisyphilitic treatment.

(*b*) *Tertiary or Chronic Syphilitic Arthritis.*—During this stage a form of arthritis occurs which is most difficult to recognize. It resembles a tuberculous arthritis so closely, that at times a differentiation can only be made by the administration of iodids and mercury or by opening the joint. In the latter case one would see gummata in the synovial

membrane or in the articular ends of the bone. The gummata are much larger and firmer than a tubercle, and are never caseated. If the disease is far advanced, ankylosis occurs, and antisyphilitic remedies produce no improvement.

The history of a preceding syphilitic infection and the presence of evidences of the disease elsewhere, as well as the results of the therapeutic tests, are the chief factors in making a diagnosis. The destruction of cartilage is seldom as extensive as in a tuberculosis and the tendency to deformity is far less marked than in tuberculosis. The absence of a primary focus of tuberculosis, or of a family history of this disease, will also aid in the diagnosis.

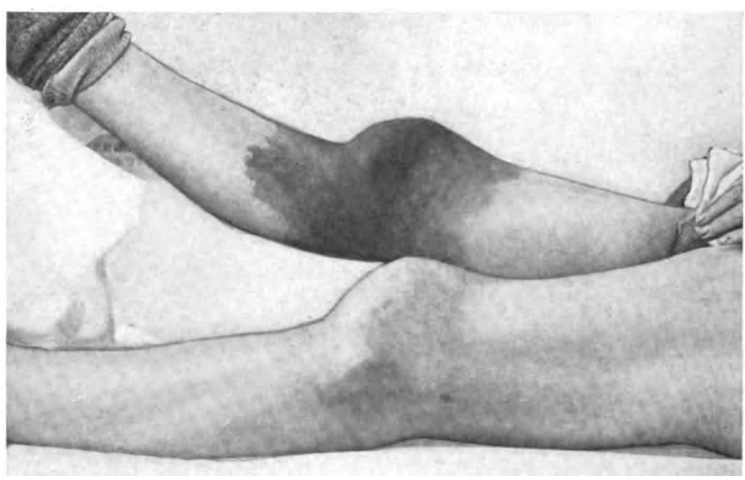

FIG. 418.—CHARCOT KNEE-JOINTS.

The illustration shows a typical case of disease of the knee-joint occurring in tabes dorsalis or locomotor ataxia, to which the name arthropathie tabetique of Charcot has been given. Note the enormous enlargement of the lower ends of both femoræ, and the backward displacement of both tibiæ.

The arthritis referred to above is that due to the presence of primary gummata in the synovial membranes. Another form is that which is secondary to a gummatous osteomyelitis, and is not so difficult to recognize, owing to the enlargement of the ends of the long bones preceding the arthritis.

The latter is most often found in the knee. Periarticular gummata also occur as localized tumors from hazelnut to walnut size, with but few subjective symptoms. It must be differentiated from the fibromatous form of tuberculous arthritis. Both of these conditions are very rare.

(*c*) *Arthritis in Hereditary Syphilis.*—This appears usually in a

gradual manner, either with or without accompanying primary bone involvement. It most often affects the knees, but may involve the wrists and elbows. It seldom appears before the sixth year. There is considerable swelling and thickening of the capsule, the latter in the form which is secondary to bone disease. Nocturnal pains are complained of. The epiphysis is often enlarged and may be entirely separated from the shaft. The loss of function in such a joint often gives rise to a condition known as *pseudo-paralysis*. Pus formation is rare. The suspicion of hereditary syphilis should always be aroused if an apparently idiopathic, almost painless, spindle-shaped

FIG. 419.—ANTERIOR VIEW OF A TABETIC OR CHARCOT KNEE-JOINT, WHICH HAD BEEN SUSPECTED TO BE A SARCOMA OF THE FEMUR.

This is the same case as shown in Figs. 420 and 421.

FIG. 420.—VIEW FROM RIGHT SIDE OF ENLARGEMENT OF THE LOWER END OF FEMUR AND KNEE-JOINT IN A CASE OF TABETIC ARTHRITIS.

Same case as shown in Figs. 419 and 421.

swelling of the larger joints, especially the knee or elbow, appears in a child, accompanied by loss of function of the arm or leg. The cornea, teeth, skull, and other epiphyses should be examined, and a careful history of the family and the infant's previous eruptions, coryza, etc., should be inquired into. These joints improve rapidly after antisyphilitic treatment.

Neuropathic Arthritis.—This occurs after middle life with such comparative frequency that the possibility of an obscure joint affection being either of tabetic or syringomyelic origin must be constantly borne in mind.

These two forms of arthropathy, viz., those due to syringomyelia and to tabes, differ somewhat in their clinical appearance.

(*a*) *Arthritis Tabetica* (*Arthropathie Tabetique, Arthritis Neurogenica*). —The clinical history varies greatly. In some cases the joint swelling appeared suddenly after a slight injury, and has persisted in spite of all treatment. In other cases the onset of the swelling was gradual, and attracted the attention of the patient only when it became quite marked and was accompanied by deformity such as subluxation, or by loss of function due to laxity of the ligaments. The joints most frequently affected are the knee, hip, and ankle, in the order named. In any case of joint disease in middle-aged or old persons, in which there has been a rapid painless swelling of the joint, the possibility of tabes must be considered and a search for the classic symptoms made. These are so fully described in all of the text-books on internal medicine and neurology that it will only be necessary to mention the lightning-like pains along the back of the lower limbs, the absence of the patellar reflexes, the swaying of the body when standing erect with eyes closed, ataxic gait, the Argyll-Robertson pupils, the bladder and rectal paralysis, and finally the disturbances of cutaneous sensation.

FIG. 421.—TABETIC KNEE-JOINT.

The illustration shows the enormous enlargement of the lower end of the femur as a result of trophic disturbances and the ability to produce abnormal abduction in the knee-joint.

In the most typical cases, the knee or ankle is enormously enlarged, there is marked crepitus on manipulation, and the ends of the femur and tibia can be felt to be markedly enlarged. The latter may be so great that in the case shown in Fig. 422 the patient was referred to the writer with the diagnosis of osteosarcoma of the lower end of the femur. Accompanying the joint swelling there is often a subluxation of one of the bones of the joint (Fig. 418). In many of the cases, the *painless abnormal mobility of the joint* is the most characteristic feature. This symptom and the rough crepitus are the chief factors in the diagnosis of

tabetic disease of the hip-joint. The swelling may disappear entirely in some cases, and then recur from time to time. In other cases there is no swelling at any time, but a tendency to the formation of osteophytes in the joint capsule.

The principal forms of arthritis from which it must be differentiated are tuberculosis and arthritis deformans. In neither of these is the swelling as painless as in tabes.

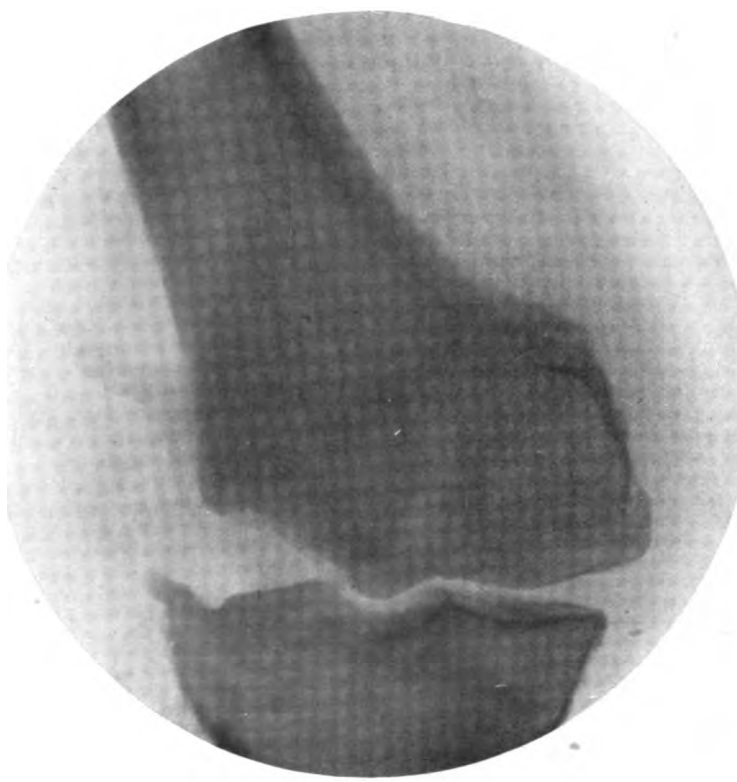

FIG. 422.—X-RAY OF A TABETIC KNEE-JOINT.
Note the hypertrophic condition of the internal condyle of the femur which simulated a neoplasm.

Arthritis deformans often affects many joints, especially the smaller ones, and there is overgrowth of bone (hypertrophic form) with tendency to ankylosis. Tuberculosis is infrequent at the time of life when tabes appears. The joint swelling is seldom as marked as in tabes, and the capsule is usually thicker. The swelling leads to more or less fixation of the joint in tuberculosis, and not to abnormal mobility as in tabes. The previous history of the two affections and the examination for the nervous symptoms of tabes will clear up any doubts.

(*b*) *Syringomyelia.*—This form of neuropathic arthritis differs from that of tabes in chiefly affecting the joints of the upper extremity. There are usually two forms: (*a*) As in tabes, there may be a sudden onset with joint swelling after an injury.

In other cases the swelling appears very slowly. In both instances the shoulder or elbow is most often affected. The swelling itself is enormous, and the abnormal mobility and rough crepitus on manipulation very marked.

(*b*) In the second form, the most striking feature is the tendency to recurrent dislocation, most often of the shoulder-joint. This may have appeared like the ordinary form of dislocation after an injury. The injury, however, is often of a trivial nature. Suspicion should be aroused in every such case, when the dislocation tends to recur upon the slightest amount of manipulation. This tendency to dislocation, accompanied by the enormous distention of the capsule, the painless course, and the rough grating sensation obtained on manipulation, should cause an examination for the other symptoms of syringomyelia to be made. These are the occurrence of painless infections about the fingers and an absence of temperature and pain sense, so that the patient will burn or freeze his fingers without being conscious of it.

FIG. 423.—SYRINGOMYELIC DISEASE OF THE ELBOW-JOINT (F. Graf).

In 80 per cent. of the cases of tabes the arthropathy is confined to the lower extremity, while in syringomyelia the same is true for the upper extremity. The clinical picture of both is similar (Figs. 419 and 423), viz., enormous swelling, relaxation of the capsule and ligament permitting of abnormal mobility or of complete or incomplete dislocations taking place. Fractures near the affected joint are more frequent in tabes. Both run an almost painless course.

Hemophiliac and Scorbutic Joints.—Both of these may appear in an acute and chronic manner.

The symptoms of both are practically the same, the chief difference

being in the history of the case. In the acute form there is pain, fever, and marked swelling of the joint. These all disappear, but may recur. In less severe cases there is only moderate swelling and pain, but no fever.

In the chronic form the joint has passed through a number of the acute or subacute attacks just described, but remains swollen with thickening of the capsule, evidences of fluctuations, and enlargement of the joint ends of the bones. Adhesions are often present, causing considerable impairment of mobility.

The joint lesions can seldom be diagnosed as accompanying a general or scorbutic condition, or as occurring as a part of a general tendency to hemorrhage (hemophilia), without an accurate history and the thorough examination of the body in general.

In the hemophiliac joints there is usually a previous history, or some other obstinate hemorrhage from slight causes. The patients are often pale and anemic. The aspiration of the joint effusion shows it to be pure blood. Since blood, even in microscopic quantities, is rarely observed in any other form of non-traumatic arthritis, its presence should lead one to suspect either hemophilia, scorbutus, or a new growth.

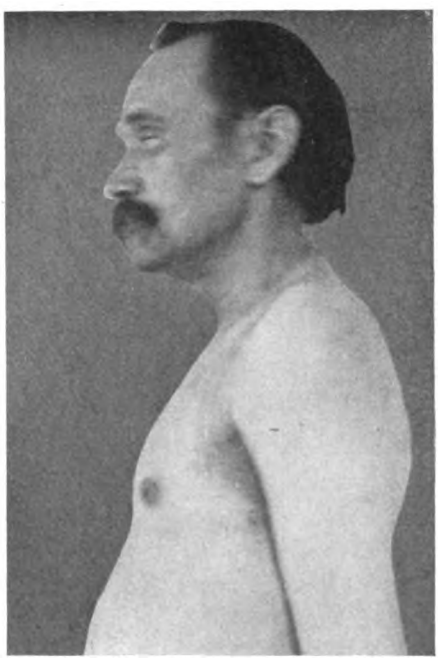

FIG. 424.—VIEW OF CASE OF TUBERCULOSIS OF THE SHOULDER-JOINT FROM OUTER SIDE, TO BE COMPARED WITH NORMAL SHOULDER SHOWN IN FIG. 425.

Note the atrophy of the deltoid from disuse, causing the acromio-clavicular articulation to become prominent; and also observe the fullness below the coracoid process, due to the thickening of the joint capsule, etc.

In scurvy (scorbutus) there is usually a history of an absence of some normally necessary factor in the diet, whether it occur in children or adults.

In children there is such marked soreness about the knees or ankles that they cry out with pain when lifted, and a condition of pseudo-paralysis results from inability to use the limbs. In adults the joint swelling is the most marked feature, and there is pain over the affected tibia or

femur. As in children, the knee- and ankle-joints are most often involved.

In both children and adults the most important diagnostic sign is the spongy, swollen, bleeding gums, a foul breath, and a tendency to subcutaneous hemorrhages.

Prompt improvement follows proper diet. Epistaxis is frequent in adults, and there is general anemia. The vast majority of hemorrhages occur in the knee, and most frequently in men. In purpura rheumatica the subcutaneous hemorrhages (Fig. 442) are usually a deciding factor, as is also the fact that many joints are usually involved.

In the chronic form a scorbutic or hemophiliac joint may resemble a tuberculous arthritis, but there is usually some rise of temperature in the latter (99° to 99.5° F. in the afternoon). The course of a tuberculosis is also more progressive, and there are never any sudden exacerbations or remissions. When ankylosis exists the differentiation from chronic rheumatic or tubercular joints is impossible, without a complete history.

Tumors of Joints.

These are very rare, and are chiefly benign in character, although a few cases of sarcomata of the larger joints (Fig. 408) have been observed. The most common of the benign forms are the joint lipomata first described by Volkmann in 1875.[1] These cases are true lipomata, usually developing beneath the synovial membrane, *i. e.*, extraarticular. They differ from a condition known as lipoma arborescens, in which there is an excessive deposit of fat in the normal joint villi. Both of the conditions just referred to occur most frequently in the knee-joint, but cases of its occurrence in the elbow and ankle have been described.

The tumor extends into the joint, either carrying the synovial membrane or breaking through the latter. The principal symptom in these cases is a painless enlargement of the joint. The swelling is soft and doughy.

Neuralgic or Hysterical Joints.

This form of joint affection is found in neurotic persons, and may simulate genuine disease. The conditions may follow an insignificant injury, usually of the hip or knee, but it may appear in any joint after an injury and be made the basis for damage suits. Any attempt at movement causes great pain.

The joint motions are apparently restricted in all directions, but if the patient's attention is diverted or if he is anesthetized, all limitation of movement disappears.

[1] Biochitzky: "Beiträge zur klinischen Chirurgie," vol. xxiii.

The joint is often swollen and sensitive, as well as fixed. Intermittent hydrops may occur in such joints. In cases of long duration there is some atrophy of the muscles above and below the joint (Figs. 258 and 259), as a result of non-use. There is seldom any rise of local temperature, but even this may exist.

Accompanying the joint symptoms are other signs of hysteria both in children and adults, and in men as well as in women.

DISEASES OF THE INDIVIDUAL JOINTS.

The clinical picture of both acute and chronic arthritis possesses certain variations according to the joint involved. These depend upon the relations of the capsule to the overlying parts, as well as upon the accessibility of the individual joint to direct manipulation. For example, the capsule of the knee-joint lies so close to the surface and extends over so great an area, that the recognition of changes both within and external to the joint is much easier than is the case with such articulations as the shoulder and hip. In the case of the shoulder but little of the capsule lies close to the surface, while in the hip, the depth of the joint prevents any direct recognition of changes.

It is therefore important to be able to search for certain clinical characteristics of each individual joint.

The following table may be of some assistance:

	Swelling First Appears.	Pain.	Most Characteristic Position.
Shoulder	Anteriorly between coracoid and head of humerus.	Over joint and along arm.	Adduction.
Elbow	On both sides of olecranon.	Over joint.	Flexed at acute or right angle.
Wrist	On dorsum.	Over joint.	Slight flexion.
Finger-joints	On dorsum.	Over joint.	Flexion.
Sacroiliac	On back of joint.	Over joint and along back of limb.	No change.
Hip	Invisible until later, then in front.	Over joint and to knee.	Varies according to stage (p. 634).
Knee	On all sides of patella.	Over joint.	Flexion, later subluxation of tibia.
Ankle	Over front of joint and below malleoli.	Over joint.	Flexion.
Tarsal joints	Invisible.	Over joint.	No change.
Toes	On dorsum.	Over joint.	Flexion.

Shoulder-joint.

Acute arthritis, exclusive of the traumatic form, is infrequent in this articulation, and has no special characteristics. The most com-

mon forms of chronic inflammation are tuberculosis, rheumatism, arthritis deformans, and syringomyelia, as well as the various forms of post-traumatic ankylosis.

Tuberculosis of the shoulder-joint is a comparatively rare affection. It begins insidiously with pain on motion and there is a dull aching pain when the limb is at rest. The pain is often neuralgic in character, and is always worse at night. The shoulder appears fuller in front, between the coracoid and humerus, and there is usually marked atrophy of the deltoid, so that the acromion is quite prominent. The arm is adducted to the side of the body. Abduction, both active and passive, is difficult, and accompanied by pain. When suppuration occurs, the sinuses appear in the axilla and over the front and back of the joint. There is usually no difficulty in distinguishing a subdeltoid bursitis from an arthritis of the shoulder. The two may however coexist, especially in tuberculosis.

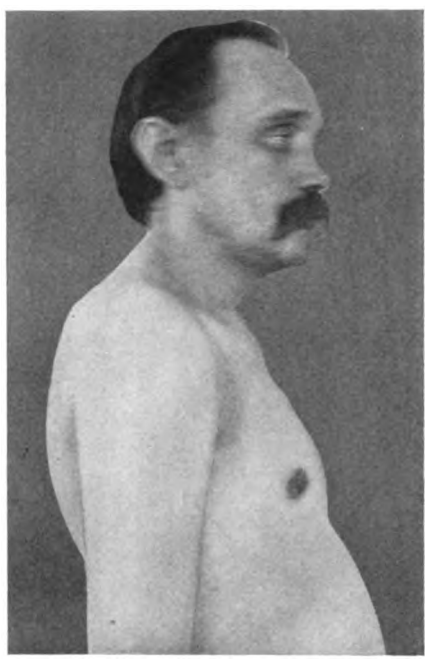

FIG. 425.—VIEW OF NORMAL SHOULDER FROM OUTER SIDE.

To be compared with Fig. 424. (Case of tuberculosis of the shoulder-joint.) Observe the depression below the coracoid process on the normal side, as compared with fullness on the diseased side.

ELBOW-JOINT.

The majority of forms of acute and chronic arthritis of this joint are accompanied by effusion and changes in the capsule. The swelling is most marked on either side of the olecranon process, and the early atrophy of the muscles of the arm and forearm, gives the joint enlargement a spindle-shaped appearance. If the effusion is extensive, fluctuation may be easily elicited over the back of the joint. The joint is held rigid in a flexed position, either at a right or an acute angle. Pronation and supination are greatly limited. If the tuberculosis is limited to the head of the radius, there is marked absence of rotary power and localized swelling. Sinuses are most apt to be found upon the posterior and lateral aspects of the joint.

WRIST-JOINT.

This joint lies so superficially that but little effusion is required to obliterate the normal depression upon the back of the wrist. The most common affection of the chronic variety is tuberculosis. In this there is swelling on the back of the wrist. The wrist-joint is stiff, and any movements are accompanied by pain. The hand is held flexed on the forearm. As in the case of the other joints, the degree of swelling can be

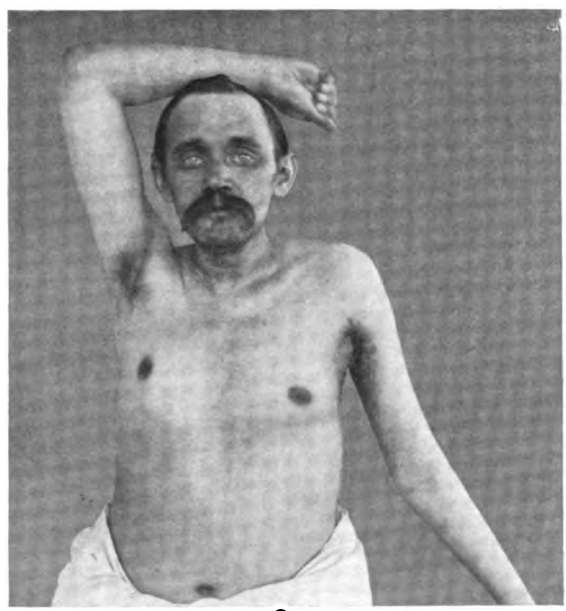

FIG. 426.—TUBERCULOSIS OF THE SHOULDER-JOINT, SHOWING THE LIMITATION OF MOTION ON THE DISEASED SIDE, AND CHARACTERISTIC ABDUCTION DEFORMITY.

On the normal side the arm could be raised up easily to the level of the head; on the diseased side it could only be voluntarily abducted from the body about forty-five degrees.

estimated by comparing its circumference with the joint of the opposite limb.

FINGER-JOINTS.

These are frequently the seat of acute rheumatic arthritis and of gouty and chronic rheumatic arthritis, as well as of arthritis deformans. Tuberculosis may occur independently of an osteomyelitic focus, but is usually associated with the latter (Fig. 398). The swelling is always more distinct on the dorsum. In acute forms the position is one of extension, while in the chronic forms flexion and lateral deviation are more common.

Special attention must be called to a form of septic arthritis, caused by a bite, the teeth entering the metacarpo-phalangeal joints while they are flexed. They run a subacute course and are often overlooked, the case being treated as one of ordinary subcutaneous phlegmon.

Sacroiliac Joints.

This occurs very rarely, and usually in young adults. Tuberculosis is practically the only form of disease of this joint.

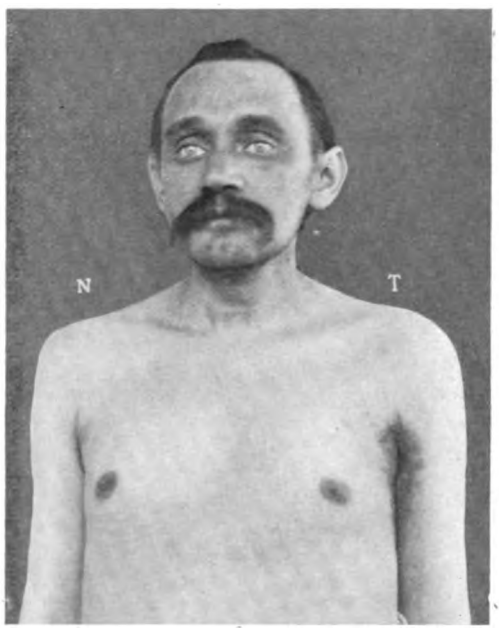

Fig. 427.—Anterior View of Case of Tuberculosis of the Shoulder-joint.

N, Normal shoulder-joint; T, tuberculous. Note the prominence of the diseased side.

Pain is felt by the patient over the articulation, which is often worse at night. The joint is also sensitive to pressure. The pain radiates down the thigh, and is increased when the patient sits down. The patient attempts to step as lightly as possible upon the toes of the diseased side, so that limping is quite marked and the pelvis compensatorily lowered. There is often swelling to be seen and felt posteriorly over the articulation. When the ilium is grasped on the diseased side and attempts made to move it, the pain in the joint is greatly increased. Abscesses open either posteriorly or burrow along the pelvic fascia to open in the lumbar or gluteal regions, in the ischiorectal fossa, or even in the inguinal region.

Disease of this articulation must be differentiated from lumbago, sciatica, from hip-joint disease, and tuberculosis of the sacrum or vertebræ. It can be differentiated from lumbago by the fact that the pain is higher up and is not localized, as in sacroiliac disease. In sciatica the predominant symptoms are pain over the sacrosciatic notch, which radiates down the back of the thigh and then into the foot. There is no tenderness over the sacroiliac joint, and the patient does not hold the pelvis rigid or cry out with pain when the ilia are pressed together.

From tuberculosis of the spine sacroiliac disease can be distinguished by the fact that one or more of the spinous processes are prominent, and there is marked reflex rigidity higher up than is the case in sacroiliac disease when movement is attempted.

From coxitis it can be differentiated by the presence of rigidity, when attempts are made to carry out movements of the hip-joint. The pain is felt in the hip or knee, and not over the sacroiliac joint. In diseases of the latter joint, when the pelvis is fixed, all movements of the hip are free.

In advanced cases of hip-joint, sacroiliac, and Pott's disease, when many sinuses are present it is often impossible, before operation, to state the primary source of the pus.

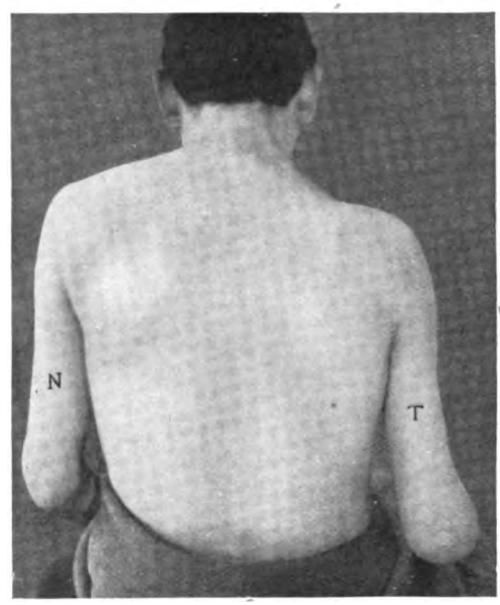

FIG. 428.—POSTERIOR VIEW OF CASE OF TUBERCULOSIS OF THE ELBOW-JOINT.

N, Normal arm; T, tuberculous. Note the characteristic obliteration of the depressions on either side of the olecranon process. (See Fig. 429.)

DISEASES OF THE HIP-JOINT (COXITIS).

Acute affections of this joint are infrequent. The acute arthritis following an osteomyelitis of the upper end of the femur in children has already been referred to (page 579) and will be taken up later under the head of differential diagnosis of tuberculosis of the hip. Acute arthritis of the joint occurs during all of the infectious diseases mentioned as causing arthritis (see page 602). The diagnosis in such cases can be made (*a*) from the history of the primary infection; (*b*) from the presence of severe pain referred to the hip or knee; (*c*) from the marked limitation of movement of the joint, the reflex muscular spasm causing almost absolute fixation; (*d*) from the presence of fever and other signs of acute inflammatory reaction.

In some cases the patients are not seen during the acute stage of coxitis. The surgeon is consulted on account of a deformity resulting from it. This may be either in the shape of an ankylosis or of a dislocation. The diagnosis in either case rests upon the objective findings taken in

conjunction with the previous history. Such apparently spontaneous dislocations following an acute coxitis have been reported after typhoid, scarlatina, acute rheumatism, influenza, etc.

Another form of acute coxitis to be mentioned is that resulting from gonorrhea. As is the case in all of the forms of metastatic gonorrheal arthritis, there is an early tendency to marked ankylosis. It is most apt to occur in young adults.

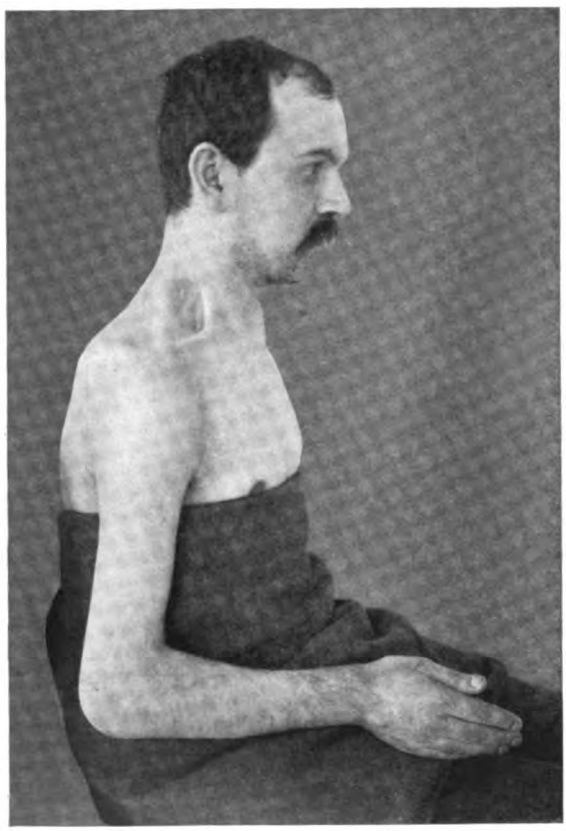

FIG. 429.—TUBERCULOSIS OF THE ELBOW-JOINT.

Note the depressed scar in the supraclavicular region following an operation for tuberculous lymph-nodes of the neck. This was probably the primary infection, having preceded the elbow-joint disease by five years. (See text.) Observe the characteristic flexion of the elbow, which occurs in all diseases of the elbow-joint, the forearm and hand being held in a position of half supination and half pronation. Observe the prominence on the outer aspect of the elbow-joint, replacing the normal depression between the olecranon and the external condyle.

The most important disease of the hip-joint is tuberculosis. It is the one from which the majority of the acute forms must be differentiated, both at the time of the onset and, if seen at a later period, after all of the acute symptoms have disappeared.

Tuberculosis of the Hip-joint (Tuberculous Coxitis).—The examination of a child or adult for the purpose of making a diagnosis of this common affection should be conducted in a more or less systematic manner, as follows:

1. *Detailed history of the case.*

2. *Inspection.* To determine (*a*) the presence of lameness; (*b*) the position in which the limb is held, *i. e.*, its attitude during walking, standing, or upon lying down.

3. *Palpation.* To determine (*a*) whether there is fixation of the joint,

i. e., limitation of its normal movements; (*b*) whether any swelling is present; (*c*) whether tapping upon the trochanter or knee causes pain.

4. *Measurement.* To determine the presence of muscular atrophy and of shortening.

5. *X-ray examination.*

1. **History.**—This should include not only the mode of onset, but also whether there is any tuberculosis in the family, or evidences of recent or old foci elsewhere in the patient. The usual history of the mode of onset is that it has been gradual.

In but few cases does the disease begin suddenly. There is not infrequently the history of a fall upon the trochanter or of other injury to the limb. The first symptom noticed by the parents is that the child begins to limp, and the hip is held a little rigid. In addition the child complains of pain in the hip or in the knee, which is increased by any movement of the affected limb. Often these pains are increased at night, so that the child awakens from a sound sleep with an outcry of sudden pain. Intelligent parents will often give such a history of gradually increasing lameness, stiffness of the hip, and pain that the attention of the surgeon is at once attracted to this joint.

FIG. 430.—APPEARANCE OF HANDS IN ACUTE RHEUMATIC POLYARTICULAR ARTHRITIS.

2. **Inspection of the Limb.**—This will give much information, and the child should be thus examined, if possible while standing, walking, and lying down, being stripped of all superfluous clothing. The child is seen to limp, resting as little weight as possible upon the toes of the diseased limb. The pelvis is elevated upon this side, so that the limb appears shortened. When the two anterior superior spines are outlined on the skin, this compensatory tilting of the pelvis can be well seen. Inspection will further reveal any changes in the attitude of the limb. This is a very common and prominent symptom,

and is due to the reflex muscular spasm. It is inadvisable to divide tuberculous coxitis into three stages according to the position of the limb, for the reason that these are so inconstant as to lead to much confusion. This is especially true of the early stage. In the early period the limb is usually abducted and rotated outward, but not always flexed. In the later stages the attitude of the limb is far more uniform. At such time there is marked adduction, internal rotation, and flexion. The limb in the early stages appears to be shortened, but, as

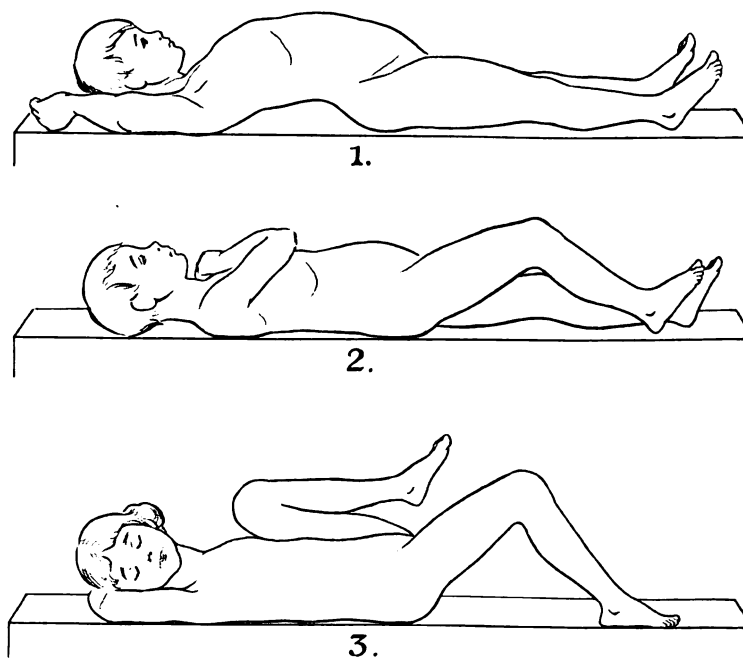

FIG. 431.—VARIOUS POSITIONS IN HIP-JOINT DISEASE (Edmund Owen).

1, Compensatory lordosis in hip-joint disease; 2, method of estimating degree of flexion of the hip, when back touches table; 3, amount of fixation of hip-joint. The normal left limb can be flexed upon the abdomen; the diseased limb forms the angle shown in the figure.

has just been explained, this is the result of tilting of the pelvis. In the later stages the shortening of the limb is genuine, due to actual loss of bone substance.

Abduction of the limb causes the pelvis to be raised, while adduction results in its being lowered. The flexion of the joint causes a compensatory lordosis, and the degree of flexion can be readily estimated.

3. **Palpation for Limitation of Motion, Location of Pain, and Swelling.**—Palpation yields much information of diagnostic value.

The child should be laid upon a firm couch or table and the range of motion upon the healthy side first ascertained, as this will often clear up the question as to whether any rigidity is due to the child being frightened.

The suspected limb should be held at the knee with one hand while the other grasps the pelvis close to the hip (Fig. 327). The examination should determine whether there is any limitation of abduction or adduction of the limb. When this movement is limited, the pelvis moves with the diseased limb. The degree of flexion can either

FIG. 432.—METHOD OF TAPPING KNEE TO DETERMINE TENDERNESS IN CASES OF SUSPECTED HIP-JOINT DISEASE.

The patient's knee-joint region is allowed to rest upon the surgeon's left or right hand, as the case may be, while the opposite hand taps upon the region of the patella.

be determined while the patient is lying upon the back (Fig. 430) or upon the abdomen. Under normal conditions a child lying upon its back shows only a slight amount of lordosis of the lumbar portion of the spinal column (Fig. 432) when the limb is fully extended. In hip-joint disease a marked lordosis will appear (Fig. 430) when attempts are made to extend the limb. The degree of flexion can be roughly determined by allowing the lumbar spine (Fig. 432) to touch the table. Such a test cannot be used where much pain exists. If the patient lies upon the abdomen the amount of flexion can be de-

termined by placing the hand upon the sacrum and alternately raising the affected and the normal limb. In case there is limitation of inward and outward rotation, the thigh is flexed to a right angle while one hand grasps the knee. Efforts are then made to turn the femur outward and inward. In the early stage of hip-joint disease, the motions which are limited are abduction, hyperextension, and rotation. In the later stage, the motions are limited in all directions.

Location of Pain.—Palpation is also utilized to determine the presence of pain and of swelling. Referred pain, however, may not be present at any stage of the disease, and is not nearly so valuable a diagnostic sign as the others mentioned here. When present, pain is usually felt on the inner side of the thigh, close to the knee-joint. Pain

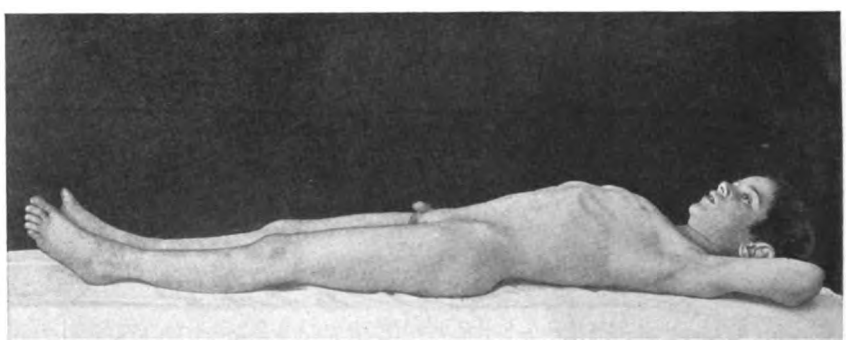

FIG. 433.—NORMAL DEGREE OF LORDOSIS OF SPINE
Note the slight forward curvature in lumbar region of a child lying in normal supine position.

in the joint itself is less constant. There is often sensitiveness to pressure over the trochanter and when the knee is gently tapped (Fig. 431). Pain is also quite marked upon pressing deeply over the front and back of the joint.

Swelling.—There is often a distinct thickening to be felt over the head of the femur at Scarpa's triangle or behind the trochanter. This sign is very difficult to elicit, especially in the more acute cases. There is at times enlargement of the inguinal glands below Poupart's ligament. Abscesses usually appear over the front of the joint, but may gravitate toward the trochanter or downward toward the knee. Similarly, sinuses may be present at any point.

4. **Measurements of the Limb for Shortening and Atrophy.**—The apparent shortening referred to, as existing in the early stages can

be ascertained by the methods of measurement of the limb as described on page 493. Later in the disease, this same measurement reveals an actual shortening, varying according to the amount of destruction of the head and neck.

The presence of atrophy even at an early stage is a diagnostic sign of considerable value in this disease. The degree of muscular atrophy is ascertained by measuring the circumference of both limbs at the middle of the thighs (Fig. 434) and middle of the legs (Fig. 435).

In the later stages a rectal examination should never be omitted, for evidences of perforation of the acetabulum, with resultant intra-pelvic inflammatory induration and abscess formation.

5. **X-ray Examination.**—As was stated in the consideration

FIG. 434.—METHOD OF DETERMINING THE CIRCUMFERENCE OF THE THIGH AT ITS MIDDLE. (See text.)

of the diagnosis of joint diseases in general, this mode of examination can only be utilized at such a late period in tuberculous arthritis, that a diagnosis is possible in the majority of cases without it. This is especially true of the hip-joint, where the destruction of bone must be fairly extensive before it will show in a skiagraph.

Differential Diagnosis.—1. *Pott's Disease* (*Tuberculous Spondylitis*).—A tuberculous lumbar spondylitis may greatly resemble hip-joint disease, owing to the limb being held in a rigidly flexed position. There is, however, no limitation of the motions of rotation, abduction, or adduction of the hip. When attempts are made to extend the hip no compensatory lordosis appears, the spine being held rigid. This latter symptom of spondylitis is more distinctly brought out when

the child is asked to sit up, after lying upon the back. It will employ every effort to raise and support itself by the use of the hands, in order to keep the inflamed lumbar spine rigid. The pains are referred to the spine or along the lower abdominal nerves, and are usually symmetrical.

2. *Chronic Arthritis Deformans* (*Morbus Coxæ Senilis*).—This might come into question in elderly patients more often than in children, in whom it is infrequent. There is marked crepitation when the hip is rotated. The movements are only slightly limited. The *x*-ray would show bony hypertrophy.

3. *Acute Osteomyelitis of the Upper End of the Femur.*—The pain is far more acute than in tuberculous coxitis, there is high fever, and

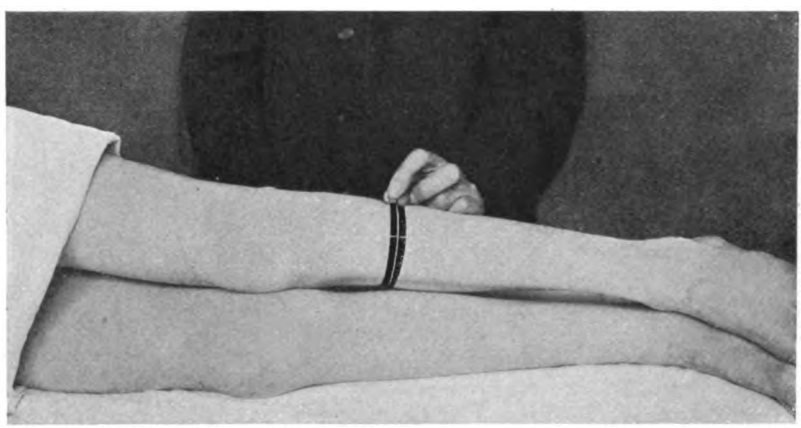

FIG. 435.—METHOD OF MEASURING THE CIRCUMFERENCE OF THE LOWER LIMB AT THE LEVEL OF THE MIDDLE OF THE CALF. (See text.)

much swelling about the hip. There are other signs of general infection, such as a rapid pulse, leukocytosis, and often delirium. The destruction of the bone is rapid, and abscess formation and shortening occur at an early period.

4. *Rheumatic and Other Forms of Primary and Secondary Arthritis.*—In these the history of the previous infection is of the utmost importance, since the symptoms greatly resemble those of tuberculous coxitis. They can be distinguished from the latter only by their shorter course and the previous history.

5. *Coxa Vara.*—The differential diagnosis of this affection is considered on page 647.

6. *Neoplasms of the Head of the Femur.*—Both carcinoma and sarcoma of distant organs may be followed by metastatic deposits

in the head of the femur and simulate tuberculous coxitis, on account of the pain, rigidity, swelling, and shortening. In the case shown in Fig. 409 there was also evening rise of temperature. The diagnosis rests upon an accurate previous history, the examination of the remainder of the body for primary growths, and the *x*-ray.

7. *Inflammation of the Iliopsoas Bursa.*—This may also cause abduction, outward rotation, and flexion of the thigh, as well as pain radiating to the knee. Adduction and inward rotation are impossible without an anesthetic, while abduction and outward rotation are free. The

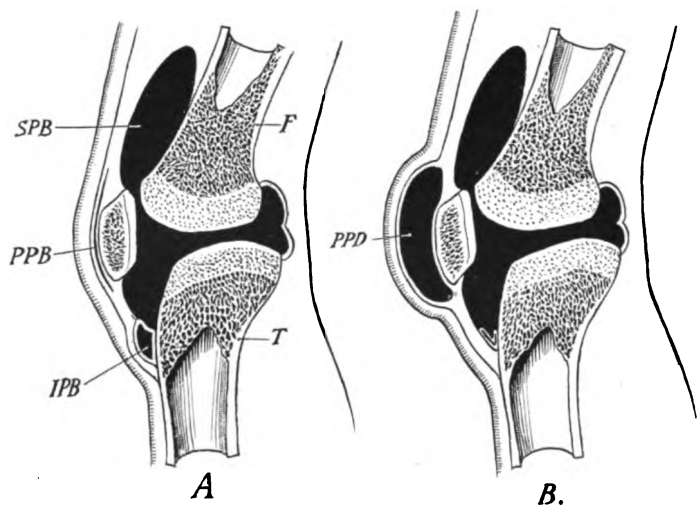

FIG. 436.—LOCATION OF VARIOUS COLLECTIONS OF FLUID IN THE VICINITY OF THE KNEE-JOINT

A, Effusion into the knee-joint, and suprapatellar bursa: *F*, Femur; *T*, tibia; *SPB*, suprapatellar bursa; *PPB*, location of prepatellar bursa; *IPB*, intrapatellar bursa. *B*, This illustration shows the simultaneous collection of fluid in the prepatellar bursa (*PPB*), and within the knee-joint itself.

swelling over the joint is more marked than in coxitis, and deep fluctuation can often be obtained.

Abscesses of this bursa may rupture into the hip-joint and vice versa.

DISEASES OF THE KNEE-JOINT.

No joint of the body is more frequently the seat of the various forms of acute and chronic arthritis than the knee. It will be unnecessary to repeat the chief diagnostic points of these affections, since in every case one must make the diagnosis by the process of exclusion outlined in the discussion of joint diseases in general. The local signs vary according to the nature of the process, *i. e.*, whether it be

acute or chronic, and again whether the effusion be serous, seropurulent, hemorrhagic, or purulent.

The following signs are common to the majority of the acute and chronic processes:

1. Pain in the knee and tenderness on pressure, especially along the lines of reduplication of the capsule.

2. Obliteration of the depressions on all sides of the patella. This may either be due to the presence of fluid in the joint itself or in the subcrural bursa, or it may be the result of thickening of the capsule or of a periarticular infiltration.

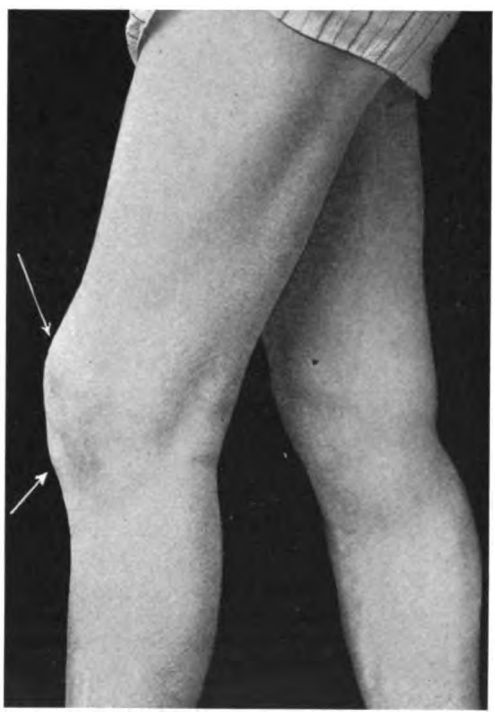

FIG. 437.—SIDE VIEW OF KNEE-JOINT IN A CASE OF ACUTE SYNOVITIS.

The arrows point to the spaces above and below the patella, which are depressions in the normal knee-joint, becoming obliterated and bulging as soon as fluid collects in the knee-joint.

3. Ballottement of the patella. This is to be found if only a small quantity of fluid be present. It is elicited either by tapping lightly on the patella or by placing the index-fingers upon it and exerting pressure. With either method the patella springs back again when the pressure is relieved. Fluid in the prepatellar bursa causes fluctuation in front of the patella, and the latter cannot be made to dance upon the fluid as is the case with an intra-articular effusion. In addition to this sign, the prominence is only over the patella, and there is but little, if any, obliteration of the normal depressions around the patella (Fig. 439).

4. The position or attitude of the limb. The knee in the more acute cases is held rigidly extended at first, but gradually flexion takes place. As the cartilages become eroded and the ligaments relaxed various deformities occur. These may be (*a*) extreme flexion; (*b*)

subluxation of the tibia (Fig. 417); (*c*) genu valgum or genu varum, or even genu recurvatum, *i. e.*, backward curvature or hyperextension.

5. Manipulation of the limb may reveal crepitus, either due to adhesions or fibrinous deposits or to erosion of cartilage. It may also show relaxation of the ligaments (Fig. 335) or enlargement of the articular ends of the bones.

6. In the acute and chronic suppurative processes, sinuses may form on all sides of the joint and lead by a tortuous route to the inside of the capsule.

The most frequent form of inflammation of the knee-joint or gonitis

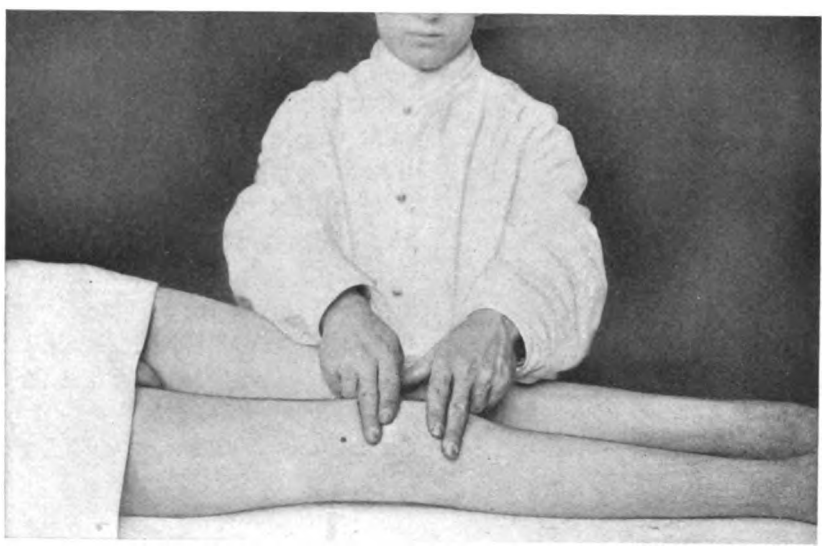

FIG. 438.—METHOD OF DETERMINING THE PRESENCE OF FLUID IN THE KNEE-JOINT, BY BALLOTTEMENT OR DANCING OF THE PATELLA ON THE UNDERLYING FLUID.

Two fingers are placed at the upper level of the patella and two at the lower, and alternately pressure is made. The patella can then be felt to be pushed back and forward, springing back, as it were, like a solid body when it is pressed upon while lying in water.

is the tuberculous, and brief reference must be made to its chief diagnostic features.

Tuberculosis of the Knee-joint (Tuberculous Gonitis).—This may occur in those who are enjoying apparently the best of health, as well as in those who have marked evidence of tuberculosis elsewhere. Some cases apparently follow a trauma. In the majority of cases, however, such an injury is a very remote one, and has little to do with the development of the process. The more important symptoms of diagnostic value are swelling of the joint, tenderness on pressure, pain, fixation, atrophy, local heat, and, later in the disease, deformities.

1. *Swelling.*—This is usually most marked on either side of the patella. When muscular atrophy of the thigh and leg takes place the limb assumes a typical spindle shape (Fig. 438). The swelling has a semifluctuating or elastic consistency, due to the granulations within the joint and to the infiltration of the capsule and periarticular tissues. It is the action of the latter upon the overlying skin, causing it to be glazed and anemic, which gave this form of tuberculosis the old term of "tumor albus."

If the joint contain either a serous or purulent effusion as the result of the tuberculous process, there is more distinct fluctuation, the space above the patella is filled out, and the patella itself shows the phenomenon of ballottement. If such a joint effusion recurs from time to time and exploratory puncture shows it to consist of fibrin or to contain rice bodies it should be regarded as strongly suspicious of tuberculosis. In some cases the diagnosis may be made if a palpable thickening of the capsule remains after the fluid has disappeared.

FIG. 439.—ANTERIOR VIEW OF A CASE OF ADVANCED TUBERCULOSIS OF THE KNEE-JOINT (LEFT).

Observe how the depressions normally existing on all sides of the patella have been obliterated, especially that above the patella corresponding to the seat of the suprapatellar bursa.

2. *Pain, Tenderness, and Local Heat.*—There is but little pain, except in the more acute cases, and the same is true of local heat. Tenderness is present especially over the upper end of the tibia. The more acute the process, the more marked are the local pain, heat, and tenderness.

3. *Rigidity, Atrophy, and Deformity.*—The patient walks with a decided limp, the knee being held rigid. The muscular fixation is not so great as in the hip-joint, and many cases permit of quite free manipulation. Muscular atrophy appears early and is usually quite marked. The position is at first that of mild flexion, the leg being rotated slightly outward. As the process advances the flexion deformity becomes more marked and may be accompanied by subluxation of the tibia, the latter lying in a plane behind that of the femur (Fig. 418). An enlargement of

the lower end of the femur and a genu valgum position is also frequently found in advanced cases.

4. *Abscess, Sinus Formation, and Fever.*—As a rule, there is only a slight rise of the evening temperature, 99° to 100° F., but in some cases, the formation of pus not only manifests itself by an increase in severity of the local symptoms, but also by a considerable rise in the general temperature, at times to 103°. In such cases one often questions the possibility of the process being of a tuberculous nature without the history of its gradual onset, the presence of the disease elsewhere in the patient himself or in his family, and lastly the fact that the capsule feels much thicker than is the case in an ordinary acute arthritis.

Abscess formation may also occur from extraarticular foci. These are usually found as quite localized, distinctly fluctuating swelling over the tibia or one of the condyles. Sinuses may be present on all sides of the joint.

5. X-ray shows erosions of cartilage and foci in bones.

FIG. 440.—LATERAL VIEW OF SAME PATIENT SHOWN IN FIG. 438.

Illustrating the characteristic flexion deformity, and the prominence of the suprapatellar bursæ.

Differential Diagnosis.— 1. From some of the acute forms of arthritis. The resemblance of some cases of acute pus formation in tuberculous knees to other forms of acute arthritis has just been referred to. Of these latter there are some which require special mention, viz., acute gonorrheal or gonitis, the acute forms of hemophiliac gonitis and some cases of monarticular acute rheumatism (Fig. 442). These can only be differentiated by the history of gradual development in tuberculosis, followed by acute symptoms. In the gonorrheal form the history and local examination of the urethra will clear up the diagnosis. In the hemophiliac arthritis there is not so much pain or tenderness or fever, and exploratory puncture reveals blood. The history will also be of the greatest aid. The monarticular rheumatic arthritis yields readily to appropriate treatment and is at times accompanied by a purpuric skin eruption (Fig. 442).

Both in children and adults a swelling of the knee-joint may persist for a long time after an injury. It may disappear and then recur as described on page 614, the question often arising as to whether the process is a tuberculous one. In children, effusions which persist for a considerable period after an injury, must be looked upon with suspicion. In adults such a chronic, often recurrent effusion, if tuberculous, is apt to be accompanied by the capsular thickening and other signs just described.

Other conditions which must be considered in the differential diagnosis are arthritis deformans, tabetic arthropathy, sarcoma of the

FIG. 441.—CHARACTERISTIC FLEXION DEFORMITY IN A CHILD SUFFERING FROM TUBERCULOSIS OF THE RIGHT KNEE-JOINT.

Note the swelling above and below the patella, and the absence of normal depressions.

femur and tibia, lipomata of the joint and hysterical joints, as well as diseases of the periarticular bursæ (page 566).

DISEASES OF THE ANKLE-JOINT.

The acute forms of arthritis require no special mention, the most frequent of these being due to acute rheumatism, gonorrhea, and to trauma. Of the chronic forms those due to tuberculosis and tabes are of chief interest. The tabetic joints occur frequently enough in middle life to lead to errors in diagnosis. The local signs of the disease, viz., enormous enlargement of the joint, abnormal mobility in all directions, without pain and marked crepitation, combined with the more general evidences of tabes, serve to make the diagnosis comparatively easy.

Tuberculosis of the Ankle-joint.—1. Swelling. As in all effusions into the ankle the first evidences are seen by a fullness of the depressions over the front and later along the lateral aspects (below the malleoli and behind the joint). The swelling has the same elastic consistency as in diseases of the knee-joint, soon giving rise to the typical spindle-like shape, through atrophy of the leg muscles.

2. Gait and position of foot. The patient walks very lame, the foot is held in an extended and somewhat adducted position. The ankle is held rigid.

3. Pain and tenderness. Pain is present at an early stage and causes marked lameness, so that the patient steps very lightly on the diseased foot. There is tenderness on pressure over the entire joint. Attempts at movement of the joint and pressure of the foot against the leg cause great pain.

FIG. 442.—PURPURA RHEUMATICA ASSOCIATED WITH ENLARGEMENT OF THE LEFT KNEE-JOINT OF A RHEUMATIC NATURE.

Differential Diagnosis.—The principal conditions from which tuberculosis of the ankle-joint must be differentiated are the chronic forms of arthritis of this joint following injury and tuberculosis of the tarsal joints. In the chronic traumatic form there is an absence of the peculiar boggy elastic swelling, there is much less pain, and if tenderness is present, it is not so diffuse.

Tuberculosis of the Tarsal Joints (Medio-tarsal and Tarso-tarsal).—In many cases if sinuses are present and the foot is uniformly swollen a differentiation is impossible. In general, however, the pain, tenderness and swelling are in the anterior and middle portions of the foot and over the particular joint involved, while the movements of the ankle-joint proper are free and painless.

In primary tuberculosis of the os calcis there is swelling behind

the ankle-joint only. The bone itself is thickened and tender, and, if sinuses are present, the probe encounters rough bone.

DEFORMITIES.

Congenital Dislocations.

Of the Hip.—This occurs most often in female children, and the attention of the physician or surgeon is seldom drawn to the condition until the child begins to walk. At such a time the gait of the child resembles the waddling mode of locomotion of a duck. This is most marked if the affection is a bilateral one. If it is present on one side only, the child seems to suddenly sink when stepping upon the foot of the affected side. This sudden shortening of the limb is due to the fact that the head has no fixed point, as is the case with the normal head in the acetabulum. It slides up on the ilium when the child rests its weight on the affected limb and causes this marked limping.

Fig. 443.—Double Congenital Dislocation of Hip (from a photograph in the collection of Dr. J. E. Moore).

The most important diagnostic signs are:

1. A waddling gait in bilateral, and the characteristic limp or sudden shortening in unilateral dislocations.

2. The trochanter lies above the Roser-Nélaton line, as in a traumatic dislocation, but it can be pulled down by force.

3. The limb is shortened, as compared with its fellow, in unilateral dislocations. This varies from 1 to 3 cm. in children one to two years of age to 8 cm. in older ones.

4. On deep palpation one can usually feel the head of the femur upon the dorsum ilii. This is best done when the child lies upon its

back and the limb is rotated with one hand, while the other grasps the head. The head can be pulled down by traction upon the limb.

5. The Trendelenburg sign. When a normal child stands upon either limb and flexes the other at the knee and thigh, the opposite buttock will not be seen to drop. In the child with congenital dislocation, however, the opposite healthy buttock will be seen to drop when the child stands upon the affected limb so that the gluteal fold is at a lower level. This is due to the fact that the gluteal muscles upon the dislocated side are unable to perform their function of keeping the pelvis level.

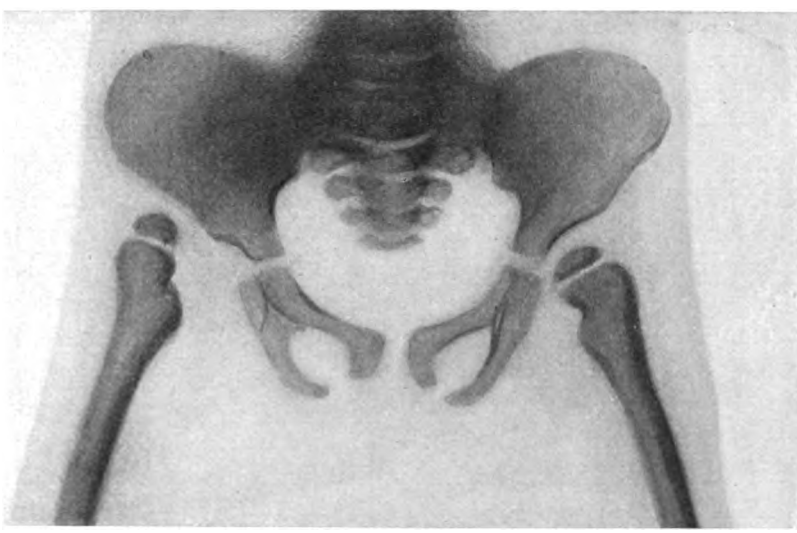

FIG. 444.—X-RAY OF CONGENITAL (RIGHT-SIDED) DISLOCATION OF THE FEMUR AT THE HIP-JOINT.

6. There is a marked lordosis and scoliosis toward the affected side. If the lesion is bilateral the lordosis is very striking.

7. The *x*-ray examination is of great value, especially in young infants who are quite fat, the head and trochanter being difficult to palpate (Fig. 444).

Differential Diagnosis.—*Coxa Vara* (see page 648).—In this affection the head cannot be felt in an abnormal position. It resembles congenital dislocation in the fact that the limb is shortened and that the trochanter lies above the Roser-Nélaton line. Coxa vara is seldom observed at as early an age as a congenital dislocation. There is also an absence of the freedom of motion seen in the latter affection. In coxa vara there is marked limitation of abduction and of inward

rotation. In case of any doubt a skiagraph will clear up the diagnosis.

Paralytic Flail Joint (*Paralytic Dislocation*).—In this condition there is also displacement of the head, the trochanter lies above the Roser-Nélaton line, and there is lumbar lordosis. There is usually evidence in the thigh and leg of extensive paralysis, and atrophy or shortening (Fig. 450).

Dislocation Following Arthritis of the Hip.—The symptoms of the spontaneous forms of dislocations of the hip, following some of the infectious diseases, resemble those of the congenital form in almost every particular. There is, however, usually a history of the primary affection, and the fact that before the onset of the latter, the patient was able to walk perfectly. The motions of the hip are also not as free as in the congenital form.

Congenital Dislocations of Other Joints.—Congenital dislocation of the knee is not frequent, only ninety-eight cases having been reported. It is regarded by some authors as a genu recurvatum or a hyperextension, rather than a displacement. It is, however, to be looked upon as a true dislocation, and is frequently double.[1] The leg is usually displaced forward, so that the condyles of the femur project in the popliteal space.

Congenital Dislocation of the Patella.—This is also infrequent. The displacement is usually outward, as in one of the varieties of traumatic dislocation. In this connection may be mentioned the rare occurrence of congenital absence of the patella, which can be recognized by the knee being broad and flat and very much impaired in function.

Congenital Dislocation of the Shoulder.—This is very rare. In the majority of cases reported as such it was due to relaxation of the joint (following the form of paralysis described on page 437) owing to tearing of the upper roots of the brachial plexus (Fig. 271). In others it is due to separation of the epiphysis.

Coxa Vara.

The attention of the profession was first called to this interesting deformity by E. Müller[1] in 1888, and the name coxa vara given to it by Hofmeister in 1894. It may be defined as a bending downward (Fig. 445) of the neck of the femur sufficiently to cause symptoms. The neck may form a right, or even an acute, angle with the shaft.

Clinically it is seen most often in males during adolescence and less frequently in children.

[1] "Zeitschrift für orthopedische Chirurgie," vol. vii.

It is best divided into the following forms:

1. Congenital coxa vara.
2. Rachitic coxa vara of childhood.
3. Coxa vara of adolescence.
4. Traumatic coxa vara.
5. Inflammatory and trophic coxa vara (following osteomyelitis, arthritis deformans, osteitis deformans, osteomalacia). The symp-

FIG. 445.—X-RAY OF A CASE OF COXA VARA, TAKEN FROM THE PATIENT SHOWN IN FIGS. 446 AND 447.

Note the downward inclination of the neck of the femur on the side of the coxa vara (right), and the mushroom-like expansion of the head of the bone. On the left side the epiphyseal line between the head and the neck and between the greater trochanter and shaft respectively are well shown.

toms of all of these forms are the same, the division being according to the age at which it is first observed, and the etiology.

The form which requires especial mention in connection with its etiology is the traumatic. This term was first given to it by Sprengel in 1898.[1]

It follows either a separation of the epiphysis or an actual fracture of the neck of the femur in children and young adults. In the case of epiphyseal separation, as well as of fracture of the neck, the

[1] "Archiv für klinische Chirurgie," vol. lvii.

head of the bone becomes flattened or mushroom-like and the neck bent downward so as to lie below the level of the trochanter. The injury may be so slight as to be overlooked, until the resulting deformity appears. Reference has been made to the symptoms of fracture of the femoral neck in children (page 499) which may result, according to Whitman,[1] in coxa vara. The diagnosis of coxa vara of whatever origin depends upon the following clinical findings:

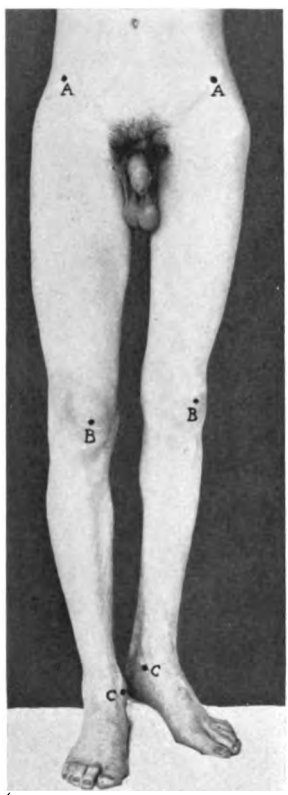

FIG. 446.—TYPICAL POSITION IN A CASE OF COXA VARA ADOLESCENTIUM.

This is the anterior view of the case shown in Figs. 445 and 447. A, A, Location of anterior superior spines of the ilium; B, B, the black point above these letters indicates the middle of the patellæ; C, C lower borders of internal malleoli. Note the shortening of the limb, the external rotation or eversion, and the prominence of the left trochanter.

1. *The History.*—The early symptoms depend upon the cause. In those due to trauma there may have been a slight or severe injury, followed by vague pains in the hip, and later the appearance of the deformity. In others there is a history, in adolescence, of gradually increasing pains in the hip and discomfort on walking.

2. *The Symptoms of the Deformity.*—(*a*) *Limitation of Motion.*—This is most marked in the direction of abduction and inward rotation, both of which are greatly restricted. The limitation of abduction is due to the pressure of the trochanter against the ilium, when the limb is abducted. The limitation of inward rotation is due to the fact that the neck of the femur is not only bent downward, but also backward in the majority of cases.

(*b*) *Attitude of the Limb.*—The limb is everted and adducted, except when the neck is bent forward. Under the latter conditions it is inverted.

(*c*) *Shortening.*—This is one of the most characteristic signs. There is genuine shortening as measured in the usual manner (Fig. 447). The trochanter lies above and a little behind the Roser-Nélaton line (Fig. 447), and is more prominent upon the side of the deformity. In children the shortening may be slight. There is also marked atrophy of the muscles of the thigh and gluteal region.

[1] "Annals of Surgery," 1900.

(*d*) *Gait and Pain.*—The patient stands upon the toes of the diseased side, the limb being adducted and rotated outward. He limps, and if the affection is bilateral there is a distinct waddling gait. There is also more or less pain in the hip, rarely in the knee, when walking. The Trendelenburg sign is also well marked in unilateral cases.

3. *X-ray Examination.*—This shows the extent of the deformity. The bend is most frequently downward and backward, less often downward and forward, and least often simply downward. The mushroom-like flattening of the head is also well seen.

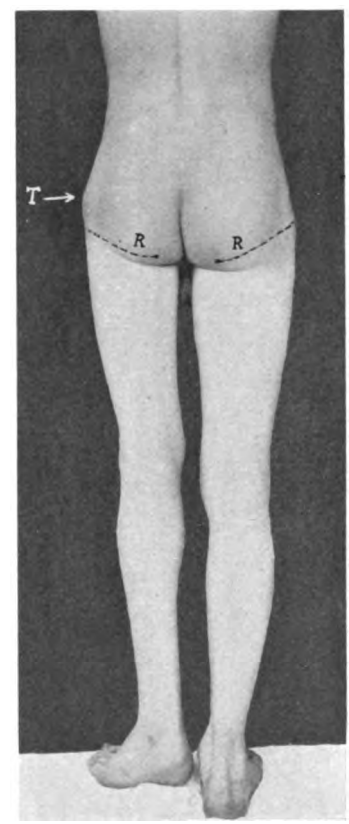

FIG. 447.—POSTERIOR VIEW OF A CASE OF COXA VARA ADOLESCENTIUM.

Same case as shown in Figs. 445 and 446. T, The arrow points to the prominent trochanter on the side upon which the coxa vara was situated: R, R, Roser-Nélaton line. Note how the trochanter lies above the Roser-Nélaton line on the side of the coxa vara. Also note the shortening and eversion of the limb.

Differential Diagnosis.[1]—It is almost impossible to differentiate cases of traumatic coxa vara from those of true coxa vara of adolescence except from the history. If the trauma has been slight, even this may be misleading.

From Tuberculous Coxitis.—Coxa vara never gives rise to abscess formation, while this is of frequent occurrence in tuberculous coxitis. The onset of coxa vara is more abrupt and acute than it is in the majority of cases of tuberculosis of the hip-joint. It is a self-limited disease, and sooner or later a spontaneous cessation of the acute symptoms may be confidently expected, while the opposite clinical tendencies characterize tuberculous coxitis. This, like tuberculous processes in other parts and organs of the body, is generally attended by a slight rise in the evening temperature, while the temperature in coxa vara remains normal. In the great majority of cases, tuberculous coxitis is a disease of childhood, and begins, in the large

[1] The author has taken many of the differential diagnostic points from the article of Dr. Nicholas Senn.

proportion of instances as a primary osteal affection in the proximal end of the femur. Its onset is insidious. The pain is referred to the inflamed joint, and radiates along the course of the obturator nerve to the inner condyle of the femur. During the early stage of the disease, the thigh is slightly flexed, abducted, and rotated outward. Nocturnal muscular twitching is almost a constant symptom; this is something which is never found in coxa vara. In tuberculous coxitis, muscular rigidity fixes the joint at an early stage. All movements are productive of pain, and light blows against the condyles invariably aggravate the pain. Tenderness, such a marked clinical feature in tuberculous and other inflammatory affections of the hip-joint, is never found in coxa vara. Shortening and outward rotation of the limb belong to the later stages of tuberculous coxitis, while in coxa vara they may even precede the painful or acute stage of the disease, and the shortening is always one of its early manifestations, usually combined with outward, and, in exceptional cases, with inward rotation of the limb. As a final diagnostic test in doubtful cases, the employment of the Röntgen ray will enable us to differentiate between the two affections (Fig. 444). In coxa vara, the downward bending of the femoral neck is almost characteristic, while in tuberculous coxitis the *x*-ray picture will either show the existence of a destructive process involving the proximal end of the femur, frequently complicated by coexisting or consecutive disease of the acetabulum, or it will show no change in the angle of the neck.

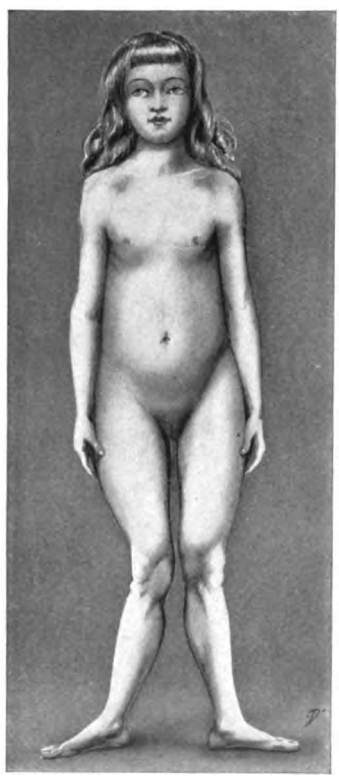

FIG. 448.—DOUBLE GENU VALGUM (Fowler).

Bilateral coxa vara is of more frequent occurrence than bilateral tuberculosis, in the relative proportion with which these two diseases are encountered in practice. Muscular atrophy is more marked in tuberculous coxitis than in coxa vara.

Arthritis Deformans.—The differential diagnosis between coxa vara and arthritis deformans, called senile coxitis, where it affects the

hip-joint, presents fewer difficulties. Coxitis senilis is a disease of advanced life.

Cases of senile coxitis are seldom met with in persons less than forty-five years of age.

In senile coxitis, the angle of the neck of the femur is not diminished. Arthritis deformans is not infrequently a polyarticular disease, while coxa vara is an affection which is only met with in the hip-joint. In senile coxitis, the head of the femur occasionally becomes elongated, but during the later stages the upper surface is deprived of its cartilaginous covering, and the exposed underlying bone becomes hardened and is polished by the limited movements of the joint. There is no pain, no cracking, or roughness elicited by joint motion as in well-advanced cases of senile coxitis. The shortening of the limb in senile coxitis is not caused by bending downward of the neck of the femur, but by loss of tissue of the head of the femur and the upper segment of the acetabulum.

FIG. 449.—BOW-LEGS (Moore).

GENU VALGUM (KNOCK-KNEE).

This may occur as a symptom of general rachitis in early life when the children first learn to walk (page 590). It also appears during adolescence (*i. e.*, between the twelfth and eighteenth years) as a static deformity. Genu valgum may also follow fractures of the femur and paralysis of the leg and thigh muscles.

The diagnosis in these varieties is not difficult. The chief features are:

1. An inward angular deformity (Fig. 448) at the knee-joint, which disappears when the leg is flexed upon the thigh.

2. When the leg is thus flexed the internal condyle is seen to be relatively prominent.

3. The gait is quite characteristic. It is a rolling one, the leg being thrown outward with each step forward.

The differentiation of either genu varum rachiticum or adolescentium from the paralytic or traumatic forms presents no difficulty. The presence of atrophied and paralyzed muscles will eliminate the paralytic form (Fig. 448), and the history of an injury will exclude the form following fractures of the femur or tibia or laceration of the internal lateral ligament of the knee.

Genu Varum (Bow-legs).

In this deformity the femur and tibia form an outward angle (Fig. 449). Like the corresponding inward angular deformity (genu valgum) it is most frequently the result of rachitis, and is one of the earliest evidences of the latter. It is seen even in children who have never attempted to stand. In later life a similar deformity appears as a symptom of osteitis deformans (page 592).

The distinctive features of the rachitic genu varum are: (1) The gait is a waddling one, the feet and knees being wide apart and the toes usually inverted; (2) the deformity is most marked in the femur and tibia when one is in the standing position (Fig. 449). In the minority of cases the bowing is either angular and chiefly in the lower third of the tibia, or there is a forward curving of the tibia and sometimes of the femur also. To the latter class the term anterior bow-legs is applied.

Fig. 450.—Marked Shortening of Right Lower Extremity Following Anterior Poliomyelitis in Infancy.

Note the pes equinus paralyticus position of the foot.

Deformities Caused by Anterior Poliomyelitis.

These are generally of three varieties: (*a*) Those due to trophic changes, resulting in atrophy of the bone with marked shortening of the limb (Fig. 450). In these cases there is an increased liability to spontaneous fracture. (*b*) Those resulting from muscular paralysis. These either cause contractures or flail joints. (*c*) Dislocations, either complete or partial.

The first class are not difficult to recognize, the only other causes

of a shortened limb being a fracture through the epiphyseal cartilage or a resection of the ends of one of the long bones. In both, the history, the absence of motor paralysis, and the other signs of poliomyelitis

FIG. 451.—TALIPES EQUINOVARUS (Moore).

will clear up the diagnosis. The deformities in the second class are the result of paralysis, which, as a rule, does not involve all of the muscles of the limb. In the thigh the muscles usually involved are those of the anterior and internal groups, resulting in a flexion of the hip and knee (Fig. 450). There is often a subluxation of the tibia backward and a marked genu valgum.

In some cases there is hyperextension of the knee, combined with flat-foot.

The most common deformities of the foot in their order of frequency are (*a*) talipes equinovarus; (*b*) calcaneo-valgus; (*c*) pes calcaneus or pes cavus.

The third form of infantile paralysis deformities is not frequent. The most common is dislocation of the hip.

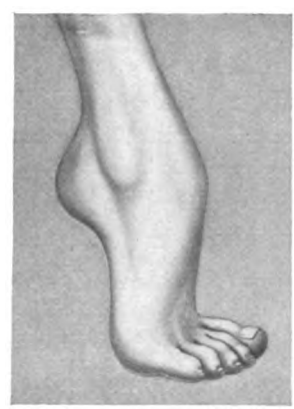

FIG. 452.—TALIPES EQUINUS (Fowler).

The diagnosis of all of these paralytic deformities depends upon the recognition of the primary disease, viz., poliomyelitis anterior. The onset is usually sudden, the paralysis is of the flaccid type, there is marked muscular and often bone atrophy, the paralysis usually affects only one limb and is not hemiplegic. The reaction of degeneration is also present.

Talipes Equino-varus (Club-foot).

This is a deformity of the foot which is readily recognized. The majority of cases are of congenital origin. In a small number, however, the condition is an acquired one, usually secondary to an infantile paralysis. The foot is inverted and rotated upon its axis, so that the outer border of the sole touches the ground (Fig. 451) and the toes point inward. The front part of the foot is at the same time depressed. The head of the astragalus and cuboid can be seen to project just beneath the skin, while the inner malleolus cannot be felt.

Fig. 453.—Talipes Calcaneus (Fowler).

The congenital can be differentiated from the paralytic form by the presence of paralysis of the muscles on the anterior and external surface of the leg in the latter. The tendo Achillis in the acquired form is found to be very tense.

Talipes Equinus.

In this deformity the heel is drawn up, and the toes point downward. It may be of congenital or acquired origin. The former is not common, the usual combination being that of equino-varus or club-foot. An acquired talipes equinus may follow (*a*) infantile paralysis, (*b*) disease of the ankle-joint, (*c*) any form of spastic paralysis (hemiplegia, etc.), (*d*) fractures or diseases of the hip- or knee-joints. It varies in degree. In moderately severe cases the patient walks upon the ball of the foot, *i. e.*, upon the heads of the metatarsal bones. The toes are hyperextended (Fig. 452). Callosities and bursæ frequently form over the ends of the metatarsal bones. In milder

Fig. 454.—Typical Flat-foot (Gillette).

cases, when the patient attempts to walk the weight is borne mainly upon the front half of the foot. In the most severe forms the weight is borne entirely on the dorsal surface of the metatarsals and toes, the sole of the foot being directed backward.

Talipes Calcaneus.

This is comparatively rare as a congenital affection. It is usually an acquired deformity, and follows an infantile paralysis of the muscles of the calf of the leg.

The front part of the foot (Fig. 453) is drawn up by the muscles of the front of the leg. The patient walks upon the heel, and the gait is inelastic because the spring of the foot is absent. It is generally associated with a talipes valgus or talipes cavus.

Talipes Cavus.

This is a condition in which the arch of the foot is increased so that the front of the foot approaches the heel (Fig. 454). It is rarely congenital. In the majority of cases it is an acquired deformity, the result of an infantile paralysis.

A B

Fig. 455.—A, Impression of Normal Foot; B, Impression of Flat-foot.

Talipes Valgus.

This is one of the more common congenital deformities of the foot. The arch of the foot is entirely lost, the sole being everted so that it touches the ground at all points, and finally the front of the foot is turned out (abducted). Acquired talipes valgus differs from an acquired flat-foot by the absence of a distinct dropping of the arch of the foot. Its most common cause is an infantile spinal paralysis. It is much less painful than flat-foot.

Flat-foot (Pes Planus).

This affection is most common during adolescence, and is essentially a yielding or lowering of the arch of the foot. The instep is

unable to support the weight of the body. It may develop either gradually or acutely. It may be due to a number of causes: (*a*) To occupations requiring prolonged standing, like that of waiters, etc.; (*b*) to rheumatism, especially gonorrheal; (*c*) after Pott's fracture (Fig. 345); (*d*) as a complication of rachitis; (*e*) weakness of the muscles of the great toe and head of the first metatarsal bone; (*f*) improperly made shoes, with low insteps; (*g*) rapid growth or increase in weight; (*h*) infantile or spastic paralysis.

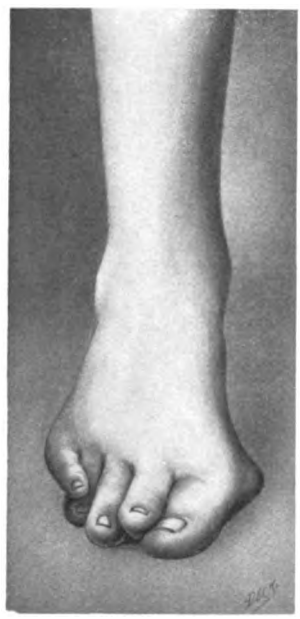

FIG. 456.—HALLUX VALGUS (Fowler).

Clinically it can be readily recognized if close attention be paid to the normal condition, and also to the fact that not every painful affection of the foot is due to "rheumatism." There are two forms clinically: (1) Flexible flat-foot or weakened foot, where the flattened position is assumed as soon as weight is put upon the foot; (2) rigid or true flat-foot, in which the deformity is permanent, owing to alterations in the structures of the bones. The condition is more bilateral than unilateral.

The diagnosis depends upon noting any lowering of the arch of the foot when the patient bears the weight upon it. An impression of the foot should be taken by allowing the patient either to step upon cardboard blackened with camphor smoke, or by covering the sole of the foot with oil and having him step upon a sheet of paper, placing the extra weight upon the foot.

FIG. 457.—APPEARANCE OF HAND IN A CASE OF WEBBED FINGERS.

The index, middle, and ring fingers are bound together so that they can only be distinguished at their distal ends.

A variable degree of pain is present in the neighborhood of the scaphoid, and often it is also referred to the leg, knee, back, or hip. In the milder cases it is only noticed when the foot is stepped upon. In the more

severe, the pain is constant, and independent of bearing the weight upon the feet. There is also some tenderness over the most painful points, viz., over the scaphoid, outer border of the foot, center of the heel, front of the foot, and behind the inner malleolus. At times the pain and tenderness seem so distinctly localized, that an inflammatory focus is thought of.

Inflammation of the tendon-sheaths of the peroneal and tibial tendons, in the shape of elongated soft swellings along the front and sides of the ankle, are often the symptom for which the physician is

FIG. 458.—X-RAY OF ANTERO-POSTERIOR VIEW OF HAND, SHOWING NEEDLE IN SITU.

FIG. 459.—X-RAY OF LATERAL VIEW OF HAND, SHOWING NEEDLE IN SITU.

consulted. In very acute cases the foot is held abducted through contraction of the peroneal muscles. The foot is often swollen, and becomes so rigid that the front of the foot cannot be adducted actively or passively as much as it can normally (Lovett).

There is also limitation of motion in the ankle-joints. When the patient walks, the feet are everted, and the weight is borne upon the inner side of the foot. There is a lack of elasticity in the gait.

In children there is but little pain on walking. The physician is often consulted because the child tires easily, or complains of pain in the legs, back, or hips. Rigidity is rarely present. The child cannot

balance itself well, and falls frequently. There is usually a greater degree of flattening than in adults.

Metatarsalgia (Morton's Disease).

This condition is characterized by frequently recurring attacks of severe pain, which usually appear between the third and fourth or

Fig. 460.—X-ray of Gunshot Wound of Hand.
Showing bullet embedded on metacarpal bone of thumb.

fourth and fifth toes while the patient is walking. The anterior arch of the foot, formed by the heads of the metatarsals, is often relaxed or flattened, so that the heads of the second, third, and fourth metatarsal bones are on a lower level than normal. The arch of the foot is often flattened. The toes are often rigid, and dorsal flexion of the foot may be limited.

Hallux Valgus.

This is a deformity of the great toe, in which the phalanges are pushed outward and form an angle with the head of the metatarsal bone, which becomes enlarged. The bursa lying over the latter may become inflamed from time to time, and be present as a tender, soft swelling (bunion), which becomes acutely inflamed at intervals.

Congenital Deformities of the Hands.

Club-hand is usually associated with other deformities. The hand is flexed and drawn over to the radial side.

Webbed fingers (syndactylism) involves two or more fingers. The union extends a variable distance to the tips (Fig. 457). It is often associated with a lack of development of the bones of one or more fingers.

Supernumerary digits (polydactylism) are also congenital. They are generally symmetrical and involve hands and feet (Fig. 457). Usually there is but a single digit in excess, on the side of the little finger or little toe. The development may be complete or more or less imperfect.

Foreign Bodies in the Hands or Feet (Figs. 458, 459, 460).

Various foreign bodies may penetrate the integument and remain embedded in the subcutaneous or deeper tissues. The most frequent locations of these are the hands and feet, and the usual substances, needles, portions of a bullet, bits of glass, etc. The most reliable method of locating these is by the use of the *x*-ray. One should never depend upon a fluoroscopic view of their location, care being taken to take skiagraphs in two directions. This method is to be especially recommended for needles.

CHAPTER VI.

DISEASES AND INJURIES OF THE SPINE.

SPINA BIFIDA.

This congenital deformity of the spine occurs most frequently on the posterior aspect, less often on the ventral or anterior surface. Various combinations occur as the result of a non-closure of the neural arches. These are:

Rachioschisis.—This is due to a complete or partial absence of union of the medullary canal. This is the most severe form. There is a defect of normal skin in which an open depression exists, at the base of which a soft red band of vascular tissue is found, which represents the cord. It rests upon a thin reddish membrane, which represents the pia mater, which is continuous on both sides with the skin. The dura and arachnoid lie beneath it, and pass over into the subcutaneous tissue. The arches are present as short stumps, and the bodies are greatly deformed.

Myelocele or Myelomeningocele.—The conditions of the bones are the same as in the first form (rachioschisis), but, owing to the accumulation of fluid between the membrane on the ventral side, the cord and its coverings on the dorsal aspect are pushed out and form a visible thin-walled sac. The cord lies upon its inner side and is closely adherent to it. As in the first form there is a defect of skin, thus favoring infection.

Myelocystocele.—This is a smaller or larger sac whose outer covering is thin, but otherwise unchanged. The innermost layer is composed of greatly thinned cord. Between it and the skin are found two thin vascular layers, representing the pia and arachnoid. This form of spina bifida is the result of the accumulation of fluid in the central canal, and the dilated cord is covered by pia-arachnoid and skin. The dura does not take any part in the coverings of this or the two preceding forms.

Meningocele.—In this form a cyst with a narrow pedicle is found. The sac is either composed of pia-arachnoid, with fluid in the subarachnoid space, or only of dura, with fluid in the subdural space. The cord seldom participates in the formation of the sac. When it does the condition is known as a myelocele.

The diagnosis of a spina bifida itself is, as a rule, not difficult. The majority occur on the posterior aspect of the spine in the lumbosacral region (Fig. 461). Rachioschisis and myelomeningocele can be recognized by the defect in the skin. In both, deformities as well as paralyses of the extremities are frequently found, with or without involvement of the sphincters. The third and fourth forms, viz., myelocystocele and myelomeningocele, are covered by normal but thinner skin. The first named is often associated with other deformities, such as

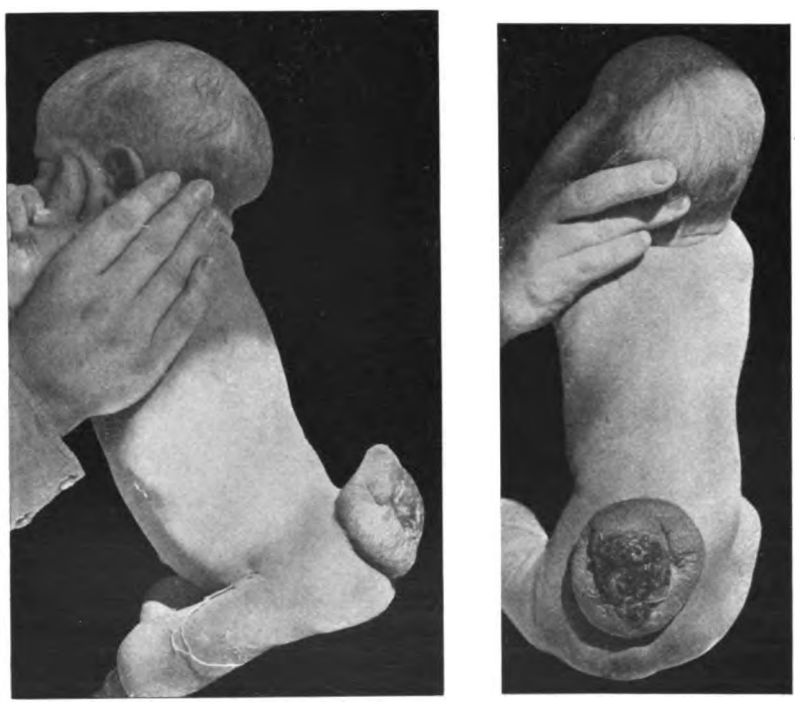

FIG. 461.—SIDE AND FRONT VIEWS OF A CASE OF EXTENSIVE SPINA BIFIDA.

hydrocephalus, club-foot, etc. These two forms can only be distinguished when the sac is opened. In a meningocele one finds a smooth serous inner wall, while in a myelocystocele there is a reddish-brown vascular tissue which leads into the open cord. Meningoceles are rarely accompanied by symptoms of paralysis. When pressure on the tumor causes the fontanelles to bulge it is more likely to be a myelocystocele.

Myelomeningoceles are usually found in the sacrum, while myelocystoceles may occur anywhere.

INJURIES OF THE SPINE.

In the examination of a patient suffering from an injury to the vertebral column either recent or of long standing, the following routine will be found useful:

1. How was the injury received?
2. What is its probable nature?
3. Does evidence of compression or destruction of the cord or its nerves exist?
4. At what level did such injury occur?
5. What are the objective evidences of such injury, exclusive of that of the cord?

General Consideration.—Before discussing spinal injuries in detail a brief résumé of our present knowledge of their pathology and the chief points in spinal localization will be taken up.

Pathology of Injuries of the Spine.—Injuries of the vertebræ usually occur in adult life and in an indirect manner. The direct modes of injury affect the arch, while the indirect involve the body of the vertebra. Most frequently the indirect are the result of a sudden bending forward (flexion) of the spine. Only in a small proportion of cases do hyperextension or lateral or rotary forces play a rôle.

Pure fractures are quite rare. In the majority of cases the injury is a combination of a fracture and a dislocation. Such fracture dislocations are most apt to occur between the tenth dorsal and second lumbar vertebræ. True dislocation without fracture is most apt to occur in the cervical region.

The part most frequently fractured is the body of the vertebræ.

The general statements on page 438 in regard to fractures of the bones of the extremities hold true for those of the vertebræ. Compression fractures are more common, however, than in the case of any other bones except those of the tarsus (Fig. 358). The compression may be so extreme that the upper and lower intervertebral discs may be brought into contact with each other, the substance of the bone being partly compressed and partly displaced upon the sides or behind into the spinal canal (Fig. 452).

With this may be associated fractures of the arches, spinous and transverse processes, or extensive tears of the ligaments.

By *dislocation of a vertebra* is meant an injury in which the adjoining articular processes on one or both sides have been partly or completely separated from each other. If a fracture of the body or its arch has occurred at the same time in a true dislocation, such a

fracture can be deemed unessential to the production of the dislocation.

The normal range of motion between adjoining vertebræ is in two axes, one vertical in the median plane, and the other horizontal, passing through the posterior part of the disc. There are two modes or varieties of dislocation, viz., (*a*) by abduction, which includes complete or incomplete unilateral dislocations forward or backward, and (*b*) by flexion, which includes bilateral dislocations forward or backward.

The spinal cord terminates at the lower border of the body of the first lumbar vertebra. It is made up of a number of segments, similar and partly independent, which correspond to the vertebral bodies and each pair of spinal nerves. Every segment possesses motor, sensory, and reflex functions besides vasomotor, visceral, and trophic activities. The spinal cord may be injured directly (*a*) by the displacement of a fragment; (*b*) by the pressure of a dislocated vertebra; (*c*) by a blood-clot; (*d*) by an inflammatory exudate; (*e*) by elongation; (*f*) by being penetrated by a fragment (rare); (*g*) by being penetrated by a cutting instrument (stab wound) or a bullet. In one case observed by the writer a piece of tin was thrown horizontally in such a manner as to enter between the atlas and skull and sever the cord.

FIG. 462.—FRACTURE-DISLOCATION OF SPINE, SHOWING CRUSHING OF THE CORD (Guy's Hospital Museum).

In fractures, the cord is usually caught between the anterior portion of one fragment and the posterior portion of another (Fig. 462).

The dura is seldom torn, the cord being pulpified at the moment of the injury. Hemorrhage may occur either around the cord (extradural), or within its substance (hematomyelia).

The blood in the former case spreads up and down in the canal, and thus compresses the cord.

In hematomyelia the hemorrhage may take place into the gray

matter alone and be limited to a few segments, or, if the lesion is more severe, the hemorrhage extends into the white columns. If the patient survive, the absorption of the clot leaves cavities which fill with scar tissue. The elements of the gray matter are thus permanently destroyed. Apparently most of the cases of injury to the neck which recover after having presented symptoms of severe injury to the cord are cases of hematomyelia.

Spinal Localization.

A knowledge of the functions of the various spinal cord segments is absolutely essential to the diagnosis of surgical lesions of the cord. Such cord lesions may follow (*a*) the pressure of a fragment in fractures of the vertebra; (*b*) the pressure of a dislocated vertebra; (*c*) hemorrhage into or around the cord; (*d*) a stab or gunshot wound; (*e*) pressure of a tumor or inflammatory exudate.

Cord lesions cause: (*a*) irritation; (*b*) partial destruction, or (*c*) complete destruction.

(*a*) *Irritative lesions* cause hyperesthesia, pain, spasms, rigidity, and increased reflexes.

(*b*) *Partial Destruction of a Segment.*—This is seldom strictly unilateral. If only one lateral half of the transverse cord section is involved, as occasionally occurs after stab wounds, the complex symptom known as *Brown-Séquard paralysis* develops. There is complete loss of power on the same side as the lesion in all parts below that point. There is also a slight loss of power below the lesion upon the opposite side. Anesthesia is complete on the side opposite the lesion, below its level.

There is a band of cutaneous anesthesia upon the same side as the lesion which marks its exact level. It varies vertically according to the extent of cord destroyed. There is a band of hyperesthesia above and below the band of anesthesia on the paralyzed side. On the opposite or anesthetic side, there is also a band of hyperesthesia a little below the level of the hyperesthetic band of the paralyzed side. The reflexes are increased below the lesion on the paralyzed side, but are abolished at the level and throughout the vertical extent of the lesion.

The muscular paralysis in these partial cross lesions is usually of a spastic character, because the reflexes are preserved and increased as just stated.

In late cases of partial cross-lesions, the rigidity and spastic features

are well developed (Church). The lower limbs are either held rigidly extended or less frequently, flexed. Contractures finally develop (Fig. 463).

(*c*) *In total destruction of the cord* the symptoms are in general: (1) Paralysis of the muscles supplied by the segment involved and of all muscles represented in the cord below the lesion. This results in a paraplegia. (2) Anesthesia in the area of skin supplied by the segment and in all parts below. This is really the best guide to the level of the lesion. (3) A zone of hyperesthesia at the upper border of the area of anesthesia.

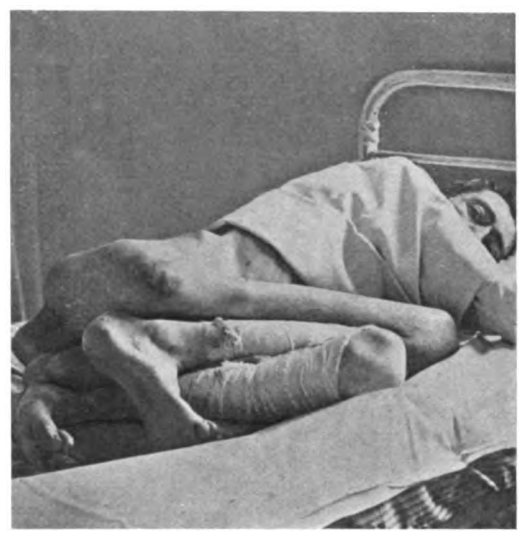

FIG. 463.—MARKED PARALYTIC CONTRACTURES OF THE LOWER EXTREMITY FOLLOWING COMPRESSION MYELITIS, DUE TO FRACTURE OF THE SPINE.

In the trunk total transverse lesions of the cord produce an anesthesia whose upper limit is horizontal, while lesions of the nerve-roots cause anesthesia or hyperalgesia which follows the direction of the intercostal nerves and spaces. (*d*) The reflexes furnish very valuable evidence not only as to the upper level of the cord lesion, but sometimes as to its vertical extent. *Complete destruction of the cord extinguishes all reflexes below the level involved, while partial division causes an enfeeblement of the same reflexes*, which later on is succeeded by an exaggeration of the same.

The absence of one or more of these increased reflexes in such a case points to the level of the lesion. Again, the upper level of abolished reflexes usually coincides with that of anesthesia, and either one enables us to locate the lesion.

(*e*) *Trophic Disturbances.*—The extent of muscular atrophy depends upon the vertical dimensions of a lesion. The muscles innervated from the cord above and below the destructive process are spared, and regain their nutrition and electrical reaction. The normal galvanic

response gradually disappears in the atrophied muscles and is replaced by the reaction of degeneration. In acute destructive lesions and cord hemorrhage, acute bedsores may form in a few hours over the sacrum, heels, malleoli, and trochanters (Fig. 369).

(*f*) *Vasomotor Changes.*—The paralyzed limbs are warmer than normal, and there is distention of the subcutaneous veins. Priapism is a very common sign of such vasomotor paralysis in lesions of the cervical segments. In addition the latter often cause flushing and perspiration on the side of the neck and face and may reduce the heart-beats to forty or less per minute. Dorsal lesions are sometimes attended by a persistently rapid pulse.

(*g*) *Visceral Symptoms.*—There is usually disturbance of the anal and vesical sphincters. When their reflex centers in the lumbar cord are destroyed the sphincters are completely relaxed, and incontinence results. If the lesion is above their spinal center only voluntary control is lost. This results in retention of urine and feces. The distention of the bladder may become so extreme that overflow occurs, resulting in the constant dribbling of urine. This latter condition is called incontinence of retention.

Cystitis and pyelonephritis almost invariably follow the continued and unavoidable use of the catheter in these cases, despite every precaution to prevent infection.

The retention of feces present in the early stages often gives way to incontinence.

Intestinal obstruction, of the variety known as adynamic ileus, may develop immediately after an injury of the spinal cord. It may be temporary or permanent, the latter invariably resulting fatally.

This paralysis of the intestinal musculature is the result of the involvement of the splanchnic nerves. The clinical picture in such cases resembles that described under intestinal obstruction (page 277).

Acute gastric dilatation may also develop as a complication of spinal cord injuries.

A study of the accompanying table of symptoms[1] (pages 669 to 675) will be found extremely useful in the diagnosis of the level of a cord lesion. The table shows the clinical signs in cases of disabling, but not absolutely destructive, cord lesions. If the entire cross-section is absolutely destroyed the symptoms are the same, but there is complete absence of muscle reflexes below the lesion.

[1] Wichmann: "The Relations of the Spinal Nerves and Segments," Berlin, 1900.

TABLE OF SYMPTOMS IN CROSS-LESIONS OF THE CORD.—(*Church and Peterson.*)

Lesion. Segment.	Motor Conditions. Paralysis.	Paresis.	Actions Lost or Impaired.	Reflex Conditions. Absent.	Increased in Partial Lesions.	Sensory Conditions. Anesthesia Marked by Diagonal Lines. Hypesthesia Marked by Crossed Lines.
V. Sacral.	None.	Coccygeus.	Elevation of coccyx.	None.	None.	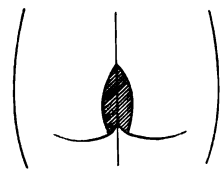
IV. Sacral.	Coccygeus.	Levator ani. Sphincter ani. Detrusor urinæ. Transversus perinei. Erector penis. Compressor urethræ.	Elevation of coccyx. Elevation of anus. Sphincter ani. Ejection of urine. Vaginal constriction.	Erection of penis diminished.	None.	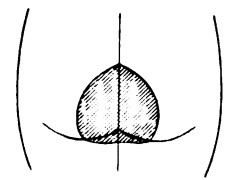
III. Sacral.	Sphincter ani. Levator ani. Detrusor urinæ. Transversus perinei. Erector penis. Compressor urethræ.	Rectum.	Defecation disturbed. Retention of urine, later followed by dribbling. Ejaculation lost. Erection possible, but paretic. [Testicle sensitive to pressure.]	Ejaculation lost. Erection diminished. Tendo Achillis.	None.	Rider's breeches form. 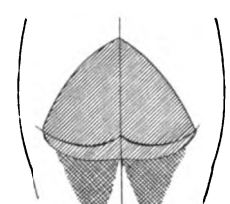 Perineum. Anus. Scrotum (posterior inferior part or labia). Penis. Thigh, uppermost posterior part hypesthetic.

TABLE OF SYMPTOMS IN CROSS-LESIONS OF THE CORD.—(*Continued.*)

Lesion. Segment.	Motor Conditions. Paralysis.	Paresis.	Actions Lost or Impaired.	Reflex Conditions. Absent.	Increased in Partial Lesions.	Sensory Conditions. Anesthesia Marked by Diagonal Lines.	Hypesthesia Marked by Crossed Lines.
II. Sacral.	Sphincter ani. Levator ani. Detrusor urinæ and other muscles as in III. Sacral.	Pyriformis. Obturator internus. Gemellus superior. Gluteus maximus. Biceps femoris. Gastrocnemius. Soleus. Tibialis posticus. All the small muscles of foot.	Outward rotation thigh. Retraction thigh. Flexion of knee. Plantar flexion of foot. Standing on the toes. Raising inner margin of foot. Defecation, Retention } as in III. Sacral.	Ejaculation. Erection. Plantar weakened.	None.	Anesthesia of genitalia, except base of penis and scrotum; hypesthetic.	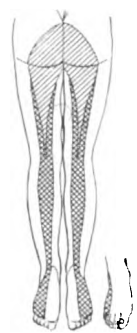
I. Sacral.	Muscles of anus. Muscles of bladder. Muscles of genitals. Pyriformis. Adductor hallucis. Flexor hallucis brevis. I-IV, Dorsal interossei. I-III, Plantar interossei. III-IV, Lumbricales. Abductor minimi digiti. Opponens minimi digiti.	Gluteus maximus. Obturator internus. Gemellus superior. Gluteus medius. Gluteus minimus. Biceps. Semimembranosus. Semitendinosus. Popliteus. Gastrocnemius. Soleus. Tibialis posticus. Peroneus longus. Peroneus brevis. Flexors of toes. Extensors of toes.	Retention of feces. Retention of urine, or dribbling. Erection and ejaculation impossible. Outward rotation of thigh impaired. Internal rotation impaired Flexion of knee difficult. Plantar flexion of foot. Raising inner margin of foot. Raising outer margin, and dorsal flexion of foot. Flexion and extension of toes, adduction of great toe, abduction of little toe, etc.	Plantar weakened. Achilles-tendon reflex. Ejaculation. Erection. Micturition. Defecation. Gluteal.	None.		

V. Lumbar.	Muscles of anus and rectum. Muscles of bladder. Muscles of genitals.		Defecation. Micturition delayed, dribbling. Erection, ejaculation impossible.	Ejaculation. Erection. Micturition.	Plantar. Tendo Achillis.
	Pyriformis. Obturator internus.	Gemellus superior. Gemellus inferior.	Outward rotation of thigh very difficult.	Defecation. Gluteal.	
		Gluteus medius. Gluteus minimus.	Inward rotation impaired.		
	Biceps femoris.	Semimembranosus. Semitendinosus.	Flexion of knee difficult.		
		Gluteus maximus.	Retraction of thigh very difficult.		
		Tensor fasciæ femoris.			
		Gastrocnemius. Soleus.	Flexion of foot barely possible.		
	Flexors of toes.		Flexion of toes impossible.		
		Extensors of toes.	Extension of toes weak, except great toe, which may be dorsally flexed.		
		Tibialis anticus.	Raising inner margin of foot difficult.		
	Peroneus longus. Peroneus brevis.		Raising outer margin of foot impossible.		
IV. Lumbar.	Muscles of rectum and anus. Muscles of bladder. Muscles of genitals.		Defecation. Micturition delayed, dribbling. Erection, ejaculation impossible.	Patellar may be wanting.	Plantar.
	Obturator internus. Pyriformis. Gemelli.	Obturator externus.	Outward rotation of thigh weak.		
	Gluteus medius. Gluteus minimus.		Inward rotation impossible.		
	Gluteus maximus.		Retraction of thigh impossible.		
	Biceps femoris. Semimembranosus. Semitendinosus.		Flexion of knee lost.		
	Popliteus.				
	Gastrocnemius. Soleus.		Plantar flexion of foot lost.		
	Flexors of toes. Extensors of toes.		Flexion and extension of toes lost.		
	Peroneus brevis. Peroneus longus.		Raising outer margin of foot.		
	Tibialis anticus.		Raising inner margin.		
		Rectus femoris. Vastus externus. Vastus internus.	Extension of thigh weak.		
		Adductor magnus. Adductor brevis. Adductor minimus. Gracilis.	Adduction difficult.		

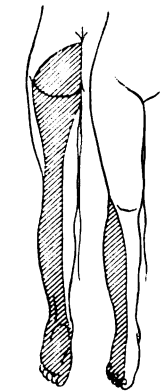

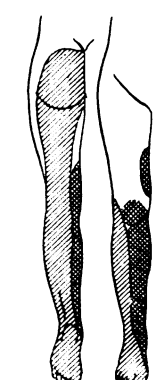

TABLE OF SYMPTOMS IN CROSS-LESIONS OF THE CORD.—(*Continued.*)

Lesion, Segment.	Motor Conditions.			Reflex Conditions.		Sensory Conditions.	
	Paralysis.	Paresis.	Actions Lost or Impaired.	Absent.	Increased in Partial Lesions.	Anesthesia Marked by Diagonal Lines.	Hypesthesia Marked by Crossed Lines.
III. Lumbar.	Muscles of anus, bladder, and genitals. Outward rotators thigh. Inward rotators thigh. Retractor (flexor) thigh. Flexors of knee. Plantar flexors of foot. Flexors of toes. Extensors of toes. Extensors of foot. Vastus externus.	Vastus internus. Rectus femoris. Crureus. Adductors of thigh. Flexors of thigh at the hips.	Extension of leg almost impossible. Psoas and iliacus can lift the leg somewhat, however.	Patellar. Cremasteric.	Ankle-clonus may exist.		
II. Lumbar.	Paralysis of all muscles of lower extremity except psoas.	Psoas.	All motions lost. [Testicle not sensitive to pressure.]	Patellar. Achilles. Cremasteric.	Achilles may be increased. Plantar.	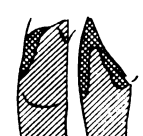	Total anesthesia of lower extremity except territory of the ilio-inguinal and external cutaneous, which is hypesthetic.
I. Lumbar.	Total paralysis of whole lower extremity, psoas included.			Cremasteric. Achilles.	Patellar none or increased. Plantar. Ankle clonus.		

XII–III. Dorsal.	Paralysis of lower extremity, and gluteal region. Paralysis of abdominal and dorsal regions gradually added as the site of the lesion ascends.		Paralysis of muscles of respiration causes diaphragmatic breathing and dyspnea.	In complete lesions epigastric reflex and abdominal reflex may be abolished. All below lost in complete division of cord.	Increased in incomplete lesions. Patellar. Cremasteric. Achilles. Plantar.	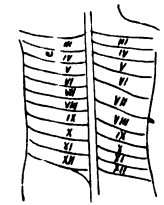 Anesthetic area begins, as a rule, two segments below site of lesion, these two intervening segments being hypesthetic.
II. Dorsal.	As in III. Dorsal.			All below lost in complete division of cord.	All subjacent reflexes.	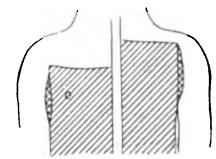
I. Dorsal.	All muscles of trunk and lower extremities.	Flexors of fingers. Muscles of the little finger. III and IV Interossei. Lumbricales. Pronator quadratus. Lower part pectoralis major. Lower part pectoralis minor.	Weakness in flexion of fingers. Pronation disturbed.	Oculopupillary symptoms. All below lost in complete division of cord.	All below increased.	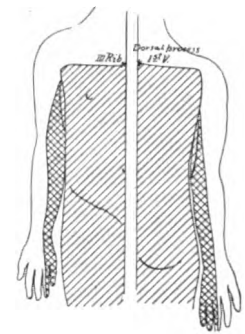

Table of Symptoms in Cross-lesions of the Cord.—(*Continued.*)

Lesion. Segment.	Motor Conditions.			Reflex Conditions.		Sensory Conditions.	
	Paralysis.	Paresis.	Actions Lost or Impaired.	Absent.	Increased in Partial Lesions.	Anesthesia Marked by Diagonal Lines.	Hyperesthesia Marked by Crossed Lines.
VIII. Cervical.	Paralysis muscles of trunk and lower extremities. Abductor of little finger. Adductor of thumb. Flexors of the little finger. Opponens minimi digiti. III and IV Interossei. Lumbricales.	Flexors of the little finger. Opponens minimi digiti. Flexor sublimis digitorum. Flexor profundus digitorum. Flexor carpi ulnaris. Extensors of the thumb and fingers. Extensor carpi ulnaris. Triceps (slight). Latissimus dorsi (lowest part) Pectoralis major. Pectoralis minor. Scalenus medialis. Scalenus posterior	Hand weak. Extension of arm. Int. rotation and retraction of arm Adduction of arm.	Oculopupillary symptoms. All below lost in complete division of cord.	All below increased.	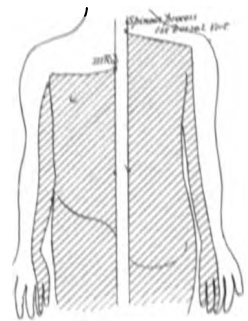	
VII. Cervical.	Lower extremities and trunk. Flexor profundus digitorum (ulnar side). Flexor carpi ulnaris. Small hand muscles. Pronator quadratus.	Extensors / Flexors / Abductors } of thumb. Extensor indicis. Extensors of the fingers (movements barely possible). Supinator longus. Biceps (very slightly paretic). Triceps. Pectoralis major. Serratus magnus (slight). Latissimus dorsi. } Teres major. }	Hand very weak. ("Winged" scapulæ.) Retraction and inward rotation of the arm.	Arm reflexes. Forearm reflexes. Palmar reflex. All below lost in complete cord division.	All below increased.	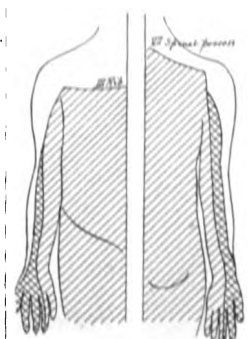	

VI. Cervical.	Muscles of lower extremity and trunk. Muscles of fingers (including thumb) and hand. Triceps. Pectoralis major. Latissimus dorsi. Teres major. Infraspinatus. Serratus magnus.	Coracobrachialis. Biceps. Brachialis anticus. Supinator brevis. Deltoid. Scaleni. Splenii. Deep head and neck muscles.	Movements of fingers and thumb impossible. Extension of forearm. Flexion of forearm weak. Supination very weak. Adduction of arm and inward rotation. Adduction, retraction, and external rotation. "Winged" scapula. Raising of arm. Rotation of head. Fatal in a few days or weeks.	Arm-reflexes. Extensor forearm reflexes. All below lost in complete cord division.	All below increased.
V. Cervical.	Muscles of lower extremity and trunk. All the muscles of the arm, forearm, hand. and fingers; even the deltoid, coracobrachialis, and brachialis anticus. Deep cervical muscles. Intercostals.	Levator anguli scapulæ. Scaleni. Diaphragm (because of filaments from V. cervical segment of the phrenic nerve), or spread of injury from 5th to 4th cervical segment. Trapezius and sternocleidomastoid are intact.	Shoulders raised with difficulty. Rotation and flexion of head. Dyspnea. Fatal in a few hours or days.	Scapular. Tendon reflexes of paralyzed muscles. All below lost in complete cord division.	All below increased.
IV–I. Cervical.	Total cross-lesions from the fourth cervical segment upward are rapidly fatal, because of complete paralysis of the diaphragm and intercostals.				

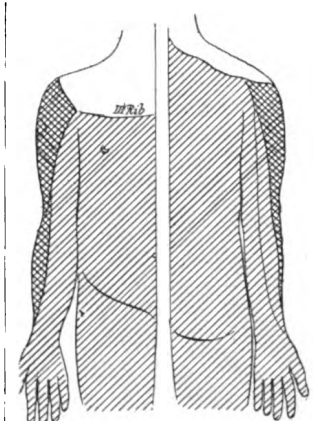

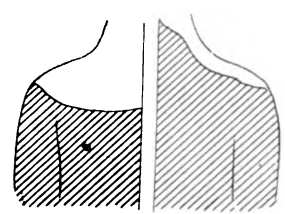

Lesions of the Cauda Equina.—The cauda equina is made up of the descending roots of lumbar, sacral, and coccygeal nerves. It is about ten inches in length. It is affected by the same lesions as the spinal cord itself. The sensory, motor, trophic, and reflex symptoms are the same as follow division of the individual nerve-trunks. In partial lesions, sensation may be but slightly disturbed when motion is quite lost. Increased reflexes are not encountered. The lowest portion of the cauda is usually involved, and the lesions cease at some definite upper level. Most cord lesions, on the other hand, are limited in vertical extent, and the reflex and trophic disorders are confined to the corresponding body segments.

In the examination of an individual, for the purpose of making a diagnosis of an injury of the spine and spinal cord, the various conditions which require consideration are: (1) Fractures; (2) dislocations; (3) hematorachis and hematomyelia; (4) concussion of the spine; (5) traumatic spondylitis.

Fractures of the Spine.

A true fracture of the vertebral column without accompanying dislocation is so infrequent that the term "fracture-dislocation" would be more appropriate. Their diagnosis can be best considered in connection with the individual regions.

Of the Upper Two Cervical Vertebræ (Atlas and Axis).—Three classes of cases occur clinically, viz.: (*a*) Those in which death is immediate, and no diagnosis can be made as to whether fracture or dislocation existed. (*b*) Those in which death occurs, weeks to months after the injury, as the result either of a secondary myelitis or after a sudden movement of the patient. In the absence of paralysis a diagnosis cannot be made in these cases. (*c*) Those in which no symptoms exist, and the nature of the injury often remains unrecognized. These last named cases are usually diagnosed as sprains. They complain of pain in the neck and it is held rigid.

It was formerly thought that practically all of the cases of fracture or dislocation of the atlas or axis belonged to the first group, *i. e.*, where death was immediate. According to Gurlt, these constitute the minority.

In the second group, where the patient survives and the symptoms of secondary myelitis appear, the diagnosis can be made from the latter, and is occasionally confirmed by the palpation through the mouth of the displaced vertebra at the level of the bony septum. In some cases the paralysis involves all of the parts below the fracture.

In others there is only partial paralysis, and, in one case, only a slight diminution of sensibility in the left arm.

From the Third Cervical to the Second Dorsal Vertebra Inclusive.—In this region one must distinguish fractures of the body from those of the arch. If the latter occur, there is crepitus or irregularity of the spinous processes. In respect to the latter, it must not be forgotten that the third and fourth cervical spines normally lie quite deeply.

In fractures of the body an abnormal prominence can often be felt through the pharynx.

The position and mobility of the head vary greatly. It is held rigid in the majority of cases, the shoulders being drawn up and the neck shortened. In some cases the head can be moved freely to either side, but not forward or backward.

As a rule, symptoms of pressure upon the spinal cord appear early. They may be due to (*a*) a hemorrhage into or around the cord, or (*b*) compression by a fragment or displaced vertebra.

If no spinal symptoms occur a differential diagnosis can only be made by an *x*-ray examination, and the fact that the symptoms persist for a longer period.

If the third to fifth cervical vertebræ are broken, death either occurs from paralysis of the phrenic nerve or the diaphragm acts only two or three times a minute, accompanied by a very slow pulse.

The extent of the peripheral paralysis accompanying compression of the cord in this region varies. Paralysis of the arms is not as constant as one would expect. Often the paralysis only extends to the level of the umbilicus or breast. The paralysis of the arms is quite often absent. In some cases the paralysis of the arms may appear upon the day after the accident, or even later. It may involve only one arm or a single group of muscles.

In some cases there is great dyspnea, especially during expiration, as a result of paralysis of the intercostal and abdominal muscles. In other cases there is marked difficulty in speech and swallowing.

There may be paralysis of sensation or of motion alone. Hyperesthesia of part or all of the arm is at times observed, as well as tonic and clonic spasms. Other symptoms of injury to this region are vasomotor changes in the face and neck, priapism, and a high temperature. In rare instances the vertebral artery has been torn, a large clot forming between the muscles of the neck. In some cases the *x*-ray has proved to be of great value. The question as to whether the cord symptoms are due to compression of a fragment or of a dis-

located vertebra, or whether they are due to hematomyelia, will be considered later (page 682).

Fractures from the Third to the Twelfth Dorsal Vertebræ.—The diagnosis of fractures in this region is not very difficult. The arch is rarely involved. Usually the bodies (Fig. 462) of one or more vertebræ are involved with direct compression of the cord. In the majority of cases the condition can be recognized (*a*) by the symptoms of spinal cord compression plus (*b*) the local evidences of injury. In some cases the compression symptoms may exist without a discernible deformity, and again there are instances where the gibbus or angular deformity is quite marked and yet no paralysis, etc., exists. The spinal cord symptoms may, as in the case of injuries higher up, be due to the compression of a blood-clot (page 681).

As a rule, the arms escape paralysis. In the most typical cases there are (*a*) paralysis of motion in the lower extremities (paraplegia); (*b*) paralysis of the bladder and rectum, resulting in retention of urine and feces; (*c*) anesthesia to the level of the injured vertebræ (pages 673 and 674); (*d*) paralysis of the abdominal and intestinal muscles. As is the case in all spinal injuries, these are subject to great variation. The motor paralysis may be irregular or even absent. The paralysis of the abdominal muscles causes the breathing to be shallow and diaphragmatic.

The tympanites resulting from the paralysis of the abdominal muscles and that of the intestinal musculature may become so extreme as to cause death from a paralytic or adynamic ileus (page 283).

Locally the diagnosis of fractures in this region is greatly aided if an angular deformity or a distinct hiatus be found. The spines may be abnormally separated or prominent, or may crepitate. This can be best elicited by passing the finger along the spinous processes. The majority of these patients die from an ascending pyelonephritis in spite of the utmost precautions taken to prevent infection during catheterization. Those who survive often show marked contractures.

Fractures of the Lumbar Vertebræ.—Fractures in this region decrease in frequency from above downward, those of the last three vertebræ being very rare. Only the first lumbar is frequently broken. The symptoms are chiefly those of pressure upon the cauda equina (page 670), since the spinal cord ends opposite the lower border of the first lumbar vertebra. Paralysis is often absent, and if it is present it resembles that of injuries of the individual peripheral nerves. The paralysis of the extremities is often unequal or irregular, being con-

fined to flexors of the thigh and leg. Anesthesia is present in a similar, irregular manner. There are often sharp pains, referred along the course of the peripheral nerves, and paresthesia. Reflexes are either absent or are only feebly present. Muscular atrophy appears very early. Vesical and rectal paralysis is frequently present.

Dislocations of the Vertebrae.

A dislocation of a vertebra is defined as an injury in which the articular processes of one or both sides have completely separated from each other, accompanied by more or less displacement of the body. The term diastasis is applied by Blasius to those dislocations in which the ligaments and intervertebral discs are so torn, that the vertebræ are separated from each other in front or behind, in a longitudinal direction. They are not displaced on each other horizontally, so as to separate the articular surfaces from each other completely, as in the case of a true dislocation.

True dislocations are most frequent in the cervical region, quite rare in the dorsal, and rarest of all in the lumbar region. We usually speak of the upper of the two vertebræ as the dislocated one. A diastasis is most apt to occur between the fifth and sixth or the sixth and seventh cervical vertebræ. It is often combined with a fracture. Dislocations of the vertebræ are best divided into (*a*) *dislocations by abduction or rotation, and* (*b*) *dislocations by flexion.* Under those by abduction or rotation are included the complete or incomplete unilateral dislocations forward or backward, and the bilateral dislocations in opposite directions. The majority of the unilateral are forward, there being only a few cases recorded in which it occurred in a backward direction. Under dislocations by flexion, are included bilateral forward or backward ones. The former is far more frequent, and follows extreme flexion of the neck. There are, as in the case of the unilateral abduction variety, but few cases of bilateral backward dislocations. The diagnosis of this class of injuries of the vertebræ, viz., dislocations, is very difficult. The majority of the symptoms are local, and there is little to distinguish them from a fracture. The evidences of displacement are the same, but there is no crepitus as in fracture. The latter sign may, however, be absent even in a fracture. Abnormal mobility might also be of value in the differentiation from a fracture, were it not for the fact that the neck is held so rigid that it is impossible to elicit abnormal mobility or crepitus, and further it is contraindicated to manipulate the spine under these conditions.

The neck is held rigid and contracted in both fractures and dislo-

cations. The chief diagnostic points of a dislocation are (*a*) the deformity; (*b*) the pain, and (*c*) the spinal cord symptoms.

(*a*) The deformity can often be recognized by passing the finger along the cervical spines, and also by palpating the transverse processes. The prominence or depression of a spinous process is often quite marked, allowance being made for the fact that one can seldom feel the upper cervical spines even in normal individuals. At times the displaced vertebræ can be felt through the pharynx (Fig. 464).

(*b*) The pain varies greatly, but is generally quite marked, and referred along the course of the affected cervical nerves.

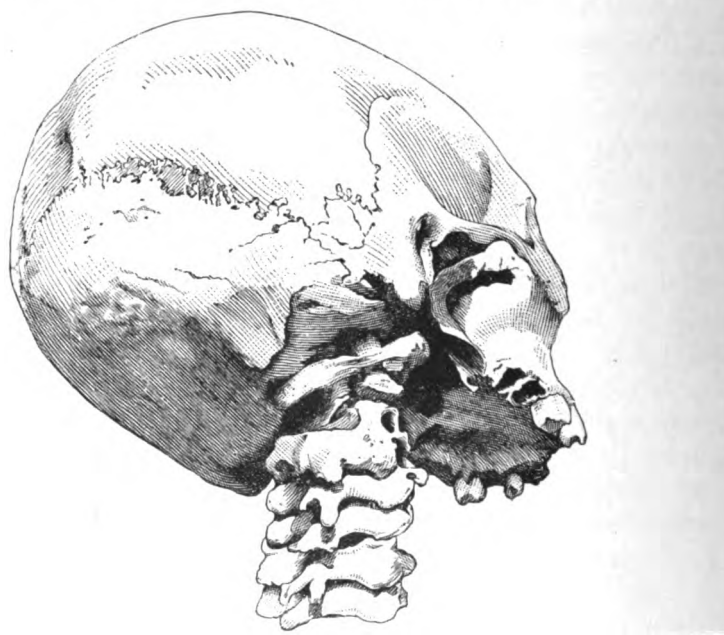

FIG. 464.—FRACTURE AND SUBLUXATION; CERVICAL VERTEBRÆ UNITED (J. Mason Warren collection, Warren Museum) (Walton).

(*c*) The spinal cord symptoms may, as in the case of a fracture, be due to hematomyelia or to the pressure of a fragment or displaced vertebra. The symptoms of compression are absent in a larger number of cases of dislocation, than of fracture; especially is this true of paralyses. If present, they are apt to be less extensive and less marked than in the case of a fracture. Immediate death may occur as the result of phrenic nerve paralysis. In general, however, the paralyses are incomplete, and anesthesia is often absent or unequal. It may be more marked on one side than the other. The paralysis may correspond entirely to that of a peripheral nerve. Paralyses may be

quite marked and then disappear gradually. In some cases the paraplegia, paralysis of the rectum and bladder, priapism, high temperature, vasomotor changes, and acute decubitus may resemble the same symptoms following a fracture (page 668).

Other nervous symptoms are localized muscular twitchings, general epileptiform convulsions, hyperesthesia, and neuralgic pains in the course of nerves that are compressed.

The *x*-ray may be of some value in confirming the diagnosis, but

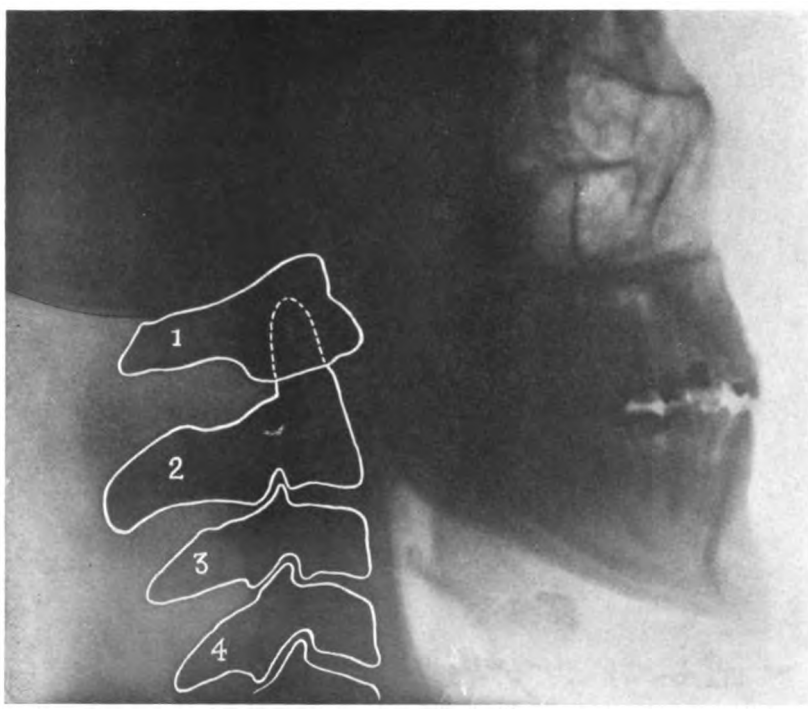

FIG. 465.—X-RAY OF NORMAL ADULT SPINE IN CERVICAL REGION.
The outlines of the upper four cervical vertebræ are traced in white and marked, 1, 2, 3, and 4, respectively.

care must be used in interpreting the skiagraph. X-rays shown in Fig. 465 were taken from a normal individual, one without any effort at displacement, and the second (Fig. 466) following extreme voluntary efforts of flexion. They were taken to prove the possibility of a normal *x*-ray resembling that of a dislocation.

HEMATORACHIS AND HEMATOMYELIA.

These conditions are so frequently associated after traumatism that they will be described together. Meningeal hemorrhage (hem-

atorachis) may be extradural or subdural. The symptoms of both are alike. In hematomyelia the hemorrhage usually takes place into the gray matter, but the white matter is not exempt. Both of these conditions occur most frequently in the cervical region.

The symptoms of hematorachis, when it occurs alone, appear more gradually than do those of hematomyelia. In both, the symptoms depend upon the tension, extent, and location of the clot.

The symptoms common to both conditions are the following: (*a*) Severe pain radiating along the compressed or involved nerve-trunks;

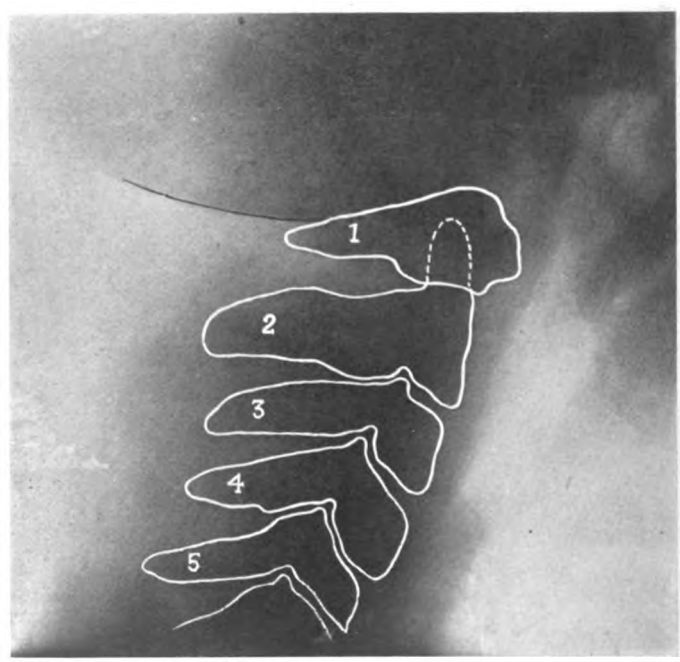

FIG. 466.—PSEUDO-DISLOCATION OF NORMAL ATLAS UPON AXIS SECURED BY PROTRUDING HEAD VOLUNTARILY FORWARD. (See text.)

(*b*) symptoms of motor and sensory paralysis; (*c*) paralysis of the bladder and anal sphincters.

The symptoms of hematomyelia are present, as a rule, immediately after an injury, and this is the only feature distinguishing it from hematorachis.

In traumatic cases the two are so frequently associated that it is almost impossible to make a differentiation.

The symptoms are usually most marked at the end of the first twenty-four hours. They subsequently improve, and disappear com-

pletely in four to six weeks. Death may, however, immediately result.

Both of these conditions can be distinguished from the spinal cord symptoms following fractures or dislocations by the fact that they develop more gradually, and, further, that they tend to disappear spontaneously within a short time.

Concussion of the Spine.

This condition has been the subject of considerable dispute ever since Erichsen, in 1871, published his treatise on "Spinal Concussion."

He described fifty-three cases of spinal injury, received chiefly during railway accidents, which had no external evidence of such injury. The list embraced cases of fracture, hematomyelia, meningitis, hysteria, and neurasthenia. To these he gave the name "railway spine," and this term is extensively employed by lawyers for litigants, even at the present time, to represent an imaginary clinical entity.

Oppenheim, in 1880, made a closer distinction between organic injuries and those not marked by histologic changes, and proposed the term "traumatic neuroses" for the latter class. About the same time Charcot taught and demonstrated that the nervous symptoms in these cases, apart from those attributable to organic lesions, were precisely the same as are presented in neurasthenia and hysteria. The latter two conditions may develop after a fright, or after a railway or other accident. They do not, however, differ in any degree in their symptoms or diagnosis from a neurasthenia or a hysteria, which do not follow trauma. Many of the symptoms develop immediately, and are so greatly improved after the settlement of a claim for damages as to have caused them to be termed *litigation symptoms*.

In some cases there is distinct simulation. A celebrated case is that of a patient who claimed to have had a dislocation of the atlas upon the axis, and had typical hysterical blindness, and paralyses of motion and sensation, shifting from one limb to the other. X-rays were shown in court which accurately resembled such a dislocation. X-rays were taken of a normal individual (Fig. 468), and it was shown that it was possible to reproduce exactly the symptoms of the claimant, who had voluntarily thrown the head forward while having a skiagraph so as to simulate a dislocation. For the diagnosis of neurasthenia and hysteria the reader is referred to text-books on nervous diseases.

Traumatic Spondylitis.

This interesting post-traumatic condition was first described by Schede and later by Kümmell. It is in reality a softening of the ver-

tebral body following an injury, with the gradual yielding of the body and resultant angular deformity. It follows injuries of the same nature as those which cause the other post-traumatic lesions previously described. The distinctive feature of the disease is the fact that pain along the compressed nerves appears months to years after the injury. Accompanying these pains there are often paralyses of varying degrees, and the gradual development of an angular deformity, or gibbus, similar to that observed in tuberculous spondylitis (page 688). In some cases there is a general increase of the curve of the spine. In these cases the diagnosis cannot be made until the deformity or paralysis appears, which occurs a considerable period after the injury.

The chief conditions from which it must be differentiated are simulation and a tuberculous spondylitis. The former is excluded by the objective evidence of the angular deformity or general increase of the curve of the particular region involved. The tuberculous condition is more frequent in early life, accompanied by muscular spasm and abscess formation, and there is less tenderness than in traumatic spondylitis.

GUNSHOT AND STAB WOUNDS OF THE SPINE.

The symptoms and diagnoses of both of these forms of injury do not differ from those of other traumatic conditions. Stab wounds usually cause contusion of the cord, producing in the majority of cases a partial paralysis of the Brown-Séquard type (see page 666).

Half of the cord is not always severed, but the surrounding degeneration produces the remainder of the symptoms.

In gunshot wounds one finds the symptoms of fracture of the body of the vertebra plus those of paralysis, or the signs of fracture of the arch or spinous process. One cannot tell whether the paralysis is due to the bullet itself or to compression by a splinter. The *x*-ray may be of some aid in this direction.

The cord symptoms differ in no manner from those following ordinary fractures or dislocations of the vertebræ. They may, however, disappear entirely.

DISEASES OF THE SPINE.

TUBERCULOUS SPONDYLITIS (POTT'S DISEASE).

This and scoliosis are the two most frequent non-traumatic affections of the spine. It rarely involves any other part of the vertebra than its body, producing a gradual disintegration of the latter. In about half of the cases, an abscess is found clinically, whose pus gravi-

tates along intermuscular planes, from the original focus. These abscesses usually present externally in certain definite places, according to whether the primary disease is in the cervical, dorsal, or lumbar regions (see below). The destruction of two or more adjacent vertebræ results in the formation of one of the most typical signs of the disease, viz., an angular deformity (see below). A complication of the disease

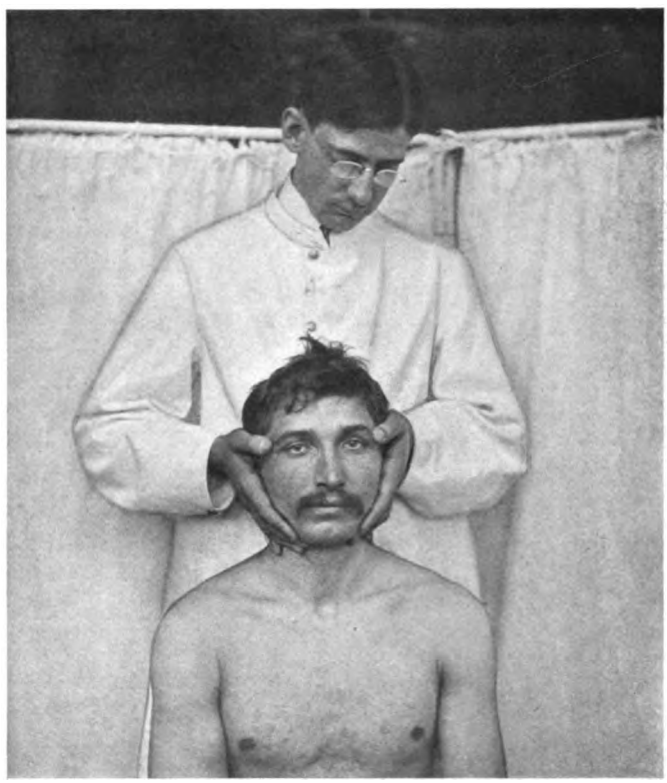

FIG. 467.—METHOD OF EXAMINATION OF THE HEAD AND NECK IN ORDER TO DETERMINE THE PRESENCE OF AN INFLAMMATORY AFFECTION OF THE UPPER CERVICAL VERTEBRA.

The surgeon should stand behind the patient, grasping the head between the extended hands, the finger-tips being placed below the lower jaw. The head is then caused to bend forward and backward, eliciting pain during these movements. Such evidence of pain is ordinarily not to be obtained in these cases of disease of the atlas or axis, on account of the voluntary fixation of the spine on the part of the patient.

is its extension to the membranes of the spinal cord, the resulting pachymeningitis giving rise to pressure symptoms of varying degree.

Primary disease of two vertebral bodies in different, non-adjacent parts of the spine is rare. The two most frequent localizations of a tuberculous spondylitis are in the twelfth dorsal and first lumbar (dorsolumbar junction) vertebræ, and next in order in the seventh

cervical and first dorsal vertebræ (cervicodorsal junction). *The most important diagnostic symptoms of the disease are:* (1) The reflex rigidity of the spine; (2) the referred pains; (3) the presence of an angular or more gradual deformity; (4) the formation of abscesses; (5) the symptoms of spinal cord involvement. *Of these the presence of the prominence, associated with muscular rigidity, and its resultant attitudes and gaits are sufficient to make a diagnosis if the diseases to be described (malignant tumors, fractures, etc.) are excluded.*

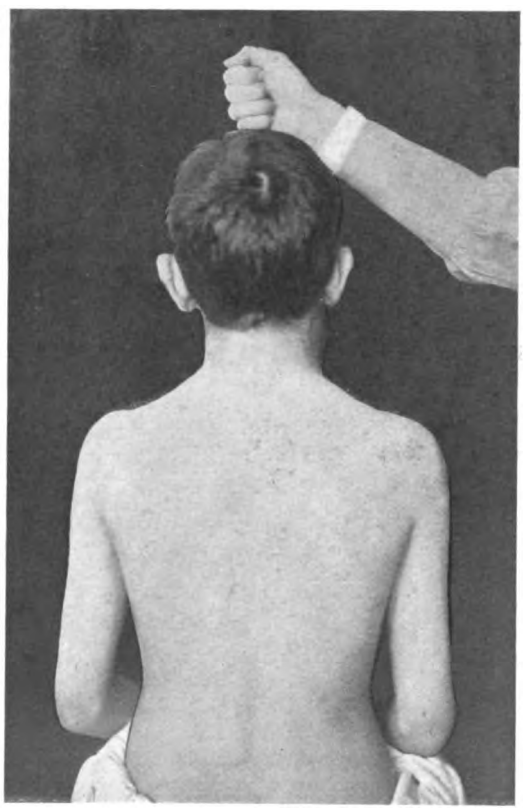

FIG. 468.—METHOD OF TAPPING HEAD IN ORDER TO DETERMINE TENDER POINTS IN SPINE.

1. *Rigidity of the Spine.*—If the disease is located in the upper cervical region (atlas or axis) the head and neck are either held in a wryneck attitude or the head is rigidly fixed in the median line. Every effort to rotate the head or to flex the head upon the neck (Fig. 467) is resisted, or accompanied by great pain. The patient attempts to fix the head voluntarily, by supporting the chin upon the hands.

In disease of the lower cervical or upper dorsal region, the chin is held raised, the muscles of the back of the neck and of the back itself are contracted and cause the spine to be held stiff and straight. It is difficult for the patient to lean forward or to pick up objects from the floor.

In disease of the lower dorsal and upper lumbar vertebræ the muscles of the back can also be felt to be contracted. The spine is held rigid, and this is most marked when the patient bends over or walks. The gait is characteristic. In the effort to fix the spine the patient will throw the shoulders and head back, and walk by sliding the feet along

the floor, so as to move the pelvis and the lumbar spine as little as possible. There is also flexion at the hip (Fig. 469), and the patient steps on the toes. In disease of the cervical and upper dorsal region the patient walks with head fixed in the median line, shoulders raised, and spine erect.

The rigidity in the dorsolumbar region is best tested by raising the limbs while the patient lies prone upon the table.

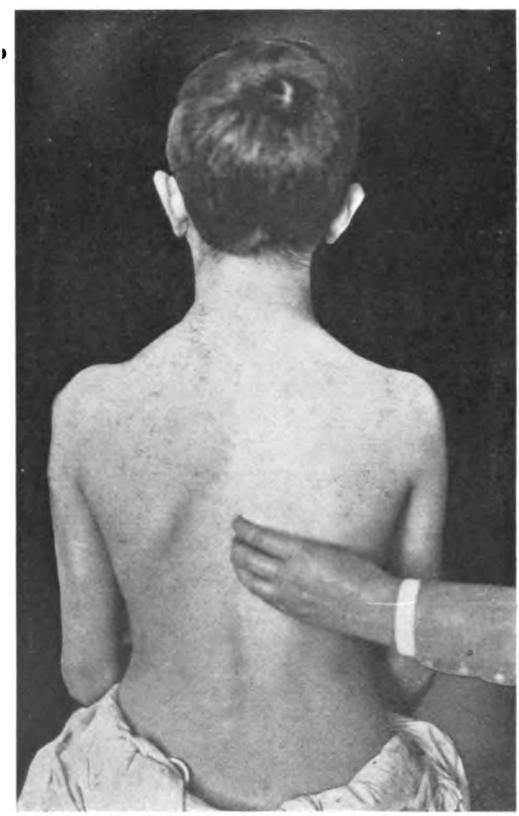

FIG. 469.—METHOD OF PALPATION OF THE SPINOUS PROCESSES FOR TENDERNESS. (See text.)

2. *Pains.*—The pain of Pott's disease is more often referred to distant points than to the diseased vertebra. It is usually referred to the terminations of the corresponding spinal nerves. In diseases of the cervical region, the pain is referred to the back of the head or neck, or to the mastoid region, or along the arms. In disease of the dorsal and lumbar vertebræ, the pains are referred to the peripheral ends of the corresponding intercostal and abdominal nerves. It is not uncommon for such patients to complain of stomach-ache, pains like those of a pleurisy, intercostal neuralgia, or lumbago, or pain in the bladder, etc. The pains are always worse at night, and are increased by any movements of the spine. In some cases the pain is elicited by tapping upon the head (Fig. 468) or pressing upon the spines.

3. *Deformity.*—This, when present, is sufficient to make a diagnosis. In acute cases there is accompanying muscular spasm and referred pains, while in subacute or chronic cases the deformity is usually present without rigidity, and the pain is minimal.

The deformity, or *gibbus*, as it is called, may be quite sharp and cause an angular prominence of the spines of only two or three vertebræ, or it may involve a number of vertebræ. The curve in the latter instance, is a more gradual one. This is especially apt to be so in the more chronic cases. Accompanying this angular deformity there are marked changes in the contour of the head and thorax, as well as a retardation of the general body growth.

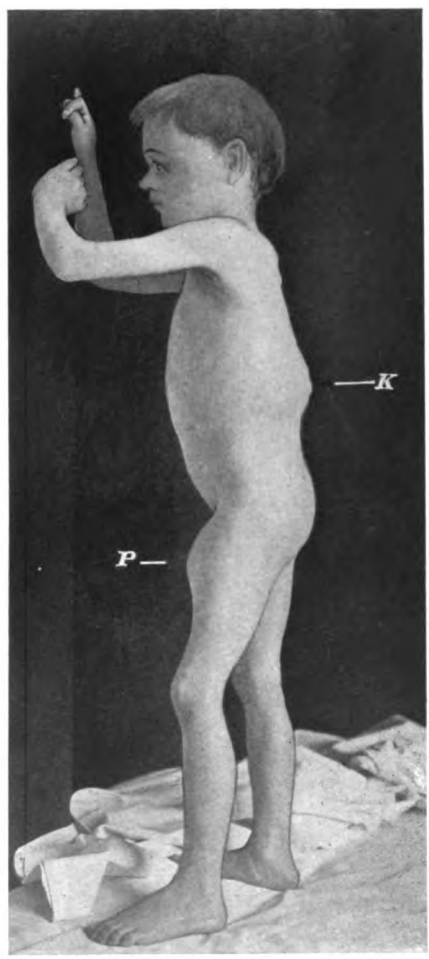

FIG. 470.—KYPHOSIS AT DORSOLUMBAR JUNCTION, DUE TO TUBERCULOSIS OF THE LAST DORSAL AND FIRST LUMBAR VERTEBRA.

K, Points to apex of kyphosis, or backward angle of deformity of spine; *P*, points to a large psoas abscess, the anterior view of which is seen in Fig. 471.

4. *Abscesses.*—Although at autopsy a collection of pus is invariably found, it can be recognized clinically in only one-half of the cases. In cervical disease, the abscess is found either in the retropharyngeal space or in the lateral regions of the neck. In the latter location it simulates an abscess having its origin in caseous lymph-nodes, but is usually larger and accompanied by the spinal symptoms—rigidity and pain on movement.

In disease of the dorsal region the abscess may appear upon the back and simulate a lipoma (Fig. 134), or an abscess having its origin in disease of the ribs. Disease close to the dorsolumbar junction causes abscesses which may appear (*a*) in the lumbar region over the kidney, or (*b*) above Poupart's ligament, simulating a reducible oblique inguinal hernia, or (*c*) over Scarpa's triangle, simulating a femoral hernia (Fig. 471). In the two latter locations the detection of fluctuation, the absence of an impulse on coughing, and the spinal symptoms soon clear up the diagnosis.

5. *Spinal Cord Symptoms.*—These are an infrequent complication, but occur especially often in the more acute cases. The motor paralysis is usually the most marked symptom. It varies from weakness to complete loss of power. The paralysis is at first of the flaccid type, but later spasticity with resultant contractures occur. The paralysis sets in gradually, but may increase rapidly, with exacerbations. It often improves with betterment of the local condition.

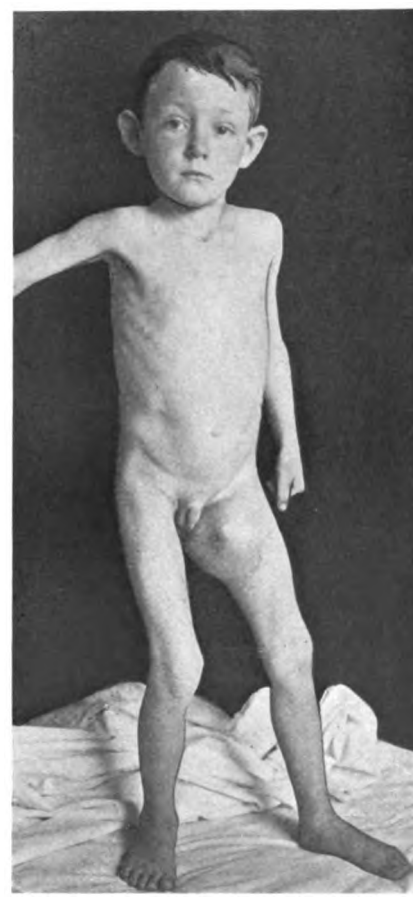

FIG. 471.—ENORMOUS PSOAS ABSCESS OVER SCARPA'S TRIANGLE IN BOY SUFFERING FROM TUBERCULOUS SPONDYLITIS OF THE DORSOLUMBAR REGION.

In upper cervical disease the arms and legs are both paralyzed, and there may be dysphagia, etc. In these cases death may occur suddenly, following spontaneous dislocation of the atlas upon the axis. The sensory paralysis is very atypical because the posterior portions of the cord are but little involved. There may be anesthesia or hyperesthesia, or only paresthesia. The reflexes are exaggerated at first, but later are absent.

In addition to the chief diagnostic features of tuberculous spondylitis just enumerated, viz., rigidity, pains, deformity, abscesses, and paralyses, it is of great value to obtain a history of tuberculosis in the family or of foci elsewhere in the body (lymph-nodes, joints, lungs, kidney, testis, peritoneum, etc.). The general condition shows quite marked changes. The patients are emaciated and anemic. There is a difference between morning and evening temperatures of from one to three degrees.

Differential Diagnosis.—*Wry-neck.*—Disease of the cervical spine must be differentiated from the various forms of wry-neck. The principal features of the rheumatic, congenital, and inflammatory forms,

the last named from inflamed lymph-nodes, have been fully considered on page 150.

Diseases close to the dorsolumbar junction must be differentiated from the following conditions:

Hip Disease.—This has been considered on page 632. The restriction of motion at the hip in Pott's disease is in only one direction, viz., hyperextension, owing to contraction of the psoas. The lumbar spine, although held somewhat rigid in hip disease, as a compensatory condition, is arched and less fixed than in Pott's disease.

FIG. 472.—SCOLIOSIS.

Showing principal curvature to right in dorsal region, and compensatory, in opposite direction, in lumbar and cervical regions. The prominence of the posterior portion of the thorax well marked on side of curvature. The difference in the contour of the chest also to be noted.

Other Forms of Backward Curvature or Kyphosis.—Rachitic kyphosis is a gradual one extending over the entire dorsal and lumbar regions. There is no muscular rigidity, and there are always other signs of rachitis (see page 590).

Senile kyphosis (Fig. 114) involves chiefly the dorsal vertebræ, and is also gradual. There is no rigidity or pain. Other conditions which require differentiation are scoliosis (page 691), hysterical spine (page 692), arthritis deformans of the spine (page 691), malignant disease (page 693), and acute osteomyelitis of the spine (page 691).

SCOLIOSIS (LATERAL CURVATURE OF THE SPINE).

This is an affection which appears during the years of growth, *i. e.*, from the sixth to the sixteenth years. Often the first complaint is from the parents, who have noticed that the child carries one shoulder higher than the other. In the majority of cases the diagnosis can be readily made by inspection from behind when the patient is divested of the clothing down to the level of the hips (Fig. 472). The most frequent curve of the spine is that in which there is a convexity in the dorsal region, to the right (right dorsal scoliosis). The right shoulder is higher, the scapula

on the side of the convexity stands out, and is also higher than its opposite. The thorax below the scapula on the same side is more rounded, and there is a corresponding enlargement on the left side of the front of the thorax.

There is a much wider space between the right arm and the side of the trunk than on the left side. If the spines of the vertebræ are marked with ink the curvature becomes quite clear. There are always compensatory curves in the opposite direction above and below the primary one (Fig. 472). The cervicodorsal and lumbar curvatures are less frequent than the dorsal. Lateral curvature may result from various causes, viz.: (1) Rachitis; (2) a sequela of infantile paralysis; (3) torticollis; (4) occupation; (5) chest diseases, especially after empyema; (6) a sequela of sciatica; (7) as a result of faulty posture. The latter is the most frequent.

ARTHRITIS DEFORMANS OF THE SPINE (SPONDYLITIS DEFORMANS).

This occurs as a part of the general disease of the joints previously described (page 615). As elsewhere its chief clinical features are pains and gradually increasing stiffness of the spine. Gonorrhea is a not infrequent cause. The disease occurs oftenest in elderly persons, but may be one of the manifestations of a generalized arthritis deformans at any age (Fig. 413). The patients at first complain of pains like those of rheumatism, especially referred along the cervical and branchial nerves. This stage is soon followed by gradually increasing rigidity, most marked in the cervical region. The patient is unable to flex or rotate the neck. In some cases flexion is possible, but there is inability to extend the neck (Fig. 414).

In many cases the cervical region is the last to be affected, the lower part of the spine being first involved. The spinal rigidity is often accompanied by the same condition in the hips. There is no angular deformity as in Pott's disease, the whole spinal column is more apt to be involved, and there is no tendency to abscess formation. Spondylitis deformans is a frequent complication of gonorrhea. The diffuse stiffness of the spine, the slight backward curve, the presence of the same conditions in the hip, knee, and other joints, as well as the absence of muscular rigidity, are the chief diagnostic points.

ACUTE OSTEOMYELITIS OF THE SPINE.

This rather rare affection presents no difficulties of diagnosis. The onset is a sudden one, with severe pain, high fever, tenderness on pres-

sure, and muscular rigidity. The formation of abscesses occurs early, and is indicated by the appearance of redness, induration, and heat in the vicinity of the affected vertebræ.

TYPHOID SPINE.

This appears during convalescence from typhoid, and is most apt to involve the lumbar portion of the spine. There is localized tenderness and pain. Disturbances of sensation, such as paresthesia and hyperesthesia, are frequent. The diagnosis can be made from an acute form of tuberculous spondylitis, by the absence of angular deformity, and of abscess formation, as well as from the history of a preceding typhoid.

HYSTERICAL SPINE.

This occurs oftenest as the result of an injury, and has been previously discussed under the head of spinal concussion (page 683). It is a local spinal manifestation of a general neurasthenia. By careful and repeated examinations one can readily eliminate any or all of the other forms of genuine spinal disease.

There is complaint of tenderness, which is often greatly exaggerated. There is no true rigidity, although some may be feigned, and can be discovered when the attention is diverted. Pressure over the same spinous process will at one examination be said by the patient to be very painful and later not noticed.

TUMORS OF THE SPINE AND SPINAL CORD.

Neoplasms, whether they arise from the vertebræ, from the meninges, or from the cord itself, can, as a rule, only be recognized *by the symptoms resulting from pressure upon the spinal nerves and cord.*

Schlesinger has recently collected 151 cases. Of these 104 involved the vertebræ primarily, 4 grew into the spinal canal from without, 11 arose from the dura, 4 from the pia-arachnoid, 5 from the nerve-roots, and 20 were intramedullary.

As a rule, all of these tumors are of more diagnostic, than therapeutic interest. The majority of those which arise from the vertebræ are of secondary carcinomatous nature. The latter are frequent after primary growths in the breasts, thyroid, and prostate. Those which are not metastatic are primary fibromata or sarcomata of the bodies. The most frequent meningeal and intramedullary growths are the gumma,

tubercle, glioma, and sarcoma. The gliomata give rise to a clinical picture described as syringomyelia (page 624).

The first symptom to attract the attention of the patient, in all of these neoplasms, is pain.

The pains affect a single spinal nerve or a pair. *Often a persistent unilateral or bilateral intercostal neuralgia is one of the earliest symptoms.* At first the pains are mild, but may become sharp and lancinat-

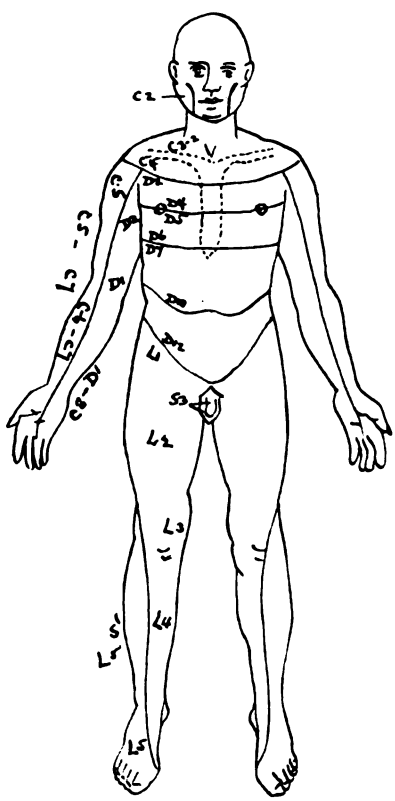

FIG. 473.—CUTANEOUS NERVE SUPPLY TO THE ANTERIOR SURFACE OF THE BODY (Seiffer).

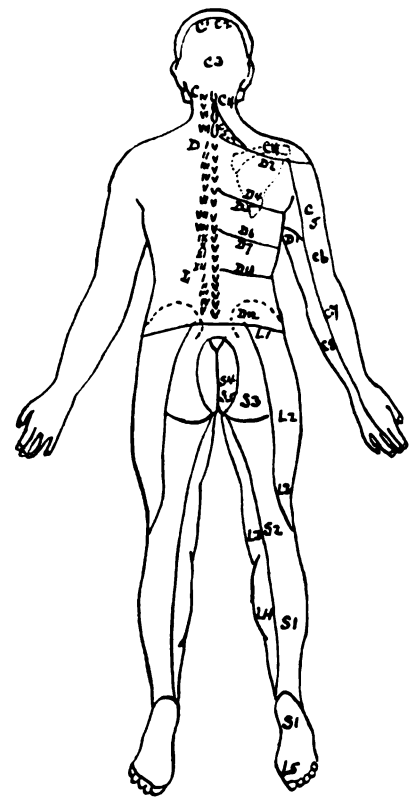

FIG. 474.—CUTANEOUS NERVE SUPPLY TO THE POSTERIOR SURFACE OF THE BODY (Seiffer).

ing, or remain as a constant dull ache. These pains are at first accompanied by hyperesthesia over the area of distribution of the nerve. This neuralgic stage may persist for months to years, and the patient be treated for neurasthenia, etc., until signs of motor irritation and paralysis appear. The symptoms of motor irritation, like twitchings, spasms, and rigidity, are soon replaced by muscular weakness and finally by complete paralysis. The latter is at first apt to affect only

one extremity, but the opposite one is soon involved, so that a para paresis or paraplegia develops.

The sensory symptoms most frequently correspond to the Brown-Séquard type (page 666), but the anesthesia is also frequently bilateral.

The reflexes below the level of the lesion are markedly increased, and this exaggeration follows the paralysis closely, the reflexes being lost when the compression is total. There is early involvement of the sphincters of the bladder and rectum, as well as the development of extensive decubitus. To locate the seat of the tumor a knowledge of the areas

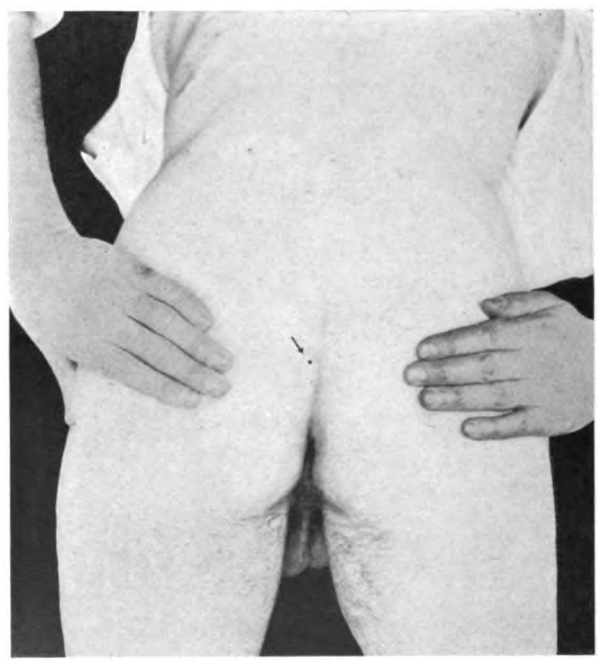

FIG. 475.—FISTULA OF COCCYGEAL REGION LEADING INTO A DERMOID CYST.
The arrow points to the black spot which represents the opening of the fistula.

of cutaneous sensation supplied by the various spinal segments is of the greatest importance (Figs. 474 and 473), as showing the upper levels of the dysesthesia.

The diagnosis depends upon a knowledge of the more or less regular order and gradual appearance of the symptoms, viz.: (*a*) Neuralgic pains; (*b*) monoplegia, later paraplegia; (*c*) anesthesia; following motor paralysis; (*d*) exaggerated, and absence of reflexes. The presence or history of a primary growth elsewhere is of great value.

From Pott's disease malignant disease can be differentiated by the

fact that the deformity when present is not angular, as in Pott's disease, but more rounded. In those tumors which arise from the cord itself there is no deformity, only neuralgic pains and muscular stiffness. The pains are never as severe in Pott's disease as in tumor. The symptoms of tumors of the cauda equina do not differ from those of injuries of the same (page 670).

SACROCOCCYGEAL TUMORS.

A number of interesting congenital conditions are found in the region of the sacrum and coccyx. They may be of three varieties:

1. *Teratomata.*—These are irregular, pendulous tumors attached to the posterior surface of the sacrum or coccyx. In one class rudiments of the skeleton and of the different viscera are found. These are remnants of a parasitic fetus, which has failed to develop. In another class there is a great variety of tissues which do not, however, represent any single organ.

2. *Cystic Tumors Behind the Rectum.*—These are found between the rectum and sacrum. The majority have their origin in persistent remnants of the post-anal gut and neurenteric canal. The unilocular variety form large cysts, and may project into the rectum. The multilocular form is made up of a number of cysts, each containing a rope-like substance resembling mucus. Dermoids also occur within and behind the rectum, and may attain a large size.

3. *Sequestration Dermoids.*—These occur over the sacrum and coccyx, and allied to them are the sinuses and dimples which occur here (Fig. 475). The sinuses open near the tip of the coccyx.

CHAPTER VII.

POSTOPERATIVE COMPLICATIONS.

These have assumed such importance at the present time, when the scope of operative interference has been so greatly extended, that the ability to recognize them at an early period renders it advisable to add a chapter on the subject. They may be divided in one of two ways, viz.:

A. According to the individual operations or regionally, *i. e.*, the part of the body operated upon.

B. According to the most prominent symptom or the organ involved in the complication.

The latter classification seems the most satisfactory from a diagnostic point of view and will be followed here. According to this mode of division the most important postoperative complications are:

1. Hemorrhage.
2. Shock and collapse.
3. Infection, not including peritonitis.
4. Pulmonary complications.
5. Cardiac complications.
6. Hepatic complications.
7. Gastro-intestinal complications, including postoperative ileus and peritonitis.
8. Postoperative ileus.
9. Postoperative peritonitis.
10. Renal complications.
11. Circulatory complications (thrombosis, etc.).
12. Miscellaneous postoperative complications.

HEMORRHAGE.

Hemorrhage following an operation may occur from the wound itself in one of three ways:

(*a*) As the result of imperfect hemostasis, either from ligating bleeding vessels too loosely or not having secured a sufficient number of bleeding vessels, the temporary closure by clots being disturbed through movements of the patient.

(*b*) As the result of constitutional causes. In this group belong those unavoidable hemorrhages which occur as the result of hemophilia and long-continued jaundice.

(*c*) As the result of infection of the wound. The thrombi, which obliterate the cut ends of the vessels, become disintegrated as the expression of a purulent softening due to microörganisms. This was formerly called secondary hemorrhage and was far more frequent than at present, when septic infection is rare.

Hemorrhage may take place after operations either (*a*) in such a way that it can be recognized at once by the reddish staining of the dressings, accompanied by increasing symptoms of anemia, *i. e.*, *external hemorrhage*, or (*b*) there may be no escape of blood from the wound or the latter may not be accessible to observation. Such postoperative bleeding is apt to follow intraabdominal operations or those upon the stomach or rectum.

These last-named hemorrhages may be properly termed *concealed or internal*, since they can only be diagnosed by recognizing the symptoms characteristic of internal hemorrhage in general, viz., those of rapidly increasing anemia and the other symptoms, such as recurrent attacks of syncope, thirst, restlessness, and rapid, empty pulse.

The diagnosis of the actual existence of the first clinical variety, viz., external hemorrhage, presents no difficulty. The blood is seen escaping either in large quantity, or there is constant oozing which frequently resists all of the ordinary methods of treatment. At times a gradually increasing hematoma may be the expression of this form of postoperative hemorrhage.

In cases where the hemorrhage is due to constitutional causes, like hemophilia, inquiry into the previous history of the patient himself or of the family will often result in a history of frequently recurring obstinate hemorrhages from the slightest of causes.

Hemorrhage due to persistent jaundice, almost invariably follows gallstone operations, and may often be recognized as such by an examination of the coagulation time of the blood, this being greatly decreased.

Hemorrhage as the result of sepsis appears much later than either of the two preceding, and is accompanied by such marked local signs that its recognition is not difficult.

The hemorrhage spoken of as concealed or internal is much more difficult to recognize than any of the above. It may follow any operation in a serous cavity, such as the brain, pleura, or peritoneum. In the brain the symptoms are those characteristic of cerebral compression (see page 36). In the peritoneal cavity the symptoms resemble those

following rupture of an extrauterine pregnancy, viz., gradually increasing pallor, soft, thready pulse, restlessness, and great thirst. Locally there are signs of irritation, from the presence of free blood in the peritoneal cavity. These symptoms of peritoneal irritation are rigidity of the abdominal wall gradually becoming quite diffuse, accompanied by tenderness on pressure, and a moderate amount of tympanites (from paresis of the intestinal muscles). These symptoms are the same as those of a beginning peritonitis, and the question may be asked, How can the diagnosis of internal hemorrhage be made from those of a beginning septic peritonitis? The answer is, that if the hemorrhage is not sufficiently marked to produce signs of general anemia, a differentiation in the early hours is impossible. Later on, *i. e.*, after six to twelve hours, the continuation and increase in gravity of the peritoneal symptoms, unaccompanied by those of general anemia, indicate septic infection. In some cases both may be combined and the symptoms of hemorrhage in the early hours be followed by those of peritonitis later.

In general it may be said that the signs of internal hemorrhage appear soon after an operation, *i. e.*, in the first six hours, while those of infection occur at a later period.

A gradual fall in blood-pressure may also be of aid in distinguishing hemorrhage from postoperative peritonitis. The differentiation of shock from both of these conditions is considered under postoperative peritonitis and shock respectively.

Hemorrhage may occur after operations like a gastro-enterostomy or those on the rectum, like hemorrhoids, etc. The bleeding may take place into the lumen of the stomach or bowel in the first-named class of operations or into the rectum in the latter.

The early recognition of such cases is often impossible except from the actual inspection of blood, either vomited or passed with a bowel movement. The reason for this is that such a passage of blood may not occur until the patient is almost exsanguinated. The only manner in which to diagnose such a concealed hemorrhage before either a bloody vomit or a tarry stool occurs, is by watching for the ordinary signs of internal hemorrhage. These are (*a*) gradual or rapidly increasing pallor of the skin and visible mucous membranes (lips, gums, tongue, and conjunctivæ); (*b*) restlessness, often accompanied by delirium or stupor; (*c*) great thirst; (*d*) the pulse becomes soft and very weak; (*e*) rapid fall of blood-pressure. The rate is not necessarily increased, since Nature's effort to check the hemorrhage is by the gradual onset of syncope. When hematemesis or evacuations of large quantities of

fresh or old tarry blood take place, accompanied by these signs of anemia, the diagnosis of concealed hemorrhage is not difficult.

SHOCK AND COLLAPSE.

The diagnosis of shock as a complication of injuries has already been referred to (see page 525). A similar condition may follow an operation, at times resulting in the death of the patients. The essential factor, as Crile has shown, is the exhaustion of the vasomotor centers, resulting in the blood collecting in the splanchnic area and a resultant fall in general blood-pressure. The heart is affected secondarily through the fall of blood-pressure, causing stagnation in the great venous trunks, and thus interfering with its action.

Postoperative shock is most apt to follow prolonged operations, and is especially frequent after those upon the viscera in the upper half of the abdomen. Collapse or syncope may follow operation, and is also due to a fall in blood-pressure, but from a different cause. It may be a sudden paralysis of the vasomotor centers, resulting from some violent afferent nerve stimulus, or it may be due to a sudden loss of blood. The clinical conditions described under hemorrhage should not be called collapse, since the vasomotor centers are intact. When, however, collapse following a severe hemorrhage has persisted for a considerable time, it begins to change into the condition of true shock, as the vasomotor centers become exhausted from their efforts to maintain the blood-pressure at the same level.

The chief symptoms of postoperative shock are the same as those following injury. These are (*a*) marked pallor and coldness of the skin and visible mucous membranes, accompanied by a slight tinge of cyanosis; (*b*) a small, irregular, and rapid pulse; (*c*) a stuporous or apathetic appearance of the patient.

The symptoms vary according to the cause. If they are the result of a sudden vasomotor nerve paralysis, there is almost complete arrest of the heart's action, marked pallor, dilated pupils, cold sweat, cold often slightly cyanotic extremities, feeble or absent respiration, and almost complete loss of consciousness. If the collapse is due to severe hemorrhage, these symptoms differ only in having appeared after a period during which the signs of such hemorrhage, viz., of anemia, predominated. In some cases it is almost impossible to determine whether the condition of the patient is due to hemorrhage or shock. This has already been referred to in the diagnosis of concealed or internal hemorrhage.

In general, shock is more apt to follow prolonged operations or those upon the brain, genitalia, abdominal viscera, etc. The restlessness, pallor, and weakness of the pulse are not nearly as marked in shock as in hemorrhage.

In some cases it is very difficult to distinguish myocardial symptoms, such as a rapid, weak pulse, from those of shock.

INFECTION AS A COMPLICATION OF OPERATION.

Infection, like hemorrhage, may be recognized either through visible local signs combined with those of a more constitutional nature, or the latter may predominate to such an extent that the local signs become insignificant.

The most important of the general signs which indicate infection is usually a rise of temperature. In the majority of patients there is a slight rise of temperature for the first twenty-four to thirty-six hours after an operation. It is well to remember that in children this postoperative aseptic fever is relatively higher than in adults, and may be accompanied, especially in nervous children, by an increased pulse-rate, which would be alarming under other circumstances.

The temperature under these conditions varies greatly. It is usually from 99° to 101° F., rarely higher. The rise takes place within twelve hours after the operation, dropping to normal a few hours later. It is supposed to be due to the absorption of fibrin ferment from the wound, and is called, for lack of a more exact name, "ferment or aseptic fever." If, however, the rise of temperature should recur upon the evening of the second day after the operation, suspicion should be aroused that infection has taken place. This secondary rise or continuation of the immediate postoperative fever will remain for a variable period, according to the nature of the infective lesion, and will usually be accompanied by local signs indicative of the virulence of the infection. The various septic complications of an operative wound differ in no particular from those following an injury. It will, therefore, not be necessary to repeat here what was said on pages 529 to 554 about sapremia, pyemia, and the other infective wound diseases. At times, however, infection may occur in a wound with very little, if any, fever, owing to the low grade of virulence of the organisms.

After operations within the cranial, pleural, or peritoneal cavities infection of the corresponding serous membrane may occur. The symptoms and recognition of these complications require no special mention, since they differ but little, except in the history, from those

originating without such operative wound. The diagnosis of postoperative septic peritonitis will be considered in connection with that of postoperative ileus.

PULMONARY COMPLICATIONS FOLLOWING OPERATIONS.

The increased frequency of these, has directed the attention of surgeons not only to their early recognition, but to the study of their causes and prevention. It is not within the province of this book to discuss the latter. The frequency with which the various forms of postoperative pulmonary complications occur and their relative influence on results are well shown in a recent publication of Bibergeil.[1] He found 283 pulmonary complications, *i. e.*, 7.2 per cent., in 3909 abdominal operations from Körte's clinic.

Of these 815 were operations above the umbilicus.
2625 were operations below the umbilicus.
469 were operations both above and below the umbilicus.

These complications were:

		Mortality.
1. Pneumonia (lobular, lobar, hypostatic)	135	1.1 per cent.
2. Pulmonary embolism	12	0.3 " "
3. Pulmonary infarcts	9	11.0 " "
4. Bronchitis	82	
5. Pulmonary abscess	12	
6. Dry pleurisy	3	
7. Pleurisy with effusion	16	
8. Empyema	13	

9. In addition to these mentioned, among quite rare pulmonary complications are gangrene and acute edema.

For every hundred abdominal operations there were 3.5 per cent. pneumonias, either lobar, lobular, or hypostatic. This corresponds to the relative frequency in other large German clinics. The frequency of pulmonary complications is, of course, greatest in advanced life, or where there has been a preëxisting bronchitis, etc.

That postoperative pulmonary complications are not always the result of a general anesthetic, like ether, is demonstrated by the frequency with which they occur after local anesthesia.

These complications are, as stated above, most frequent after laparotomies, but they may occur as a result of almost any operation, such as operations in the mouth, herniotomies, ligation of varicose veins, etc. They are especially frequent after incarcerated or strangulated herniæ.

[1] "Archiv für klinische Chirurgie," vol. lxxviii.

The most common modes of origin are (*a*) by aspiration of mucus or vomitus; (*b*) by the detachment, from the field of operation, of thrombi which are carried to the lungs; (*c*) migration of organisms through the diaphragm.

The recognition of these various forms of pulmonary complications usually presents no difficulties, since *their physical and general signs differ but little from those observed in non-operated cases.*

The lobular and hypostatic forms of pneumonia occur far more frequently than does the lobar or croupous variety. The latter affects the right lower lobe oftener than any other.

Lobular and lobar pneumonia, pulmonary edema, pleuritis, and bronchitis belong to the complications which occur within the first week after an operation. Pulmonary infarcts, embolism, abscess, gangrene, empyema, and hypostatic pneumonia usually occur at a later period. In a few cases pulmonary edema immediately followed the administration of the anesthetic. One of the most distressing of these complications is *pulmonary embolism.* This may occur at such a late period, *e. g.*, when the patient is getting up, that all thought of any complication has been dismissed. A thrombus becomes detached, apparently without cause, from a vein in the vicinity of the field of operation, and is swept through the right heart into the pulmonary artery. It lodges in one of the primary bifurcations of the latter vessel (Fig. 476), and gives rise to most serious symptoms and often causes death.

Some of the emboli may not occlude the vessel, but float to the periphery of the lung and cause subpleural patches of embolic lobular pneumonia. In 40 out of 66 cases of pulmonary embolism collected by Lotheissen (quoted by Gebele[1]) the origin of the thrombus was in the veins of the leg; the next most frequent seat was the pelvic veins.

The recognition of the more serious form of pulmonary embolism is important. The symptoms usually appear quite suddenly at a time when least expected. There is great dyspnea, accompanied by cyanosis and shallow rapid respirations. The pulse becomes rapid and almost imperceptible, and death may ensue within a few minutes. In cases in which one recovers from this condition, the above symptoms gradually diminish in severity. The physical signs are practically *nil.*

CARDIAC COMPLICATIONS.

A patient with a normal heart very rarely develops postoperative cardiac complications. The effect of the anesthetic is a transient one,

[1] Gebele: "Beiträge zur klin. Chir.," vol. xlv.

FIG. 476.—SECTION OF LUNG SHOWING RAMIFICATIONS OF PULMONARY ARTERY AND LODGMENT OF AN EMBOLUS IN ONE OF THE POINTS OF BIFURCATION OF THE VESSEL.

This is condition found at autopsy in cases of pulmonary embolism. (See text.)

as a rule, leaving no trace after the patient has recovered consciousness. Even under pathologic conditions, it has been found that the anesthetics most frequently given, ether and chloroform, have no ill effects in the majority of cases of valvular lesions. It is only in cases of myocarditis that postoperative complications are liable to follow. In these death may occur as a result of the myocarditis, in from one to several days after the operation, the severity of which has been increased by the operation. Under the latter conditions, in elderly patients one not infrequently notices marked irregularity in the rhythm and volume of the pulse following an operation. In general the signs of such a myocarditis are an irregular, weak, and rapid pulse with feeble heart tones and evidences of cardiac dilatation.

HEPATIC COMPLICATIONS.

1. **Icterus.**—This may occur from a number of different causes, for example:

(*a*) It may be a symptom of an acute gastro-enteritis, occurring as a result of the toxic effects of the anesthetic upon the digestive tract.

(*b*) It has been described as a direct result of the toxic action of chloroform upon the blood. This is very rare, if it ever occurs.

(*c*) It may be a symptom of one of the postoperative complications to be described, as cholemia or acid intoxication.

(*d*) Postoperative obstruction of the common duct by a gallstone, which has either been overlooked during an operation for gallstones, or has passed down into the common bile-duct from the seat of formation of the calculus in the intrahepatic bile-ducts.

The diagnosis of the cause of the jaundice in a given case can only be made by a careful study of the accompanying symptoms.

2. **Acid Intoxication.**—This condition is placed under the head of hepatic complications because in a number of cases, in which the liver has been examined microscopically, acute fatty degeneration in some cases [1] and necrotic changes in the parenchyma in others [2] have been found.

This complication has been given various names, such as cholemia, acidosis, acetonemia, and acid intoxication. The last-named term seems the most appropriate for the present, although the condition is one of a toxemia due to hepatic insufficiency. It may be the result

[1] Bevan and Favill: "Jour. Amer. Med. Assoc.," Sept., 1905.

[2] Eisendrath: "Jour. Amer. Med. Assoc.," Nov., 1901.

of a number of toxic agents, viz., anesthetics (especially chloroform), poisons, infective microörganisms, and pregnancy. These affect the secreting cells of the liver, and prevent their normal function. Acetone and diacetic and oxybutyric acids are found in both the blood and urine. They are, however, to be regarded as by-products, and not as the essential causes.

They are of various degrees. In the milder form the recovery is rapid, showing as symptoms only restlessness, mild delirium, and drowsiness after the anesthesia. Bevan and Favill have collected 30 cases, of which 28, including their own, were fatal. Twenty-three of the 30 followed chloroform anesthesia. In the graver cases the symptoms are delirium, vomiting, restlessness, convulsions, coma, Cheyne-Stokes respiration, cyanosis, and icterus in a variable degree. The most characteristic symptoms, according to Brewer,[1] are a sweetish odor of the breath, delirium, and rapidly fatal coma. According to Kussmaul, to these symptoms are to be added "air hunger," *i. e.*, deep breathing accompanied by a bright red color of the mucous membranes. In the case described by the writer in 1901, the chief symptoms were delirium, coma, intense jaundice, and very high temperatures, to 108° F. These symptoms of acid intoxication have appeared from ten to one hundred and fifty hours after operation.

GASTRIC COMPLICATIONS.

The most frequent gastric complications are:

1. Vomiting.
2. Hematemesis.
3. Acute dilatation of stomach.

1. **Vomiting** after operation may occur at various periods, and the diagnosis of its cause rests upon three factors:

(*a*) Length of time which has elapsed since the operation.

(*b*) Character of vomitus.

(*c*) Accompanying symptoms.

(*a*) *Length of Time after Operation.*—If the vomiting is due to the anesthetic, it usually occurs before the patient has become fully conscious, *i. e.*, in the first twelve to twenty-four hours after operation. Ether and chloroform differ somewhat in this respect. If due to ether, it occurs usually before the patient regains consciousness and is brief in duration. It begins early and ends early. With chloroform, the nausea and vomiting may begin immediately after operation, but more commonly they

[1] "Annals of Surgery," vol. xxxvi.

begin late, being delayed as long as twenty-four hours. Postoperative chloroform vomiting is quite persistent, often lasting three to four days. If vomiting after either anesthetic persists longer than twenty-four to forty-eight hours after operation, other postoperative complications must be thought of, and search made for symptoms which will either confirm the suspicion of their presence, so that a diagnosis may be made, or exclude their presence. One of the most frequent causes of prolonged postoperative vomiting, is defective excretion of urea, and not infrequently uremic complications are overlooked until too late to be remedied.

Persistent nausea and vomiting as symptoms of nephritic complications will be referred to again, under renal complications. Other causes of vomiting appearing later than the ordinary post-anesthetic vomiting may be due to acute dilatation of the stomach, postoperative ileus, and peritonitis. The diagnosis can only be made in such cases from the character of the vomitus and the symptoms characteristic of these conditions. Let it not be forgotten that occasionally chloroform vomiting will persist for a number of days, accompanied by violent headache and great depression. The majority of these cases are due to renal complications. Another cause of late postoperative vomiting is that of acid intoxication (see page 704).

Obstinate postoperative vomiting has frequently been observed following abdominal operations in neurotic individuals.

(*b*) *Character of Vomitus.*—The vomitus which occurs after ether or chloroform anesthesia consists of mucus, or mucus mixed with bile. If it persists for some hours after anesthesia, it may consist of bile alone. In operations about the mouth, nose, or throat the vomiting of large amounts of blood, *i. e.*, hematemesis, may be a complication of an abdominal operation and is referred to later. In acute dilatation of the stomach, which will also be described, the vomitus is a brownish sour liquid, which attracts attention on account of the large quantities brought up with each effort. The diagnosis of these conditions can be made from the brownish character of the vomitus, from the accompanying symptoms of collapse and the distention of the upper abdomen. The vomiting occurring as a result of postoperative peritonitis or ileus will be described under three heads.

(*c*) *Accompanying Symptoms.*—The vomiting due to ether or chloroform is seldom accompanied by other symptoms than those of nausea or vertigo. If the vomiting due to one of these anesthetics persists for a number of days, it is accompanied by great mental depression and anxiety, hollow sunken eyes, retracted abdomen, diminished

excretion of urine, dry skin, etc. If vomiting is due to other causes, such as postoperative nephritis, ileus, peritonitis, acid intoxication, or acute gastric dilatation, the symptoms are those described under the respective heads in this chapter.

2. **Postoperative Hematemesis.**—Reference has already been made under the head of "hemorrhage" to the vomiting of blood, occurring as the result of an improperly performed gastro-enterostomy. One of the first to call attention to this condition was von Eiselsberg, in 1899. He reported a number of cases in which it followed ligation of the omentum. Since this time, a number of others have directed attention to this postoperative complication. It has been found to follow a variety of abdominal operations, even on organs like the appendix. The etiology of the condition is still a matter of dispute. The vomiting of blood begins within the first twenty-four hours after the operation, there usually being an interval between the vomiting which is due to the anesthetic and that of the hematemesis. Usually an ounce of intensely acid blood is vomited at frequent intervals. The general condition is similar to that of an intense toxemia, with rapid, small pulse, and cold, moist skin. This condition is followed by a rapidly progressing collapse.

The diagnosis presents no difficulty, especially if the black blood vomited at frequent intervals is accompanied by the symptoms of toxemia mentioned above. The only condition with which it could possibly be confused, is acute dilatation of the stomach. In this, the vomitus is thin and brownish and the symptoms of collapse appear much more rapidly. The enormous swelling of the upper abdomen, with displacement of the lower viscera and interference with respiration, are also important diagnostic signs of acute dilatation.

3. **Acute Gastric Dilatation.**—This condition was formerly considered to be a very rare complication, but more recent observation has shown it to occur comparatively frequently. This later view is the result of closer observation and earlier diagnosis. The generally accepted theory of etiology is that it is the result of a paralysis of the muscles of the stomach wall, either of central or local origin, and may follow any abdominal operation, especially those upon the gallbladder and kidney.

The earliest and most common symptom is nausea and vomiting. This may begin soon after recovery from the anesthesia, increasing in severity in proportion to the degree of dilatation. In other cases it may not begin until the second or third day following the operation.

The vomiting can be distinguished from the ordinary postoperative vomiting by the gradual increase in the quantity of fluid. Enormous quantities of thin, brownish, sour fluid are vomited. The emesis is accompanied by symptoms of collapse. The upper half of the abdomen is at the same time much distended and dull on percussion, thus differentiating it from postoperative ileus, where it is tympanitic. The temperature is either normal or subnormal, the pulse increased in frequency, and the urine either greatly diminished or there is complete suppression. Through the stomach-tube, an excessive quantity of brownish fluid escapes. The change in contour of the upper half of the abdomen, and the decreased area of dullness after every expulsion of vomitus, show that this fluid is not free in the peritoneal cavity. Many of the milder cases recover spontaneously, although the majority end fatally unless speedy relief is given.

POSTOPERATIVE ILEUS.

This subject has attracted considerable attention. Various divisions have been suggested. The one hitherto accepted by the majority of surgeons has been that of Mikulicz into:

(*a*) Mechanical.

(*b*) Dynamic.

Finney[1] has recently suggested what seems to be a better classification; his division is as follows:

(*a*) Mechanical.

(*b*) Septic.

(*c*) Dynamic.

While the distinction is very often impossible, the diagnostic features are generally as follows:

Mechanical ileus is characterized by later onset, visible peristalsis, and severe colicky abdominal pains. The abdominal distention is asymmetrical, and at first there is no change in the pulse or temperature. Later the condition is characterized by persistent vomiting and constipation.

Septic ileus is often masked by the general signs of septicemia, thus differing in its clinical aspect from that of mechanical ileus.

A dynamic ileus develops as the result of a paralysis of the intestinal muscles, with few of the signs of obstruction and none of the signs of septicemia. The difficulty of differentiating an acute ileus from an acute peritonitis is apparent, and the later the case is seen, the more

[1] "Annals of Surgery," June, 1906.

difficult does this differentiation become, for advanced cases of obstruction are almost always complicated by peritonitis. In both conditions the leukocytes are increased, and in both the opsonic content of the blood is very high. The method of estimating this opsonic content of blood has recently been studied by Simon and Lemar.[1] This will be described on page 716. In favor of the diagnosis of obstruction are a rapid, feeble pulse; ashy, pinched countenance; rapid distention of the abdomen, which is not board-like; increased peristalsis; early and severe vomiting, soon becoming fecal; severe, cramp-like pain referred to the umbilical region, and absence of fever.

In some cases of postoperative obstruction no symptoms appear until weeks or months after the operation. The symptoms are usually due to bands or adhesions. The diagnosis in these cases presents no difficulty. The symptoms of obstruction appear in a patient who has previously been subjected to an abdominal operation.

There are other cases in which adhesions following an operation result in incomplete obstruction. In this class, especially frequent after appendiceal operations, the patients present a variety of symptoms. The patient may complain simply of colicky pains, accompanied by more or less abdominal distention and constipation. In other cases there is the history of colicky pains, accompanied by nausea and vomiting, recurring at irregular intervals. A form of postoperative ileus of the mechanical type, to be especially mentioned, is strangulation of a loop of intestine in a postoperative hernial opening. This may occur months or years subsequent to an operation.

POSTOPERATIVE PERITONITIS.

The occurrence of peritonitis is comparatively infrequent, as a postoperative complication at the present time. The symptoms and diagnosis do not differ in any respect from those occurring in peritonitis complicating disease or injury of any of the abdominal viscera, that is, not following operation.

The chief diagnostic points are: (*a*) Colicky pains, gradually increasing in severity; (*b*) uniform muscular rigidity, and tenderness on pressure over the abdomen; (*c*) rapidly increasing distention; (*d*) gradually rising pulse-rate, reaching 140 to 160, or even higher at the end of twenty-four hours; (*e*) absolute constipation, regardless of cathartics or enemas; (*f*) sunken eyes; anxious expression, subnormal temperature, general cyanosis, cold and clammy extremities, dry, coated

[1] "Johns Hopkins Hosp. Bull.," Jan., 1906.

tongue, diminished secretion of urine, vomiting and hiccough, often persistent.

The symptoms which should attract the most attention are the rapidly increasing pulse-rate, the condition of the abdomen, and the complete obstipation, neither feces nor flatus being passed.

RENAL COMPLICATIONS.

Both ether and chloroform have an irritant effect upon the normal kidneys. A large number of observers have found that in about 25 per cent. of all cases the administration of either of these anesthetics is followed by the appearance of albumin and of hyaline and granular casts in the urine. This condiiton of renal irritation lasts only from one to four days, as a rule, and does not give rise to any postoperative symptoms.

Cases, however, have been reported by Fränkel and others where prolonged (two to three hours) administration of chloroform has been followed in eight to ten days by death. In such cases the chloroform caused marked fatty degeneration of the heart muscle, as well as of the hepatic and renal parenchyma.

It has also been found[1] that during the administration of ether to animals, the excretion of nitrogenous substances is practically abolished.

The question which is of direct interest in respect to postoperative renal complications is, Do ether and chloroform have any ill effects upon the diseased kidney? There is some difference of opinion in regard to this question. There are some surgeons who believe that it is perfectly safe to give ether to nephritic patients. The majority, however, believe that the administration of chloroform, as a rule, is not followed by renal complications in those previously suffering from such disease. Ether may, on the other hand, be given to a large percentage of patients suffering from nephritis of the more chronic type and not be followed by any mild or graver signs of irritation.

In a certain percentage of cases there is indisputable clinical evidence that various forms of renal complications may occur after operation. This often takes place when least expected.

The various clinical forms of such complications are:

1. Mild uremic symptoms, such as (*a*) nausea and vomiting (prolonged many days after this common postoperative symptom should have ceased); (*b*) headache; (*c*) diminished quantity of urine, containing variable amounts of albumin and casts, and decrease in urea percentage.

[1] "British Medical Journal," Sept. 9, 1905.

2. Grave uremic symptoms—such as convulsions, restlessness, delirium, and coma. The secretion of urine may be practically abolished or it may contain the various constituents so characteristic of uremia under non-operative conditions. These may be blood, hyaline, granular, and epithelial casts, renal epithelium, large quantities of albumin, and a very small amount of urea.

Postoperative renal complications usually appear within twenty-four to forty-eight hours after the anesthesia. They may occur in the following classes of patients:

1. As an acute exacerbation of a latent nephritis, which had not been recognized before operation.

2. As an acute nephritis developing in a patient who had been previously known to have a chronic nephritis, either latent or active.

3. As a reflex anuria of one kidney, following operations upon the opposite, especially nephrectomy or nephrotomy.

The diagnosis in all of these classes of cases can only be made: (*a*) by excluding other conditions which might give rise to postoperative nausea, vomiting, delirium, etc.; (*b*) by the previous history of the case as to urinary findings; (*c*) by the examination of the urine both quantitatively and qualitatively.

CIRCULATORY COMPLICATIONS.

Thrombosis and Embolism.—Postoperative complications, at times of the gravest character, may be the result of a thrombosis of an adjacent vein, which has occurred either prior to such operation or has developed subsequently to it. In the former condition we speak of a preoperative and in the latter of a postoperative thrombosis. If the phlebitis is of a non-suppurative type, the condition may give rise to local signs, such as pain and swelling, or it may cause any of the forms of embolic pulmonary complications spoken of on page 702, viz., infarcts, pneumonia, embolism, and pleuritis. If the phlebitis is of the septic or suppurative type the clinical picture is more like that of a septicopyemia with the formation of metastatic foci of septic infarction or embolism.

The non-suppurative type of postoperative thrombosis is comparatively frequent. Cordier[1] in a recent paper states that it occurs in about 2 per cent. of all abdominal operations. It is most common after appendectomy, herniotomy, salpingectomy, oöphorectomy, and hysterectomy. It occurs even when the primary condition has been an asep-

[1] "Jour. Amer. Med. Assoc.," 1905, p. 1792.

tic one. Gangrene of the affected limb has never occurred. In the majority of cases either the right or left femoral or saphenous veins are affected or the veins of both sides.

In a number of cases the mesenteric or pelvic veins or those of the abdominal wall are affected.

Clinically these cases of phlebitis appear in one of two forms:

1. A variable time after operation, usually from the seventh to the fourteenth day, the patient may suddenly show the signs of pulmonary embolism described on page 702, viz., dyspnea, cyanosis, rapid pulse, etc. These are the cases in which either a diagnosis of phlebitis was not made, on account of the depth of the vein involved, or the clinical picture of a phlebitis was not recognized.

2. The phlebitis with resultant thrombosis appears about the tenth to fourteenth day. It causes pain referred to the location of the sapheni or other veins involved. Accompanying the pain there is tenderness over the course of the vein, and the latter can be felt (if the saphenous is involved) as a firm, tender cord.

If the femorals are involved, there is usually quite marked swelling of the entire limb, the edema being of a firm character, and the skin glossy and pale (the phlegmasia alba dolens of former days). At times all of the superficial veins are quite prominent and thrombosed.

The diagnosis in these cases of postoperative thrombosis is usually not difficult, if veins like the sapheni or femorals are involved. In the other veins a diagnosis before the occurrence of embolic symptoms is impossible.

MISCELLANEOUS POSTOPERATIVE COMPLICATIONS.

Postoperative Eruptions.—(*a*) *Surgical Scarlatina.*—This subject has been thoroughly reviewed by Dr. Alice Hamilton.[1] It may occur after almost any operation, in both adults and children. It does not differ clinically from ordinary scarlatina except in the following particulars:

1. It is especially apt to attack adults.

2. The period of incubation is shorter than that of ordinary scarlatina.

3. The eruption begins at the wound or in some other unusual place.

4. The throat symptoms are either mild or absent.

5. Desquamation occurs at an earlier period.

In the majority of cases reported in the literature as surgical scar-

[1] "American Journal of Med. Sciences," 1904.

latina, the eruption was either due to sepsis or to erysipelas. The latter is especially apt to be puzzling to differentiate, if it begins in the throat as an angina.

(*b*) *Septic Rashes.*—This greatly resembles a surgical scarlatina, but can be differentiated from it by the accompanying symptoms of septicemia. The eruption is usually a diffuse erythema, is accompanied by a marked rise in temperature, rapid pulse, restlessness, etc. It usually lasts only a few days. In children it appears even in mild cases of sepsis, and frequently the eruption is the only symptom present. There are usually no changes in the wound even in the graver cases. In these cases the symptoms of septicemia (page 537) accompany the eruption.

The following are some of the points which may help in distinguishing a septic from a scarlet fever rash:

1. The premonitory febrile symptoms are usually absent, the rash being the first thing noticed in most cases.

2. The distribution of the rash is irregular; it appears often simultaneously all over the body, and not, as in scarlet fever, on the neck and face first.

3. There are no throat symptoms, except in those cases where the wound is in the throat.

4. The pyrexia is high and of the septic type, with often marked intermissions.

(*c*) *Drug Eruptions and Poisoning.*—These may either be local, as the result of the action on the skin of the field of operation, or there may be more generalized eruption. They are frequent after the use of bichlorid of mercury, carbolic or salicylic acids, or any preparation containing iodin.

The localized eruption is either a fine pustular one, or there are all the signs of an acute dermatitis. The more generalized eruptions are usually of the erythematous type, often accompanied by intense pruritus.

The occurrence of postoperative symptoms of iodoform, carbolic acid, or of bichlorid poisoning are so rare at the present time that they require no special mention, being fully described in the text-books on therapeutics and materia medica.

DIABETIC COMPLICATIONS.

These are of the utmost importance, and may be of various forms.

1. A latent diabetes may be aroused into activity.

2. A previously existing diabetes may be greatly intensified and cause most serious complications. Glycosuria has been found to occur in normal individuals after operations. The sugar is, however, transitory and is so slight in amount as to have no clinical significance. The usual forms in which postoperative diabetic complications appear, are (*a*) as a gangrene of the edges of the wound or of a limb with early evidences of marked sepsis; (*b*) as a coma accompanied by pulmonary edema and resulting fatally within a few days after the operation; (*c*) as a marked glycosuria, which gradually subsides without giving rise to any general symptoms.

The development of these diabetic complications must always be borne in mind, not only in those whose urine was known to contain a trace or a larger quantity of sugar before the operation, but in every patient above middle age. A preoperative urinary examination must always include the test of sugar. The diagnosis of a diabetic coma must be made by excluding other causes for coma or gangrene and finding sugar in the urine.

POSTOPERATIVE PAROTITIS.

This occurs most frequently after abdominal operations, and is often described as a *cœliac parotitis*. It may also appear as a complication of inflammatory affections of the abdominal viscera.

The parotid gland of one or both sides is almost invariably involved. The inflammation may be (*a*) of a simple type, like that occurring in the epidemic form of parotitis (mumps); (*b*) abscess formation may take place; (*c*) gangrene of the parenchyma may occur. The diagnosis is not difficult. The appearance after an abdominal operation of a swelling, just in front of and below the ear, accompanied by tenderness and fever, is quite characteristic. If suppuration or gangrene occur, the local signs are correspondingly more marked.

STATUS THYMICUS.

This peculiar complication of anesthesia has been recognized for some time. After the administration of chloroform, death has suddenly occurred, accompanied by symptoms of cardiac and respiratory paralysis. In the autopsies on these cases, usually children, a general hyperplasia of the lymphatic structures has been found. The thymus gland is markedly enlarged and from this finding the condition first received its name.

ACUTE THYROIDISM.

This is a complication occurring after thyroidectomy. The symptoms are a great rise in temperature (103° to 108° F.), high pulse-rate, face flushed, restlessness, and at times delirium and coma.

The condition may be only a transitory one, or it may result fatally.

POSTOPERATIVE HYSTERIA.

This requires no special description. The diagnosis of the various forms, in which this protean affection may appear, does not differ in any manner from the recognition of hysteria occurring under other circumstances than as a postoperative condition.

CHAPTER VIII.

METHODS OF EXAMINATION.

EXAMINATION OF THE BLOOD IN SURGICAL CASES.

The methods of clinical examination of the blood which are of surgical interest are:

1. Counting the red and white corpuscles.
2. Estimation of the percentage of hemoglobin.
3. Examination for the plasmodium malariæ.
4. The differential leukocyte-count.
5. The determination of the opsonic index.

The technic of the first three of these is so fully discussed in the special books upon the blood and diagnostic methods that it may be omitted here.

DIFFERENTIAL LEUKOCYTE-COUNT.

Attention has been recently called by Gibson[1] to the value of the differential leukocyte-count in surgical cases, especially those due to infection. Normally the percentage of each variety of leukocyte, as given by Cabot,[2] in the blood of healthy adults is:

(*a*)	Small lymphocytes	20	to 30	per cent.
	Large lymphocytes	4	to 8	"
(*b*)	Polynuclear neutrophiles	62	to 70	"
(*c*)	Eosinophiles	0.5	to 4	"
(*d*)	Mast-cells	0.025	to 0.9	"

Sahli estimates the number of polynuclear neutrophiles at 70 to 72 per cent. Sondern's average for polynuclear neutrophiles in the normal blood is 68 per cent. Gibson has adopted 75 per cent. as a working average.

The method of estimating the different kinds of leukocytes is readily accomplished by staining a film of dried blood by the Ehrlich, Wright,[3] or Zollikoffer[4] stains. The application of this differential leukocyte-count to surgical diagnosis will be referred to on page 725.

[1] "Annals of Surgery," April, 1906. [2] Cabot: "Clinical Examination of Blood."
[3] Cabot: "Clinical Examination of Blood." [4] Sahli: "Diagnostic Methods."

OPSONINS AND THE OPSONIC INDEX.

The school of Metchnikoff believes that the leukocyte is the only element of the blood actively concerned in the phagocytosis of micro-

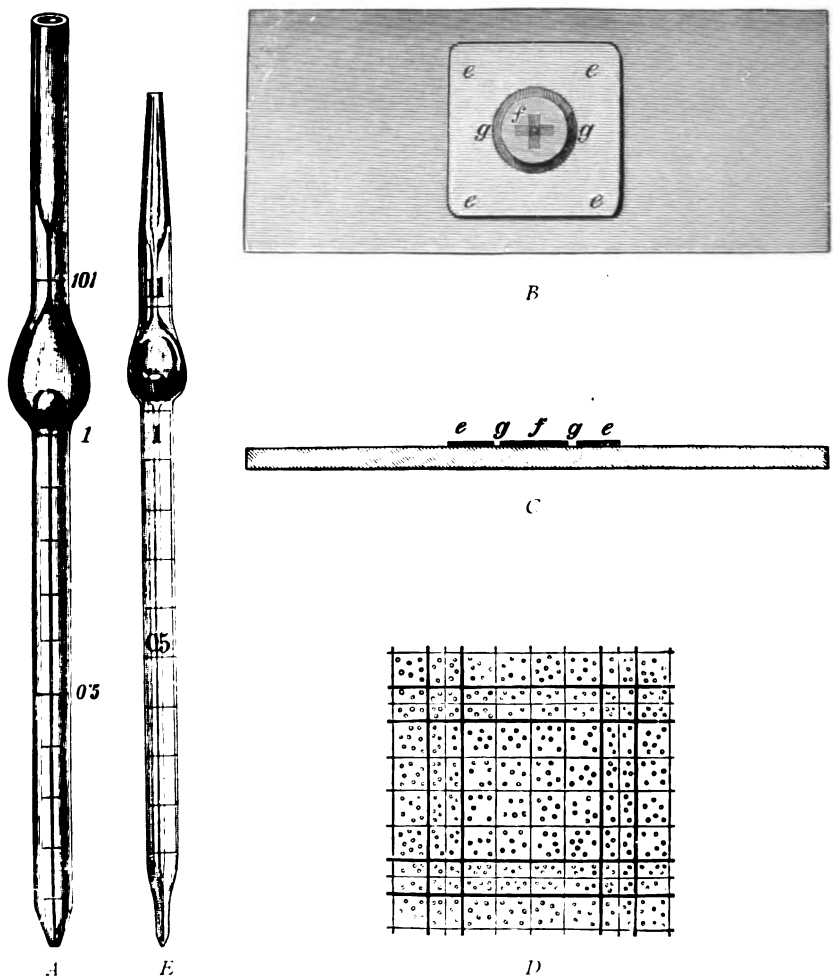

FIG. 477.—THOMA-ZEISS BLOOD-COUNTING APPARATUS.

A, Mélangeur; *B*, counting-chamber, seen from above; *C*, profile of counting-chamber; *D*, microscopic picture of a portion of ruled field with blood-cells; *E*, white counter.

örganisms. It attributes everything to the white blood-corpuscle, and does not consider that the blood-fluid takes any active part in the phenomenon.

In the early part of 1903, Wright and Douglas, of St. Mary's Hospital, London, approached the problem of phagocytosis. They separated

the corpuscular from the fluid elements of the blood. That is to say, they obtained leukocytes suspended in a neutral medium instead of in the blood-plasma, and the blood-plasma (or blood-serum) free from leukocytes or erythrocytes. They prepared also an emulsion of staphylococci in normal salt solution, and found that, if they brought together only the leukocytes and the staphylococci, practically no phagocytosis occurred, but that the addition of blood-plasma (or blood-serum) to the leukocytes and the staphylococci effected some change, so that phagocytosis did occur. The obvious deduction was that the leukocyte by itself was impotent, and further that the blood-plasma contained some substance which was essential to the attainment of phagocytosis.

Using ingenious methods of their own devising, they investigated the blood-plasma in order to determine the characters of this phagocytic element, and the following are the most important of their conclusions:

1. The substance, so essential to phagocytosis, does not act upon the leukocytes (as a stimulant to the leukocytes, for example), but it combines with the microörganisms and prepares them for phagocytosis; hence the name *opsonin*, from *opsono*, I cater for, I prepare victuals for. The conception of their mode of action is that the opsonins are carried in the lymph to the nest of microbes which are responsible for the morbid process; that they chemically unite with the microörganisms, and that then, and not until then, the leukocytes have the power of enveloping and destroying these microörganisms. Thus it follows that the amount of phagocytosis which is observed is a measure of the quantity of opsonins present in any particular plasma, and does not represent the vital activity of the leukocytes.

2. The opsonins in a normal serum are almost completely destroyed by heating for ten minutes at 60° C.

3. The opsonins have been shown to be distinct from the bacteriolysins, the agglutinins, and the antitoxins.

Moreover, as shown by Bulloch and Mestern, the opsonins have a high degree of specificity. For example, the blood of a person may contain half the normal quantity of opsonins necessary to combat a tuberculous infection such as tuberculous cystitis, and yet contain a normal amount of opsonins that have to do with an invasion of staphylococci, such as causes furunculosis.

Wright and Douglas have shown by a striking experiment how invariable a factor the leukocyte really is. They obtained leukocytes both from an immunized patient and also from a normal individual. To a specimen of each of these they added some normal serum, and

also some staphylococci, and allowed phagocytosis to take place. They then found that in the presence of normal serum the leukocytes of the immunized patient took up just as many staphylococci as the normal leukocytes in the presence of the same normal serum. They next took two portions of a suspension of normal leukocytes to which had been added some staphylococci, and mixed with one of these portions some serum from the immunized patient, and with the other some normal serum, and allowed phagocytosis to take place. They then found that the leukocytes, to which had been added the serum from the immunized patient, took up about one-half as many staphylococci as did the leukocytes to which the normal serum had been added. This affords striking testimony that the leukocyte is an indifferent or a constant factor in the phenomenon of phagocytosis. The amount of phagocytosis observed, therefore, represents the quantity of opsonins present in the blood. So far as we can tell at present, the plasma has nothing to do with the "quality" of the leukocytes.

Technic.—If we wish to measure the quantity of opsonins present in the blood of a man suffering from furunculosis, which is almost always due to the staphylococcus pyogenes, we require:

1. A drop or two of blood from the patient, and a drop or two from a normal person, from each of which we can easily obtain sufficient serum for our estimation.

2. An emulsion of staphylococci in salt solution.

3. Leukocytes washed free from their plasma.

We draw up in a capillary pipet equal quantities of the patient's serum, the staphylococcus emulsion, and the leukocytes; thoroughly mix all three, and having sealed the mixture in the capillary tube, place it in an incubator at 37° C.

With a second capillary pipet we again carry out precisely the same operations, except that instead of the patient's serum we use normal serum. This is incubated for the same length of time. An ordinary blood-film is made from each tube at the expiration of the fifteen minutes' incubation. These films are appropriately stained, and then examined microscopically with an oil-immersion lens. Numerous leukocytes are seen, in the protoplasm of which lie few or many staphylococci. The number of staphylococci, taken up by say 40 leukocytes, is counted. Let us say that in the film prepared with the patient's serum we count 80 staphylococci in the 40 leukocytes. The average per leukocyte is then $\frac{80}{40}$ or 2. This figure is known as the "phagocytic index" of the leukocyte. We then count the number of staphylococci taken up by the 40 leukocytes in the film prepared with the normal serum; let

us say we count 160 staphylococci; if we divide $\frac{160}{40}$ we get the "normal phagocytic index" for this particular experiment, namely, 4.

In each of these preparations the leukocytes and the emulsion of staphylococci are constant factors; the only variable factor is the blood-serum.

The amount of phagocytosis depends upon the quantity of opsonins present. It follows, therefore, that the comparison between the two phagocytic indices above recorded, is a comparison between the quantity of opsonins present in the blood-serum of a diseased person and in that of a normal person. The actual ratio in this case is 2 : 4 or 0.5 : 1; the latter figure is the normal "opsonic index," and 0.5 is the *abnormal opsonic index* of a patient who is the subject of a staphylococcus infection, namely, furunculosis.

When we say that a patient has an opsonic index of 0.5 to staphylococcus, we mean that his blood-plasma contains but half the normal quantity of those opsonins which are essential to combating a staphylococcal infection successfully. Moreover, it seems probable that this deficiency was antecedent to the infection or, in other words, it has made the infection possible.

The Opsonic Index: Bacterial Infections.—Certain generalizations have emerged from the investigation of numerous cases.

1. If the bacterial infection be strictly localized, the opsonic index of the blood, as concerns the particular microbe causing the infection, is below normal. For example, the blood of a patient who is suffering from furunculosis will probably show an opsonic index of about 0.6 to the infecting microörganisms, that is, to the staphylococcus pyogenes; or, again, the blood of a patient who is suffering from tuberculous glands in the neck will probably show an opsonic index of about 0.7 to the tubercle bacillus. In each case, the patient's blood is compared with the blood of a normal man.

2. The second generalization has to do with those infections which are not strictly localized. In such cases the opsonic index will be found high at one time and low at another; that is, the opsonic index in systemic infections tends to fluctuate from high to low. This characteristic is well shown in cases of acute pulmonary tuberculosis.

These two generalizations are of primary importance both as concerns the diagnosis and the treatment of bacterial infections.

LEUKOPENIA, LEUKOCYTOSIS, AND HYPERLEUKOCYTOSIS.

By the term *leukopenia* is understood a state of the blood in which there is a decrease in the number of white corpuscles. *Leukocytosis* means an increase of white corpuscles. For clinical purposes it is advisable to consider 10,000 as the extreme limit of ordinary normal leukocytosis. The term *hyperleukocytosis* is used by some to indicate any counts in excess of 10,000. By the majority of surgeons, the term leukocytosis is used to indicate any increase of white corpuscles above the normal. Leukocytoses are either physiologic or pathologic. In the latter the polynuclear neutrophile cells predominate.

Leukocytosis in inflammation is regarded as an index of reaction, rather than of the absolute severity of an infection. As Sondern says, "Good resistance on the part of the body will produce pronounced leukocytosis, even in slight infections. Poor resistance produces little leukocytosis in slight and none at all in severe infections."

Physiologic Leukocytosis.

A normal increase may occur under the following conditions:

1. During digestion.
2. After exertion or a cold bath.
3. During pregnancy, parturition, and the puerperium.
4. In new-born children (up to 30,000).

The leukocytosis of digestion begins about one hour after a meal, and reaches its maximum (a 30 to 40 per cent. increase) in about three to four hours (Rieder). Considering the comparatively slight digestion leukocytosis, any great degree of pathologic leukocytosis can be recognized, even during digestion.

Leukocytosis occurs after the administration of ether and after operations as a transitory condition.

Pathologic Leukocytosis.

In the Infectious Diseases.—*Pneumonia.*—A leukocytosis reaching as high as 50,000 to 60,000 is quite common in this disease. The leukocytosis is composed of polynuclear neutrophiles. A normal leukocyte-count with a relative increase of the polynuclear neutrophiles, indicates a severe infection and reduced resistance.

Typhoid Fever.—In this condition a normal leukocytosis or even a leukopenia is the rule. This is of great aid in distinguishing typhoid from pyogenic infections.

Complications which cause a rapid increase in the number of white

corpuscles are perforation, suppuration, cystitis, parotitis, pulmonary complications, nephritis, thrombosis, and cholecystitis.

Acute Articular Rheumatism.—In uncomplicated cases of this disease there is usually a slight polynuclear neutrophilic leukocytosis (about 15,000), which persists as long as there is fever and exudation.

Meningitis.—In suppurative meningitis there is always a marked leukocytosis, while in tuberculous meningitis the leukocyte-count may be normal or up to 20,000. Absence of leukocytosis points to tuberculosis, but its presence does not exclude it.

Scarlet Fever.—In this condition the blood shows a leukocytosis with high eosinophiles, which serves to distinguish this eruptive fever from septic rashes, etc., in which the polynuclear neutrophiles predominate and the eosinophiles are relatively low.

Erysipelas has a very high leukocytosis of the typical septic variety, namely, a great increase in the neutrophiles.

Septicemia is characterized by a rapid development of severe anemia. There is usually a marked leukocytosis, except in some very mild cases, and in severe, rapidly fatal cases. Blood-cultures may contain the causal organism.

Local abscess formation usually shows a leukocytosis.

Illustrations of such a localized pus formation are a felon, gum boil, external cutaneous abscess, genital abscess, parotic abscess, subphrenic abscess, infections in the neck, etc.

Special Varieties of Abscess Formation.—*Appendicitis.*—In this condition the leukocyte-count affords valuable aid for us both as to the diagnosis of the condition, as well as to the stage of the pathologic process. The count should be made at regular intervals, say every hour or two, in all cases, and compared with the symptoms and general condition of the patient.

The following are general conclusions from actual cases, according to Cabot:

1. There are no changes in the red cells, except the anemia of chronic cases.

2. Coagulation slow, but the fibrin is always increased in pus cases.

3. As in all infections, the very mild and very septic cases show no leukocytosis.

4. Catarrhal appendicitis is rarely accompanied by leukocytosis. An increase from 12,000 to 14,000 is a rare exception.

5. An increasing leukocytosis is an evidence of a spreading process. It should be closely watched and never disregarded. This is of far more significance than the actual number of cells.

6. A low count, 8,000 to 11,000, means one of several things:

(*a*) A mild case.

(*b*) A very severe case in which the resistance of the organism is diminished.

(*c*) An abscess thoroughly walled off.

After the abscess has become walled off the count usually remains stationary or slightly decreases. If the count rapidly increases after such a condition, it means that the abscess has ruptured into the peritoneal cavity. Such a rupture may not, however, be accompanied by an increase, but sometimes by a rapid fall of the leukocyte-count.

7. In the majority of cases the abscess is not completely walled off, and a moderately fluctuating leukocytosis is found.

When the leukocytosis increases slowly and steadily, the case is increasing in severity, as a rule.

When a leukocytosis of 18,000 to 25,000 is maintained, it means a localized large abscess.

8. Size of leukocytosis:

(*a*) Catarrhal, usually below 12,000.

(*b*) Acute diffuse appendicitis without pus, 11,000 to 22,000.

(*c*) Gangrenous appendicitis, usually 20,000 or more.

(*d*) When pus distends the appendix the count is high, 20,000 or over.

When an acute perforation occurs into the free peritoneal cavity, the leukocytosis may fall temporarily; if a reaction on the part of the body takes place, a rapid increase follows; if no reaction takes place, there is no increase.

Differential Diagnosis.—The leukocytosis of appendicitis will differentiate the following conditions:

(*a*) Intestinal colic and the crises of locomotor ataxia.

(*b*) Impaction of feces.

(*c*) Gallstone colic and renal colic, if no infection is present.

(*d*) Ovarian and pelvic neuralgic pains.

(*e*) Floating kidney.

(*f*) Extrauterine pregnancy—this does cause a leukocytosis at times, however.

Acute and Chronic Salpingitis and Pelvic Peritonitis.—These cause the same changes as found in appendicitis, and the blood-count is of value only in distinguishing them from non-septic conditions.

Infection of the Gallbladder and Bile-passages.—Exactly the same may be said of these as of pelvic infection and appendicitis. The blood is only of value to establish the fact of infection and pus formation, but is of little value in differentiating it from other abscesses.

Osteomyelitis has a high leukocytosis which is extremely valuable in differentiating it at an early stage from rheumatism or the prodromes of infective disease, especially smallpox.

Infections of the Serous Membranes.—*Pleural, Pericardial, and Peritoneal.*—This is almost always accompanied by a leukocytosis. The degree of leukocyte increase is extremely variable, and varies from normal to 40,000, and even higher. It is not always possible to differentiate the serous and dry inflammations from the suppurative, as the latter may not have a higher leukocytosis than other varieties.

The leukocyte count is, however, valuable in the following conditions:

(*a*) To differentiate peritonitis from (1) obstruction (non-malignant), (2) malignant disease, (3) hysteria, malingering, etc. A leukocytosis speaks in favor of an inflammatory process.

(*b*) From tuberculous infection, which has no leukocytosis.

Gastro-intestinal Tract.—*Gastric ulcer* causes an increasing anemia with a moderate leukocytosis. Of diagnostic value excepting in complications.

(*a*) Perforation, a rapid rise in the leukocyte-count is usual.

(*b*) Hemorrhage, often an increase of leukocytosis. In chronic hemorrhagic cases the picture may simulate a pernicious anemia.

Duodenal Ulcer.—Same as in ulcer of stomach proper.

Acute Gastro-intestinal Affections.—A fairly well marked leukocytosis is the rule.

Chronic Digestive Disturbances.—As a rule, no leukocytosis and no digestion leukocytosis.

Intestinal Obstruction.—According to Bloodgood, the leukocyte-count here is valuable. Within a few hours the leukocytes rise rapidly. If obstruction is partial, the counts are between 14,000 and 16,000; if complete, usually 20,000 or more. The higher the count and the shorter the duration, the greater the probability of gangrene. If the count shows 20,000 within the first twenty-four hours, the chances are that gangrene is present. On the second day the count does not change much. Then if gangrene or peritonitis occurs the count begins to fall; otherwise the count remains high until the fourth or fifth day, when the leukocytes gradually fall, whatever the condition of the abdomen. If after three days of obstruction the count is still over 20,000 the prognosis is good. If the count is below 15,000 the probability is that gangrene, peritonitis, or fatal auto-intoxication has occurred.

Surgical Conditions of the Liver.—The coagulation time of the blood is reduced in all conditions affecting the function of the liver.

This is especially true if jaundice is present, when the hemorrhage from an operative procedure may be uncontrollable. Usually the capillary vessels are the worst ones.

Gallstones, when no infection is present, cause little or no change. A slight leukocytosis is sometimes found. During a colic this may be slightly increased, but, as a rule, not to be compared with the leukocytosis of infectious processes. All infectious processes of the liver and bile-passages cause a marked leukocytosis; for example, cholangitis, cholecystitis, abscess, thrombosis, and infections of the blood-vessels. This is valuable in differentiating them from typhoid, grippe, etc., which may simulate these conditions.

Diseases of the Pancreas.—Acute pancreatitis and hemorrhagic pancreatitis show a fair increase in the leukocyte-count, which will help to distinguish them from the ordinary pains of indigestion, etc. Chronic pancreatitis shows no such change, a low percentage of hemoglobin being the only help in a diagnostic way that may be present.

Urinary System.—Infections cause a leukocytosis. This is the only distinguishing feature, and aids in determining, for instance, when pus is present in calculous obstruction, and helps fix indications for an operation.

The same holds true in all kidney and bladder affections. The determination of the functional capacity of the kidneys by means of the freezing-point of the blood will be described elsewhere (see page 747).

Nervous System.—The blood examination is of little value in diagnosing diseases of the nervous system directly, as few characteristic conditions are produced.

Injuries, infections, and all suppurations increase the number of leukocytes, so that they help to establish the presence of an obscure abscess, for instance, or differentiate it from a tumor. The leukocyte-count is of value in detecting malignancy and hysteria in many cases.

Malignant Disease.—Blood examinations in malignant tumors sometimes afford substantial aid in locating and determining the rapidity of growth and the degree of malignancy, the presence of ulceration and secondary infection, as well as of repeated internal hemorrhages, when carefully considered together with the symptoms.

The blood as a whole shows the picture of a secondary anemia, that is, the reduction in the hemoglobin, and the blood-cells are in about the same proportion.

Occasionally the blood-destroying power or malignancy of the tumor is so great that the picture of a pernicious anemia is produced.

In most cases the coagulation time is normal or increased. When sloughing is present, it becomes more rapid. When an inflammatory reaction occurs around the tumor, the fibrin may be greatly increased. The red cells are usually smaller in size, pale, and are easily destroyed.

The hemoglobin in cancer cases will average 50 per cent. or lower.

The color index is almost invariably below 1.

The leukocyte changes in cancer are important and depend on the following conditions:

I. On the position of the growth.

(*a*) When the tumor is situated in the esophagus or cardia, the leukocytes may be diminished. It is in this situation that the pernicious type of anemia is frequent. When the leukocytes are increased, it is fair to assume the presence of these growths in other locations, or that extensive sloughing is taking place.

(*b*) Cancer of the uterus and of the stomach, especially if hemorrhages are taking place, show a high leukocyte-count.

(*c*) Malignant tumors of the kidney, thyroid, and pancreas almost always cause a high leukocytosis.

II. Size. Everything else being equal, tumors of the parenchymatous organs and viscera cause greater leukocytosis than the slower growing epitheliomatous and scirrhus varieties. For example, cancers of the skin, lip, scirrhus of the breast, etc., cause a low leukocyte-count, while tumors of the liver and kidney produce very large ones, as these tumors, as a rule, grow to be of large size.

III. Cancer of the bones and blood-forming organs may give a blood-picture depending on the blood-function of these organs. For instance, large numbers of myelocytes, eosinophiles, and intermediate cells may be present, in some respects simulating leukemia, so offering valuable aid in locating metastasis in bones, etc.

Sarcoma.—The blood in this condition is of about the same importance as in carcinoma, with the exception that the changes, as a rule, are greater.

THE VALUE OF THE DIFFERENTIAL LEUKOCYTE-COUNT.

The paper of Gibson[1] previously referred to (page 715) is a valuable contribution to the value of this diagnostic method. He believes that the real value of the polynuclear count lies in "*the relative disproportion of the polynuclear percentage to the total leukocytosis.*" He believes that "with a moderate rise of the total leukocytosis there should be, in

[1] "Annals of Surgery," April, 1906.

favorable cases, a moderate rise of the polynuclear cells only, showing that the infection is localized and absorption is limited. On the other hand, if there is only a moderate leukocytosis with a notable increase in the polynuclear cells, it indicates almost unquestionably that there is either a severer form of lesion or less resistance to absorption, or that both conditions exist." His conclusions will be quoted in full.[1]

The differential leukocyte-count is of value chiefly in indicating fairly consistently (1) the existence of suppuration or gangrene, as evidenced by an increase of the polynuclear cells disproportionately high as compared to the total leukocytosis.

(2) The greater the disproportion, the surer are the findings, and in extreme disproportions the method has proved itself practically infallible.

(3) As the relative disproportion between the leukocytosis and the percentage of polynuclear cells is of so much more value than the findings based on a leukocyte-count alone, this latter method should be abandoned in favor of the newer and more reliable procedure.

(4) The negative findings, showing no relative increase or even an actual decrease of the proportion of the polynuclear cells, while of less value, shows with rare exceptions the absence of the severer forms of inflammation.

(5) In its practical applications, the method is of more frequent value in the interpretation of the severity of the lesions of appendicitis and their sequela.

Value of the Ordinary Leukocyte-count in Differential Diagnosis.—I. When we are dealing with an obscure, deep-seated disease when hemorrhage can be excluded, the presence of a persistent leukocytosis suggests suppuration or malignant disease, rather than tuberculosis or syphilis, for example, and excludes any simple functional or hysterical affection. The absence of leukocytosis, however, does not exclude malignant disease, though it makes suppuration very unlikely.

II. Between malignant disease and suppuration, if the other signs and symptoms do not decide, there may be nothing in the blood to decide. In decided pyemia we may get pyogenic cocci in the blood by culture, but a negative result would not exclude a suppurating focus. The reaction of iodophilia may help to decide the presence of pus, also the increase of fibrin in the blood speaks for the presence of pus.

III. Between malignant disease and hemorrhage, a marked anemia favors hemorrhage, as the anemia of cancer is slow to develop. The leukocytes give no special aid.

[1] For further details, the reader is referred to the original article.

IV. Between cancer and ulcer of the stomach, if there has been no recent hemorrhage, leukocytosis favors cancer, but its absence is of no weight either way. In cancer the hemoglobin steadily decreases, while in ulcer it fluctuates—increasing between hemorrhages, and dropping immediately after one.

The presence of a digestion leukocytosis speaks for ulcer, but if any degree of catarrh and glandular degeneration is present it would also be absent in ulcer.

V. Between cancer of the liver and bile-ducts, on the one hand, and simple gallstone colic or obstruction, on the other, the presence of a leukocytosis favors cancer, and we must bear in mind that gallstones with cholangitis may raise the leukocyte-count as much or more than in cancer. Simple cysts or echinococcus cysts cause no leukocytosis, nor does syphilis of the liver.

VI. The appearance in the blood of large numbers of eosinophiles, myelocytes, and nucleated rods will arouse the suspicion of metastasis in the bones.

VII. If the leukocytosis disappears with the removal of the growth and then reappears, we may look for recurrence of the growth.

VIII. A steadily increasing leukocytosis in a case of malignant disease points to a rapidly growing tumor or the occurrence of metastasis.

IX. Between malignant disease and pernicious anemia, the diagnosis will rest on the following points:

	Malignant Disease.	Pernicious Anemia.
Color index and volume index	Low—less than 1.	Usually above 1.
Leukocytosis	Usually increased.	Diminished.
Lymphocytes	Relatively decreased.	Increase in active number.
Average size of red cell	Usually below normal, 7.5.	Often increased, and great variation in size.
Nucleated red cells	If present, the normoblast type predominates.	Normoblasts the minority—megaloblasts frequent.

X. Between a malignant and a benign tumor, the presence of a leukocytosis will speak against its being benign.

XI. When we suspect a tumor and no actual increase in the whole count is present, the increase of the polymorphonuclear variety will have the same significance as a leukocytosis.

Tuberculosis in a general way may be stated to cause a gradual loss of hemoglobin and red cells, producing the typical secondary anemia.

The leukocytes are usually not increased when secondary infection is absent, and this is valuable in diagnoses.

There are many exceptions to this rule, however, such as:

Meningeal tuberculosis—leukocytosis 7,000 to 30,000.

Bone tuberculosis—often a slight increase.

Genital tuberculosis—a leukocytosis is rather the rule.

Syphilis.—The blood-findings offer little information to the surgeon for diagnostic purposes—except possibly the fact that the increasing lymphocytosis would indicate a late stage and its non-contagious stage.

PERNICIOUS ANEMIA.

(*a*) Red blood-cells 1,200,000 per cu. mm.

(*b*) White blood-cells much below 7,500 per cu. mm.

(*c*) Hemoglobin variable—relatively increased, very often color index high.

(*d*) Deformity in shape and size of red blood-corpuscles frequent.

(*e*) Red cells stain irregularly (polychromatophilia).

(*f*) Megaloblasts more numerous than normoblasts.

(*g*) Lymphocytosis.

Must be distinguished surgically from:

1. Pernicious type of anemia of malignant tumors. In some cases absolutely impossible from the blood alone, but usually a microphitic increase is present with a low color index.

2. From anemia produced by tuberculosis and very chronic suppuration.

3. Acute suppuration will show a leukocytosis, low hemoglobin amounts, low color index.

4. Chronic hemorrhage—as from piles, stomach ulcers, etc. Not always possible, but picture of blood will approach more nearly that of a secondary anemia.

LEUKEMIA.

Characteristics of blood:

1. Myeloid leukemia.
   (*a*) Red cells about 3,000,000—nucleated cells very numerous.
   (*b*) White cells about 450,000, of which
   (*c*) Myelocytes form about 30 per cent.
   (*d*) Every possible form of white cell intermediate between the ordinary varieties is to be seen. (Polymorphous blood.)

2. Chronic lymphatic leukemia.
   (*a*) Red cells about 3,000,000 or lower, nucleated cells rare.
   (*b*) White cells about 300,000, of which
   (*c*) Small lymphocytes form over 90 per cent.
   (*d*) Myelocytes and eosinophiles are rare.
3. Acute lymphatic leukemia.
   (*a*) Red cells much diminished, nucleated cells rare.
   (*b*) Large forms of lymphocytes predominate, often degenerated.
   (*c*) Neutrophiles and eosinophiles very scanty.

The above blood-picture will serve to distinguish leukemia from other diseases causing splenic and glandular enlargement, as well as from tumors simulating such enlargements:

1. Hodgkin's disease.
2. Tumors of spleen and vicinity (kidney and retroperitoneal lymph-nodes).
3. Enlargement of lymph-nodes from tuberculosis, syphilis, malignant disease.
4. Hydronephrosis.
5. Large leukocytosis from any cause.
6. Chronic malaria.
7. Amyloid disease.

THE ESTIMATION OF BLOOD-PRESSURE IN SURGICAL CASES.

Blood-pressure.—The determination of blood-pressure has assumed such practical importance that every surgeon should be familiar with the use of the appropriate instruments.

Of the latter there are a number of different kinds. The one which is most easily employed at the bedside or operating table is the Riva-Rocci sphygmomanometer, as modified by Cook and Briggs (see Fig. 16). For details as to its use, the reader is referred to special treatises on the subject of blood-pressure. Experimental and clinical observations by Crile, Cushing, Cook, Janeway,[1] and others have shown that the estimation of blood-pressure is of great value from both a diagnostic and therapeutic standpoint in the following surgical conditions:

During Surgical Operations.—To be of value a determination should be made every five minutes, the pulse-rate being recorded on a chart. Ether, even in large amounts, seldom produces a significant

[1] Janeway: "Clinical Study of Blood-pressure." Cook: "Jour. Amer. Med. Assoc.," p. 1199, 1903.

fall in blood-pressure. Chloroform is usually accompanied by a marked fall in blood-pressure in 69 per cent., and a moderate fall in 18.9 per cent. of the cases, according to Blauel.

An initial rise in blood-pressure follows any cutting operation, while the irritation of large nerve-trunks causes a much greater reflex rise of blood-pressure.

The opening of the peritoneal cavity is at first followed by a sharp rise, but there is a subsequent fall in blood-pressure dependent on the duration of the operation and the amount of exposure and manipulation of the viscera.

Blood-pressure in Surgical Accidents and Diseases. Hemorrhage.—The loss of any considerable volume of blood, either during an operation or as the result of an accident, causes an immediate fall in blood-pressure. It is very difficult to draw any deductions after an accident as to whether the low amount of blood-pressure is the result of hemorrhage or shock. This uncertainty is due to the fact that the acute anemia causes a considerable degree of shock. One distinction is, however, present, viz., that if the bleeding is checked or ceases spontaneously, and is not succeeded by shock, the blood-pressure will gradually rise. This latter condition is due to the fact that there is a definite physiologic tendency for the blood-pressure to return to its level.

Collapse and Shock.—The term *shock*, according to Crile,[1] should be limited to the condition (page 526) in which there is a gradual fall in blood-pressure. The term *collapse* should be confined to those cases in which the essential phenomenon is a sudden fall of blood-pressure, due to hemorrhages, injuries of the vasomotor center, or cardiac failure. The lowering of the blood-pressure in shock is due to repeated afferent impulses acting on the vasomotor center and causing exhaustion of the latter.

In operations involving handling or long exposure of abdominal viscera, after subcutaneous injuries of the thoracic or abdominal viscera, or in peripheral injuries such as follow a crushing force, there is a steady fall in blood-pressure as a symptom of shock.

Head Injuries.—The marked rise in blood-pressure, as an expression of increased intracranial tension in head injuries or diseases, has been referred to (page 38).

The estimation of the blood-pressure is of considerable value in connection with all other general and focal symptoms.

A low blood-pressure, according to Kocher[2] and Cushing,[3] may be

[1] "Boston Medical and Surgical Jour.," March 5, 1903.

[2] Nothnagel's "Spec. Path. u. Therap.," vol. ix.

[3] "Amer. Jour. of the Med. Sciences," 1902 and 1903.

present in concussion and in the paralytic stage of compression. A marked rise in blood-pressure follows any lesion, whether traumatic or non-traumatic, which produces an increase of the intracranial pressure and resultant anemia of the medulla (page 38).

The writer makes it a practice to have systematic blood-pressure measurements made at regular intervals (every half hour) in cases of head injuries.

A high blood-pressure is present in (*a*) acute compression of the brain from splinters of a depressed fracture, or from an extradural or subdural clot; (*b*) in fractures of the base of the skull; (*c*) in cerebral apoplexy.

A high and rising blood-pressure indicates progressive failure of circulation in the medulla and an increasing hemorrhage.

Hemorrhage into the anterior fossa of the skull has the least, while that into the posterior fossa has the most, effect on general blood-pressure. Uremic coma is accompanied by increased blood-pressure, so that this symptom cannot be utilized to differentiate uremic from apoplectic coma.

Acute Peritonitis.—The arterial tension rises in the early stages of acute peritonitis, and this sharp rise in blood-pressure may be of great value in making a diagnosis of typhoid perforation and other forms of incipient peritonitis.

CYTODIAGNOSIS.

This method of examination is of increasing interest to surgeons. It consists in the study of the character and number of the cellular constituents of exudates and transudates. For the technic of this method the many special text-books should be referred to.[1]

The conclusions obtained should never be employed as the sole means of making a diagnosis. It is and must always remain a single symptom. Cytodiagnosis is, however, of aid in the following fluids:

Cerebrospinal Fluid.—In epidemic cerebrospinal meningitis the fluid is at first clear, and gradually becomes more turbid. Polynuclear neutrophiles predominate in all stages, but in some the lymphocytes are in the majority.

In tuberculous meningitis, either mononuclears or polynuclears predominate, usually the former. All forms of purulent meningitis of traumatic or metastatic origin show microörganisms and typical pus cells.

[1] Sahli: "Diagnostic Methods."

In tetanus and in cerebral tumors there are no cells in the cerebrospinal fluid.

These findings enable one to make a differential diagnosis of acute spinal meningitis from tetanus, or from the cerebral symptoms of a tumor, or from the acute infectious diseases.

Pleural Fluids.—1. A predominance of lymphocytes means a tuberculous effusion.

2. A predominance of polynuclear neutrophiles means an effusion of an acute infectious origin.

3. A large number of endothelial cells, occurring especially in sheets or plaques, means a mechanical effusion or transudate.

4. In neoplasms of the pleura. Free tumor cells are often found in bunches. The cells are difficult to distinguish from leukocytes and endothelium, because both of the latter are also present in the exudate of a neoplasm. Karyokinesis speaks for a neoplasm.

There have been too few observations of joint, peritoneal, or pericardial fluids to draw any conclusions.

EXAMINATION OF THE SPUTUM, STOMACH CONTENTS, URINE, AND FECES.

The importance of a thorough examination of these secretions and excretions cannot be too strongly emphasized. They are of the greatest value from a diagnostic standpoint.

The results have been discussed in connection with the various injuries and surgical diseases in the preceding chapters. It is beyond the scope of a book of this character to describe the technical procedures. For the latter the reader is referred to the many standard treatises devoted to this purpose (Sahli, Boston, Simon, von Jaksch, etc.).

THE NEWER METHODS OF DIAGNOSIS OF RENAL LESIONS.

Ureteral Catheterization and Examination with Sounds, Etc.[1]

The urine from each kidney can be collected separately by means of elastic catheters inserted into the ureters. The tip of the catheter should only extend beyond the vesical end of the ureter. If the catheter has not been passed into the pelvis of the kidney, urine is ejected from the distal (*i. e.*, external) portion of the catheter at intervals, just as it is normally from the ureteric opening into the bladder. If the tip of the

[1] The sections upon Ureteral Catherization and Cystoscopy were written by Dr. Gustav Kolischer, of Chicago.

catheter extends into the pelvis of the kidney the urine drips out in a continuous stream. At times the insertion of a ureteral catheter is followed by a temporary reflex anuria. The flow of urine through the catheter may also be obstructed by a plug of mucus or pus, arrested in the catheter. This can be overcome by injecting some sterile water into the catheter. If blood appears in the urine which is being collected, the tip of the catheter should be pushed a little higher up, so that it is possible to exclude an injury to the ureteral mucous membrane through the passage of the catheter. In case it should be impossible to catheterize one ureter, or if it be considered undesirable to catheterize the ureter of the presumably healthy side, the so-called balloon catheter is employed. This is a ureteral catheter whose eye is covered by a very thin rubber membrane. After this catheter is inserted into one ureter, the rubber is inflated by means of a syringe, and after the inflation is finished the distal end of the catheter is tied. In this way the catheterized ureter is plugged, and the urine coming down from the opposite kidney is collected in the bladder and can be drained out by an ordinary catheter. Previous to the act of collecting a specimen, the bladder must be carefully irrigated, and then emptied.

If it is necessary to make a differentiation between a complete severing or transverse section of a ureter and a ureteral fistula, which involves only a part of the ureteral wall, ureteral catheterization will solve this problem in the following way: In case of a complete lack of connection between the distal ureteral stump and the proximal end of the ureter, it will be impossible to pass the catheter beyond the region of the fistula, and at the same time the distal opening of the catheter will remain dry. If only a parietal, partial lesion of the ureter is present, quite often the catheter will slip over this place beyond the region of the superficial fistulous opening, and urine will come down through the catheter.

The emptying of a fluctuating tumor occupying the renal region, through the insertion of a ureteral catheter inserted high up, will classify this tumor as a nephritic one. In case it should be desirable to measure the length of that portion of the catheter which is inserted into the ureter a so-called zebra catheter is employed. This is a catheter whose surface is marked in turn by yellow and black spaces, each being one centimeter long. By counting the number of these fields, which disappear into the ureteral opening, the desired measurement is secured. An additional aid in making the diagnosis of concretions deposited in the renal pelvis may be had by the use of the ureteral catheter.

The catheter is introduced until its tip rests in the renal pelvis; then

sterile water is injected through the catheter into the renal pelvis. If this injection is followed by the appearance of blood in the urine, which has been taken from this kidney, this phenomenon points very strongly to the presence of concretions, whose movement as the result of the injected stream of water produced hemorrhage. If a wax-tipped ureteral catheter, after being withdrawn from the renal pelvis and ureter, shows scratches on its wax coating, absolute evidence is furnished of the existence of concretions.

In deciding upon the patulency of a ureter, either solid sounds or catheters, strengthened through the insertion of a metallic mandrin, must be used. All these instruments should be well lubricated with glycerin before using. It must be remembered, however, that the mere fact that a catheter or a sound meets with resistance somewhere in the ureteral canal, does not prove the existence of some permanent obstruction. Very often the catheter is simply caught in a mucous fold, or the mucosa is, by virtue of some inflammation, swollen to such an extent as to impede the smooth progress of the catheter-tip. This is especially true for the vesical part of the ureters. In case the catheter does not progress smoothly and warps, several methods can be employed in order to exclude errors in the above-mentioned sense.

Glycerin or vaselin oil is injected through the catheter in the ureter, and then a thicker catheter is employed, the tip is repeatedly twisted around, so as to extricate it out of an interfering fold of mucosa; in case the ureteral opening should show signs of inflammation, a few drops of adrenalin solution are injected into the vesical end of the ureter, so as to cause the mucosa to contract and thus reduce the swelling.

The diagnosis of a stricture of the ureter can only be made if a thinner catheter or sound passes through the whole length of the ureter, after a previously employed larger instrument has failed to do so, and if the sound, after having passed through the region of apparently reduced lumen, gives the examining hand the distinct impression of being "engaged."

The diagnostic range of ureteral catheterization can be amplified by its combination with radiography (Fig. 478). If a metallic sound (lead wire) or a catheter armed with a metallic stylet is introduced into the ureter and renal pelvis, and an *x*-ray picture is taken while the catheterizing instrument is *in situ*, the shadow of the wire will appear in the *x*-ray picture.

The following information can thus be gleaned: The shadows of the wire mark the course of the ureter. In case the renal pelvis should be enlarged (dilated) the proximal end of the wire adjusts itself to the

shape of the pelvis, outlining its extent by curling up on the inner surface of the pelvis. In case one or more concretions are present in the kidney, their topographic position can be determined; if the shadow of the wire-tip is in direct connection with the shadow of the concretion, the diagnosis of a pelvic stone is made; if the shadow of the concretion appears inside the shadow of the kidney at a distance from the wire-tip, the diagnosis of a concretion inside of the renal parenchyma is made; its exact location can be determined by judging the distance of its shadow from the shadow of the wire-tip.

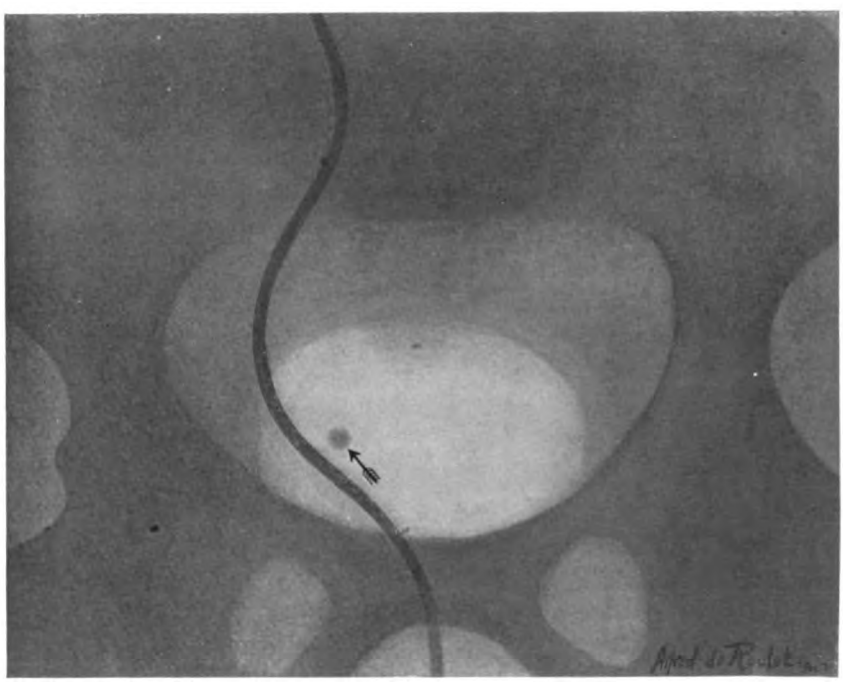

FIG. 478.—RADIOGRAPH OF SUSPECTED RENAL CALCULUS WITH SOUND IN URETER (E. Hurry Fenwick). The arrow points to a shadow which was shown to lie outside of the ureter, the latter being filled with a shadowgraph bougie. The shadow proved to be a patch in an atheromatous artery.

If small round shadows appear in the picture somewhere alongside the course of the ureter, it can be determined whether these shadows are produced by ureteral concretions or not.

Ureteral concretions will necessarily produce shadows that are in intimate relation to the shadow produced by the wire lying in the ureter. Other conditions which produce shadows, not in close relation to the sound, are calcified mesenteric lymph-nodes, phleboliths in the veins of the pelvis, areas of ossification in the ligaments of the pelvis.

If the shadow of the wire leads directly into the shadowy outline of a tumor, the connection of this tumor with the kidney is established.

The collection of urine separately from each kidney renders it possible to determine which kidney or whether both are diseased, (*a*) by the microscopic and chemical analysis of the collected specimens; and (*b*) it furthermore enables the examiner to investigate the functional capacity of either kidney.

CYSTOSCOPY.

Cystoscopy is the ocular inspection of the inner surface of the urinary bladder, accomplished by means of appropriately constructed instruments.

Under special conditions the vesical end of the posterior urethra also becomes accessible to inspection. Modern cystoscopy rests upon the following principles:

(*a*) The viscus is dilated by means of the inflation of air, or through a transparent watery fluid which has been injected into the bladder.

(*b*) Through the insertion of an incandescent electric light into the bladder, and the enlarging of the virtual picture, either by a lens inserted in the instrument used or through the combination of a prism and lens by means of a telescope-like arrangement (Figs. 479 and 480).

The cystoscopes most often used belong either to the group which furnish inverted pictures or they belong to a second group which furnish a direct view, that is, an upright picture. To the first-mentioned class of instruments belongs the so-called retrospective cystoscope, which by a peculiar optic arrangement permits the inspection of the internal orifice of the urethra and of the extreme inner part of the posterior urethra. The addition of conducting canals converts the cystoscopes into instruments which can be used for ureteral catheterization and for operative procedures.

The second group of cystoscopic instruments includes those which furnish a direct view, that is, upright pictures. The addition of conducting canals transforms these instruments also into cystoscopes which can be employed for ureteral catheterization and for endovesical operation.

In order to determine the topographic location of various lesions we resort to conclusions drawn from (*a*) the position of the ocular end of the instrument, and (*b*) from the relation of the lesion under question to certain landmarks on the inner surface of the bladder.

A little knob soldered to the circumference of the ocular part, in the same sagittal plane as the convexity of the beak, indicates the

position of the cystoscopic window, and thus the location of the object in view.

A further more precise determination is furnished by the following intravesical landmarks:

1. The internal orifice of the urethra. It appears under normal conditions as a crescent-shaped fold of dark red color, only slightly glossy, and of velvety surface.

2. The intraureteric ligament. It presents itself as a small band,

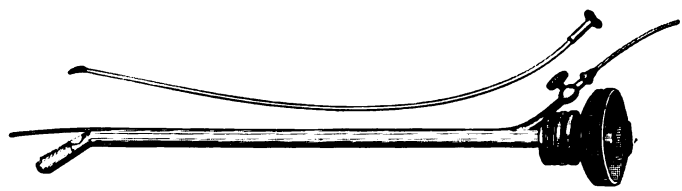

FIG. 479.—BRENNER'S URETER-CYSTOSCOPE.



FIG. 480.—NITZE'S CYSTOSCOPES.

more or less prominent, running in a transverse direction through the field of view covering the trigonum.

3. The ureteral openings, appearing at either end of the above-described band.

4. The air-bubble, naturally always floating on top of the filling fluid, thus indicating the vertex of the bladder. This bubble shows silvery reflexes, is translucent, and in its center the reflex of the incandescent light is to be seen; it oscillates according to the respiratory movements.

The normal color of the mucosa of the bladder is a light yellow

with a pinkish or grayish tinge, and the ramifications of the blood-vessels are distinctly to be seen; the surface of the vesical mucosa is smooth and glossy, and any deviation from one or from several of these conditions points to pathology.

The ureteral openings appear normally as fine slits of a somewhat darker color than the surrounding mucosa, only during the ejaculations of urine are these slits transformed temporarily into holes; a ureteral opening of a dark red color or a permanent gaping of the ureteral mouth is pathologic.

Cystitis.—Acute inflammation of the mucosa characterizes itself by the change of the normal color to a red of different shades, and by the disappearance of the blood-vessels in the affected areas; in the adjacent parts, the blood-vessels appear to be injected and dilated. The intensity of the coloring is in proportion to the intensity of the inflammatory process.

In cystitis that occurs in circumscribed patches, areas of mucosa of normal appearance separate the dark spots; if the cystitis is of a general character, large areas appear dark red, without showing any blood-vessels, or the whole surface of the mucosa is dark red, and of velvety appearance.

In case of intense inflammation shreds of epithelium are attached by one end to the inflamed areas, and submucous hemorrhages are to be seen in the immediately adjacent parts.

Acute gonorrheal cystitis is characterized by the confinement of the process to the trigonum, that appears to be studded with red spots of various sizes; the greatest intensity of coloring is found in the centers of these blotches, the coloring tapering to pink in the periphery of these foci.

Chronic cystitis is characterized by the changing of the red color into a more brownish shade, the surface of the affected parts is without any gloss whatever, and the hemorrhagic spots appear to be black.

The mucosa is quite often swollen and raised into thick clumsy folds, impressing the inexperienced eye at first glance as neoplastic formations. They can be differentiated from polypi in the following ways: Polypi have not such a broad insertion; polypi are, at least at their ends, translucent; and if transillumined show very distinctly their blood-vessels, while folds of the swollen mucosa are absolutely opaque.

The products of cystitis in chronic cases appear either as lumps of a whitish appearance and of a frowsy surface, attached to discolored parts of the mucosa, or they cover, formed into membranes, the dependent parts of the bladder.

In some cases of long standing the chronic inflammation leads to the formation of villous excrescences around the internal urethral orifice and on the adjacent parts of the bladder entrance.

These formations remind one of a glove in miniature. They are not transparent, and give distinctly the impression of jelly-like infiltration.

Cystitic Ulcers.—They appear in the cystoscopic view as fossettæ sunken down into round elevations; their bottom is covered with a grayish coat; the elevations are located in cystic brownish-colored areas; their favorite location is in the trigonum.

Tuberculosis of the Bladder.—A. *Tuberculous Catarrh or Tuberculous Parenchymatous Cystitis.*—A large area of the mucosa appears to be reddened. The blood-vessels in the involved area are not to be seen, the whole surface being smooth and giving the impression of a gelatinous swelling. Numerous ecchymoses are also to be seen. The inflamed area is extremely sensitive to the touch and the capacity of the bladder is always markedly reduced. This picture, of course, indicates only a suspicion of tuberculosis. The final diagnosis can only be made by finding tubercle bacilli in the urine.

B. *Nodular and Ulcerative Tuberculous Cystitis.*—In the trigone one most frequently sees nodules of different sizes, varying from the size of a hempseed to that of a lentil. These nodules are of a grayish or yellowish color, surrounded by a dark red margin.

Some of these nodules are broken down in the center, so that small ulcers result. Their edges are undermined, raised, and ragged. In more advanced cases, two or three of these ulcers may become confluent, thus forming a larger ulcer of irregular outline. The floor of these ulcerations is covered by pale, irregular granulations, which bleed very easily.

If these nodules or ulcers are grouped around a ureteral opening, or if the ureteral mouth shows signs of inflammation, if it is gaping, red, and its lips swollen, or, if the ureteral opening forms the central part of such an ulcer, the diagnosis of descending tuberculosis, originating in the kidney, is almost certain. Here again the final diagnosis rests upon finding tubercle bacilli.

C. *Tuberous Form of Tuberculosis.*—We see one or two solitary tumor-like excrescences of various thickness and height protrude from a red, darkened area of the mucosa: The top of such a prominence always carries an ulcer, with puffy, ragged edges; its bottom is covered by easily bleeding granulations. This form of tuberculosis preferably appears near the internal orifice or in the vertex of the bladder.

Solitary Ulcers.—These ulcers may appear anywhere in the bladder.

They are surrounded by apparently healthy mucosa of normal color, gloss, and vascular ramification. Their contour is quite round, the edges are sharp, and the floor is covered with solid red granulations. The ulcer is below the level into the mucosa, and it appears as though stamped out of the lining with a sharp die. These ulcers are rare, and appear almost exclusively in young individuals.

Edema of the Bladder.—In *general edema of the bladder*, the mucosa appears to be thrown up into thick clumsy folds. The color, if no acute inflammatory conditions of the lining are coexistent, is whitish. The blood-vessels are not to be seen. The surface, especially the crest of the folds, appears as if covered with glistening white scum.

Circumscribed edema shows limited areas of the mucosa teased apart at the surface, so that the affected part of the mucosa appears like a flake of wet, white absorbent cotton (retrostrictural edema).

Inflammatory tumors, in becoming attached to the bladder wall, produce a certain kind of circumscribed edema, which is peculiar to the bladder mucosa. On account of the characteristic appearance and the pathology, it is called bullous edema.

The affected area of the mucosa appears to be covered with any number of translucent globuli, whose sizes vary from that of a lentil to that of a large pea. In different places white flakes, attached by one end to the mucosa, float in the fluid, which has been injected into the bladder.

If these globuli are closely crowded together, the whole affected parts offer the appearance of a cluster of small grapes. The base and the adjacent mucosa appear reddened, quite often wrinkled.

If the inflammatory tumor which has produced the condition pushes the bladder wall into the lumen of the viscus, and if a great many of these globuli have burst on account of the tension, the whole affection may be mistaken for a neoplasm.

Prostatic Hypertrophy.—Changes in the size and formation of the prostate gland become visible inside of the viscus, and can be diagnosed through the cystoscope, if the vesical surface of the gland is the main seat of the affection.

Any change in the normally crescent-shaped, sharp outline of the internal orifice, as it appears in the cystoscopic view, points to abnormalities in the prostate.

It is, however, important to make allowance for an indentation of the urethral canal, if the ocular end of the cystoscope is markedly elevated.

If one lateral lobe is enlarged, one side of the circumference appears to be elevated and protruding into the field of view.

If such a lateral lobe is considerably enlarged, and grows into the bladder, a hilly prominence in the so-called vesical neck is to be seen. If prostatitis is present the mucosa covering this prominence appears edematous. If both lateral lobes are enlarged, the aspect of the internal orifice is changed into a V-shape. If both lateral lobes grow into the viscus, several prominences elevating the mucous membrane of the trigonum are to be seen. If the median lobe is moderately and uniformly enlarged the crescent-shaped outline of the internal orifice of the urethra appears to be flat.

If this uniform enlargement reaches a higher degree, the concave outline of the internal orifice is changed into a convex one.

If the median lobe becomes pedunculated, and if the upper part of it keeps on growing, the cystoscope reveals a pedunculated valve hanging across the internal orifice.

A uniform enlargement of the prostate not only changes the outline of the internal orifice into a straight or even into a convex line, but it also shows the resulting base of the bladder as a deep valley, whose bottom appears dark on account of the shadow. All these findings are more distinctly and markedly seen through the employment of the retrospective cystoscope.

In case arteriosclerosis is the cause of the prostatic trouble, thick, rigid-appearing blood-vessels are to be seen meandering through the mucosa covering the prostate; these blood-vessels spring into prominence like strands buried in the mucosa.

As a rule, we see tiny blood-streams trickling down from these places, which were touched in introducing and manipulating the cystoscope.

Vesical Calculi.—Bladder stones present themselves in the cystoscopic view as well-defined foreign bodies, that distinguish themselves sharply from the bladder wall.

As to any conclusions regarding their size, it must be remembered that only at a certain distance (varying according to the lens system employed) from the window, objects will appear in their natural size, otherwise they become magnified in the cystoscopic observations. Furthermore, if a concretion is so large that it extends beyond the cystoscopic field of view, we only get a constructive picture of the whole stone; but we can always arrive at a pretty accurate conclusion as to the size of the stone if we observe its distance from, or its extension over, the aforementioned landmarks inside of the bladder.

Further information as to whether a stone is freely movable or partially embedded between folds of mucous membrane, or whether it is encysted to any extent in a diverticulum, can be gained by using a ureteral or operative cystoscope through whose conducting canal we introduce a sound or a forceps.

By trying to move the stone or by dislodging it, all points may be cleared up, upon which we desire information. With the aid of the cystoscope, we observe the color of the concretion, the quality of its surface, and its general formation. Phosphates and lime-stones appear as white foreign bodies, which, as a rule, are egg-shaped.

Urates show a yellowish color and a round form. Oxalates are either brown, or of a blackish-brown; occasionally they show a black-greenish tinge. Their general formation, as a rule, is rather irregular, their surface is granular, and in marked forms they appear like mulberries.

The cystoscope decides very readily whether only one or many stones are present. If we discover facets on the surface of one, this is a strong indication to look for other calculi. If cystitis or traumatic ulcerations are present, we discover these readily by ocular inspection. In a differential diagnostic way, large blood coagula or pus coagula deserve to be mentioned. Blood coagula have quite a characteristic yellow, leathery appearance; their surface is absolutely smooth, much more so than that of any stone. Large masses of pus appear to be strongly light-reflecting, almost white, like small snowballs, and their surface shows a very loose structure.

Tumors of the Bladder Wall.—Neoplasms of the bladder appear in the cystoscopic field as protrusions that are attached to the bladder wall at one end, and extend into the lumen of the viscus at the other. This standing out in relief is characteristic of neoplasms. It is very pronounced, if the tumors are pedunculated. If the tumors are attached to the bladder wall by a broad basis it is less pronounced. If a neoplasm infiltrates the bladder wall, this standing out in relief is least pronounced. In the latter case, a preliminary symptom is quite characteristic, viz., when we try to dilate the bladder by injecting water by means of a hand-syringe, we experience an exquisite sensation of rigid resistance. The cystoscopic pictures are very clear and easily recognized and classified if no cystitis is coexistent. The tumor-mass, not showing any blood-vessels, and being of a different color, can be differentiated very readily from the normal mucosa. The impression of something solid is strengthened by the appearance of the shadows that are cast by the tumor over the mucosa.

These shadows change their position according to variations in the

position of the cystoscopic beak. Swollen, thick mucosa folds may occasionally simulate neoplasms. The following points will aid in distinguishing these swollen folds of mucous membrane from tumors. The folds when swollen are always multiple, which is rather rare in tumors. The folds appear as diffuse swellings, while neoplasms appear to be more sharply defined. Swollen mucosa folds show over their entire surface a whitish, glistening scum.

Malignant tumors, as a rule, ulcerate on their surface, and then present on their summit an irregularly shaped ulceration, which almost uniformly bears incrustations. If a neoplasm occurs in a cystitic bladder, or if a neoplasm is ulcerated, a certain method must be employed in order to obtain good views. After the instrument is introduced, it must be kept quiet for a while, so as to give the particles of débris and pus floating in the fluid a chance to settle down to the most dependent parts of the bladder. The so-called villous polypi or papillomata of the bladder give very beautiful and characteristic views. As a rule, they grow from a common pedicle, which divides into several branches. These show a leaf-like appearance, and float around like water-plants in the fluid which has been employed to fill the bladder.

If the light is allowed to pass through these leaves they show quite distinctly long loops of blood-vessels. Some of these tumors show at their edges a fimbriated condition.

All these tumors are of a benign nature, and contact may produce free hemorrhage. Other tumors imitate the shape of a mushroom.

Malignant tumors show, besides the ulceration already referred to, an irregular surface, there being recesses or excavations and hemorrhages in the adjacent mucosa. An extensive phlegmon of the mucosa in its initial stages can hardly be differentiated from an infiltrating cancer in the cystoscopic view. The diagnosis can, however, be made from the accompanying symptoms of each condition.

Encrusted tumors may occasionally be mistaken for calculi and vice versa. The employment of an operative cystoscope and the manipulation of the questionable object by a forceps introduced through it will assist in making a differential diagnosis.

In rare cases a blood coagulum attached with one end to the bladder wall and floating around with its free end may be taken for a polypus. Close observation of its surface, and the lack of any translucency, even at the edges, will finally settle the diagnosis.

Parasites of the Bladder.—Parasites on and in the bladder wall produce a cystitis of the following character. The cystoscope shows reddish patches disseminated all over the inner surface. Adherent to

the centers of these foci of inflammation are whitish or yellowish granular areas. These granules are not as flat as the covering of ordinary ulcers, but protrude into the viscus, and show strong reflecting power. These granules are formed by the mycelia of the parasite, whose character must be determined by microscopic examination.

Syphilis of the Bladder Wall.—Syphilis of the bladder produces various cystoscopic pictures, according to the luetic lesions present. Condylomata lata (mucous patches) appear as yellowish prominences of the well-known form. Syphilitic ulcers do not differ from those of other infections in appearance. Gummata elevate the mucosa, and after breaking down show central ulcerations. The diagnosis can only be made positive through antisyphilitic medication.

Leukoplakia of the Bladder.—This condition manifests itself in the cystoscopic view by the appearance of white patches, located in the trigonum or at the junction of the base of the bladder to the fundus. These patches are somewhat prominent above the surface of the mucosa, are of oval or circular shape, and vary in size from a diameter of 3 to 6 mm. The surface of these patches appears to be of solid, dense structure. If these patches are in a condition of reaction, showing a lighting up of a cystitis, they have a scarlet-red small periphery, and the blood-vessels in the adjacent mucosa appear to be injected.

Patent Urachus.—In this condition we see at the top of the bladder a round hole, surrounded by a rim of protruding, highly vascularized, smooth, shiny mucosa. The center of this opening is dark. A ureteral catheter introduced into this shadowy center proceeds without any obstruction for several inches in an upward direction.

In case inflammation has occurred around the opening of the urachus into the bladder, the ring of mucous membrane encircling the opening appears to be swollen; ribbons of detached epithelial covering project into the lumen of the bladder, and pus flakes are seen to drop from the opening of the urachus into the bladder. In the mucosa adjoining the opening numerous submucous hemorrhagic patches are to be seen.

Abnormal Communication of the Bladder with Some Preformed Cavity or Some Perivesical Area of Injection, etc.—The perforation of a pelvic abscess into the bladder is marked in the cystoscopic picture by a bulging of the affected bladder area into the lumen. If the exudate is still under high tension, this part of the mucosa is covered with edema bullosum. If the tension has considerably relaxed, the mucosa appears to be generally swollen, but, as a rule, a few pearls of circumscribed edema are to be noticed in the otherwise generally edematous mucosa.

The perforation appears as a ragged hole, whose edges are everted. The border is covered with pus flakes and with ribbons of the detached epithelial layer. The adjacent mucosa is dark red, the vascularization is no longer visible. Ecchymoses are numerous, and quite often we see a thin stream of pus running down into the bladder. Pressure on the inflammatory tumor increases the flow of pus into the bladder. The pus accumulates in the trigonum and fundus, and appears there as a white, strongly reflecting mass.

The perforation of a pyosalpinx shows a similar picture, but the bladder wall, as a rule, is involved in the inflammatory changes only to a very limited extent. As a rule, no flow of pus into the bladder is to be noticed. Pressure on the pyosalpinx makes corrugated, sausage-shaped strands of pus appear in the perforation. If the pressure is kept up, these strands accumulate and are arranged in loops at the fundus, thus giving the appearance of a network of white, strongly reflecting strands.

The perforation of a dermoid cyst shows similarly an opening surrounded by the signs of contiguous inflammation. Either bunches of hair, covered with caseous masses, or parts of the bony skeleton can be seen protruding into the bladder.

Vesicorectal fistulæ may become the object of cystoscopic examination if the fistula is a tortuous one, or if the rectal fistulous opening is so small that it can easily be closed temporarily by packing. In either case it becomes possible to dilate the bladder for a sufficient length of time to permit a cystoscopic examination to be made.

The vesical opening of such a fistula always appears like a crater, drawn in toward the bowel, so that concentric longitudinal folds of mucous membrane appear. The border of the fistula appears to be smooth and the mucosa tense over it. The signs of inflammatory reaction around the fistulous opening are very slight. Once in a while fragments of feces may be seen adherent to the edges.

Vesicovaginal fistulæ can be rendered accessible for cystoscopic examination either by clamping together the edges of the communication or by tightly packing the vagina with wet cotton.

The vesical opening of the fistula is always surrounded by an inflamed area of mucosa; the most important feature of this examination is to determine what relation the ureteral openings bear to the fistula.

The communication of the bladder with a loop of intestine, as a result of the perforation of an intestinal carcinoma into the bladder, gives quite a striking picture.

In the fundus, or in the vertex of the bladder anywhere, we see a

dark excavation of varying size. This recess shows a double border. In the inner part the smooth mucosa of the intestine, shiny and pinkish, protrudes into the viscus. In some places we see ulcerated portions of the neoplasm. Irregular craters with a discolored base, their edges ragged, and ribbons of necrosing tissue floating from their periphery, are seen. The outer ring of the edge is formed by the vesical mucosa. It appears to be dark, velvety red, and submucous hemorrhagic patches are to be seen. The adjacent mucosa is characterized by a very dense network of the finest blood-vessels.

Hemorrhoids of the Bladder.—Simple dilated large veins appear in the cystoscopic picture as meandering blue strands of various caliber; they quite often protrude above the level of the mucosa. True "hemorrhoids," that is, well-developed phlebectasias, parietal dilatations, or pockets in the veins, give different cystoscopic pictures, according to their relation to the cystoscopic beak.

If the light strikes them from the front or diffusely, they appear as well-defined blue globules with a smooth surface. If they are transilluminated from behind, they appear as reddish, somewhat transparent globules, that frequently carry a dark center ("phleboliths"). Once in a while a floating-blood coagulum is seen to be attached to the periphery of such a nodule. In order to test the functional capacity of the two kidneys, several methods are in use:

Chromocystoscopy.

Drugs which stain the urine are brought into the circulation after being swallowed or by intramuscular injections. These drugs after a certain length of time (thirty minutes) color the urine. If this coloring is delayed in its appearance, or if the intensity of the coloring is lessened, the kidney is considered to be below par. Methylene-blue can be given by mouth, and for intramuscular injections a 4 per cent. indigo-carmin solution is used. The limitations of this method of chromocystoscopy are obvious. In the first place, we have no sliding scale that would enable us to draw reliable conclusions as to the time the stain appears in the urine or from the intensity of the coloring.

It is a matter of experience that normal kidneys show great variations as to both of these points, and that not infrequently diseased kidneys act very promptly as to these signs. The only diagnostic point that can be gained by this method is, if a stained urine is ejaculated from both ureteral openings, then we are dealing with two functionating kidneys and, considering the rarity of a horseshoe kidney, we can say with strong probability that two functionating kidneys are present.

CRYOSCOPY.

Cryoscopy is the determination of the molecular concentration of the urine and blood by determining their respective freezing-point. The principle of this method is this: The richer a given substance is in regard to molecules, the lower will its freezing-point be below that of distilled water. The best apparatus to use is that of Boeckmann (Fig. 481).

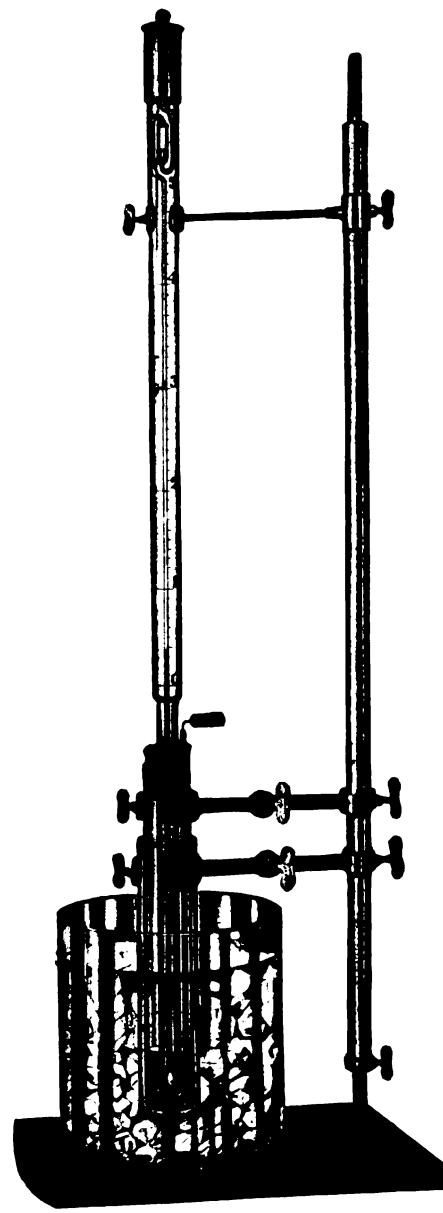

FIG. 481.—APPARATUS FOR CRYOSCOPY (Fowler).

Under normal conditions the urine is more concentrated as to molecules than the blood. If comparison between the freezing-point of the blood and of water show that this normal difference is diminished, then the functional capacity of the kidney, *i. e.*, its eliminative power, is diminished.

In other words, the question to be answered is whether one kidney will be sufficient to attend to the necessary elimination after the other has been removed.

Normally the human blood has a freezing-point of 0.56° C. lower than the freezing-point of distilled water. If this freezing-point of the blood sinks lower than the above-mentioned figure, then, according to those who recommend this method, we must conclude that there is retention, consequently an increase of the molecules in the blood, caused by an insufficient kidney action. *A normal freezing-*

point does not always indicate renal sufficiency. A high freezing-point may be found when the kidneys have a perfect functional capacity.

If the deviation is more than 0.59° C. it is not advisable, as a rule, to extirpate a kidney. The freezing-point of the urine normally is from —1.3° to 2.0° below the freezing-point of water; a deviation beyond this limit proves the kidney to be unreliable, showing that the molecular concentration of the urine is unusually low. We must be sure that no polyuria exists in order that it may be of value. Extensive investigations have proved that this method is only reliable if the results are positive.

Phloridzin Test.

The administration of phloridzin leads, as a rule, to temporary glycosuria. This glycosuria appears fifteen to thirty minutes after the administration of the drug, and disappears usually after three hours. After the urine has begun to run well through the ureteral catheter, twenty minims of a 1 per cent. phloridzin solution (freshly prepared) are given by intramuscular injection.

Delay in the appearance of the sugar, or small quantities of it, is supposed to point to an insufficiency of the kidney. The more renal parenchyma present, the more sugar is excreted, since the phloridzin, by irritating them, causes the withdrawal of sugar from the blood. This method is also reliable only in a positive sense, because researches have proved that sometimes absolutely normal kidneys do not show the sugar reaction. It is of value when combined with ureteral catheterizaion. The employment of this method seems to involve a certain risk, as there are a few cases reported in which the administration of phloridzin was followed by hematuria or unusually prolonged glycosuria.

All of the previously enumerated methods have in common one serious drawback. They do not furnish us any clue as to whether an existing reduction in the functional capacity of a kidney is not a temporary condition due to the toxic substances brought into the circulation from the other, *i. e.*, diseased kidney.

Electric Conductivity of Urine.

An attempt has been recently made to estimate the functional capacity of a kidney by determining the fluctuations in the electric resistance of the urine produced by running indigo-carmin through the kidneys.

The principle is this, that first the electric conductivity of the urine is tested; immediately afterward indigo-carmin is injected into the gluteal muscles, and the electric conductivity is again tested half an hour

after this administration. It is claimed that diseased kidneys show a decidedly decreased electric resistance after this application, and it is furthermore claimed that any decrease beyond twenty ohms classifies such a kidney as a surgically unreliable one.

Healthy kidneys show an increase in electric resistance varying up to ten ohms after the stain appears in the urine. Healthy kidneys, only temporarily reduced in their functional capacity, which reduction is proved by any of the above mentioned methods, show nevertheless their normal possibilities by an increase of electric resistance after administration of indigo-carmin.

INDEX.

ABDOMEN, 231
affections of, acute, 245
pain as early symptom, 256
suppuration as early symptom, 246
condition of, in intussusception, 282
examination of, in enterostenosis, 342
in intestinal strangulation, 280
in volvulus, 280
recti muscles of, suppuration in, 231
tumors of, 285
arising from pelvic viscera of female, 323
auscultation in, 289
due to inflammatory exudates, 320
due to tuberculous peritonitis, 320
having origin in pelvic viscera or bones, 323
history, 285
inflation of stomach or colon in, 289
inspection in, 287
occurring in corresponding locations, 285
palpation in, 288
percussion in, 289
results obtained from abdominal examination and its adjuncts, 286
Abdominal aorta and branches, abdominal tumors due to aneurysms of, 321
differential diagnosis, 322
viscera, injuries of, 237
general condition of patient, 238
history and mode of accident, 237
internal hemorrhage in, 244
local signs, 239
symptoms, 240
wall, affections of, 231
congenital conditions of, 235
desmoids of, 233
differential diagnosis, 234
fibroma of, 233
furuncles of, 231
inflammatory affections of, 231
injuries of, 237
lipoma of, 233
pigmented nevi of, 233
retromuscular suppuration in, 231
suppuration in, 231
tumors of, 233
Abscess, cerebral, otitic, 83
discharging through umbilicus, 236
epidural, 56, 80
extradural, 80
extrasphincteric, 352
formation, leukocytosis in, 721
Abscess in Pott's disease, 688
intrasphincteric, 352
left subphrenic in ulcer of stomach, 334
multiple, of omentum, 255
of brain, 57, 82
acute traumatic, 58
and tumor of brain, differentiation, 80
chronic traumatic, 59
irritation and paralytic symptoms, 83
optic neuritis in, 83
symptoms of, focal, 83
general, 82
of cerebellum, symptoms, 83
of superior rectal space, 352
perisinuous, 80
peritonsillar, 190
prevesical, 232
pulmonary, 213
single, 248
subphrenic, 253
differential diagnosis, 254
temporo-sphenoidal, 83
tropical, 248
differential diagnosis, 248
Acetabulum, fractures of, 497
Achondroplasia, 591
Acid intoxication, hepatic, postoperative, 703
Acromegaly, 592
tumor of pituitary body causing, 79
Actinomycosis, ileocecal, inflammatory tumors of intestine from, 307
of face, 97
of jaws, 120
of lungs, 216
of neck, 161
of pleura, 216
of thoracic wall, 202
Adenocarcinoma of sweat or sebaceous glands of extremities, 557
Adenocystoma, benign, of testicle, 399
Adenoma of sweat and sebaceous glands of extremities, 556
of face, 99
thyroid, 186
Adhesions, perigastric, in ulcer of stomach, 335
Adynamic ileus, 283
differential diagnosis, 283
Air embolism in injuries of veins of neck, 154
in tissues in fracture of base of skull, 27
Air-passages, foreign bodies in, 156, 220
Albuminuria after fracture of base of skull, 34

Alimentary canal, injuries of, free fluid in peritoneal cavity in, 241
obliteration of liver dullness in, 241
symptoms, 240
tympanites in, 241
vomiting in, 240
Anemia, pernicious, examination of blood in, 728
Aneurysm, arteriovenous, of scalp, 69
cirsoid, of extremities, 558
of face, 99
of scalp, 68
false, 431
non-traumatic, of larger vessels of extremities, 559
of abdominal aorta and branches, abdominal tumors due to, 321
differential diagnosis, 322
of extremities, 558
of subclavian artery, 153
thoracic, 207
traumatic, 431
of face, 99
of neck, 152
of scalp, 69
Angina Ludovici, 124
sclerotica abdominis, 276
Angioma of face, 98
of muscles of extremities, 572
of salivary glands, 142
of scalp, 68
cavernous, 68
Angle, carrying, 474
Ankle-joint, diseases of, 644
dislocations at, 516
in lateral direction, 517
in sagittal section, 516
or near, 516
injuries in vicinity of, 513
tuberculosis of, 645
differential diagnosis, 645
Ankylosis of temporo-maxillary joint, 122
Anthrax complicating wounds, 543
edema complicating wounds, 543
Anuria in renal calculus, 370
Anus, atresia of, 346
fissure of, 354
fistula of, 353
pruritus of, 349
Aorta, abdominal, and branches, abdominal tumors due to aneurysms of, 321
differential diagnosis, 322
Aphasia, motor, 47
sensory, 48
visual, 48
Apoplectiform attacks in brain tumors, 76
Apoplexy, late traumatic, 53
Appendicitis, 256
chronic, 341
differential diagnosis, 260
leukocytosis in, 259, 721
in differentiating, 722
pain in, 256
pulse in, 258
temperature in, 259
Appendicitis, tenderness and muscular rigidity in, 257
tumor in, 260
vomiting in, 257
Appendix, vermiform, hernia of, in inguinal hernia, 409
Armor-like cancer, 230
Arteries, injuries of, 429
of extremities, diseases of, 557
of neck, injuries, 152
Arteriovenous aneurysm of scalp, 69
Arteritis of extremities, 557
Artery, carotid, injury of, 152
middle meningeal, hemorrhage from, 48, 50
subclavian, aneurysm of, 153
injury of, 152
vertebral, injury of, 152
Arthritis, 602
acute, of extremities, 579
traumatic, 604
chronic, 611
of temporo-maxillary joint, 122
deformans, 615
differential diagnosis, 617
general progressive form, 616
Heberden's nodes in, 615
in children and young individuals, 617
monarticular form, 616
of spine, 691
polyarticular form, 616
vertebral form, 616
due to syringomyelia, 624
due to tabes, 622
following infectious diseases, 608
gonorrheal, 609. See also *Gonorrheal arthritis.*
gouty, 618
acute, 618
atypical or irregular form, 619
chronic, 618
neurogenica, 622
neuropathic, 621
pneumococcus, 608
primary acute, of temporo-maxillary joint, 122
secondary acute, 606
by extension, 610
of temporo-maxillary joint, 122
to pus foci elsewhere, 607
syphilitic, 619
acquired, 619
chronic, 619
hereditary, 620
secondary, 619
tertiary, 619
tabetica, 622
traumatic, 450
diagnosis shortly after injury, 452
free bodies in joints in, 455
locking of joint in, 455
rupture of ligaments in, 453
subluxation of cartilages in, 453
typhoidal, 608
urica, 618
Arthropathie tabetique, 622

Ascites, 318
Aseptic fever, postoperative, 700
Asphyxia, traumatic, 196
Astragalus, dislocation of, 518
  fractures of, 520
Atresia ani, 346
    et recti, 346
  recti, 346
Atrophy, syphilitic, of tongue, 133
Auditory nerve, injury, in fracture of base of skull, 30
Auscultation in empyema, 210
  in tumors of abdomen, 289

Back, furuncles on, 201
  ulcerations on, in tertiary syphilis, 201
Bacterial infections, effect on opsonic index, 719
Balanitis, 385
Barlow's disease, 591
Bile-duct, common, gallstones in, 337, 340
Bile-passages, infection of, leukocytosis in, 722
Bladder, 371
  abnormal communication of, cystoscopy in, 744
  calculus of, 375
    cystoscopy in, 741
  congenital malformations, 371
  distended, 323
  ectopia of, 371
  edema of, cystoscopy in, 740
  examination of, in renal calculus, 370
  exstrophy of, 371
  hemorrhoids of, cystoscopy in, 746
  hernia of, in inguinal hernia, 407
  inflammation of, 372. See also *Cystitis.*
  injuries of, symptoms, 243
  lesions of, 361
    clinical picture, 361
    examination of urine in, 361
    objective examination in, 362
  leukoplakia of, cystoscopy in, 744
  parasites of, cystoscopy in, 743
  rupture of, in fractures of pelvis, 491
  syphilis of, cystoscopy in, 744
  tuberculosis of, 374
  cystoscopy in, 739
  tuberculous catarrh of, cystoscopy in, 739
  tumors of, 376
    cystoscopy in, 742
  ulcers of, cystoscopy in, 739
  wounds of, 372
Blastomycotic disease of face, 95
  ulcers of extremities, 546
Blood, cryoscopy of, 747
  escape of, from ear, nose, and mouth in fracture of base of skull, 27
  examination of, 715
    in leukemia, 728
    in pernicious anemia, 728
  in pyemia complicating wounds, 540
  in septicemia complicating wounds, 537
Blood-counting apparatus, Thoma-Zeiss, 716
Blood-cysts of neck, 177
Blood-pressure in acute peritonitis, 731
  in collapse, 730
  in hemorrhage, 730
  in injuries of head, 51, 730
  in shock, 730
  in surgical accidents and diseases, 730
    cases, 729
    operations, 730
  increased, in brain tumors, 75
Blood-vessels, injuries of, 429
    in dislocations, 456
    in fractures, 443
      of base of skull, 32
    subcutaneous, 198
Bones, contusions of, 438
  cranial, contusions of, 61
  injuries of, 422
    general considerations upon, 438
  of extremities, benign tumors of, 594
    carcinoma of, 601
    cysts of, 594
    diseases of, 575
      acute, 575, 577
      chronic, 575, 582
    enchondroma of, 596
    endothelioma of, 601
    exostoses of, 595
    injuries of, 438
    myeloma of, 601
    perithelioma of, 594, 601
    sarcoma of, 597. See also *Sarcoma of bones of extremities.*
    syphilis of, 584, 585
      acquired, 586
    tuberculosis of, 582
    tumors of, 593
Bow-legs, 654
Brachial plexus, injuries of, 155, 437
Brain, abscess of, 57, 82. See also *Abscess of brain.*
  areas, localization, 44
  compression of, 36
    first stage, 37
    fourth stage, 39
    from infection of meninges or brain, or tumors of brain, 37
    from intracranial hemorrhage, 36
    from splinters of depressed fracture, 36
    second stage, 37
    stage of advanced compression, 38
      of compensation, 37
      of incipient or mild compression, 37
      of paralysis, 39
    third stage, 38
  concussion of, 35
    stage of depression, 35
      of irritation, 36
  contusion of, 42
  diseases of, 73
  injuries of, 17
    differential diagnosis, 54
    in fracture of skull, 34
    suppuration following, 55
  laceration of, 42
  motor region, tumors of, 76
  tumors of, 75

Brain, tumors of, apoplectiform attacks in, 76
choked disc in, 75
compression from, 37
general convulsions in, 76
headache in, 75
increased blood-pressure in, 75
mental symptoms in, 75
optic neuritis in, 75
slow pulse in, 75
symptoms, focal, 76
general, 75
tenderness of skull in, 76
vertigo in, 76
vomiting in, 75
venous sinuses of, hemorrhage from, 49, 53
white matter of, lesions, 47
Branchial cyst, 174
fistula, 147
Breast, caking of, 222
carcinoma of, 228. See also *Carcinoma of breast.*
diffuse fibroadenoma of, 224
fibroma of, 223
diseases of, 221
fibroadenoma of, 227
hypertrophy of, 227
inflammatory processes of, 221
sarcoma of, 228
tuberculosis of, 225
tumors of, 227
benign, 227
differential diagnosis, 230
malignant, 228
Brenner's ureter-cystoscope, 737
Bronchi, foreign bodies in, 156
Bronchiectasis, 213
Brown-Séquard paralysis, 666
Bulla, formation of, in fractures, 442
Bursa, injuries of, 428
of extremities, diseases of, 566
thyrohyoid, 177
Bursitis, acute, of extremities, 566
chronic, of extremities, 566
syphilitic, of extremities, 567
tuberculous, of extremities, 567

Cachexia in malignant tumors of kidney, 317
Caking of breast, 222
Calculus in bladder, cystoscopy in, 741
renal, 365
anuria in, 370
disturbances in micturition in, 369
examination of bladder in, 370
of ureters in, 370
hematuria in, 368
pain in, 367
radiographic examination in, 369
results of palpation in, 367
urinary changes in, 367
salivary, 125, 140
vesical, 375
Callus formation, delayed, in fractures, 445
Caput obstipum, 150
Carbuncle of neck, 160
Carcinoma, armor-like, 230
en cuirasse, 230
leukocytosis in, 725
of bones of extremities, 601
of breast, 228
age in, 228
complications, 230
condition of nipple and regional lymph-nodes, 229
edema of hand in, 230
location and growth, 229
mobility, consistency, and form, 229
paraplegia dolorosa in, 230
of duodenum, 308
of face, 100
of floor of mouth, 126
of intestine, 308
condition of bowel movements in, 309
differential diagnosis, 309
symptoms of stenosis in, 308
tumor in, 309
of jaws, 115
of larynx, 191
of lips, 108
of liver, 296
of neck, 181
primary, 181
secondary, 181
of parotid gland, 145
of rectum, 359
of scalp, 69
of stomach, 335
hemorrhage in, 335
pain in, 335
tumor in, 336
vomiting in, 335
of tongue, 134
differential diagnosis, 135
Carotid artery, injury of, 152
internal, intracranial portion, injuries, hemorrhage from, 50
body, sarcoma of neck arising from, 180
sheath, sarcoma of neck arising from, 180
space, suppuration in, 159
Carpal bones, dislocations of, 483
fractures of, 483
Carpo-metacarpal dislocations, 484
Carrying angle, 474
Cartilages, costal, fractures of, 194
subluxation of, in traumatic arthritis, 453
Catarrh, tuberculous, of bladder, cystoscopy in, 739
Catheterization, ureteral, 732
in tuberculosis of kidney, 365
Cauda equina, lesions of, 676
Cellulitis, emphysematous, complicating wounds, 534
of finger or hand, complicating wounds, 531
Cephalhematoma, 18
Cephalhydrocele, traumatic, 19
Cephalic tetanus, 541
Cerebellum, abscess of, symptoms, 83
lesions of, 48
tumors of, 77

Cerebral abscess, otitic, 83
localization, 44
sinus, thrombosis of, 84
Cerebrospinal fluid, cytodiagnosis of, 731
escape of, in fracture of base of skull, 28
meningitis, cytodiagnosis in, 731
Cervical rib, 148
Chancre of lip, 105
of tongue, 130
Charcot knee-joints, 620
Cheeks, tumors of inside of, 127
Chest, 193. See also *Thorax.*
Choked disc in brain tumors, 75
Cholecystitis, acute, 246
differential diagnosis, 247
phlegmonous, 247
Chondrodystrophia fœtalis, 591
Chondroma of jaws, 113
of neck, 178
Chondrosarcoma of parotid gland, 144
Chromocystoscopy, 746
Circulatory complications, postoperative, 710
Circumflex nerve, injuries of, 435
Cirsoid aneurysm of extremities, 558
of face, 99
of scalp, 68
Claudication, intermittent, 551
Clavicle, dislocations of, 464
at acromioclavicular joint, 464
of sternal end, 464
fractures of, 462
Claw-hand, 436
Club-foot, 656
Club-hand, 661
Cœliac parotitis, 141, 713
Colic, gallstone, 264. See also *Gallstone colic.*
in enterostenosis, 342
renal, 270
symptoms of, 270
Collapse, blood-pressure in, 730
postoperative, 699
Colles' fracture, 482
Colon, inflation of, in tumors of abdomen, 289
Coma and compression of brain, differentiation, 40
Compression of brain, 36. See also *Brain, Compression of.*
Concussion of brain, 35
stage of depression, 35
of irritation, 36
of spine, 683
Constipation in enterostenosis, 342
in intestinal obstruction, 277
strangulation, 280
in volvulus, 280
Contraction, Dupuytren's, 573
Contracture, ischemic muscular, of extremities, 571
Contused wounds of scalp, 18
in infants and young children, 18
in older children and adults, 20
Contusions, cerebral, 42
of bones, 438
Contusions of cranial bones, 61
of hip, 498
of muscles, 424
of urethra, 380
simple, effect on skin, 423
Convolutions, ascending frontal and parietal, lesions of, 44
general, in brain tumors, 76
Corset liver, 291
differential diagnosis, 292
Costal cartilages, fractures of, 194
Coxa vara, 648
attitude of limb, 650
differential diagnosis, 651
gait and pain, 651
history, 650
limitation of motion, 650
shortening, 650
symptoms, 650
traumatica, 499
x-ray examination, 651
Coxitis, 631
tuberculous, 632. See also *Tuberculosis of hip-joint.*
Cranial bones, contusions of, 61
Craniotabes, 70
Crepitus in fractures, 447
Crisis, Dietl's, 271, 312
differential diagnosis, 271
visceral, 274
Cryoscopy, 747
apparatus for, 747
Curvature, lateral, of spine, 690
Cutaneous tissue, infection of, complicating wounds, 531
Cut-throat, 156
Cyanosis in penetrating injuries of thorax, 200
Cystadenoma of jaws, 110
Cystic disease of liver, 295
duct, gallstones in, 340
goiter, 177
lymphangioma, congenital, of neck, 176
mastitis, chronic, 223
tumors behind rectum, 695
of neck, 174
ulcers, cystoscopy in, 739
Cystitis, 372
acute, 372
general symptoms, 373
painful and increased frequency of urination in, 372
sensation of weight and tenderness in, 373
urine in, 373
chronic, 373
cystoscopy in, 738
differential diagnosis, 374
diphtheritic, 373
nodular and ulcerative tuberculous, cystoscopy in, 739
tuberculous parenchymatous, cystoscopy in, 739
Cystoscopes, Nitze's, 737
Cystoscopic examination in tuberculosis of kidney, 365

Cystoscopy, 736
in abnormal communication of bladder, 744
in calculi in bladder, 741
in cystitic ulcers, 739
in cystitis, 738
in edema of bladder, 740
in hemorrhoids of bladder, 746
in hypertrophy of prostate, 740
in leukoplakia of bladder, 744
in nodular and ulcerative tuberculous cystitis, 739
in parasites of bladder, 743
in patent urachus, 744
in syphilis of bladder wall, 744
in tuberculosis of bladder, 739
in tuberculous catarrh of bladder, 739
parenchymatous cystitis, 739
in tumors of bladder wall, 742
in ulcers of bladder, 739
Cysts, blood, of neck, 177
branchial, 174
dentigerous, of jaws, 108
dermoid, of extremities, 556
of face, 99
of floor of mouth, 126
of neck, 178
of scalp, 67
hydatid, in muscles of extremities, 572
of liver, 294
differential diagnosis, 294
suppurating, 254
of neck, 177
of spleen, 306
lymph, of extremities, 564
of accessory thyroids and parathyroids, 177
of bones of extremities, 594
of mesentery, 310
of pancreas, 301
differential diagnosis, 302
of salivary ducts, 142
glands, 142
retention-, of salivary glands, 141
sebaceous, of extremities, 556
of face, 99
of neck, 178
thyroglossal, 126, 176
unilocular, of neck, 177
Cytodiagnosis, 731
of cerebrospinal fluid, 731
meningitis, 731
of pleural fluids, 732
of tuberculous meningitis, 731

Deafness, word-, 48
Decubital ulcers of extremities, 548
of tongue, 128
Defence musculaire, 240
Deformities caused by anterior poliomyelitis, 654
congenital, of hands, 661
in dislocations, 459
in fractures, 447
in Pott's disease, 687
of extremities, 646
Delirium, traumatic, 528, 529
in fractures, 444
tremens, 528, 529
in fractures, 444
Dental ulcers, 128
Dentigerous cysts of jaws, 108
Dermoid cysts of extremities, 556
of face, 99
of floor of mouth, 126
of neck, 178
of scalp, 67
sequestration, sacrococcygeal, 695
Descent, imperfect, of testicle, 388
complications, 388
hernia and hydrocele in connection with, 391
inflammation in, 389
tumor formation in, 389
Desmoids of abdomen, 233
differential diagnosis, 234
of muscles of extremities, 572
Diabetic complications, postoperative, 712
gangrene of extremities, 551
Diaphragm, penetrating wounds of, 201
subcutaneous injuries of, 197
Diaphragmatic hernia, 421
Dietl's crisis, 271, 312
differential diagnosis, 271
Digestion, disturbances of, leukocytosis in, 723
Digits, supernumerary, 661
Dilatation, idiopathic, of esophagus, 330
of stomach, 331, 332
from acquired stenosis of pylorus, 332
from congenital stenosis of pylorus, 331
postoperative, 706
Diphtheritic cystitis, 373
Dislocations at ankle-joint, 516
in lateral direction, 517
in sagittal section, 516
carpo-metacarpal, 484
change in length of limb in, 461
congenital, of hip, 646
differential diagnosis, 647
of extremities, 646
of knee, 648
of patella, 648
of shoulder, 648
deformity in, 459
diagnosis in general, 458
disturbance of function of limb in, 461
general considerations on, 456
habitual, 456
injury of blood-vessels in, 456
of nerves in, 457
near ankle, 516
objective signs of, 459
of astragalus, 518
of carpal bones, 483
of clavicle, 464
at acromioclavicular joint, 464
of sternal end, 464
of hip, 496
of jaw, 90
of knee, 506
backward, 506

Dislocations of knee, forward, 506
of metacarpal bones, 486
of metatarsal bones, 523
of patella, 505
of phalanges, 486
of radius, 478
and ulna, 477
backward, 478
of shoulder-joint, 470
backward forms, 472
subspinous forms, 472
of shoulder region, 461
of spine, 679
pathology, 664
of tendons, 427
of toes, 524
of ulna and radius, 477
backward, 478
of vertebræ, 679
pathology, 664
of wrist, 484
pathologic, 456
recurrent, 456
special, 461
subacromial, 472
subastragaloid, 518
subclavicular, 472
subcoracoid, objective signs, 471
subglenoid, symptoms of, 472
tibiotarsal, 516
x-ray examination in, 461
Displacement, congenital, of kidney, 311
Distended bladder, 323
Diverticula of esophagus, 177, 329
of pharynx, 177
Drug eruptions, postoperative, 712
Drugs, poisoning from, postoperative, 712
Dullness in flanks and right iliac region in perforating ulcers of stomach and duodenum, 267
liver, obliteration of, in perforating ulcers of stomach and duodenum, 266
Duodenal ulcer, 332. See also *Ulcer of stomach.*
Duodenum, cancer of, 308
ulcer of, 332. See also *Ulcer of stomach.*
perforating, 266. See also *Ulcer, perforating, of duodenum.*
Dupuytren's contraction, 573
Dyspeptic symptoms in ulcer of stomach, 333
Dyspnea in penetrating injuries of thorax, 200

Ear, escape of blood from, in fracture of base of skull, 27
middle, suppuration from, intracranial complications, 80
Echinococcus cysts. See *Hydatid cysts.*
Ectopia testis, 388
vesicæ, 371
Edema, anthrax, complicating wounds, 543
malignant, complicating wounds, 534
of bladder, cystoscopy in, 740
of glottis, 190
of hand in cancer of breast, 230
Edema, pulmonary, in fractures, 444
Elbow, miner's, 567
pulled, 479
sprains of, 473
Elbow-joint, injuries in vicinity of, 478
tuberculosis of, 628
Electric conductivity of urine, 748
Elephantiasis, 554
Eleventh nerve, injury, in fracture of base of skull, 31
Embolic gangrene of extremities, 552
Embolism, air, in injuries of veins of neck, 154
fat, in fractures, 443
in fractures, 442
of mesenteric vessels, 272
differential diagnosis, 273
postoperative, 710
pulmonary, postoperative, 702
Emphysematous cellulitis complicating wounds, 534
Empyema, 208
auscultation in, 210
causes, 208
clinical course, 209
differential diagnosis, 210
exploratory puncture in, 210
history, 209
in penetrating injuries of thorax, 200
inspection in, 209
metapneumonic, 208
of joints, tuberculous, 612
palpation in, 209
percussion in, 209
physical examination in, 209
tuberculous, 208
Enchondroma of bones of extremities, 596
of ribs, 207
Endothelioma of bones of extremities, 601
Enlargement of cervical lymph-nodes, 163. See also *Lymph-nodes of neck, enlargement.*
of kidney, diseases accompanied by, 313
in renal tuberculosis, 365
of lips, 104
of prostate, 377
differential diagnosis, 378
of spleen, 305
Enterocele, acute partial, 404
Enterostenosis, 341
colic in, 342
condition of feces in, 342
constipation in, 342
examination of abdomen in, 342
history in, 342
peristalsis in, 342
tympanites in, 342
Epidermal infection complicating wounds, 531
Epididymis, tumors of, 399
Epididymitis, gonorrheal, 392
Epidural abscess, 56, 80
Epilepsy, traumatic, 62
Epiphyseal separation of femur in children, 500
Epiphysitis of extremities, 580

Epispadias, 379
Epithelioma of extremities, 557
of face, 101
of lips, 107
of penis, 386
Epulis, 112
Eruptions, drug, postoperative, 712
postoperative, 711
Erysipelas complicating wounds, 535
facial, 92
leukocytosis in, 721
of scalp, 66
Erysipeloid complicating wounds, 536
Esophagus, diseases of, 324
diverticulum of, 177, 329
foreign bodies in, 330
methods of examination, 331
idiopathic dilatation of, 330
stricture of, 324. See also *Stricture of esophagus.*
subcutaneous injuries of, 198
Examination, methods of, 715
Exophthalmic goiter, 189
Moebius' symptom of, 189
Stellwag's symptom of, 189
von Graefe's symptom of, 189
Exostoses of bones of extremities, 595
Exploratory puncture in empyema, 210
Exstrophy of bladder, 371
Extradural abscess, 80
Extrasphincteric abscess, 352
Extra-uterine pregnancy, rupture of, 284
Extremities, 422
diseases of, 544
of skin, 554
and subcutaneous tissues, 544
lower, infection in, complicating wounds, 534
tumors of skin and subcutaneous tissue, 555
Exudates, inflammatory, abdominal tumors due to, 320

FACE, actinomycosis of, 97
angioma of, 98
benign tumors of, 98
blastomycotic disease of, 95
bones of, fractures, 87
injuries, 87
carcinoma of, 100
cirsoid aneurysms of, 99
dermoid cysts of, 99
epithelioma of, 101
erysipelas of, 92
fibroma molluscum of, 99
furuncles of, 94
injuries and diseases of, 86
lipoma of, 99
lupus of, 95
malignant tumors of, 100
neoplasms of, 98
sarcoma of, 101
sebaceous cysts of, 99
glands, adenoma of, 99
soft parts, diseases of, 92
infections of, 92
Face, soft parts, injuries of, 86
sweat glands, adenoma of, 99
syphilis of, 96
traumatic aneurysms of, 99
Facial nerve, injury of, 139
in fracture of base of skull, 28
Facies in perforating ulcers of stomach and duodenum, 267
False aneurysm, 431
Fasciæ of extremities, diseases of, 573
Fat embolism in fractures, 443
Feces, condition of, in enterostenosis, 342
examination of, 732
Feet, foreign bodies in, 661
Felon, 532
Femoral hernia, 414
differential diagnosis, 415
Femur, epiphyseal separation, in children, 500
fractures of, 500
of head, 497
of lower end, 503
of neck, 493
in children, 499
of shaft, 501
Ferment fever, postoperative, 700
Fetal rickets, 591
Fever in gallstone colic, 264
in intussusception, 282
Fibroadenoma, diffuse, of breast, 224
of breast, 227
Fibroma, diffuse, of breast, 223
molluscum of face, 99
of abdomen, 233
of jaws, 111
of neck, 179
of salivary glands, 142
of scalp, 68
of thorax, 206
Fibula, fractures of lower end, 514
of upper end, 509
isolated fractures of upper and middle thirds of shaft, 512
Finger, cellulitis of, complicating wounds, 531
Finger-joints, diseases of, 629
Fingers, webbed, 661
Fissure of anus, 354
Fistula, branchial, 147
in ano, 353
salivary, 139
thyroglossal, 147
Flat-foot, 657
Floating kidney, 312
differential diagnosis, 313
liver, 293
differential diagnosis, 293
spleen, 304
Foreign bodies in air passages, 156, 220
in bronchi, 156
in esophagus, 330
methods of examination, 331
in feet, 661
in hands, 661
in rectum, 348
in trachea, 156

Foreign bodies, intestinal obstruction from, 282
Fossa, individual, of base of skull, fracture, 32
middle, of skull, tumors of, 78
Fourth nerve, injury, in fracture of base of skull, 30
Fractures, 438
abnormal mobility of bone in, 447
associated with fragilitas ossium, 441
with general diseases, 441
with idiopathic friability of bone, 441
with local lesions of bone, 441
with osteoporosis, 441
closed, 439
Colles', 482
complete, 438, 439
complicated, 439
complications of, 442
compound, 439
crepitus in, 447
deformity in, 447
delayed callus formation in, 445
union in, 445
delirium tremens in, 444
diagnosis in general, 446
displacement of fragments, 440
embolism in, 442
fat embolism in, 443
faulty union in, 446
fibrous union in, 445
formation of bullæ in, 442
greenstick, of radius and ulna, 480
gunshot, 439
healing of, 442
history in, 446
in sarcoma of bones of extremities, 600
incomplete, 438, 439
injury to blood-vessels in, 443
to nerves in, 443
intercondyloid, of lower end of humerus, 474
isolated, of upper and middle thirds of shaft of fibula, 512
longitudinal, 439
loss of function of limb in, 448
mal-union in, 446
number of fragments, 440
objective signs of, 447
oblique, 439
of acetabulum, 497
of astragalus, 520
of bones of face, 87
of carpal bones, 483
of clavicle, 462
of costal cartilages, 194
of femur, 500
of great trochanter, 498
of head and neck of radius, 477
of femur, 497
of hyoid bone, 155
of inferior maxilla, 89
of larynx, 155
of lower end of fibula, 514
of humerus, 473
Fractures of lower end of humerus, epiphyseal separation, 475
of external epicondyle and external condyle, 476
of internal epicondyle or internal condyle, 476
of radius, 482
of tibia, 514
of lower jaw, 89
of lumbar vertebræ, 678
of malar bone, 88
of metacarpal bones, 486
of metatarsal bones, 522
of nasal bones, 87
of neck of femur, 493, 503
in children, 499
of os calcis, 521
of patella, 505
of pelvis, 488
abnormal mobility in, 489
pain in, 489
rupture of bladder in, 491
of urethra in, 490
of phalanges, 486
of toes, 522
of ribs, 193
signs due to fracture alone, 193
due to injury of intrathoracic viscera, 194
of scapula, 465
of shaft of femur, 501
of humerus, 472
of radius, 479
of tibia, 510
of ulna, 479
of shoulder region, 461
of skull, 22
at later period, 26
depressed, 24
compression of brain from splinters, 36
of vertex, 25
examination of vertex, 23
where no scalp wound is present, 23
where wound of scalp exists, 25
fissured, 25
history of mode of injury, 22
intracranial symptoms, 34
of base, 27
albuminuria after, 34
escape of blood from ear, nose, and mouth, 27
of cerebrospinal fluid, 28
glycosuria after, 34
hemorrhage or presence of air in tissues, 27
injury of auditory nerve, 30
of facial nerve, 28
of hypoglossal nerve, 31
of nerves, 28
of ninth, tenth, and eleventh nerves, 31
of olfactory nerve, 30
of optic nerve, 30

Fractures of skull, of base, injury of third, fourth, and sixth nerves, 30
of trigeminal nerve, 31
of twelfth nerve, 31
of vessels, 32
of individual fossæ, 32
of both tables, 26
of external table, 25
of internal table, 26
punctured, 25
of spine, 676
from third cervical to second dorsal vertebra, 677
to twelfth dorsal vertebræ, 678
of atlas and axis, 676
of upper two cervical vertebræ, 676
pathology, 664
of sternum, 194
of superior maxilla, 88
of surgical neck of humerus, 469
of tarsal bones, 519
of trachea, 155
of upper end of fibula, 509
of humerus, 466
epiphyseal separation, 468
of anatomic neck, 467
of radius, 477
of tibia, 506
of ulna, 477
of upper jaw, 88
open, 439
osteomyelitis in, 443
pain in, 448
pathologic, 439, 441
pertrochanteric, of Kocher, 498
pneumonia in, 444
Pott's, 514
pseudarthrosis in, 445
pulmonary edema in, 444
seat of, 440
septic complications in, 443
simple, 439
special, 461
spiral, 439
spontaneous, 441
subjective signs of, 448
subperiosteal, 441
supracondyloid, of humerus, 474
T, of lower end of humerus, 474
thrombosis in, 442
transverse, 439
traumatic delirium in, 444
union with deformity in, 446
vicious union in, 446
x-ray examination in, 449
Y, of lower end of humerus, 474
Fragilitas ossium, fracture associated with, 441
Free bodies in joints in traumatic arthritis, 455
Frontal convolution, ascending, lesions of, 44
lobe, lesions of, 47
tumors of, 76
Frost-bite, gangrene of extremities from, 552
Furuncles of abdomen, 231
Furuncles of back, 201
of face, 94
of neck, 160

GALLBLADDER, gallstones in, 339
hydrops of, 297
infection of, leukocytosis in, 722
malignant disease of, 298
region, palpation of, in gallstones, 339
tumors of, 297
differential diagnosis, 298
Gallstone colic, 264
differential diagnosis, 264
fever in, 264
jaundice in, 264
muscular rigidity in, 264
pain and tenderness in, 264
vomiting in, 264
Gallstones, 337
diagnosis in interval, 338
of location, if arrested temporarily or permanently, 339
differential diagnosis, 337
history, 338
in common duct, 337, 340
in cystic duct, 340
in gallbladder, 339
leukocytosis in, 724
palpation of gallbladder region in, 339
physical examination in, 339
Ganglion of extremities, 570
Gangrene of extremities, 548
diabetic, 551
dry, 549
embolic, 552
from frost-bite, 552
from injury to arteries or veins of limb, 552
from Raynaud's disease, 553
in infectious diseases, 552
moist, 549
pre-senile, 551
senile, 551
pulmonary, 213
Gangrenous stomatitis, 123
Gastro-intestinal tract, diseases of, leukocytosis in, 723
Genito-urinary tract, lower portion of, localization of pus in, 381
instrumental examination for, 383
two-glass test for, 381
urethroscopy for, 384
Genu valgum, 653
varum, 654
Gibbus in Pott's disease, 688
Glanders complicating wounds, 543
Glossitis, acute, 128, 129
chronic, 129
Glottis, edema of, 190
Glycosuria after fracture of base of skull, 34
Goiter, 179, 185
cystic, 177
exophthalmic, 189. See also *Exophthalmic goiter.*
fibrous, 186

Goiter, lingual, 137
malignant, 187
non-malignant, 185
retrosternal, 187
simple parenchymatous, 185
vascular, 186
Gonitis, tuberculous, 641. See also *Tuberculosis of knee-joint.*
Gonorrheal arthritis, 609
phlegmonous, 609
purulent, 609
serofibrinous, 609
articular hydrops, 609
epididymitis, 392
orchitis, 392
peritonitis, acute, 250
Gouty arthritis, 618
acute, 618
atypical or irregular form, 619
chronic, 618
Graefe's symptom in exophthalmic goiter, 189
Granulation-tissue tumors of jaws, 111
Granuloma of jaws, 111
Greenstick fractures of radius and ulna, 480
Gumma of lips, 106
Gummatous osteomyelitis of extremities, 587
periostitis of extremities, 587
Gunshot fractures, 439
wounds of spine, 684

HABITUAL dislocation, 456
Hallux valgus, 661
Hands, cellulitis of, complicating wounds, 531
congenital deformities, 661
edema of, in cancer of breast, 230
foreign bodies in, 661
Harelip, 103
Head, affections, 17
injuries of, blood-pressure in, 730
tetanus, 541
Headache in brain tumors, 75
in purulent leptomeningitis, 81
Heart, diseases of, postoperative, 702
penetrating injuries of, 200
subcutaneous injuries of, 198
Heberden's nodes in arthritis deformans, 615
Hemangioma of extremities, 556
of neck, 176
cavernous, 176
of tongue, 133
Hemangiosarcoma of extremities, 557
Hematemesis, postoperative, 706
Hematomyelia, 681
Hematorachis, 681
Hematuria in malignant tumors of kidney, 315
in renal calculus, 368
Hemophilia, 433
Hemophiliac joints, 624
Hemorrhage, 525
blood-pressure in, 730
characteristic signs of, 525
Hemorrhage, compression of brain from, 36
concealed, postoperative, 697
external, postoperative, 697
from injuries of intracranial portion of internal carotid and vertebral arteries, 50
from middle meningeal artery, 48
from smaller arteries of pia arachnoid, 49
from venous sinuses of brain, 49, 53
in cancer of stomach, 335
in fracture of base of skull, 27
in scalp, location, 18
in ulcer of stomach, 333
intermeningeal, 49, 52
internal, early signs of, 284
in injuries of abdominal viscera, 244
postoperative, 697
intracranial, 48
middle meningeal, 48, 50
postoperative, 696
subdural, 52
Hemorrhoids, 355
of bladder, cystoscopy in, 746
Hemothorax in penetrating injuries of thorax, 199
Hepatoptosis, 293
Hernia, 401
cerebri, 62
diaphragmatic, 421
femoral, 414
differential diagnosis, 415
in connection with imperfect descent of testicle, 391
incarcerated, 402
inflamed, 402
inguinal, 404
differential diagnosis, 409
direct, 406
hernia of bladder in, 407
of ovary in, 409
of vermiform appendix in, 409
indirect, 405
interstitial, 407
oblique, 405
straight, 406
unusual contents of, 407
Littré's, 404
lumbar, 421
obstructed, 402
obturator, 421
of bladder in inguinal hernia, 407
of muscles, 427
of ovary in inguinal hernia, 409
of vermiform appendix in inguinal hernia, 409
pulmonary, 207
rarer forms of, 421
sciatic, 421
strangulated, 403
umbilical, 417
congenital, 417
in adults, 418
infantile, 417
ventral, 420
Herpes of lips, 104

Hip, congenital dislocations of, 646
differential diagnosis, 647
contusion of, 498
dislocation of, 496
injuries of, 492
in children, 498
Hip-joint, diseases of, 631
tuberculosis of, 632. See also *Tuberculosis of hip-joint.*
Hodgkin's disease, enlargement of cervical lymph-nodes in, 166
Hour-glass stomach in ulcer of stomach, 334
Housemaid's knee, 567
Humerus, fractures of lower end, 473
epiphyseal separation, 475
intercondyloid, 474
of external epicondyle and external condyle, 476
of internal epicondyle or internal condyle, 476
of shaft, 472
of surgical neck, 469
supracondyloid fracture of, 474
T-fractures, of lower end, 474
upper end, fractures of, 466
epiphyseal separation, 468
of anatomic neck, 467
Y-fractures, of lower end, 474
Hydatid cysts in muscles of extremities, 572
of liver, 294
differential diagnosis, 294
suppurating, 254
of lungs, 216
of neck, 177
of skull, 72
of spleen, 306
Hydrocele in connection with imperfect descent of testicle, 391
Hydrocephalocele, 71
Hydrocephalus, 73
Hydronephrosis, 313
differential diagnosis, 314
Hydrophobia complicating wounds, 542
Hydrophobic tetanus, 541
Hydrops, articular, tuberculous, 611
of gallbladder, 297
of joints, chronic, 614
gonorrheal, 609
intermittent, 605, 614
Hyoid bone, fractures of, 155
Hyperleukocytosis, 720
Hypertrophy of breasts, 227
of prostate, cystoscopy in, 740
Hypoglossal nerve, injury, in fracture of base of skull, 31
Hypospadias, 379
Hysteria, postoperative, 714
Hysterical joints, 626
spine, 692

Icterus, postoperative, 703
Ileocecal actinomycosis, inflammatory tumors of intestine from, 307
tuberculosis, inflammatory tumors of intestine from, 307
Ileus, 277
Ileus, adynamic, 283
differential diagnosis, 283
postoperative, 707
Incarcerated hernia, 402
Index, opsonic, 719
abnormal, 719
effect of bacterial infections on, 719
phagocytic, of leukocyte, 718
Infection along tendon-sheaths complicating wounds, 532
between muscles and tendons of forearm and arm complicating wounds, 532
epidermal, complicating wounds, 531
hepatic, 248
in lower extremities complicating wounds, 534
in wounds of upper extremities, 530
intracranial, following injury, differential diagnosis, 61
of cutaneous and subcutaneous tissues complicating wounds, 531
of lymph-nodes of scalp, 66
of male reproductive organs, 391
of scalp, 65
postoperative, 700
renal, 251
subungual, complicating wounds, 532
ungual, complicating wounds, 532
Infectious diseases, arthritis following, 608
gangrene of extremities in, 552
leukocytosis in, 720
Inflamed hernia, 402
Inflammation, acute, of lymph-nodes of extremities, 565
of neck, 162
chronic, of lymph-nodes of extremities, 566
of bladder, 372. See also *Cystitis.*
of intra-abdominal portion of vas deferens, 276
of testicle in imperfect descent, 389
Inflammatory exudates, abdominal tumors due to, 320
processes of rectum and results, 349
Inflation of stomach or colon in diagnosis of tumors of abdomen, 289
Inguinal hernia, 404. See also *Hernia, inguinal.*
Inspection in tuberculous coxitis, 632, 633
in tumors of abdomen, 287
of rectum, 345
Instrumental examination for localization of pus in genito-urinary tract, 383
Intermittent claudication, 551
Intestinal obstruction, 277
acute, 277
chronic, 341. See also *Enterostenosis.*
constipation in, 277
early signs of, 277
examination of abdomen in, 280
from foreign bodies, 282
history of, 282
from tumors, 282
history of, 282
leukocytosis in, 723
pain in, 278

Intestinal obstruction, probable nature and seat of, 279
symptoms of, 277
vomiting in, 278
strangulation, 279
constipation in, 280
history of, 279
nausea in, 280
pain in, 279
shock in, 280
vomiting in, 280
Intestine, carcinoma of, 308
condition of bowel movements in, 309
differential diagnosis, 309
symptoms of stenosis in, 308
tumor in, 309
evacuation of, in intussusception, 282
neoplasms of, 308
tumors of, 307
inflammatory, 307
from ileocecal actinomycosis, 307
from tuberculosis, 307
Intoxication, acid, hepatic postoperative, 703
Intrasphincteric abscess, 352
Intussusception, 281
condition of abdomen in, 282
evacuation of bowels in, 282
fever in, 282
meteorism in, 282
nausea in, 282
pain in, 281
previous history, 281
prostration in, 282
tenesmus in, 282
tumor in, 282
vomiting in, 282

JAUNDICE in gallstone colic, 264
Jaw, dislocation of, 90
lower, fractures of, 89
upper, fractures of, 88
Jaws, actinomycosis of, 120
acute suppurative osteomyelitis of, 121
carcinoma of, 115
chondroma of, 113
cystadenoma of, 110
dentigerous cysts of, 108
diseases of, 108
fibroma of, 111
granulation-tissue tumors of, 111
granuloma of, 111
infections of, 117
following compound fractures, 119
from teeth, 118
odontoma of, 109
osteoma of, 110
phosphorus necrosis of, 121
sarcoma of, 113
syphilis of, 120
tuberculosis of, 119
tumors of, 108
benign, 108
malignant, 113
Joints, acute rheumatism of, leukocytosis in, 721
Joints, chronic rheumatism of, 618
diseases of, 601
examination of joint, 603
general condition of patient, 603
history of case, 603
empyema of, tuberculous, 612
free bodies in, in traumatic arthritis, 455
hemophiliac, 624
hydrops of, chronic, 614
gonorrheal, 609
intermittent, 605, 614
tuberculous, 611
hysterical, 626
injuries of, 422
general considerations upon, 450
lipoma of, 626
neuralgic, 626
of extremities, injuries of, 438
rheumatism of, acute, 605
scorbutic, 624
tuberculosis of, 611. See also *Tuberculosis of joints.*
tumors of, 626

KELOID of extremities, 555
Kidney, calculus in, 365. See also *Calculus, renal.*
colic of, 270
symptoms, 270
congenital displacement of, 311
malformations of, 312
diseases of, newer methods of diagnosis, 732
postoperative, 709
enlargement of, diseases accompanied by, 313
in tuberculosis of kidney, 365
floating, 312
differential diagnosis, 313
in pyemia complicating wounds, 539
in septicemia complicating wounds, 537
infections of, 251
injury of, symptoms, 241
lesions of, 361
clinical picture, 361
examination of urine in, 361
objective examination in, 362
malignant tumors of, 315
cachexia in, 317
hematuria in, 315
metastases in, 317
pain in, 316
tumors in, 316
metastatic suppuration of, 252
movable, 312
differential diagnosis, 313
neoplasms of, 314
differential diagnosis, 318
polycystic, 314
differential diagnosis, 314
tuberculosis of, 363. See also *Tuberculosis of kidney.*
tumors of, 311
Knee, dislocations of, 506
backward, 506
forward, 506

Knee, housemaid's, 567
Knee-joint, Charcot, 620
  congenital dislocation of, 648
  diseases of, 639
  injuries in vicinity of, 504
  tuberculosis of, 641. See also *Tuberculosis of knee-joint.*
Knock-knee, 653
Kocher's pertrochanteric fracture, 498

LACERATION of brain, 42
Lachrymal and salivary glands, symmetrical disease of, 98
Larynx, carcinoma of, 191
  fractures of, 155
  papilloma of, 190
Leg, varicose ulcers of, 545
Leptomeningitis, purulent, 56, 81
    headache in, 81
    optic neuritis in, 81
    pulse in, 81
    respiration in, 81
Leukemia, examination of blood in, 728
  lymphatic, enlargement of cervical lymph-nodes in, 164
Leukocyte-count, differential, 715
    value of, 725
      in differential diagnosis, 726
Leukocytes, phagocytic index of, 718
Leukocytosis, 720
  in abscess formation, 721
  in acute articular rheumatism, 721
  in appendicitis, 259, 721
    in differentiating, 722
  in carcinoma, 725
  in diseases of gastro-intestinal tract, 723
    of nervous system, 724
    of pancreas, 724
    of urinary system, 724
  in disturbances of digestion, 723
  in duodenal ulcer, 723
  in erysipelas, 721
  in gallstones, 724
  in gastric ulcer, 723
  in infection of gallbladder and bile-passages, 722
    of serous membranes, 723
  in infectious diseases, 720
  in intestinal obstruction, 723
  in malignant disease, 724
  in meningitis, 721
  in osteomyelitis, 723
  in pelvic peritonitis, 722
  in pneumonia, 720
  in salpingitis, 722
  in sarcoma, 725
  in scarlet fever, 721
  in septicemia, 721
  in surgical conditions of liver, 723
  in syphilis, 728
  in tuberculosis, 727
  in typhoid fever, 720
  pathologic, 720
  physiologic, 720
Leukoma, 129
Leukopenia, 720
Leukoplakia, 129
  of bladder, cystoscopy in, 744
Ligaments, rupture of, in traumatic arthritis, 453
Lingual goiter, 137
  tonsil, 138
Lipoma arborescens, 626
  at floor of mouth, 126
  of abdominal wall, 233
  of face, 99
  of joints, 626
  of neck, 178
  of salivary glands, 143
  of scalp, 67
  of thorax, 206
  of tongue, 133
Lips, 104
  carcinoma of, 108
  chancre of, 105
  enlargement of, 104
  epithelioma of, 107
  gumma of, 106
  herpes of, 104
  malformations of, 103
  ulcerations of, 105
Litigation symptoms, 683
Littré's hernia, 404
Liver, acid intoxication of, postoperative, 703
  carcinoma of, 296
  corset, 291
    differential diagnosis, 292
  cystic disease of, 295
  diseases of, postoperative, 703
  dullness, obliteration of, in injuries of alimentary canal, 241
      in perforating ulcers of stomach and duodenum, 266
  floating, 293
    differential diagnosis, 293
  hydatid cysts of, 294
      differential diagnosis, 294
  infections of, 248
  sarcoma of, 296
  suppurating echinococcus cysts of, 254
  surgical conditions of, leukocytosis in, 723
  syphilis of, 296
  tumors of, 291
    malignant, 296
      differential diagnosis, 297
Localization, cerebral, 44
  spinal, 666
Locking of joint in traumatic arthritis, 455
Lockjaw, 122, 540. See also *Tetanus.*
Lumbar hernia, 421
  puncture, determining point for, 52
    method of performing, 53
  vertebræ, fractures of, 678
Lungs, abscess of, 213
  actinomycosis of, 216
  echinococcus of, 216
  edema of, in fractures, 444
  embolism of, postoperative, 702
  gangrene of, 213
  hernia of, 207
  postoperative complications of, 701

Lungs, prolapse of, in penetrating injuries of thorax, 200
subcutaneous injuries of, 196
tumors of, 217
Lupus of face, 95
Luschka's gland, sarcoma of neck arising from, 180
Lymphangioma, congenital cystic, of neck, 176
of extremities, 556
of face, 100
of tongue, 134
Lymphangiosarcoma of extremities, 557
Lymphangitis, acute, of extremities, 563
chronic, of extremities, 564
Lymphatic leukemia, enlargement of cervical lymph-nodes in, 164
Lymph-cysts of extremities, 564
Lymph-nodes of extremities, acute inflammation of, 565
chronic inflammation of, 566
diseases of, 565
of neck, acute inflammation, 162
affections, 162
enlargement, 163
carcinomatous, 167
in lymphatic leukemia, 164
in lymphosarcoma, 165
in pseudo-leukemia, 166
simple hyperplastic, 172
syphilitic, 168
tuberculous, 169
of scalp, infection, 66
pelvic, neoplasms of, 323
Lymphosarcoma, enlargement of cervical lymph-nodes in, 165
Lymph-vessels of extremities, diseases of, 563

MACROLABIA, 104
Main en griffe, 436
Mal perforans pedis, 546
Maladie cystique, 223
Malar bone, fractures of, 88
Malformations, congenital, of bladder, 371
of kidney, 312
of neck, 147
of penis, 379
of rectum, 346
of urethra, 379
in connection with urachus, 236
of lips, 103
of neck, acquired, 147
congenital, 147
Mal-union in fractures, 446
Mastitis, acute puerperal, 221
chronic, 223
cystic, 223
interstitial, 224
neonatorum, 223
traumatic, 223
Mastoid suppuration, intracranial complications of, 80
Maxilla, inferior, fractures of, 89
superior, fractures of, 88
Median nerve, injury of, 437
Mediastinum, affections of, 218
inflammatory processes of, 218
tumors of, 219
Medulla, lesions of, 48
Meningeal artery, hemorrhage from, 48
Meninges, infection, compression of brain from, 37
Meningitis, cerebrospinal, cytodiagnosis in, 731
leukocytosis in, 721
serous, 82
tuberculous, cytodiagnosis in, 731
Meningocele, 71, 662
spuria traumatica, 19
Mental disturbances following cranial injury, 64
in pyemia complicating wounds, 539
in septicemia complicating wounds, 537
symptoms in brain tumors, 75
Mesenteric vessels, embolism of, 272
differential diagnosis, 273
thrombosis of, 272
differential diagnosis, 273
Mesentery, cysts of, 310
tumors of, 310
Metacarpal bones, dislocations of, 486
fractures of, 486
Metapneumonic empyema, 208
Metatarsal bones, dislocations of, 523
fractures of, 522
Metatarsalgia, 660
Meteorism in intussusception, 282
Microstomia, 104
Micturition, disturbances in, in renal calculus, 369
painful and increased frequency of, in acute cystitis, 372
Middle ear suppuration, intracranial complications of, 80
Mikulicz's disease, 98
Miner's elbow, 567
Mobility, abnormal, in fractures of pelvis, 489
Moebius' symptom of exophthalmic goiter, 189
Moles on extremities, 556
pigmented, of scalp, 68
of thorax, 206
Molluscum fibrosum of face, 99
Morton's disease, 660
Motor aphasia, 47
region of brain, tumors of, 76
Mouth, diseases of, 103, 123
escape of blood from, in fracture of base of skull, 27
floor of, carcinoma of, 126
dermoid cysts at, 126
diagnosis of conditions at, 124
lipoma at, 126
injuries of, 123
syphilis of, 124
Movable kidney, 312
differential diagnosis, 313
Mucous patches on tongue, 131
Mummification of extremities, 549
Mumps, 140

Muscles and tendons of forearm and arm, infection between, complicating wounds, 532
contusions of, 424
hernia of, 427
injuries of, 424
of extremities, angioma of, 572
desmoids of, 572
diseases of, 570
hydatid cysts in, 572
inflammatory affections, 570
sarcoma of, 572
tumors of, 572
penetrating wounds of, 428
rupture of, 426
Muscular contracture, ischemic, of extremities, 571
paralysis of extremities, 571
rheumatism, acute, of extremities, 570
rigidity in appendicitis, 257
in gallstone colic, 264
in perforating ulcers of stomach and duodenum, 266
Musculospiral nerve, injuries of, 435
Myelocele, 662
Myelocystocele, 662
Myeloma of bones of extremities, 601
Myelomeningocele, 662
Myoma, large, of uterus, 324
Myositis, acute serous, of extremities, 570
suppurative, of extremities, 571
fibrous, of extremities, 571
ossificans of extremities, 571
sclerosing, of extremities, 571
simple chronic, of extremities, 571
syphilitic, of extremities, 571
traumatic ossifying, 425
tuberculous, of extremities, 571

NASAL bones, fractures of, 87
deformity due to syphilis, 98
septum, injuries of, 87
Nausea in intestinal strangulation, 280
in intussusception, 282
in ulcer of stomach, 333
in volvulus, 280
Neck, actinomycosis of, 161
affections of, 147
arteries of, injuries, 152
blood-cysts of, 177
carbuncle of, 160
carcinoma of, 181
primary, 181
secondary, 181
chondroma of, 178
cystic tumors of, 174
dermoid cysts of, 178
echinococcus cysts of, 177
fibroma of, 179
furuncle of, 160
hemangioma of, 176
cavernous, 176
inflammatory processes in, 157
injuries of, 152
lipoma of, 178
lymphangioma of, congenital cystic, 176
Neck, lymph-nodes of, acute inflammation, 162
affections, 162
enlargement, 163. See also *Lymph-nodes of neck, enlargement.*
malformations of, acquired, 147
congenital, 147
nerves of, injuries, 154
osteoma of, 178
previsceral suppuration in, 158
sarcoma of, 179
arising from carotid body, 180
sheath, 180
sebaceous cysts of, 178
solid tumors of, 178
superficial structures, infection of, 160
traumatic aneurysms of, 152
tumors of, 172
auscultation and percussion, 174
classification, 174
examination, 172
of blood, spleen, mouth, and body in general, 173
inspection, 172
palpation, 173
unilocular cysts of, 177
veins of, injuries, 154
woody phlegmon of, 161
Necrosis, phosphorus, of jaws, 121
Nerve, auditory, injury, in fracture of base of skull, 30
circumflex, injury of, 435
eleventh, injury, in fracture of base of skull, 31
facial, injury of, 139
fourth, injury, in fracture of base of skull, 30
hypoglossal, injury, in fracture of base of skull, 31
median, injury of, 437
musculospiral, injury of, 435
ninth, injury, in fracture of base of skull, 31
olfactory, injury, in fracture of base of skull, 30
optic, injury, in fracture of base of skull, 30
peroneal, injury of, 438
popliteal, external, injury of, 438
sciatic, and branches, injury of, 438
sixth, injury, in fracture of base of skull, 30
tenth, injury, in fracture of base of skull, 31
third, injury, in fracture of base of skull, 30
trigeminal, injury, in fracture of base of skull, 31
twelfth, injury, in fracture of base of skull, 31
ulnar, injury of, 437
Nerves, injuries of, 433, 435
in dislocations, 457
in fractures, 443
of base of skull, 28
of extremities, diseases of, 573

Nerves of extremities, tumors of, 574
of neck, injuries of, 154
Nervous system, diseases of, leukocytosis in, 724
Neuralgia, trigeminal, 101
Neuralgic joints, 626
Neuritis of extremities, 573
optic, in abscess of brain, 83
in brain tumors, 75
in purulent leptomeningitis, 81
Neuromata dolorosa of extremities, 574
multiple, of extremities, 575
traumatic, of extremities, 574
Neuropathic arthritis, 621
Nevus, pigmented, of abdomen, 233
Ninth nerve, injury, in fracture of base of skull, 31
Nitze's cystoscopes, 737
Nodes, Heberden's, in arthritis deformans, 615
Noma, 95, 123
Nose, escape of blood from, in fracture of base of skull, 27
saddle-, due to syphilis, 97

OBSTRUCTED hernia, 402
Obstruction, intestinal, 277. See also *Intestinal obstruction.*
Obturator hernia, 421
Occipital lobe, lesions, 47
tumors of, 77
Odontoma of jaws, 109
Olfactory nerve, injury, in fracture of base of skull, 30
Omentum, multiple abscess of, 255
puckering of, 343
tumors of, 310
Opsonic index, 719
abnormal, 719
effect of bacterial infections on, 719
Opsonins, 716
technic of measuring quantity, 718
Optic nerve, injury, in fracture of base of skull, 30
neuritis in abscess of brain, 83
in brain tumors, 75
in purulent leptomeningitis, 81
Orchitis, gonorrheal, 392
Os calcis, fractures of, 521
innominatum, sarcoma of, 323
Osteitis deformans, 592
Osteoarthropathic pneumatique, 592
Osteoma of extremities, 595
of jaws, 110
of neck, 178
of skull, 72
Osteomalacia of extremities, 589
differential diagnosis, 590
Osteomyelitis, acute infective, of extremities, 578
of ribs, 202
of skull, 70
of spine, 691
of sternum, 203
suppurative, of extremities, 578, 579
differential diagnosis, 581
Osteomyelitis, acute suppurative, of jaws, 121
gummatous, of extremities, 587
in fractures, 443
leukocytosis in, 723
Osteoporosis, fracture associated with, 441
Otitic cerebral abscess, 83
Ovary, hernia of, in inguinal hernia, 409
tumors of, large, 324
pedunculated, 324
torsion of pedicle, 273
differential diagnosis, 274

PACHYMENINGITIS hæmorrhagica interna, 55
purulent, 56
Pain as early sign of acute abdominal affections, 256
in appendicitis, 256
in carcinoma of stomach, 335
in coxa vara, 651
in fractures, 448
of pelvis, 489
in gallstone colic, 264
in intestinal obstruction, 278
strangulation, 279
in intussusception, 281
in malignant tumors of kidney, 316
in perforating ulcers of stomach and duodenum, 266
in Pott's disease, 687
in renal calculus, 367
in tuberculosis of joints, 612
of kidney, 365
in tuberculous gonitis, 642
in ulcer of stomach, 332
in volvulus, 280
location of, in tuberculous coxitis, 636
referred, from spinal and thoracic conditions, 276
Palate, diseases of, 103
tumors of, 127
Palpation in empyema, 209
in tuberculous coxitis, 632, 634
in tumors of abdomen, 288
of gallbladder region in gallstones, 339
of rectum, 345
results of, in renal calculus, 367
Pancreas, diseases of, leukocytosis in, 724
Pancreatic cysts, 301
differential diagnosis, 302
neoplasms, 303
differential diagnosis, 303
tumors, 299
Pancreatitis, acute, 270
differential diagnosis, 270
chronic, tumors due to, 299
Papillary wart on extremities, 556
Papilloma of larynx, 190
of tongue, 134
Paralysis, Brown-Séquard, 666
muscular, of extremities, 571
pseudo-, 621
Paraphimosis, 385
Paraplegia dolorosa in cancer of breast, 230
Parasites of bladder, cystoscopy in, 743

Parathyroid glands, accessory, cysts of, 177
Parietal convolutions, ascending, lesions of, 44
lobe, lesions, 47
tumors of, 77
Parotid duct, injuries of, 139
gland, carcinoma of, 145
chondrosarcoma of, 144
injuries of, 138
tumors of, 145
Parotitis, cœliac, 141, 713
postoperative, 713
Patella, congenital dislocation, 648
dislocations of, 505
fractures of, 505
Patent urachus, cystoscopy in, 744
Patulency of ureter, 734
Pedicles of ovarian and uterine tumors, torsion, 273
differential diagnosis, 274
Pelvic lymph-nodes, neoplasms of, 323
peritonitis, leukocytosis in, 722
viscera, abdominal tumors having origin in, 323
of female, tumors of abdomen arising from, 323
Pelvis, fractures of, 488
abnormal mobility in, 489
pain in, 489
rupture of bladder in, 491
of urethra in, 490
Penis, congenital malformations of, 379
diseases and injuries of, 379
epithelioma of, 386
Percussion in empyema, 209
in tumors of abdomen, 289
Perforating ulcers of stomach and duodenum, 266
differential diagnosis, 267
dullness in flanks and right iliac region in, 267
facies in, 267
muscular rigidity in, 266
obliteration of liver dullness in, 266
pain in, 266
pulse in, 267
respiration in, 267
symptoms, 266
vomiting in, 266
of typhoid fever, 268
differential diagnosis, 269
Perforation in ulcer of stomach, 333
Pericarditis, suppurative, 217
Pericardium, penetrating injuries of, 200
subcutaneous injuries of, 198
Pericolitis sinistra, 255
Perigastric adhesions in gastric ulcer, 335
Perinephritis, 251
differential diagnosis, 252
Periosteal sarcoma of ribs, 207
Periostitis, acute infective, of extremities, 578
of skull, 70
traumatic, of extremities, 577
gummatous, of extremities, 587
Perirectal infection, 350
phlegmon, diffuse, 350
Perisinuous abscess, 80
Peristalsis in enterostenosis, 342
Perithelioma of bones of extremities, 594, 601
Peritoneal cavity, free fluid in, in injuries of alimentary canal, 241
Peritoneum, tumors of, 310
Peritonitis, acute, blood-pressure in, 731
gonorrheal, acute, 250
pelvic, leukocytosis in, 722
pneumococcus, 250
postoperative, 708
primary forms, 250
tuberculous, 343
abdominal tumors due to, 320
acute, 250
ascitic form, 344
differential diagnosis, 344
Peritonsillar abscess, 190
Pernicious anemia, examination of blood in, 728
Peroneal nerve, injury of, 438
Pertrochanteric fracture of Kocher, 498
Pes planus, 657
Pfeiffer's disease, 171
Phagocytic index of leukocyte, 718
Phagocytosis, 716
Phalanges, dislocations of, 486
fractures of, 486
of toes, fractures of, 522
Pharynx, diverticula of, 177
Phimosis, 385
Phlebitis of extremities, 561
postoperative, 711
Phlegmon, acute, of thoracic wall, 201
diffuse perirectal, 350
ligneux of Reclus, 161
of scalp, 66
woody, of neck, 161
Phlegmonous cholecystitis, 247
Phloridzin test, 748
Phosphorus necrosis of jaws, 121
Pia arachnoid, hemorrhage from smaller arteries of, 49
Pituitary body, tumor of, causing acromegaly, 79
Pleura, actinomycosis of, 216
subcutaneous injuries of, 196
tumors of, 212
Pleural fluids, cytodiagnosis of, 732
Plexus, brachial, injury of, 154, 437
Pneumococcus arthritis, 608
peritonitis, 250
Pneumonia in fractures, 444
in penetrating injuries of thorax, 200
leukocytosis in, 720
postoperative, 701, 702
Pneumothorax in penetrating injuries of thorax, 199
Podagra, 618
Poisoning from drugs, postoperative, 712
Poliomyelitis, anterior, deformities caused by, 654

Polycystic kidneys, 314
differential diagnosis, 314
Polydactylism, 661
Polyps of rectum, 359
Pons varolii, lesions of, 47
Pontomedullocerebellar space, tumors of, 77
Popliteal nerve, external, injury of, 438
Postoperative complications, 696
miscellaneous, 711
Pott's disease, 684
abscesses in, 688
deformity in, 687
differential diagnosis, 689
gibbus in, 688
pain in, 687
rigidity of spine in, 686
spinal cord symptoms, 689
fracture, 514
Pregnancy, extra-uterine, rupture of, 284
Prevesical abscess, 232
Previsceral suppuration in neck, 158
Proctitis, 349
acute, 349
chronic, 349
hypertrophic, 350
Prolapse of lung in penetrating injuries of thorax, 200
of rectum, 356
Prostate, affections of, 377
enlargement of, 377
differential diagnosis, 378
hypertrophy of, cytoscopy in, 740
Prostration in intussusception, 282
Pruritus ani, 349
Pseudarthrosis in fractures, 445
Pseudoleukemia, enlargement of cervical lymph-nodes in, 166
Pseudoparalysis, 621
syphilitic, 585
Psoriasis linguæ, 129
Puckering of omentum, 343
Puerperal mastitis, acute, 221
Pulled elbow, 479
Pulse in appendicitis, 258
in perforating ulcers of stomach and duodenum, 267
in purulent leptomeningitis, 81
in pyemia complicating wounds, 539
in septicemia complicating wounds, 537
slow, in brain tumors, 75
Puncture, exploratory, in empyema, 210
lumbar, determining point for, 52
method of performing, 53
Purulent leptomeningitis, 56, 81
headache in, 81
optic neuritis in, 81
pulse in, 81
respiration in, 81
pachymeningitis, 56
Pus, localization of, in lower portion of genito-urinary tract, 381
instrumental examination in, 383
two-glass test for, 381
urethroscopy for, 384
Pyelitis, 362
Pyelonephritis, 251
differential diagnosis, 251
Pyemia complicating wounds, 538
differential diagnosis, 540
Pylephlebitis, suppurative, 249
Pylorus, stenosis of, acquired, gastric dilatation from, 332
congenital, gastric dilatation from, 331
Pyonephrosis, 252
Pyopericardium, 217

Rachioschisis, 662
Rachitic rosary, 591
Rachitis, 590
Radiographic examination in renal calculus, 369
Radius and ulna, dislocation of, 477
backward, 477
dislocation of, 478
fractures of shaft, 479
of head and neck, 477
of lower end, 482
of upper end, 477
greenstick fracture of, 480
lesions of, 473
subluxation of, 479
Railway spine, 683
Ranula, acute, 125
chronic, 126
Rashes, septic, postoperative, 712
Raynaud's disease, gangrene of extremities due to, 553
Reclus, phlegmon ligneux of, 161
Rectal space, superior, abscess of, 352
Recti muscles of abdomen, suppuration in sheath of, 231
Rectum, 345
abnormal opening of, 346
atresia of, 346
cancer of, 359
circumscribed suppuration of, 350
congenital malformations of, 346
cystic tumors behind, 695
examination of, 345
foreign bodies in, 348
history in examining, 346
inflammatory processes and results, 349
injuries of, 347
inspection of, 345
neoplasms of, 359
palpation of, 354
polyps of, 359
prolapse of, 356
stricture of, 357
differential diagnosis, 358
ulceration of, non-malignant, 354
use of specula in examining, 345
Referred pain from spinal and thoracic conditions, 276
Reproductive organs, male, infections of, 391
Respiration in perforating ulcers of stomach and duodenum, 267
in purulent leptomeningitis, 81
Retained testicle, 388
Retention-cysts of salivary glands, 141

Retromuscular suppuration in abdominal wall, 231
Rheumatism, acute articular, 605
leukocytosis in, 721
of extremities, 570
chronic articular, 618
Rib, cervical, 148
Ribs, acute osteomyelitis of, 202
enchondroma of, 207
fractures of, 193
signs due to fracture proper, 193
due to injury of intrathoracic viscera, 194
periosteal sarcoma of, 207
secondary tumors of, 207
tuberculosis of, 203
Rickets, 590
fetal, 591
Riva-Rocci sphygmomanometer, 38
Rodent ulcers of extremities, 557
Rosary, rachitic, 591
Rupture of bladder in fractures of pelvis, 491
of extra-uterine pregnancy, 284
of ligaments in traumatic arthritis, 453
of muscles, 426
of tendons, 426
of urethra, 380
in fractures of pelvis, 490

Sacrococcygeal sequestration dermoids, 695
teratomata, 695
tumors, 695
Sacroiliac joints, diseases of, 630
tuberculosis of, 630
Saddle-nose due to syphilis, 97
Salivary and lachrymal glands, symmetrical disease of, 98
calculus, 125, 140
ducts, cysts of, 142
fistula, 139
glands, affections of, 138
angioma of, 142
benign connective-tissue tumors of, 142
cysts of, 142
inflammatory affections of, 140
injuries of, 138
fibroma of, 142
lipoma of, 143
mixed tumors of, 143
retention-cysts of, 141
sarcoma of, 143
submaxillary, solid tumors of, 125, 179
syphilis of, 141
tuberculosis of, 141
tumors of, 141, 142
Salpingitis, leukocytosis in, 722
Sapremia complicating wounds, 536
Sarcoma, leukocytosis in, 725
of bones of extremities, 597
differential diagnosis, 600
fracture in, 600
myelogenous, 599
periosteal, 599
primary forms, 598
Sarcoma of bones of extremities, x-ray in, 600
of breast, 228
of extremities, 556
of face, 101
of jaws, 113
of liver, 296
of muscles of extremities, 572
of neck, 179
arising from carotid body, 180
sheath, 180
of os innominatum, 323
of salivary glands, 143
of scalp, 69
of skull, 72
of spleen, 306
of thorax, 206
of tongue, 134
periosteal, of ribs, 207
Scalp, angioma of, 68
cavernous, 68
arteriovenous aneurysm of, 69
carcinoma of, 69
cirsoid aneurysm of, 68
contused wounds of, 18
in infants and young children, 18
in older children and adults, 20
dermoid cysts of, 67
diseases of, 65
erysipelas of, 66
fibroma of, 68
hemorrhages in, location, 18
infection of, 65
injuries of, 17
lipoma of, 67
lymph-nodes of, infection, 66
malignant tumors of, 69
penetrating wounds of, 17
phlegmon of, 66
pigmented moles of, 68
sarcoma of, 69
traumatic aneurysm of, 69
tumors of, 66
vascular tumors of, 68
warts of, 68
Scapula, fractures of, 465
Scarlatina, leukocytosis in, 721
postoperative, 711
Sciatic hernia, 421
nerve and branches, injury of, 438
Sclerosing myositis of extremities, 571
Scoliosis, 690
Scorbutic joints, 624
Scorbutus, 591
Scurvy, 591
Sebaceous cysts of extremities, 556
of face, 99
of neck, 178
glands of extremities, adenocarcinoma of, 557
adenoma of, 556
of face, adenoma of, 99
Sensory aphasia, 48
Septic complications in fractures, 443
rashes, postoperative, 712
Septicemia complicating wounds, 537
differential diagnosis, 540

Septicemia, leukocytosis in, 721
Septicopyemia complicating wounds, 538
Septum, nasal, injuries of, 87
Sequestration dermoids, sacrococcygeal, 695
Shock, 525
  blood-pressure in, 730
  characteristic signs of, 526
  in intestinal strangulation, 280
  in volvulus, 280
  postoperative, 699
Shoulder, congenital dislocation, 648
  injuries of, differential diagnosis, 460
  region, dislocations in, 461
    fractures in, 461
Shoulder-joint, diseases of, 627
  dislocations of, 470
    backward, 472
    subspinous forms, 472
  tuberculosis of, 628
Sigmoid sinus, thrombosis of, 85
Sinus, cavernous, thrombosis of, 85
  cranial, thrombosis of, 84
  sigmoid, thrombosis of, 85
  thrombosis, intracranial, 59
Sinuses, venous, of brain, hemorrhage from, 49, 53
Sixth nerve, injury, in fracture of base of skull, 30
Skin, injuries of, 423
Skull, acute osteomyelitis of, 70
    periostitis of, 70
  congenital defects of, 71
  diseases of, 69
  echinococcus of, 72
  fractures of, 22. See also *Fractures of skull.*
  injuries of, 17
    mental conditions following, 64
  middle fossa of, tumors of, 78
  osteoma of, 72
  sarcoma of, 72
  syphilis of, 69
  tenderness of, in brain tumors, 76
  tuberculosis of, 69
  tumors of, 72
Sounds, examination of ureter with, 732
Specula, use of, in examining rectum, 345
Speech region, lesions of, 47
Spermatic cord, torsion of, 274
Spermatocele, 399
Sphygmomanometer, Riva-Rocci, 38
Spina bifida, 662
Spinal conditions, referred pain from, 276
  cord symptoms of Pott's disease, 689
    tumors of, 692
  localization, 666
Spine, acute osteomyelitis of, 691
  arthritis deformans of, 691
  concussion of, 683
  cross-lesions of, table of symptoms in, 669-675
  diseases and injuries of, 662, 684
  dislocations of, 679
    pathology, 664
  fractures of, 676. See also *Fractures of spine.*
Spine, gunshot wounds of, 684
  hysterical, 692
  injuries of, 664
    pathology, 664
  lateral curvature, 690
  railway, 683
  rigidity of, in Pott's disease, 686
  stab wounds of, 684
  tumors of, 692
  typhoid, 692
Spleen, enlargements of, 305
  floating, 304
  hydatid cysts of, 306
  sarcoma of, 306
  tumors of, 304
  wandering, 304
Spondylitis deformans, 691
  traumatic, 683
  tuberculous, 684. See also *Pott's disease.*
Sprains, 453
  of elbow, 473
Sputum, examination of, 732
Stab wounds of spine, 684
Status thymicus, postoperative, 713
Stellwag's symptom of exophthalmic goiter, 189
Steno's duct, wounds of, 86
Stenosis of pylorus, acquired, gastric dilatation from, 332
    congenital, gastric dilatation from, 331
  symptoms of, in cancer of intestine, 308
Sternum, acute osteomyelitis of, 203
  fractures of, 194
  secondary tumors of, 207
  tuberculosis of, 203
Still's disease, 617
Stomach, carcinoma of, 335. See also *Carcinoma of stomach.*
  contents, examination of, 732
  dilatation of, 331, 332
    from acquired stenosis of pylorus, 332
    from congenital stenosis of pylorus, 331
    postoperative, 706
  diseases of, postoperative, 704
  hour-glass, in ulcer of stomach, 334
  inflation of, in tumors of abdomen, 289
  surgical diseases of, 331
  tumors of, 289
    differential diagnosis, 290
  ulcer of, 332. See also *Ulcer of stomach.*
    perforating, 266. See also *Ulcer, perforating, of stomach.*
Stomatitis, 123
  gangrenous, 123
  ulcerative, 123
Strangulated hernia, 403
Strangulation, intestinal, 279. See also *Intestinal strangulation.*
Stricture of esophagus, 324
    carcinomatous, 328
    cicatricial, 328
    due to pressure from external causes, 328
    methods of examination, 325
    spasmodic, 329

Stricture of rectum, 357
differential diagnosis, 358
of ureter, 734
Subacromial dislocation, 472
Subastragaloid dislocations, 518
Subclavian artery, aneurysm of, 153
injury of, 152
Subclavicular dislocation, 472
Subcoracoid dislocation, objective signs, 471
Subcortical regions, lesions of, 47
Subcutaneous tissue, infection of, complicating wounds, 531
Subdural hemorrhage, 52
suppuration, 56
Subglenoid dislocations, symptoms of, 472
Subluxation of cartilages in traumatic arthritis, 453
of radius, 479
Submaxillary gland, salivary, solid tumors of, 125, 179
solid tumors of, 179
region, infection in, 158
Subperiosteal fractures, 441
Subphrenic abscess, 253
differential diagnosis, 254
left, in ulcer of stomach, 334
Subungual infection complicating wounds, 532
Supernumerary digits, 661
Suppuration as early sign of acute abdominal affections, 246
circumscribed, of rectum, 350
in abdominal wall, 231
in carotid sheath space, 159
in sheath of recti muscles of abdomen, 231
intracranial, following injuries, 55
mastoid, intracranial complications of, 80
metastatic, of kidney, 252
middle ear, intracranial complications, 80
previsceral, in neck, 158
retromuscular, in abdominal wall, 231
subdural, 56
Suppurative pericarditis, 217
pylephlebitis, 249
Supracondyloid fracture of humerus, 474
Supraorbital nerves, method of making pressure on, 29
Sweat glands of extremities, adenocarcinoma of, 557
adenoma of, 556
of face, adenoma of, 99
Swelling in tuberculosis of joints, 612
in tuberculous coxitis, 636
gonitis, 642
Symmetrical disease of lachrymal and salivary glands, 98
Syndactylism, 661
Synovitis, chronic serous, 605, 614
Syphilis, acquired, of bones of extremities, 586
leukocytosis in, 728
nasal deformity due to, 98
of bladder, cystoscopy in, 744
of bones of extremities, 584, 585
of thorax, 205
of face, 96
Syphilis of jaws, 120
of liver, 296
of mouth, 124
of salivary glands, 141
of skull, 69
of testicle, 398
of tongue, 130
saddle-nose due to, 97
tertiary, ulcerations on back in, 201
Syphilitic arthritis, 619. See also *Arthritis, syphilitic.*
atrophy of tongue, 133
bursitis of extremities, 567
lesions, secondary, of tongue, 131
tertiary, of tongue, 131
lymph-node enlargement of neck, 168
myositis, of extremities, 571
pseudoparalysis, 585
ulcerations of lip, 105
ulcers of extremities, 545
Syringomyelia, arthritis due to, 624

TABES, arthritis due to, 622
Talipes calcaneus, 657
cavus, 657
equinovarus, 656
equinus, 656
valgus, 657
Tarsal bones, fractures of, 519
Teeth, infection of jaws from, 118
Temperature in appendicitis, 259
in tuberculosis of joints, 613
Temporo-maxillary joint, ankylosis of, 122
chronic arthritis of, 122
diseases of, 122
primary acute arthritis of, 122
secondary acute arthritis of, 122
Temporo-sphenoidal abscess, 83
Tenderness in appendicitis, 257
in gallstone colic, 264
in tuberculosis of joints, 612
Tendons and muscles of forearm and arm, infection between, complicating wounds, 532
dislocations of, 427
injuries of, 424
of extremities, diseases of, 567
inflammatory affections of, 567
tumors of, 570
penetrating wounds of, 428
rupture of, 426
Tendon-sheaths, infection along, complicating wounds, 532
injuries of, 424
of extremities, diseases of, 567
inflammatory affections of, 567
tumors of, 570
penetrating wounds of, 428
Tenesmus in intussusception, 282
Tenosynovitis, acute primary, of extremities, 567
serofibrinous, of extremities, 567
seropurulent, of extremities, 568
secondary, of extremities, 568
chronic, of extremities, 568
serous, of extremities, 568

Tenosynovitis, chronic syphilitic, of extremities, 570
crepitans, of extremities, 567
of extremities, 567
tuberculous, of extremities, 568
Tenovaginitis of extremities, 567. See also *Tenosynovitis.*
Tenth nerve, injury, in fracture of base of skull, 31
Teratoma, sacrococcygeal, 695
Test, phloridzin, 748
tuberculin, in tuberculosis of joints, 613
two-glass, for pus in genito-urinary tract, 381
Testicle, 387
abnormalities in development of, 387
benign adenocystoma of, 399
ectopia of, 388
hernia of, in connection with imperfect descent, 391
hydrocele of, in connection with imperfect descent, 391
imperfect descent of, 388
complications, 388
hernia and hydrocele in connection with, 391
inflammation in, 389
tumor formation in, 390
inflammation of, in imperfect descent, 389
mixed tumors of, 400
neoplasms of, 399
retained, 388
syphilis of, 398
traumatic affections of, 393
tuberculosis of, 393
tumor formation of, in imperfect descent, 391
tumors of, 399
Tetanus, 122, 540
cephalic, 541
complicating wounds, 540
differential diagnosis, 541
head, 541
hydrophobicus, 541
symptomatic, 122
T-fractures of lower end of humerus, 474
Third nerve, injury, in fracture of base of skull, 30
Thoma-Zeiss blood-counting apparatus, 716
Thoracic aneurysm, 207
conditions, referred pain from, 276
duct, injuries of, 155
subcutaneous injuries of, 198
viscera, injuries of, 195
non-penetrating or subcutaneous injuries of, 195
wall, actinomycosis of, 202
acute and chronic inflammatory processes of, 201
phlegmon of, 201
skin and subcutaneous tissues of, inflammatory processes, 201
tumors of, 206
Thorax, 193
bones of, syphilis, 205
bony, affections of, 202
Thorax, bony walls of, injuries, 193
fibroma of, 206
lipoma of, 206
penetrating injuries of, 199
dyspnea and cyanosis in, 200
emphysema in, 200
empyema in, 200
hemothorax in, 199
pneumonia in, 200
pneumothorax in, 199
prolapse of lung in, 200
pigmented moles of, 206
sarcoma of, 206
Throat, cut-, 156
Thrombophlebitis of extremities, 562
Thrombosis in fractures, 442
of cavernous sinus, 85
of cranial sinus, 84
of extremities, 561
of mesenteric vessels, 272
differential diagnosis, 273
of sigmoid sinus, 85
postoperative, 710
sinus, intracranial, 59
Thyroglossal cysts, 126, 176
fistula, 147
Thyrohyoid bursæ, 177
Thyroid adenoma, 186
gland, accessory, cysts of, 177
Thyroidism, acute, postoperative, 714
Thyroiditis, 188
Tibia, fractures of lower end, 514
of shaft, 510
of upper end, 506
Tibiotarsal dislocations, 516
Tissues, air in, in fracture of base of skull, 27
soft, injuries of, 422
signs, 423
Toes, dislocations of, 524
phalanges of, fractures, 522
Tongue, 127
benign tumors of, 133
carcinoma of, 134
differential diagnosis, 135
chancre of, 130
congenital affections of, 127
decubital ulcers of, 128
goiter of, 137
hemangioma of, 133
injuries of, 128
lipoma of, 133
lymphangioma of, 134
malignant tumors of, 134
mucous patches on, 131
papilloma of, 134
psoriasis of, 129
sarcoma of, 134
syphilis of, 130
syphilitic atrophy of, 133
lesions of, secondary, 131
tertiary, 131
tonsil of, 137
tuberculosis of, 130
Tongue-tie, 127
Tonsil, lingual, 138

Torsion of pedicles of ovarian and uterine tumors, 273
differential diagnosis, 274
of spermatic cord, 274
Trachea, foreign bodies in, 156
fractures of, 155
Trigeminal nerve, injury, in fracture of base of skull, 31
neuralgia, 101
Trismus, 122, 540. See also *Tetanus*.
Trochanter, great, fracture of, 498
Trophic ulcers of extremities, 546
Tropical abscess, 248
differential diagnosis, 248
Tuberculin test in tuberculosis of joints, 613
Tuberculosis, ileocecal, inflammatory tumors of intestine from, 307
leukocytosis in, 727
of ankle-joint, 645
differential diagnosis, 645
of bladder, 374
cystoscopy in, 739
of bones of extremities, 582
of breast, 225
of elbow-joint, 628
of hip-joint, 632
differential diagnosis, 637
history, 633
inspection in, 632, 633
location of pain in, 636
measurements in, 636
palpation in, 632, 634
swelling in, 636
x-ray examination in, 637
of jaws, 119
of joints, 611
differential diagnosis, 613
family and personal history, 613
fungous form, 612
loss of function and rigidity in, 612
onset and course, 612
pain in, 612
position of limb in, 612
swelling in, 612
temperature in, 613
tenderness in, 612
tuberculin test in, 613
x-rays in, 613
of kidney, 363
cystoscopic examination in, 365
increased frequency of urination in, 364
pain in, 365
renal enlargement in, 365
symptoms, 364
general, 365
ureteral catheterization in, 365
urinary changes in, 364
of knee-joint, 641
abscess, sinus formation, and fever in, 643
differential diagnosis, 643
heat in, 642
pain in, 642
rigidity, atrophy, and deformity in, 642
swelling in, 642
tenderness in, 642
x-ray examination in, 643
Tuberculosis of ribs, 203
of sacroiliac joint, 630
of salivary glands, 141
of shoulder-joint, 628
of skull, 69
of sternum, 203
of testicle, 393
of tongue, 130
Tumor albus, 642
Tumors, benign, of bones of extremities, 594
connective-tissue, of salivary glands, 142
of breast, 227
of face, 98
of jaws, 108
of tongue, 133
cystic, behind rectum, 695
of neck, 174
due to chronic pancreatitis, 299
granulation-tissue, of jaws, 111
inflammatory, of intestine, 307
from ileocecal actinomycosis, 307
tuberculosis, 307
intestinal obstruction from, 282
history of, 282
malignant, of breast, 228
of extremities, 556
of epithelial type, 557
of face, 100
of jaws, 113
of kidney, 315. See also *Kidney, malignant tumors of*.
of liver, 296
differential diagnosis, 297
of scalp, 69
of tongue, 134
mixed, of salivary glands, 143
of testicle, 400
of abdomen, 285. See also *Abdomen, tumors of*.
of abdominal wall, 233
of bladder, 376
wall, cystoscopy in, 742
of bones of extremities, 593
of brain, 75. See also *Brain, tumors of*.
of breast, 227
differential diagnosis, 230
of cerebellum, 77
of chest wall, 206
of epididymis, 399
of frontal lobe, 76
of gallbladder, 297
differential diagnosis, 298
of inside of cheeks, 127
of intestine, 307
of jaws, 108
of joints, 626
of kidney, 311
of liver, 291
of lungs, 217
of mediastinum, 219
of mesentery, 310
of middle fossa of skull, 78
of motor region of brain, 76
of muscles of extremities, 572
of neck, 172. See also *Neck, tumors of*.
of nerves of extremities, 574

Tumors of occipital lobe, 77
of omentum, 310
of ovary, large, 324
pedunculated, 324
torsion of pedicles, 273
differential diagnosis, 274
of palate, 127
of pancreas, 303
differential diagnosis, 303
of parietal lobe, 77
of parotid gland, 145
of peritoneum, 310
of pituitary body causing acromegaly, 79
of pleura, 212
of pontomedullocerebellar space, 77
of salivary glands, 141, 142
of scalp, 66
of skin and subcutaneous tissue of extremities, 555
of skull, 72
of spinal cord, 692
of spine, 692
of spleen, 304
of stomach, 289
differential diagnosis, 290
of tendons of extremities, 570
of tendon-sheaths of extremities, 570
of testicle, 399
of umbilicus, 236
of uterus, pedunculated, 324
torsion of pedicles, 273
differential diagnosis, 274
pancreatic, 299
sacrococcygeal, 695
secondary, of ribs or sternum, 207
solid, of neck, 178
of submaxillary salivary gland, 125, 179
vascular, of scalp, 68
Twelfth nerve, injury, in fracture of base of skull, 31
Two-glass test for pus in genito-urinary tract, 381
Tympanites in enterostenosis, 342
in injuries of alimentary canal, 241
Typhoid fever, leukocytosis in, 720
perforation, 268
differential diagnosis, 269
spine, 692
Typhoidal arthritis, 608

Ulcer, blastomycotic, of extremities, 546
cystitic, cystoscopy in, 739
decubital, of extremities, 548
of tongue, 128
dental, 128
duodenal, 332. See also *Ulcer of stomach.*
of bladder, cystoscopy in, 739
of stomach, 332
complications, 333
differential diagnosis, 333
dyspeptic symptoms in, 333
hemorrhage in, 333
hour-glass stomach in, 334
left subphrenic abscess in, 334
leukocytosis in, 723
Ulcer of stomach, nausea in, 333
pain in, 332
perforation in, 333
perigastric adhesions in, 335
symptoms, 332
vomiting in, 333
perforating, of duodenum, 266
differential diagnosis, 267
dullness in flanks and right iliac region in, 267
muscular rigidity in, 266
obliteration of liver dullness in, 266
pain in, 266
pulse in, 267
symptoms, 266
vomiting in, 266
of stomach, 266
differential diagnosis, 267
dullness in flanks and right iliac region in, 267
muscular rigidity in, 266
obliteration of liver dullness in, 266
pain in, 266
pulse in, 267
symptoms, 266
vomiting in, 266
of typhoid fever, 268
differential diagnosis, 269
rodent, of extremities, 557
syphilitic, of extremities, 545
traumatic, of extremities, 544
trophic, of extremities, 546
tuberculous, of extremities, 547
varicose, of leg, 545
Ulceration of lip, 105
of rectum, non-malignant, 354
on back in tertiary syphilis, 201
Ulcerative stomatitis, 123
Ulna and radius, dislocation of, 477
backward, 477
fracture of shaft, 479
of upper end, 477
greenstick fracture of, 480
lesions of, 473
Ulnar nerve, injury of, 437
Umbilical hernia, 417. See also *Hernia, umbilical.*
Umbilicus, abscess discharging through, 256
tumors of, 236
Ungual infection complicating wounds, 532
Urachus, malformations in connection with, 236
patent, cystoscopy in, 744
Ureter, examination of, in renal calculus, 370
with sounds, 732
patulency of, 734
stricture of, 734
Ureteral catheterization, 732
in tuberculosis of kidney, 365
concretions, 735
Ureter-cystoscope, Brenner's, 737
Urethra, congenital malformations of, 379
contusion of, 380
diseases and injuries of, 379
rupture of, 380
in fractures of pelvis, 490

Urethroscopy for localization of pus in genito-urinary tract, 384
Urinary changes in renal calculus, 367
in tuberculosis of kidney, 364
organs, injuries of, symptoms, 241
system, diseases of, leukocytosis in, 724
Urine, cryoscopy of, 747
electric conductivity of, 748
examination of, 732
in renal and vesical lesions, 361
in acute cystitis, 373
Urosepsis, 251, 373
Uterus, myoma of, large, 324
tumor of, pedunculated, 324
torsion of pedicle, 273
differential diagnosis, 274

VARICOSE ulcers of leg, 545
veins of extremities, 562
complications, 563
Vas deferens, inflammation of intra-abdominal portion, 276
Veins, injuries of, 432
of extremities, diseases of, 561
of neck, injuries of, 154
varicose, of extremities, 562
complications, 563
Ventral hernia, 420
Vermiform appendix, hernia of, in inguinal hernia, 409
Vertebræ, dislocations of, 679
pathology, 664
fractures of, 676. See also *Fractures of spine.*
lumbar, fractures of, 678
Vertebral arteries, injuries of, hemorrhage from, 50
artery, injury of, 152
Vertigo in brain tumors, 76
Viscera, abdominal, injuries of, 237. See also *Abdominal viscera, injuries of.*
thoracic, injuries of, 194
non-penetrating or subcutaneous injuries of, 195
Visceral crises, 274
Visual aphasia, 48
Volvulus, 280
constipation in, 280
examination of abdomen in, 280
nausea in, 280
pain in, 280
previous history, 280
shock in, 280
vomiting in, 280
Vomiting after operation, 70
accompanying symptoms, 705
character of vomitus, 705
length of time, 704
in appendicitis, 257
in cancer of stomach, 335
in gallstone colic, 264
in injuries of alimentary canal, 240
in intestinal obstruction, 278
strangulation, 280
in intussusception, 282
in perforating ulcers of stomach and duodenum, 266
Vomiting in tumors of brain, 75
in ulcer of stomach, 333
in volvulus, 280
Vomitus, character of, in postoperative vomiting, 705
von Graefe's symptom in exophthalmic goiter, 189

WANDERING spleen, 304
Warts of scalp, 68
papillary, on extremities, 556
Webbed fingers, 661
White matter of brain, lesions, 47
Woody phlegmon of neck, 161
Word-deafness, 48
Wounds, anthrax complicating, 543
edema complicating, 543
cellulitis of finger or hand complicating, 531
contused, of scalp, 18
in infants and young children, 18
in older children and adults, 20
emphysematous cellulitis complicating, 534
epidermal infection complicating, 531
erysipelas complicating, 535
erysipeloid complicating, 536
glanders complicating, 543
gunshot, of spine, 684
hydrophobia complicating, 542
infection along tendon-sheaths complicating, 532
between muscles and tendons of forearm and arm complicating, 532
in lower extremities complicating, 534
of cutaneous and subcutaneous tissues complicating, 531
infective complications of, 529
lockjaw complicating, 540
malignant edema complicating, 534
of bladder, 372
of Steno's duct, 86
of upper extremities, local infections in, 530
penetrating, of muscles, 428
of scalp, 17
of tendons, 428
of tendon-sheaths, 428
pyemia complicating, 538
differential diagnosis, 540
sapremia complicating, 536
septicemia complicating, 537
differential diagnosis, 540
septicopyemia complicating, 538
stab, of spine, 684
subungual infection complicating, 532
tetanus complicating, 540
ungual infection complicating, 532
Wrist, dislocations of, 484
ganglion of, 570
Wrist-drop, 436
Wrist-joint, diseases of, 629
injuries in vicinity of, 480
Wry-neck, 150

Y-FRACTURES of lower end of humerus, 474

t.6722
Surgical diagnosis 1907
Countway Library
BDV8545
3 2044 045 536 018